

Ten good reasons to practice ultrasound in critical care

Daniel Lichtenstein¹, Simon van Hooland², Paul Elbers³, Manu L.N.G. Malbrain⁴

¹Medical ICU, Hospital Ambroise-Pare, Boulogne (Paris-West University), France

²Nephrology Department, AZ St Lucas Hospital, Ghent, Belgium

³Department of Intensive Care Medicine, Research VUmc Intensive Care (Revive), Institute for Cardiovascular Research (ICaR-VU), Amsterdam, The Netherlands

⁴ICU and High Care Burn Unit, Ziekenhuis Netwerk Antwerpen, ZNA Stuivenberg, B-2060 Antwerp, Belgium

Abstract

Over the past decade, critical care ultrasound has gained its place in the armamentarium of monitoring tools. A greater understanding of lung, abdominal, and vascular ultrasound plus easier access to portable machines have revolutionised the bedside assessment of our ICU patients.

Because ultrasound is not only a diagnostic test, but can also be seen as a component of the physical exam, it has the potential to become the stethoscope of the 21st century. Critical care ultrasound is a combination of simple protocols, with lung ultrasound being a basic application, allowing assessment of urgent diagnoses in combination with therapeutic decisions.

The LUCI (Lung Ultrasound in the Critically Ill) consists of the identification of ten signs: the bat sign (pleural line); lung sliding (seashore sign); the A-lines (horizontal artefact); the quad sign and sinusoid sign indicating pleural effusion; the fractal and tissue-like sign indicating lung consolidation; the B-lines and lung rockets indicating interstitial syndromes; abolished lung sliding with the stratosphere sign suggesting pneumothorax; and the lung point indicating pneumothorax. Two more signs, the lung pulse and the dynamic air bronchogram, are used to distinguish atelectasis from pneumonia. The BLUE protocol (Bedside Lung Ultrasound in Emergency) is a fast protocol (< 3 minutes), also including a vascular (venous) analysis allowing differential diagnosis in patients with acute respiratory failure. With this protocol, it becomes possible to differentiate between pulmonary oedema, pulmonary embolism, pneumonia, chronic obstructive pulmonary disease, asthma, and pneumothorax, each showing specific ultrasound patterns and profiles. The FALLS protocol (Fluid Administration Limited by Lung Sonography) adapts the BLUE protocol to be used in patients with acute circulatory failure. It makes a sequential search for obstructive, cardiogenic, hypovolemic, and distributive shock using simple real-time echocardiography in combination with lung ultrasound, with the appearance of B-lines considered to be the endpoint for fluid therapy. An advantage of lung ultrasound is that the patient is not exposed to radiation, and so the LUCI-FLR project (LUCI favouring limitation of radiation) can be unfolded in trauma patients. Although it has been practiced for 25 years, critical care ultrasound is a relatively young but expanding discipline and can be seen as the stethoscope of the modern intensivist.

In this review, the usefulness and advantages of ultrasound in the critical care setting are discussed in ten points. The emphasis is on a holistic approach, with a central role for lung ultrasound.

Key words: ultrasound, critical care, BLUE protocol, FALLS protocol, LUCI, LUCI-FLR project, SESAME protocol, advantages, lung ultrasound

Anestezjologia Intensywna Terapia 2014, tom XLVI, nr 5, 339–351

Należy cytować wersję z:

Lichtenstein D, van Hooland S, Elbers P, Malbrain MNLG: Ten good reasons to practice ultrasound in critical care, *Anaesthesiol Intensive Ther* 2014, vol. 46, no 5, 323–335.

TESTIMONIAL: A SHORT TRIP BACK TO THE PAST

Being given this exciting request for the International Fluid Academy Days (IFAD, www.fluid-academy.org) gave me the opportunity for a small trip to the past. On a sunny Saturday morning in May 1983, a student was asked to transport a hospitalised lady for an abdominal ultrasound examination. He had little choice but to agree of course, but once in the ultrasound room, after seeing the radiologist nonchalantly manipulating the probe, showing gallbladder and kidney, he felt as if he had been hit by a lightning bolt. So, doctors were able to see the transparency of human beings.

One year later, the student learned the basis of general ultrasound. Another year later, starting a curriculum in intensive care, he used to wait until there was nobody left in the radiology department, in order to borrow discreetly the ultrasound machine. This however was forbidden and inconceivable at that time. Four years later (1989), as the doors of François Jardin's ICU opened, he had the privilege of using the on-site ADR-4000 machine, to learn echocardiography as part of a pioneering team, and to study the examination possibilities of this strange instrument.

One of his first surprises was to see that no one bothered about the critically ill patient, although ultrasound little by little gained its place: the heart for cardiologists, the abdomen for radiologists, and the uterus for obstetricians. The intensivists and emergency physicians were far from the idea of using this tool. A second surprise was to discover, in his day/night work, that what he had been taught was wrong. Especially the dogma regarding the most vital organ (i.e. the lung), stipulating that ultrasound of the lung was not possible (among other misconceptions). An intensivist using general ultrasound in 1989 was very unusual. And applying the probe to 'forbidden areas' (like the lung) was even worse. Attitudes have changed in medicine these last 25 years. From a minor science dedicated to counting gallstones during office hours, ultrasound has become a tool for a visual kind of medicine, able to scan critically ill patients from head to toe, allowing instant modifications of treatment.

Today, laptop machines are very popular in the emergency room (ER) and the intensive care unit (ICU). Modern ultrasound machines are excellent and allow a choice of multiple probes (abdominal, vascular, and cardiac). However, he still uses a 1992-technology-based ultrasound machine (last update in 2008), for a variety of reasons (good analogic image resolution, 32-cm width screen, fast 7-sec start-up time, unique probe allowing the expediting of most protocols, flat and compact design that is easy to clean...). Before the 1992 unit, he used 1982 technology, which was, with 44-cm width, no larger than today's laptops. He felt there was no reason to wait for the revolution of these laptop technologies in order to save lives on-site. So, in all fairness, this article could have been written at any time since 1982.

Daniel Lichtenstein,
medical student in 1983

Over the past decade, critical care ultrasound has gained its place in the armamentarium of monitoring tools [1]. A greater understanding of lung, abdominal, and vascular ultrasound plus easier access to portable machines have revolutionised the bedside assessment of our ICU patients. Because ultrasound is not only a diagnostic test, but can also be seen as a component of the physical exam, it has the potential to become the stethoscope of the 21st century [2]. Critical care ultrasound is a combination of simple protocols, with lung ultrasound being a basic application, allowing the assessment of urgent diagnoses in combination with therapeutic decisions. Ultrasonography is not a new technology. In 1942, Karl Dussik, a neurologist from Vienna, was the first to use ultrasound medically as a diagnostic tool to locate brain tumours and cerebral ventricles. However, what he believed to be anatomical structures were later found to be artefacts [3]. The Frenchman André Dénier was the first to describe possible diagnostic applications for ultrasound [4]. Due to its bedside availability, absence of radiation, good reproducibility and cost efficiency, ultrasound has subsequently gained widespread popularity in many specialties [5, 6]. Data from health care registries

shows a rapid rise in the number of ultrasound studies being performed. And, even more interestingly, an estimated two thirds of these studies are being performed by clinicians instead of radiologists. This revolution can be explained by the huge advantages clinicians gain by performing bedside ultrasound. They can directly interpret the images in their clinical context and the examination can be performed 24/7 without the need for external consultants. In addition, ultrasound studies can be easily repeated, allowing assessment of therapeutic effects.

These advantages are of even greater value in the setting of critical care medicine, as immediate decision making can be life saving. Thus, the use of ultrasound is now rapidly spreading in ICUs worldwide. However, it is the development of lung ultrasound that has unleashed the true potential of the technique to the critical care provider [1, 5, 7–12]. Until recently, the lung was considered 'forbidden territory' for ultrasound and a change of attitude was needed [11]. It is true that direct visualisation of the lung parenchyma is often difficult or impossible with ultrasound. However, lung ultrasound interpretation is based on the analysis of sonographic artefacts that arise from interactions of the ul-

trasound beams with tissue media having different acoustic impedance. This has given rise to a new ultrasound language, including comet-tail reverberation artefacts, called B lines [13], the description of the interstitial syndrome [14] and the BLUE (*bedside lung ultrasound in emergency*) protocol [7]. This has changed the way we work in intensive care medicine, and even more importantly helped to improve patient outcome.

It is against this background that we here present ten good reasons why you should start performing critical care ultrasound.

TEN GOOD REASONS

ULTRASOUND IS HELPFUL IN DIFFERENTIAL DIAGNOSIS OF ACUTE RESPIRATORY FAILURE

In the early days, lung ultrasound was considered not to be feasible. Yet all signs and symptoms of the artefacts would have been readily available with the 1982 ADR-4000 machine. Little by little, despite many rejections, the initial protocols and study materials were published. The BLUE protocol is one application among many others describing the clinical relevance of lung ultrasound in the critically ill (LUCI), namely in the differential diagnosis of an acute respiratory failure [7].

In the BLUE protocol, the three standardised examination points are the upper BLUE point, the lower BLUE point, and the PLAPS point (Fig. 1) [15]. The BLUE protocol uses the *seven principles* of LUCI. In brief, these are: 1) a simple technique, and the simplest machine is the most suitable; 2) in the thorax, air and water are mixed, generating specific ultrasound signs and signatures and artefacts; 3) the lung is the most voluminous organ, but adapted points for analysis,

the BLUE points (Fig. 1), allow for standardised scanning; 4) all signs and artefacts start from the pleural line, a basic landmark; 5) the artefacts, usually considered as annoying limitations of ultrasound, are of specific interest [16]; 6) the lung is a vital organ that moves, therefore dynamic analysis is crucial with lung sliding being the basic dynamic sign of normality; and 7) all acute, life-threatening disorders are superficially located around the pleural line, creating a window for LUCI.

The BLUE protocol is easy, if the user agrees to follow each simple step. The BLUE protocol uses the 7th principle to identify and describe ten signs allowing the diagnosis of the *six most frequently seen acute diseases* (not the most easy to diagnose) by creating *eight profiles* yielding an overall 90.5% accuracy [7]. The pleural line generates the **bat** sign, a permanent landmark indicating the parietal pleura (Fig. 2). Lung **sliding** and the **A-line** define the normal lung surface. They indicate gas movement and sliding of the parietal and visceral pleura with to-and-fro movements. M-mode helps to understand this movement and results in the **seashore** sign (Fig. 2). The **quad** sign and the **sinusoid** sign are standardised signs allowing the diagnosis of a pleural effusion, regardless of its volume or echogenicity. The probe is applied at the PLAPS point, a posterior area accessible in the supine position (Fig. 1). The boundaries of the collection are regular, and a quadri-angular surface can be drawn (the quad sign). The sinusoid sign is drawn by the visceral pleura moving towards the pleural line during inspiration. This is illustrated in Figure 3 [17]. The **shred** (or fractal) sign and the **tissue-like** signs are used for diagnosing a lung consolidation. The shred sign corresponds to nontranslobar consolidations, with an irregular border between aerated

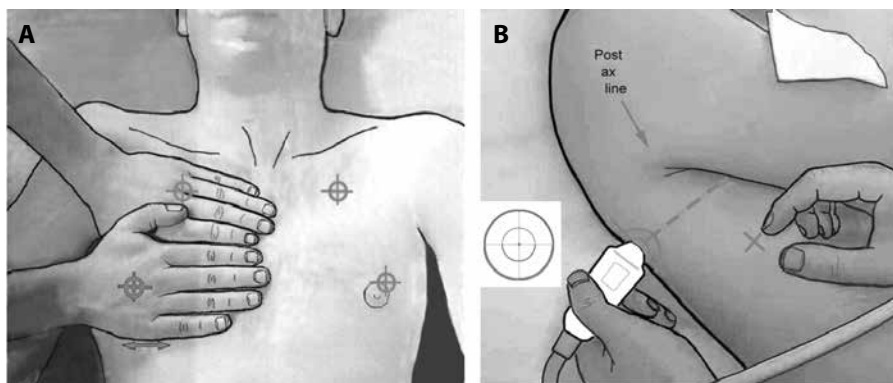


Figure 1. Areas of investigation showing the standardised examination BLUE points; **A** — two hands placed this way (size equivalent to the patient's hands, upper hand touching the clavicle, thumbs excluded) correspond to the location of the lung, and allow three standardised points to be defined. The upper-BLUE point is at the middle of the upper hand. The lower-BLUE point is at the middle of the lower palm; **B** — the PLAPS point is defined by the intersection of a horizontal line at the level of the lower BLUE point and a vertical line at the posterior axillary line. Small probes allow positioning posterior to this line as far as possible in supine patients, providing more sensitive detection of posterolateral alveolar or pleural syndromes (PLAPS). The diaphragm is usually at the lower end of the lower hand. Adapted from 'Lung ultrasound in the critically ill' [11]

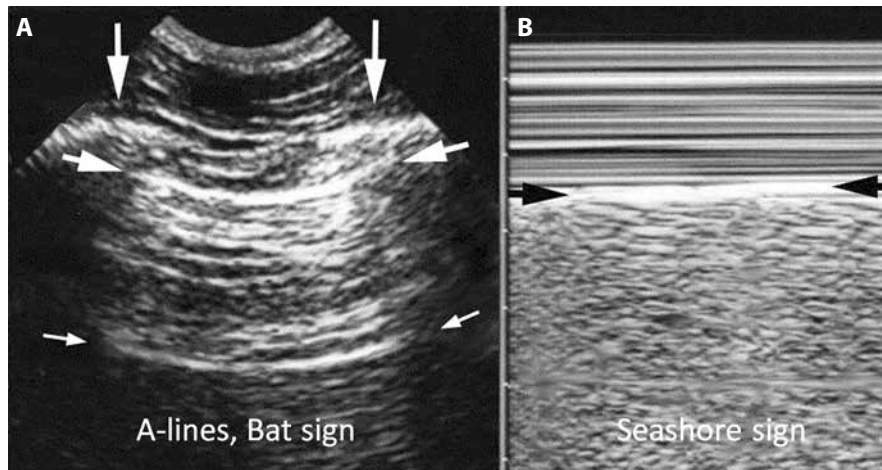


Figure 2. Ultrasound scan of the anterior intercostal space: bat and seashore sign; **A** — the ribs (vertical arrows) with shadows are visualised. The pleural line (upper, horizontal arrows), is a horizontal hyperechogenic line, half a centimetre below the rib line in adults. The association of ribs and pleural line make a solid landmark called the bat sign. The pleural line indicates the parietal pleura. The horizontal repetition artefact of the pleural line is called the A-line (lower, small horizontal arrows). The A-line indicates that air is the main component visible below the pleural line; **B** — M-mode reveals the seashore sign, which indicates that the lung moves at the level of the chest wall. The seashore sign therefore indicates that the pleural line also is the visceral pleura. Above the pleural line, the motionless chest wall displays a stratified pattern. Below the pleural line, the dynamics of lung sliding show a sandy pattern. Note that both images are strictly aligned, of importance in critical settings. Both images, i.e. lung sliding plus A-lines, define the A-profile (when found at the anterior chest wall). Adapted from 'Lung ultrasound in the critically ill' [11]

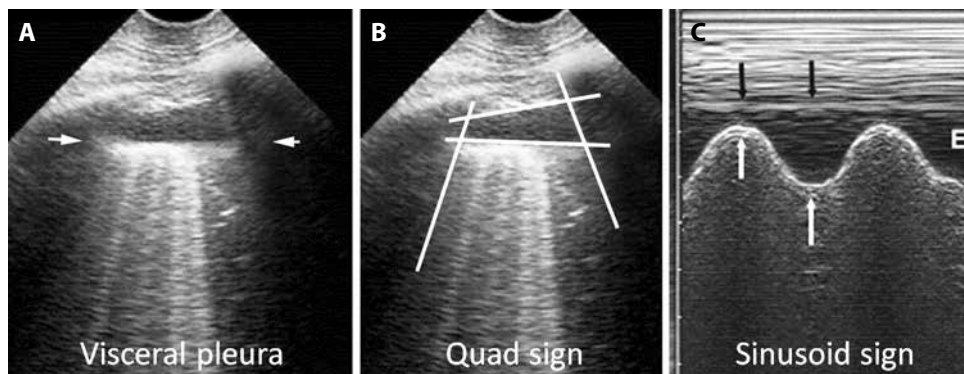


Figure 3. Examination of pleural effusions: quad and sinusoid sign; **A** — ultrasound examination of pleural effusion at the PLAPS point. Below the pleural line, a regular line roughly parallel to the pleural line can be seen: the lung line, indicating the visceral pleura (arrows); **B** — the visceral pleura (lung line), together with the parietal pleura (pleural line) and the shadow of the ribs, form a kind of quadrant: the quad sign; **C** — M-mode shows movement of the lung line or visceral pleura (white arrows) towards the pleural line or parietal pleura (black arrows) on inspiration, creating the sinusoid sign compatible with free pleural effusion. Quantitative data: this effusion found at the PLAPS point has an expiratory thickness of roughly 13 mm, i.e. an expectedly small volume. A 15-mm distance is the minimum required for safe diagnostic or therapeutic puncture [17]. E indicates expiration. Adapted from 'Lung ultrasound in the critically ill' [11]

and consolidated lung regions. The tissue sign is seen in translobar consolidation as it looks like liver parenchyma. This is illustrated in Figure 4. Lung rockets are a sign of interstitial syndrome with 93% accuracy [14]. The B-line is always a comet-tail artefact, arising from the pleural line and co-occurring with lung-sliding [18–24]. B-lines are almost always long, well-defined, laser-like, and hyperechogenic, erasing A-lines as illustrated in Figure 5. A rocket sign consists of three or more B-lines between two ribs [5]. Abolished lung sliding and exclusive A-lines are a basic sign of pneumothorax, with 95% sensitivity and 100% negative predictive value [25–27]. In a case of pneumothorax, a motionless pleural line can be

observed in M-mode generating the stratosphere sign as shown in Figure 6. Visualisation of the lung point allows the ruling in of pneumothorax (Fig. 7) [28].

In order to be clinically helpful, the BLUE protocol defines eight profiles, correlated with six diseases seen in 97% of the patients admitted to the ICU [7]. A consolidation is not a diagnosis, but, incorporated into a specific profile, it contributes to making the correct diagnosis (not necessarily pneumonia). The A, A', B, B', A/B and C-profiles can all be identified at the anterior chest wall in supine patients.

The A-profile defines a normal lung surface. Associated with a deep venous thrombosis, it makes the diagnosis of

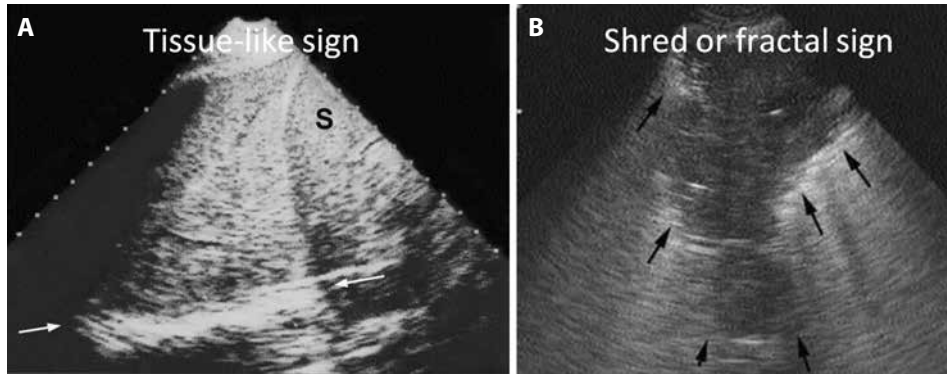


Figure 4. Lung consolidation: shred, fractal and tissue-like sign; **A** — a massive consolidation (probe at the PLAPS point) of the whole left lower lobe. No aerated lung tissue is present, and no fractal sign can be generated. The lower border is at the level of the mediastinal line (arrows). The pattern is tissue-like, similar to the spleen (S). The thickness of this image is roughly 10 cm, a value incompatible with a pleural effusion. Quantitative data: the 10-cm depth would correspond to a volume of roughly 1 L; **B** — partial right middle lobe consolidation. This generates a shredded, fractal boundary between the consolidation and the underlying aerated lung (arrows). This is the quite specific shred (or fractal) sign as opposed to the regular lung line in a case of pleural effusion. This anterior consolidation generates the C-profile in the BLUE protocol. Quantitative data: the thickness at the right image is 5.5 cm, corresponding to a 165-mL consolidation, roughly. Adapted from 'Lung ultrasound in the critically ill' [11]

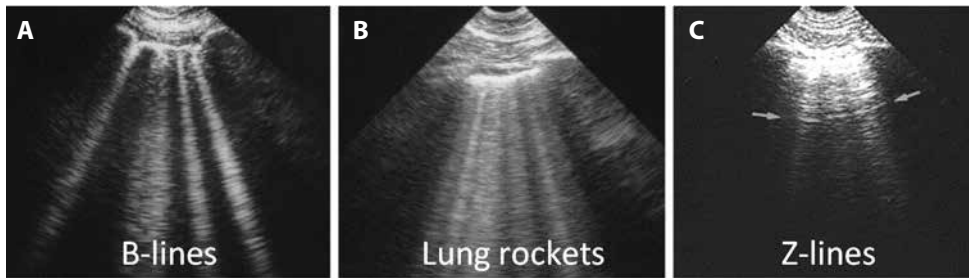


Figure 5. Interstitial syndrome: lung-rockets; **A** — presence of four or five B-lines, called lung rockets (here septal rockets correlating with thickened subpleural interlobular septa), suggestive for lung oedema; **B** — presence of twice as many B-lines, called ground-glass rockets. Suggestive for severe pulmonary oedema (with ground glass areas on CT); **C** — Z-lines for comparison. These 'parasites' are ill-defined, short, and do not erase A-lines (arrows). Adapted from 'Lung ultrasound in the critically ill' [11]

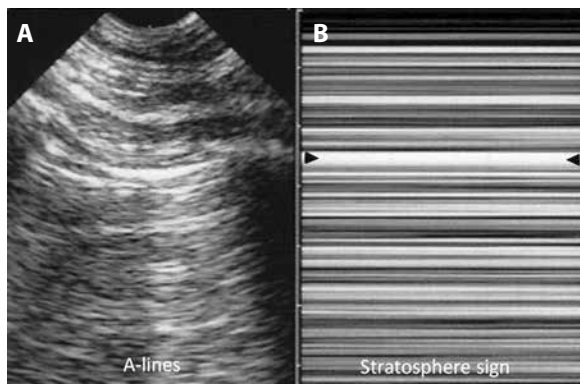


Figure 6. Pneumothorax: stratosphere sign; **A** — pleural line with A-lines, indicating gas below the pleural line. Although not visible on the left image, lung sliding was totally absent; **B** — on M-mode, the abolition of lung sliding is visible through the stratosphere sign (which replaces the seashore sign) and indicates total absence of motion. This suggests pneumothorax as a possible cause. Arrows indicate location of the pleural line. The combination of abolished lung sliding with A-lines, at the anterior chest wall, is the A'-profile of the BLUE protocol (as opposed to the A-profile, where lung sliding is present, ruling out pneumothorax). Adapted from 'Lung ultrasound in the critically ill' [11]

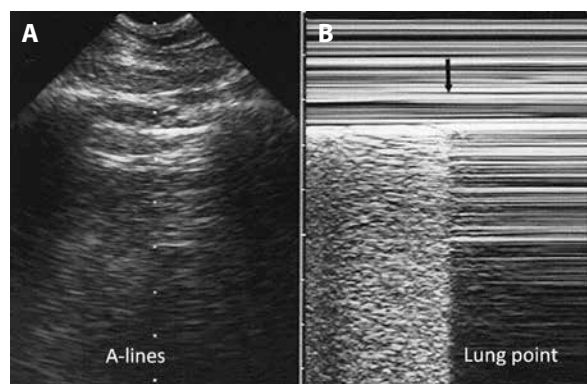


Figure 7. Pneumothorax at the lung point; **A** — real-time mode allows detection of the inspiratory increase in volume of the collapsed lung. When reaching the chest wall where the probe is positioned, it makes a sudden change in the ultrasound image, usually from an A'-profile to an A- or B-profile. The change is sudden because ultrasound is a highly sensitive method, able to detect subtle changes, such as the difference between free gas and alveolar gas; **B** — M-mode. The left-hand side of the image shows lung patterns (lung sliding) before the visceral pleura disappears. The arrow shows the exact moment the visceral pleura is no longer in contact with the pleura line. The right-hand side image shows the A'-profile (lung sliding abolished with A-lines). This sign has been called lung point, a specific sign of pneumothorax. Adapted from 'Lung ultrasound in the critically ill' [11]

pulmonary embolism with 99% specificity. In combination with the absence of a deep venous thrombosis (DVT) and the presence of a postero-lateral alveolar and/or pleural syndrome (called PLAPS), it highly suggests the diagnosis of pneumonia (specificity 96%). In a case of absence of DVT and PLAPS, this profile is called the **nude profile** which correlates with severe asthma or COPD (specificity 97%).

The **A'-profile**, defined as abolished lung sliding with exclusive A-lines, is suggestive of pneumothorax, and makes mandatory the detection of a lung point, a specific sign of pneumothorax. The lung point shows, at the area of inspiratory contact of the lung with the wall, sudden changes, from an A'-profile to lung sliding or lung rockets.

The **B-profile** associates anterior lung sliding with anterior lung rockets, and highly suggests acute cardiovascular pulmonary oedema (specificity 95%).

The **B'-profile** combines abolished lung sliding with lung rockets, and is also correlated with pneumonia (specificity 100%).

The **A/B-profile**, i.e. unilateral lung rockets, suggests pneumonia (specificity 100%).

The **C-profile** defines anterior lung consolidations (from large parenchymal volumes to a simple thickened, irregular pleural line) and again suggests pneumonia (specificity 99%).

Each of these eight profiles is supported by the pathophysiology (Fig. 8). Each profile can be assessed in less (sometimes much less) than three minutes, making the BLUE protocol a really fast protocol. A recent meta-analysis confirmed the usefulness of lung ultrasound and concluded that, when conducted by highly-skilled sonographers, ultrasound performs well for the diagnosis of pneumonia [29]. General practitioners and emergency medicine physicians should be encouraged to learn LUCI since it appears to be an established diagnostic tool in the hands of experienced physicians [29, 30].

There are of course limitations, such as the presence of pulmonary embolism without DVT. This issue, and many other questions, are discussed elsewhere [31, 32]. Examination of the heart itself is not included, since the BLUE protocol provides only a direct analysis of the lungs. Some rare conditions resulting in respiratory failure (like chronic interstitial syndrome, fat embolism, tracheal stenosis, etc.)

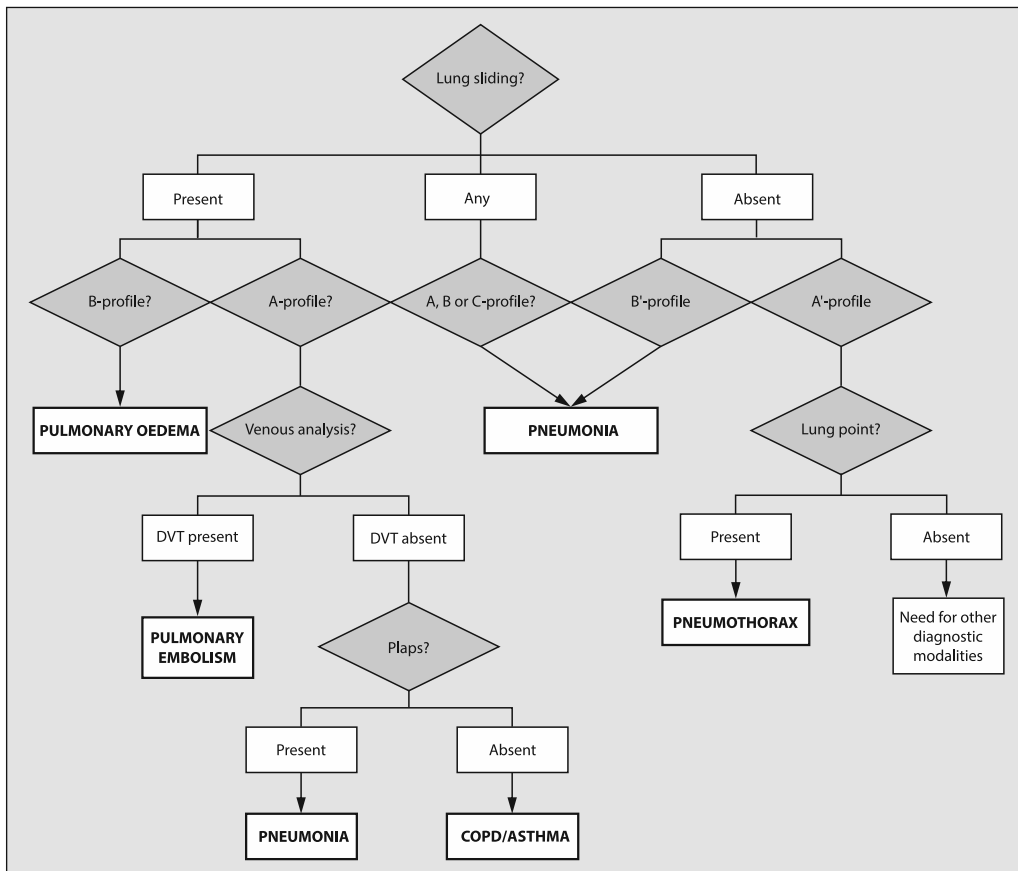


Figure 8. The modified BLUE protocol starting at the upper and lower BLUE points looking for lung sliding, and moving to the PLAPS point allows immediate differential diagnosis of the main causes of acute respiratory failure using lung and venous ultrasound. The decision tree should only be seen a guidance for diagnosis (with an accuracy of around 90%). Adapted from [7]. PLAPS = Postero Lateral Alveolar and/or Pleural Syndrome. COPD = chronic obstructive pulmonary disease. See text for explanation.

are not included for the sake of simplicity. They are indeed numerous, but apply to only 3% of the patients seen in the ER for acute respiratory failure, and many of these conditions can be diagnosed using other classical tools. As an example, a massive pleural effusion is rare, but not difficult to diagnose. In bedside lung ultrasound, the operator should be aware and interpret double lung point, septate pneumothorax and hydro-point. The conventional diagnostic protocol of bedside lung ultrasound for pneumothorax should be occasionally adapted to such complex cases [33]. Chronic interstitial diseases, yielding the B-profile, require identification of some subtle signs that will be incorporated in the Extended BLUE (E-BLUE) protocol. It is important to realise that the BLUE protocol is just a tool, at its best only when fully integrated in the clinical examination, in other words

as the modern stethoscope. Clinical data will be included in the E-BLUE protocol in the near future.

**ACUTE CIRCULATORY FAILURE:
A NICE, SECOND GOOD REASON**

One feature of holistic ultrasound is its ability to combine examination of lung and heart. This is referred to as emergency cardiac sonography that combines some elements of the BLUE protocol for the management of acute circulatory failure. This is not ‘echo’ (an expert field for cardiologists), nor is it ‘ultrasound’, a term too redolent of the radiological world. The FALLS protocol (Fluid Administration Limited by Lung Sonography) uses the potential of lung ultrasound for the early demonstration of fluid overload at an infra-clinical level [34]). The FALLS protocol is based on Weil and Shu-

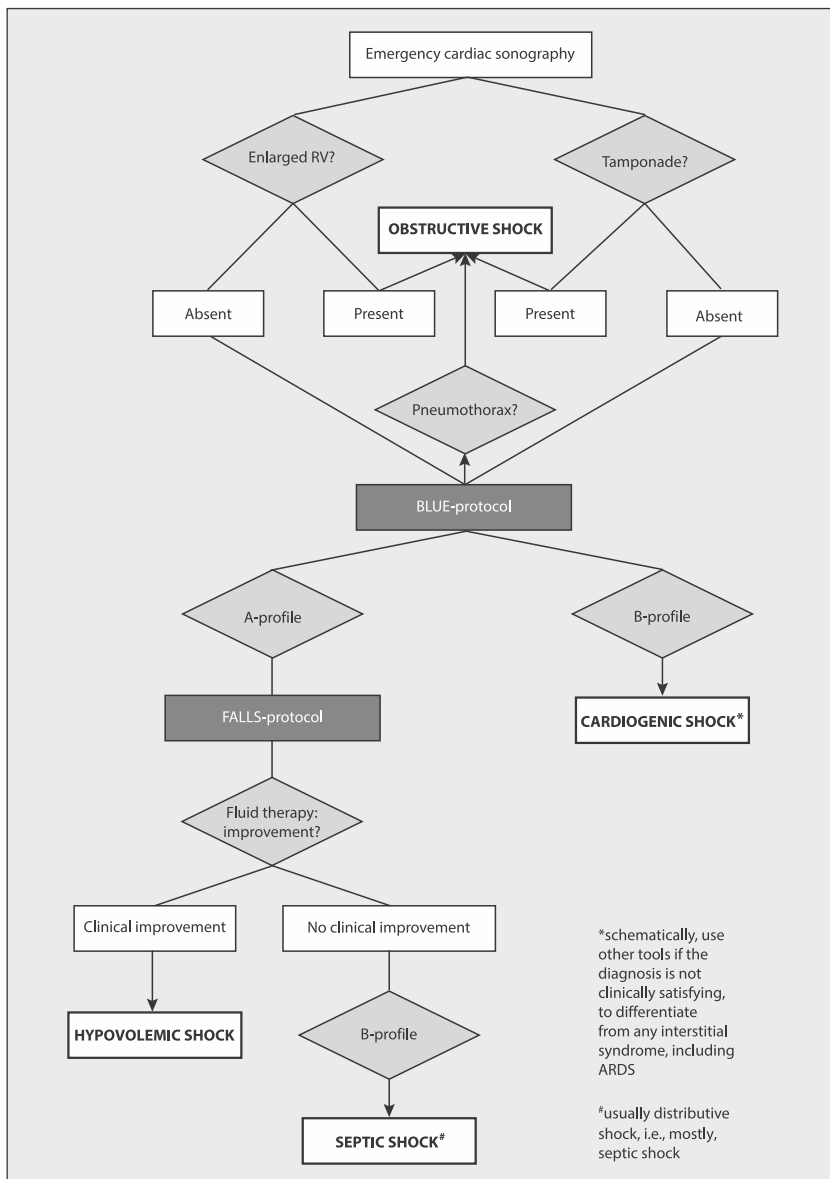


Figure 9. The FALLS protocol. A decision tree facilitating the understanding of the FALLS protocol. According to the Weil classification, cardiac and lung ultrasound sequentially rule out obstructive, cardiogenic (from left heart), hypovolemic and finally distributive shock, i.e. septic shock in current practice. Adapted from [34]. FALLS protocol = Fluid Administration Limited by Lung Sonography; BLUE protocol = Bedside Lung Ultrasound in Emergency; RV = right ventricle

bin's classification, considering firstly obstructive shock, followed by cardiogenic, hypovolemic and finally distributive shock [35]. The decision tree is illustrated in Figure 9.

The FALLS protocol searches sequentially for: 1) substantial pericardial fluid; 2) a dilated right ventricle; and 3) an A'-profile. Obstructive shock is reasonably ruled out in a case of absence of tamponade, pulmonary embolism, or pneumothorax; 4) The B-profile is sought. In its absence, a cardiogenic shock from left origin (i.e. the vast majority) is, by definition, ruled out. At this stage, the patient has neither the B-profile nor the A'-profile, and thus usually has the A-profile or its equivalents (A/B profile, C-on-A-profile) and is called a FALLS-responder. This patient can have either hypovolemic or distributive shock, and will benefit, in both cases, from fluid administration.

This is the therapeutic part of the FALLS protocol. The recovery of a circulatory failure under fluid therapy defines the hypovolemic shock. If the shock state persists despite fluid therapy, there will however be no indication for discontinuation. Ongoing fluid therapy may eventually generate a subclinical interstitial syndrome that can be immediately detected as A-lines will change to B-lines. This change occurs at a pulmonary artery occlusion pressure (PAOP) value of 18 mm Hg (with 97% safety), or 13 mm Hg (with 93% safety). The transformation from A-lines to lung rockets defines, in the FALLS protocol, the presence of distributive shock, i.e. in current practice septic shock. Previous fluid therapy has proven to be inefficient in this situation, and the appearance of B-lines indicates the discontinuation of further fluid administration (this is the FALLS-endpoint) and other therapies should be initiated to improve the circulatory status (usually vasoactive drugs like dobutamine or norepinephrine).

This is a very schematic description of a protocol that of course needs much more development (comprehensive work is in preparation). Among many frequently asked questions, we choose one which probably highlights the idea behind the FALLS protocol: 'Can the FALLS protocol really manage a shocked patient without knowing the cardiac output?' By determining who should receive fluids, and when to discontinue fluids, the FALLS protocol is able to support a diagnosis. Monitoring CO in a known condition is another setting with different rules.

CARDIAC ARREST: A THIRD LEGITIMATE REASON

In cardiac arrest, every second counts. The idea of using ultrasound perhaps seems 'crazy' in such a setting. But this is precisely what was done in the past to manage patients long before the advent of laptop machines. This is an opportunity to describe in more detail the 1992 Japanese ultrasound device used at our institution (last update in 2008). With a 32 cm width, it can be brought immediately

to the bedside, and we ask readers to compare these dimensions with those of current laptops. A start-up time of only seven seconds is a critical advantage here (again, please compare), and greatly helps daily routine duties in the ICU. One probe allows a whole body investigation: heart, lungs, veins, abdomen, i.e. our protocol for cardiac arrest. This probe, probably the probe of the future for the young community, is neither cardiac nor vascular nor abdominal. Its microconvex shape allows its insertion at any site, very narrow as well as large, linear or not, deep or superficial (from 1–17 cm penetration). The machine has one setting, used for everyday applications, which means that no change is required for it to be immediately operational. No filter, no time lag, no harmonics that can confuse in detecting artefacts or analysing dynamic events. This is not the setting 'lung' (as we can see increasingly available as preset on modern machines), this is the setting 'critical ultrasound', i.e. not especially the lung but the veins, heart, abdomen, optic nerve etc. We need the same settings for a fast assessment of the whole body.

Now, we can scan this cardiac arrest, in a sequence adapted to its likely origin and to logic using the SESAME protocol, a suitable abbreviation of the long abbreviation SESAMOOSIC, standing for 'Sequential Emergency Scanning Assessing Mechanism Or Origin of Shock of Indistinct Cause'. The SESAME protocol suggests starting with a lung scan for three major reasons [36]. Firstly, pneumothorax (as a cause) can be ruled out. Secondly, half of the diagnosis of pulmonary embolism is done following the rules of the BLUE protocol. Thirdly, an immediate clearance for fluid therapy can be ordered, following the rules of the FALLS protocol. All of this can be obtained in just a few seconds or minutes, i.e. a minimal hindrance during the course of resuscitation. The SESAME protocol continues by scanning the abdomen in trauma patients to detect a massive bleeding, or the lower femoral veins in non trauma patients for the second half of the diagnosis of pulmonary embolism (specificity 99%). Next comes the pericardium, which is straightforward in a case of a pericardial tamponade, as this usually creates a suitable window.

When pneumothorax, hypovolemia, pulmonary embolism and tamponade have been ruled out (four major and highly reversible causes), we must then scan the heart itself. Here, the user takes the responsibility of interrupting the cardiac compressions with no certainty of having a suitable window (as opposed to the lung step). The scan, best performed via subcostal window, or at worst, parasternally (necessitating removal of the hands during external heart compression), can detect various dynamic changes suggesting ventricular fibrillation, auriculo-ventricular blockade, or again asystole.

The SESAME protocol does not require any validation, since these applications already belong to the domain of ultrasound. The user just has to work faster (with a suitable machine enabling the speeding up of this ultrafast protocol).

ASSISTANCE DURING VENOUS CANNULATION

Venous cannulation is a 'natural' application, which can also be used in cardiac resuscitation. ICU physicians have all cannulated veins using the blind methods, and mostly succeeded. Yet the word 'mostly' is not sufficient for those who aim for a zero fault rate (i.e. being inspired by aviation rules). Since 1989, we have become accustomed to cannulating our veins using ultrasound (the technology was suitable, at the bedside, before laptop machines). We have always preferred the subclavian (infraclavicular) vein because of its low rate of infectious complications. We have always preferred to see the whole needle through its route in the soft tissues, favouring our self-taught approach that was called later the 'in-plane' technique [37]. Our micro-convex probe makes everything easier: it is easily held, and can expose the vein at short-axis or long-axis easily (without condemning the user to follow anatomical constraints). Using permanent control, the risk of pneumothorax appears quite impossible (and in any case it would be detected immediately using the post-catheter ultrasound control). The infraclavicular subclavian vein is sometimes the only available venous access site in trauma patients with cervical collars, G-suits, etc.

The advantages of ultrasound-guided central **venous catheter** placement include correct identification of the vein, detection of variable anatomy and intravascular thrombi, and the avoidance of inadvertent arterial puncture [38]. It is safer and less time-consuming than the classical landmark technique, especially in patients with coagulopathy or thrombopenia [39]. In cardiac arrest, once a massive bleeding has been detected, if some intratracheal epinephrine has succeeded in a temporary return of spontaneous circulation (ROSC), it is certainly time to insert a catheter, if possible a large, but not necessarily long, one. Our use of ultrasound allows us, without any probe change, during a SESAME protocol, to make use of this application.

Ultrasound guided **arterial cannulation** helps in reducing the number of attempts, shortening the procedure time, and increasing the success rate, including in children [38, 39].

ASSESSING ARDS (OR ANY CRITICALLY ILL LUNG UNDER MECHANICAL VENTILATION)

Ultrasound can help to guide airway management in a patient with acute respiratory distress who needs to be intubated and mechanically ventilated, as it can predict the difficult airway or sleep apnoea, the proper ETT size, or confirm proper ETT placement, etc. [38]. The intensivists

works most comfortably when the greatest possible amount of information on the patient is available. The lung is the first vital organ. The bedside radiograph, apart from the stethoscope, used to be the only tool for bedside assessment. CT is not an easy option in ARDS, as the patient in this setting is often ventilated and difficult to transport. This is why the concept of using lung ultrasound in ARDS may be termed the PINK protocol, by avoiding desaturation (and 'blue' cyanosis) during CT. The PINK protocol uses the ten signs of LUCI, already described in the BLUE protocol section, with no adaptation: they work in the same way in ARDS patients. The intensivists will therefore know, for a given patient, the amount of pleural fluid that can be withdrawn. We have never used ultrasound when inserting a needle for withdrawing pleural fluid, because it complicates a procedure, which, based on the logic, is extremely simple (equally, we will never insert a needle without ultrasound having been done immediately before).

The amount of lung consolidation can be assessed semi-quantitatively, by determining the area of maximal consolidation (our consolidation index, based on simplicity), and can be followed up on a daily basis, for example after changing ventilator settings. Baro- or volutrauma can be immediately detected with LUCI. Critical care ultrasound not only helps to establish a diagnosis but also to install a specific therapeutic action. In ARDS, all types of pneumothorax can occur, from free cases (giving classical A'-profile and lung point) to more complex, septated cases.

FINDING THE CAUSE OF A FEVER IN AN ICU PATIENT

Fever of unknown origin (FUO) is frequent, but fever of unknown sonographic origin (FUSO) is rare!

Fever in the ICU is one reason for performing whole body ultrasound in a sequential way, considering the most frequent and easy-to-diagnose causes, apart from the visible ones (skin troubles) and those which do not require first-line ultrasound (urinary infection) [40]. Usually, we find a (possibly infected) jugular internal thrombosis, or a maxillary sinusitis, showing the sensitive and specific sinusogram [41], but the most substantial contribution is probably the acquired pneumonia. We benefit from the allocated space for developing simple ways for distinguishing pneumonia from atelectases as frequently seen after several days of mechanical ventilation.

The resorption atelectasis can be diagnosed as soon as it appears, as can be illustrated by a pseudo-experimental model of complete, bilateral obstructive atelectasis, i.e. a deep breath followed by apnoea. The saturation rapidly drops after apnoea, causing an unstable situation. During this manoeuvre, instantaneously, lung sliding is abolished, at the whole lung surface. Usually, equivalents of lung sliding such as the lung pulse are present, avoiding the regrettable

diagnosis of pneumothorax. Abolished lung sliding with the lung pulse is one immediate sign. With time passing (few volunteer apnoeists would reach this stage), the gas in the lungs is resorbed, resulting in a whole lung consolidation with all criteria of volume decreasing as evidenced by elevated diaphragmatic cupola and heart attraction. If gas is still present, it is supposed to be static causing the static air bronchogram. A dynamic air bronchogram rules out obstructive atelectasis [42].

A substantial lung consolidation with conserved lung sliding, no loss of volume, and dynamic air bronchograms, is probably pneumonia. The pleural fluid usually present can be punctured, although it has low risks of showing positive cultures in patients drowned with antibiotics. Note that the distinction between pneumonia and atelectasis belongs to the domain of the PINK protocol, not the BLUE protocol (which does not deal with rare causes of acute respiratory failure). Abdominal causes are less frequent causes of fever (as will be discussed).

DECREASING RADIATION DOSES WHILE IMPROVING PATIENT MANAGEMENT (AND CONTRIBUTING TO HUGE COST SAVINGS): THE LUCI-FLR PROGRAMME

X-rays and CT-scans are of great interest, but have significant drawbacks too, i.e. the huge radiation doses — not to mention some other side effects of CT (e.g. need for transportation, risks of iodine injection).

Lung ultrasound can answer clinical problems with more accuracy than bedside radiographs, and with roughly the same accuracy as CT. In some instances, ultrasound is superior (e.g. assessment of pleural septations, necrosis within consolidations, dynamic air bronchograms, diaphragmatic dynamics and lung sliding). Ultrasound provides accurate quantitative data regarding the volume of pleural effusions, lung consolidations, and pneumothorax (the lung point location gives a real-time idea of the pneumothorax volume) [28, 43, 44]. LUCI therefore appears as a reasonable, fully operational, bedside gold standard.

Lung Ultrasound in the Critically Ill Favouring Limitation of Radiation, the LUCI-FLR programme, is a way of answering clinical questions while bypassing traditional imaging tools [11, 30]. The aim of the LUCI-FLR programme is to decrease, over the next 30 years, urgent X-rays by one third, and urgent thoracic CT by two thirds. This is what one may call a 'reasonable target'. We will explain some aspects of this project (which is no longer a project but increasingly a reality as it has already begun).

The LUCI-FLR project aims at limiting traditional radiographic diagnostic tools. The idea of eradicating bedside radiographs, heralded by some, indicates a limited knowledge of the limitations of ultrasound and would be a scary idea. On the contrary, we must keep all our skills in order

to interpret correctly bedside radiographs. Ultrasound and radiography can on occasion be complementary. We give a basic example around a simple idiopathic pneumothorax. We admit that the first radiograph showing the disease, although not mandatory, makes an acceptable irradiation. The tube is inserted. The transformation from an A'-profile to an A-profile indicates that the lung is at the chest wall. No need for X-ray. The persistence of an A'-profile with a lung point indicates the opposite, even if a radiograph has been done and seems normal. No need for CT. In the first case, the tube will be clamped, with checking by lung ultrasound, and we will see one of the two previous possibilities: either the lung remains on the chest wall in spite of the clamping, or the culprit lesion in the visceral pleura remains unsealed.

All physicians using ultrasound in this way are avoiding excessive irradiation in their clinical practice and are taking part in the LUCI-FLR programme. There is no need for multicentre validations. All the relevant articles have been published and validated. One just has to choose the right tool that makes LUCI easy, and learn it the right way. This is the LUCI-FLR programme. It is safer for patients, limits radiation, and saves costs.

PRACTICING A HOLISTIC APPROACH TO THE HEART

In the 1950s, the heart was the only 'raison d'être' for ultrasound, and cardiologists took advantage of this. One result was the development of an expert discipline. Even today, learning echocardiography for non-cardiologists remains an adventure. One of the aims of LUCI and its protocols (BLUE protocol, FALLS protocol) is to help simplify the cardiac part, just in case the suitable acoustic windows would be of poor quality (or even missing). And remember that there are numerous ICU physicians who have no echocardiographic machine at all.

Sophisticated calculations of the systolic and diastolic functions of the left ventricle, using up-to-date, costly, machines, is one approach. Detecting an A-profile on lung ultrasound is another approach, as seen in the BLUE protocol (if there is no B-profile, there is no pulmonary oedema) and the FALLS protocol (if there is no B-profile, there is no cardiogenic shock from left origin). We refer again to what we said above regarding CO measurements, since we must treat the patient and not the numbers.

To confirm pulmonary embolism, powerful algorithms are developed that work at the bedside, but the BLUE protocol has made the diagnosis readily available (by looking just at the lungs and the veins), while the heavy and powerful echocardiographic machine is still starting up. Non-cardiologists like intensivists and emergency physicians are currently developing guidelines for teaching the 'basics' of echocardiography [45]. Without adding the lung (and veins), these guidelines may contribute to an incomplete knowledge of critical care ultrasound.

PRACTICING MEDICINE IN A NEW WAY, A VISUALISING MODERN TOOL FOR ALL

The patient is the first to benefit from an immediate, on-site, noninvasive visual diagnosis. Any physician should appreciate this new dimension, which allows a new feeling of comfort in the difficult ICU environment. Ultrasound is not only the stethoscope of the 21st century, but could even be considered as an 'anti-ageing drug'. Every step of the diagnostic process is made lighter, more confident, allowing for more sleep during on calls, helping the brain to perform better when lives need to be saved. Using ultrasound is a challenging opportunity and should not be a cumbersome obligation. We have already given an example (under reason 5), of the need to use ultrasound during thoracentesis. Having used the tool thousands of times for decades, we are always glad to find a diagnosis without ultrasound, using just our clinical examination. Ultrasound is a wonderful tool, but only a tool. It can sometimes be difficult to handle, or can have a breakdown, or storage problems. But it helps the physician to improve his/her clinical skills: if a pleural effusion was clinically missed, but is confidently objectified using ultrasound, one can again perform percussion, auscultation, and learn to master these subtle signs. In a standard ICU, ultrasound is greatly appreciated by the nursing team, as many trips to the CT will now become unnecessary. Finally, the hospital CEO will be delighted to make savings.

LET THE READERS CHOOSE THEIR OWN FINAL 'CUSTOM-MADE' REASON

Ultrasound is such a multifaceted tool that any user will highlight one of its potential uses. For some, it will be the comfort of knowing that this particular patient has a free lower limb venous network. For others, knowing that the GI tract of a patient receives oxygen (unless it would die from mesenteric infarction) as the visualisation of a peristalsis is a reassuring dynamic sign. For doctors who make airborne missions, knowing that a patient who will be transported over the ocean has no floating venous thrombosis, no incipient bladder retention, no occult pneumothorax, or some other condition, is priceless. It allows them to conclude that the flight will be safe (our ULTIMAT protocol, Ultrasound Lump Test Initiating Medical Airborne Transportation). Other examples are legion: 1) In emergency medicine? Detecting free fluid (i.e. usually, blood) in a young patient admitted for an apparently ordinary blunt abdominal trauma, immediately changes the management; 2) In anaesthesiology? Some doctors need to inject fluids around the nerves and want to see where they are: ultrasound provides good visual guidance (although alternative tools exist) during regional anaesthesia or neuraxial and chronic pain procedures,

vascular access, airway management, neuro-monitoring (transcranial Doppler, optic nerve sheath diameter, pupillary light reflex), gastro-intestinal ultrasound (nasogastric tube positioning, peristalsis, gastric residual volume, ileus, colonic pseudo-obstruction), focused transthoracic and transoesophageal echocardiography [38]; 3) In paediatrics? A child with fever and a fractal sign has pneumonia; and 4) In oncology? Looking at left heart contractility before injecting the first dose of cardiotoxic chemotherapy in an emergency setting is a simple but contributively application, etc.

We will let the readers complete this short paragraph, a very concise summary of a 300-page textbook [32].

ONE NEW LEARNING EXPERIENCE

Practical ultrasound training opportunities are still relatively scarce. For example, while The Netherlands has a national beginner's course and a consolidation track called Intensive Care Ultrasound (ICARUS) (www.frontierscritical-care.nl), many other countries are dependent on pioneering hospitals or conferences that organise introductory meetings. This hampers the true embedding of ultrasound in many ICUs. Therefore, an innovative approach may be needed. As described recently by Radmanesh et al., social media have entered the ultrasound community [46]. An example is Handsonecho, a new ultrasound-teaching platform that combines social media and multimedia to spread educational ultrasound related information. This includes free learning experiences and the production of short ultrasound video 'snacks' obtained by interviewing Prof. Lichtenstein (www.handsonecho.com/snacks). Other examples are echo courses preceding international meetings like the Course on Acute Care Ultrasound (CACU) held during the annual International Fluid Academy Days (<http://www.fluid-academy.org>), at ESICM, ISICEM, or the websites of 123sonography (<http://123sonography.com>), ceurf (<http://www.ceurf.net>), ICU sonography (<http://www.criticalecho.com>) etc. While these can never replace practical training, using information technology to guide critical care physicians in the appropriate use of ultrasound may prove an invaluable contribution to the field.

BEFORE CONCLUDING

This short text, of little use to those who are daily users of critical care ultrasound, was written for two other groups of physicians. Some are still reluctant to see this 'specialised' tool in 'non-specialised' hands. This wrong vision has come about through decades of misconceptions, making them see ultrasound as an expert field requiring high commitment and costly equipment. Others, too enthusiastic, go too fast, to the detriment of the scientific rigour that ultrasound needs.

The future of ultrasound lies between these two extremes, since both carry the potential for harm, a fate ultrasound does not deserve!

CONCLUSIONS

We feel privileged to have been invited to write a review on this elegant topic. Elegance is the reason we practice, or rather 'love' ultrasound. Beyond yielding data of clinical importance, there is something fascinating in 'discovering' one's patient. However, the bottom line is that our passion is truly based on scientific considerations.

The lung takes a central place in our ten reasons for performing critical care ultrasound [47]. We hope that, once colleagues are fully familiar with the different aspects of LUCI (the one probe philosophy, the definition of a holistic concept of critical ultrasound), they will agree that ultrasound is even more revolutionary than they believed, and as such they may even become more enthusiastic.

Once a tool for visual medicine falls into the right hands (i.e. the intensivist's hands), finding ten good reasons to use ultrasound is easy, but also challenging, as there are so many others. Our choice was based on what we believe truly makes a difference in daily clinical practice at the bedside of our sickest patients.

References:

1. Volpicelli G, Elbarbary M, Blaivas M et al.: International evidence-based recommendations for point-of-care lung ultrasound. *Intensive Care Med* 2012; 38: 577–591.
2. Gillman LM, Kirkpatrick AW: Portable bedside ultrasound: the visual stethoscope of the 21st century. *Scand J Trauma Resusc Emerg Med* 2012; 20: 18.
3. Dussik KT: On the possibility of using ultrasound waves as a diagnostic aid. *Neurol Psychiatr*. 1942; 174: 153–168.
4. Dénier A: Les ultrasons, leur application au diagnostic. *Presse Méd* 1946; 22: 307–308.
5. Lichtenstein DA, Meziere GA, Lagoueyte JF, Biderman P, Goldstein I, Gepner A: A-lines and B-lines: lung ultrasound as a bedside tool for predicting pulmonary artery occlusion pressure in the critically ill. *Chest* 2009; 136: 1014–1020.
6. Lichtenstein D, Goldstein I, Mourgeon E, Cluzel P, Grenier P, Rouby JJ: Comparative diagnostic performances of auscultation, chest radiography, and lung ultrasonography in acute respiratory distress syndrome. *Anesthesiology* 2004; 100: 9–15.
7. Lichtenstein DA, Meziere GA: Relevance of lung ultrasound in the diagnosis of acute respiratory failure: the BLUE protocol. *Chest* 2008; 134: 117–125.
8. Lichtenstein DA, Mauriat P: Lung ultrasound in the critically ill neonate. *Curr Pediatr Rev* 2012; 8: 217–223.
9. Lichtenstein D, Karakitsos D: Integrating lung ultrasound in the hemodynamic evaluation of acute circulatory failure (the fluid administration limited by lung sonography protocol). *J Crit Care* 2012; 27: 533 e11–19.
10. Bellani G, Mauri T, Pesenti A: Imaging in acute lung injury and acute respiratory distress syndrome. *Curr Opin Crit Care* 2012; 18: 29–34.
11. Lichtenstein DA: Lung ultrasound in the critically ill. *Ann Intensive Care* 2014; 4: 1.
12. Bouhemad B, Zhang M, Lu Q, Rouby JJ: Clinical review: bedside lung ultrasound in critical care practice. *Crit Care* 2007; 11: 205.
13. Volpicelli G, Cardinale L, Garofalo G, Veltri A: Usefulness of lung ultrasound in the bedside distinction between pulmonary oedema and exacerbation of COPD. *Emerg Radiol* 2008; 15: 145–151.
14. Lichtenstein D, Meziere G, Biderman P, Gepner A, Barre O: The comet-tail artifact. An ultrasound sign of alveolar-interstitial syndrome. *Am J Respir Crit Care Med* 1997; 156: 1640–1646.
15. Lichtenstein D, Meziere G: The BLUE points: three standardized points used in the BLUE protocol for ultrasound assessment of the lung in acute respiratory failure. *Crit Ultrasound J* 2011; 2011: 109–110.
16. Lichtenstein D: Classification of artefacts. In: *Lichtenstein D (ed): Whole body ultrasonography in the critically ill*. Heidelberg, New York, Berlin: Springer-Verlag; 2010: 185–188.
17. Lichtenstein D: Pleural effusion volume. In: *Lichtenstein D [ed]: Whole body ultrasonography in the critically ill*. Springer-Verlag, Heidelberg, New York, Berlin 2010: 132–133.
18. Volpicelli G, Caramello V, Cardinale L, Mussa A, Bar F, Frascisco MF: Bedside ultrasound of the lung for the monitoring of acute decompensated heart failure. *Am J Emerg Med* 2008; 26: 585–591.
19. Trezzi M, Torzillo D, Ceriani E et al.: Lung ultrasonography for the assessment of rapid extravascular water variation: evidence from hemodialysis patients. *Intern Emerg Med* 2013; 8: 409–415.
20. Soldati G, Copetti R, Sher S: Sonographic interstitial syndrome: the sound of lung water. *J Ultrasound Med* 2009; 28: 163–174.
21. Picano E, Frassi F, Agricola E, Gligorova S, Gargani L, Mottola G: Ultrasound lung comets: a clinically useful sign of extravascular lung water. *J Am Soc Echocardiogr* 2006; 19: 356–363.
22. Jambrik Z, Monti S, Coppola V et al.: Usefulness of ultrasound lung comets as a nonradiologic sign of extravascular lung water. *Am J Cardiol* 2004; 93: 1265–1270.
23. Gargani L: Lung ultrasound: a new tool for the cardiologist. *Cardiovasc Ultrasound* 2011; 9: 6.
24. Agricola E, Bove T, Oppizzi M et al.: 'Ultrasound comet-tail images': a marker of pulmonary oedema: a comparative study with wedge pressure and extravascular lung water. *Chest* 2005; 127: 1690–1695.
25. Lichtenstein DA, Menu Y: A bedside ultrasound sign ruling out pneumothorax in the critically ill. *Lung sliding*. *Chest* 1995; 108: 1345–1348.
26. Dulchavsky SA, Hamilton DR, Diebel LN, Sargsyan AE, Billica RD, Williams DR: Thoracic ultrasound diagnosis of pneumothorax. *J Trauma* 1999; 47: 970–971.
27. Kirkpatrick AW, Sirois M, Laupland KB et al.: Hand-held thoracic sonography for detecting post-traumatic pneumothoraces: the Extended Focused Assessment with Sonography for Trauma (EFAST). *J Trauma* 2004; 57: 288–295.
28. Lichtenstein D, Meziere G, Biderman P, Gepner A: The 'lung point': an ultrasound sign specific to pneumothorax. *Intensive Care Med* 2000; 26: 1434–1440.
29. Chavez MA, Shams N, Ellington LE et al.: Lung ultrasound for the diagnosis of pneumonia in adults: a systematic review and meta-analysis. *Respir Res* 2014; 15: 50.
30. Koeze J, Nijsten MW, Lansink AO, Droogh JM, Ismael F: Bedside lung ultrasound in the critically ill patient with pulmonary pathology: different diagnoses with comparable chest X-ray opacification. *Crit Ultrasound J* 2012; 4: 1.
31. Lichtenstein D: Lung ultrasound in the critically ill. *Curr Opin Crit Care* 2014; 20: 315–322.
32. Lichtenstein D: Whole body ultrasonography in the critically ill. Heidelberg, New York, Springer-Verlag, Berlin 2010.
33. Volpicelli G, Boero E, Stefanone V, Storti E: Unusual new signs of pneumothorax at lung ultrasound. *Crit Ultrasound J* 2013; 5: 10.
34. Lichtenstein D: Fluid administration limited by lung sonography: the place of lung ultrasound in assessment of acute circulatory failure (the FALLS protocol). *Expert Rev Respir Med* 2012; 6: 155–162.
35. Weil MH, Shubin H: Proposed reclassification of shock states with special reference to distributive defects. *Adv Exp Med Biol* 1971; 23: 13–23.
36. Lichtenstein DA: How can the use of lung ultrasound in cardiac arrest make ultrasound a holistic discipline. The example of the SESAME – protocol. *Med Ultrason* 2014; 16: 252–255.
37. Gabriel M, Pawlaczyk K, Waliszewski K, Krasinski Z, Majewski W: Location of femoral artery puncture site and the risk of postcatheterization pseudoaneurysm formation. *Int J Cardiol* 2007; 120: 167–171.
38. Terkawi AS, Karakitsos D, Elbarbary M, Blaivas M, Durieux ME: Ultrasound for the anesthesiologists: present and future. *ScientificWorldJournal* 2013; 2013: 683685.
39. Kumar A, Chuan A: Ultrasound guided vascular access: efficacy and safety. *Best Pract Res Clin Anaesthesiol* 2009; 23: 299–311.
40. Lichtenstein DA: Point-of-care ultrasound: infection control in the intensive care unit. *Crit Care Med* 2007; 35 (5 Suppl): S262–267.
41. Lichtenstein D, Biderman P, Meziere G, Gepner A: The 'sinusogram', a real-time ultrasound sign of maxillary sinusitis. *Intensive Care Med* 1998; 24: 1057–1061.

42. *Lichtenstein D, Meziere G, Seitz J*: The dynamic air bronchogram. A lung ultrasound sign of alveolar consolidation ruling out atelectasis. *Chest* 2009; 135: 1421–1425.
43. *Oveland NP, Lossius HM, Wemmelund K, Stokkeland PJ, Knudsen L, Sloth E*: Using thoracic ultrasonography to accurately assess pneumothorax progression during positive pressure ventilation: a comparison with CT scanning. *Chest* 2013; 143: 415–422.
44. *Soldati G, Testa A, Sher S, Pignataro G, La Sala M, Silveri NG*: Occult traumatic pneumothorax: diagnostic accuracy of lung ultrasonography in the emergency department. *Chest* 2008; 133: 204–211.
45. *Via G, Hussain A, Wells M et al.*: International evidence-based recommendations for focused cardiac ultrasound. *J Am Soc Echocardiogr* 2014; 27: 683 e1–e33.
46. *Radmanesh A, Duszak R, Fitzgerald RT*: Social media and public outreach: a physician primer. *Am J Neuroradiol* 2014.
47. *van der Werf TS, Zijlstra JG*: Ultrasound of the lung: just imagine. *Intensive Care Med* 2004; 30: 183–184.

Adres do korespondencji:

*Daniel A Lichtenstein, MD
Medical ICU, Hospital Ambroise-Pare,
Boulogne (Paris-West University), France
e-mail: D.Licht@Free.Fr*

Otrzymano: 6.10.2014 r.

Zaakceptowano: 28.10.2014 r.