

## Research paper

# Fetal pericardial effusion after maternal COVID-19 vaccination: a fortuitous association?



Sandra da Silva Mattos<sup>1,2</sup> , Maria T. Bernardino Chaves<sup>2</sup> , Carolina Paim Freitas<sup>2</sup> ,  
Rossana Severi<sup>2</sup> , Petra Brissant<sup>2</sup> , Daniela Davino<sup>2</sup> , Vinicius Souto-Maior<sup>3</sup> 

<sup>1</sup>Maternal-Fetal Cardiac Unit, Real Hospital Português de Beneficência em Pernambuco, Brazil

<sup>2</sup>Laboratório de Imunopatologia Keiso Asami, Universidade Federal de Pernambuco, Brazil

<sup>3</sup>Department of Statistics, Universidade Federal de Pernambuco, Brazil

## Abstract

**Introduction:** Studies monitoring COVID-19 and its vaccines are warranted to expand knowledge about the virus and its effects in humans. The objective of this study was to compare the reasons for referral and the fetal echocardiographic results during (PAND: Mar/20-Aug/21) and before (PREP: Set/19-Feb/20) the COVID-19 pandemic.

**Material and methods:** Single outpatient centre, retrospective study.

**Results:** A total of 10,778 fetal echocardiograms were performed; 10,732 corresponding to initial examinations performed in 10,551 pregnancies (10,376 singletons; 171 twins; 2 triplets; 2 quadruplets). Only first-time exams were reviewed. There were 5652 during PREP and 5080 during PAND. Maternal ages ( $X$ ) varied between 14 and 46 years ( $\bar{X}_{PREP} = 29.1$  and  $\bar{X}_{PAND} = 29.2$ ), and gestational weeks ( $Y$ ) varied between 16 and 39 weeks ( $\bar{Y}_{PREP} = 26.9$  and  $\bar{Y}_{PAND} = 27.6$ ). The exams were not performed in women with known active COVID-19 infection. In PREP, more women were referred due to maternal or fetal risk factors. During PAND, more women were referred due to a suspected heart defect on ultrasound. During PAND we identified more fetuses with congenital heart disease and arrhythmias. A higher incidence of pericardial effusion, without structural heart disease, was observed during the months of June, July, and August 2021, compared to the remaining months ( $p < 0.001$ ).

**Conclusions:** The identification of more structural heart disease during PAND may reflect changes in referral patterns. The increase in isolated pericardial effusion coincided with the period of massive COVID-19 immunization. We hypothesize that this finding may reflect a transient inflammatory response that could signal to fetal immunization against SARS-CoV-2.

**Key words:** fetal echocardiography, pericardial effusion, COVID-19.

### Corresponding author:

Prof. Sandra da Silva Mattos  
Maternal-Fetal Cardiac Unit  
Real Hospital Português de Beneficência em Pernambuco  
Avenida Agamenon Magalhães  
520010-075, Recife, Brazil  
e-mail: [ssmattos@cardiol.br](mailto:ssmattos@cardiol.br)  
tel.: (5581)981314848

## Introduction

The COVID-19 pandemic created a global health crisis of unprecedented proportions, with medical, economic, psychosocial, and behavioural challenges to populations throughout the world. Its medium- to long-term effects cannot be foreseen [1].

COVID-19 can damage the heart. Cardiovascular complications such as myocarditis, pericardial effusion, and pericarditis have been reported in adults [2, 3], children [4-6], and fetuses [7]. No reports have, thus far, suggested an increase in congenital heart malformations.

COVID-19 cardiovascular complications can be part of a complex multisystemic inflammatory syndrome or they can be isolated [8]. The latter has been described in the form of myocarditis or takotsubo cardiomyopathy [9].

Although measures such as mask-wearing and social distancing are important, immunization is the most effective tool to contain the pandemic. However, some serious adverse events have been reported after mRNA vaccine application in different age groups, and this has raised concerns about their safety and efficacy, particularly in more vulnerable groups such as the mother-fetus dyad [10-12].

Thus, short- and long-term follow-up studies after both the disease and its immunization programs remain an important aspect of the pandemic surveillance, which is necessary to determine its true impact and expand knowledge about this novel and challenging virus and its effects in humans.

This study aimed to compare results from fetal echocardiograms performed during and before the COVID-19 pandemics

to see if there were differences in referral patterns or echocardiographic findings.

## Material and methods

This is a single-centre, retrospective study from the Outpatient Department of Fetal Cardiology of a tertiary hospital in northeast Brazil.

We reviewed echocardiogram reports of all pregnant women referred to our unit between September 2019 and August 2021 and divided them into 2 periods: pre-pandemic (PREP: Sep/19 to Feb/20) and pandemic (PAND: Mar/20 to Aug/21). No hospitalized patients were included in the study, and all women declared that they were free of clinical symptoms suggestive of acute COVID-19 infection during the time of examination.

Five echocardiographers performed the examinations. Data collected included the reason for referral, maternal age and parity, gestational week, and final diagnosis. Only first-time examinations were reviewed.

Statistical analysis included descriptive techniques and hypothesis testing to assess statistical differences between the PREP and PAND periods. Hypothesis tests were performed by considering a level of significance of 5% ( $p < 0.05$ ).

## Results

A total of 10,778 fetal echocardiograms were performed; 10,732 corresponding to initial examinations performed in 10,551 pregnancies (10,376 singletons; 171 twins; 2 triplets; 2 quadruplets). First-time exams numbered 5,652 during PREP and 5,080 during PAND. There were no significant differences between women's age or gestational age at the time of examination between the 2 groups. The women's ages ( $X$ ) varied between 14 and 46 years ( $\bar{X}_{PREP} = 29.1$  and  $\bar{X}_{PAND} = 29.2$ ), and gestational ages ( $Y$ ) varied between 16 and 39 weeks ( $\bar{Y}_{PREP} = 26.9$  and  $\bar{Y}_{PAND} = 27.6$ ).

In PREP, many women were referred for a fetal echocardiogram as part of their routine prenatal care or due to mild maternal or fetal risk factors, such as diabetes and hypertension or the presence of a golf ball or tricuspid regurgitation. During PAND, some women who were offered the exam on a routine basis declined to take it to avoid the risk of exposure to COVID-19 by entering a hospital facility. Thus, during PAND there were more fetal echocardiograms performed in women with suspected congenital heart disease on ultrasound, as shown in Table 1.

As for the echocardiographic findings, during PAND more fetuses presented with structural heart disease and arrhythmias (Table 2). Most of the arrhythmias described in the period were irregular heart rates due to supraventricular extrasystoles and without fetal cardiovascular compromise. There were 7 cases of sustained tachyarrhythmia, 2 in PREP and 5 in PAND, and 2 cases of total atrioventricular block in PAND.

Strikingly, a much higher incidence of pericardial effusion without structural heart disease was observed during the months of June, July, and August 2021, compared with the remaining months of the PAND and PREP periods ( $p < 0.001$ ), as shown in Table 3 and in Figures 1 and 2. These effusions were

**Table 1.** Referral reasons for fetal echocardiogram

Referral reason	PREP	PAND	<i>p</i> -value*
Total, <i>n</i> (%)	5562 (100)	4989 (100)	–
Fetal risk factor, <i>n</i> (%)	313 (5.63)	216 (4.33)	0.0026
Maternal risk factor, <i>n</i> (%)	497 (8.94)	375 (7.52)	0.0091
Routine, <i>n</i> (%)	4580 (82.34)	4118 (82.54)	0.8103
Suspected CHD, <i>n</i> (%)	172 (3.09)	280 (5.61)	< 0.0001

PREP – pre-pandemics: September 2018 to February 2020, PAND – pandemic period: March 2020 to August 2021, CHD – congenital heart disease.

\*Z test to compare 2 proportions.

**Table 2.** Diagnoses from fetal echocardiograms in the 2 periods

Diagnostic groups	PREP	PAND	<i>p</i> -value*
Normal, <i>n</i> (proportion)	5144 (0.9101)	4790 (0.9429)	< 0.0001
Congenital heart disease, <i>n</i> (proportion)	67 (0.0119)	107 (0.0211)	0.0002
Arrhythmia, <i>n</i> (proportion)	16 (0.0028)	32 (0.0063)	0.0110
Mild anomalies, <i>n</i> (proportion)	424 (0.0750)	152 (0.0299)	< 0.0001

PREP – pre-pandemics: September 2018 to February 2020, PAND – pandemic period: March 2020 to August 2021.

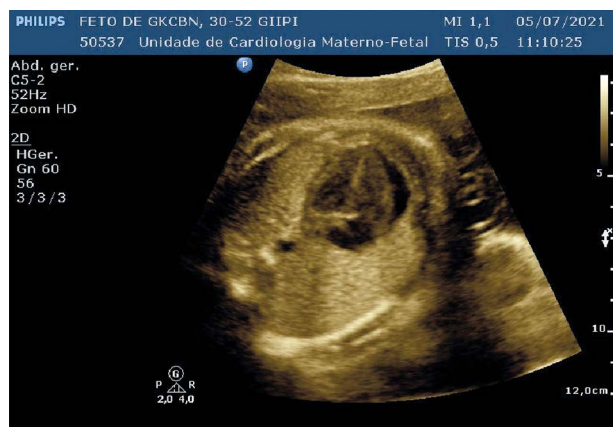\*Z test to compare 2 proportions.

**Table 3.** Presence of pericardial effusion in fetal echocardiograms during the 2 periods

Parameter	PREP	PAND	<i>p</i> -value*	Jun 21, Jul 21, and Aug 21	<i>p</i> -value*
<i>n</i>	69	149		100	
<i>N</i>	5652	5080	< 0.0001	1012	< 0.0001
Proportion	0.0122	0.0293		0.0988	

PREP – pre-pandemics: September 2018 to February 2020, PAND – pandemic period: March 2020 to August 2021.

\*Z test to compare 2 proportions.



**Figure 1.** Anterior fetal pericardial effusion demonstrated on 2D echo 4-chamber view of a 30-week-old fetus

observed in otherwise normal fetal hearts, mostly anterior, with maximal area between 3 and 5 mm, and led to no haemodynamic compromise.

## Discussion

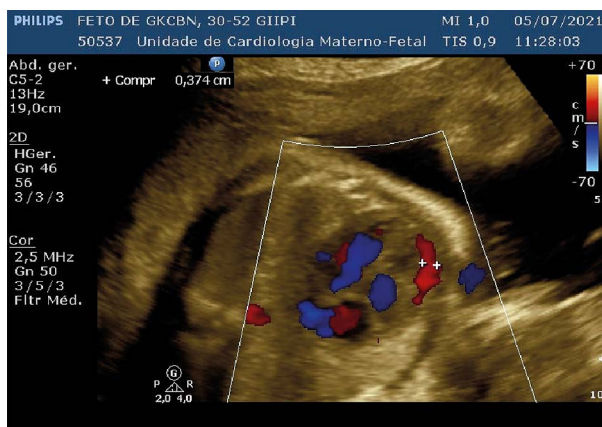
COVID-19 can affect the heart of adults and children, either in isolation or as part of a multisystemic inflammatory syndrome [8, 9].

Pregnant women are considered a group vulnerable to acquiring viral respiratory infections due to the physiological changes in their immune and cardiopulmonary systems. Nonetheless, as pointed out by Juan et al. [13], despite increasing numbers of published studies, there are still insufficient good-quality data to draw unbiased conclusions with regard to COVID-19 complications in pregnant women, as well as its vertical transmission and perinatal complications. This highlights the need for continuous research and complete data presentation on this challenging novel disease.

Overall, the impact of viral infections on fetuses, although documented in many situations, is still poorly understood. Racicot and Mor [14] highlight that virus-host interaction during pregnancy is complex and highly variable. Direct fetal infection, such as Cocksakie B, Cytomegalovirus, Rubella, or Zika, can have devastating effects on fetal development [15]. However, this placental barrier-crossing phenomenon is rare [16]. A consequence of the maternal inflammatory response, rather than the direct effect of the virus, is likely to be a more common mechanism behind the fetal effects of maternal viral infections [17].

Among fetal cardiovascular complications from viral infections, congenital heart malformations, pericarditis, myocarditis, and even dilated cardiomyopathy [18-20] have been reported. Thus far, only isolated cases of fetal cardiovascular complications have been reported during the COVID-19 pandemic [7, 21].

This study comes from an outpatient paediatric and fetal cardiology service. The echocardiograms were performed on women who reported being free of any clinical symptoms at the time of examination. However, no COVID-19 tests were requested prior to the exams, and thus we cannot



**Figure 2.** Colour flow Doppler in diastole showing flow across the atrioventricular valves and intra-pericardial flow moving in opposite direction

rule out potential asymptomatic cases during the pandemic period.

More cases of fetal congenital heart disease were identified during the pandemic period, but there was also a shift in referral pattern, from more referrals due to mild maternal or fetal risk factors prior to the pandemic to more referrals due to a suspected cardiac abnormality on screening ultrasound during the pandemic. This shift in referral pattern may justify our findings; however, further studies are warranted in this area.

More strikingly, a highly significant increase in fetal pericardial effusion was observed in the months of June, July, and August of 2021 when compared with all remaining PAND and PREP periods.

In the 1980s, Jeanty et al. described the presence of 1-2 mm of pericardial fluid in otherwise normal fetuses after the 20<sup>th</sup> gestational week, and pointed out that with each generation of equipment one must re-evaluate what is normal and abnormal in diagnostic imaging [22].

There is no doubt that, with current imaging equipment and a good window of insonation, this normal rim of pericardial fluid can be observed and measured at the point of maximum thickness. The fluid moves toward the cardiac apex during systole and toward the atrium during diastole, and its velocity increases linearly in both systole and diastole with gestational age [23] and is not considered a pathological finding.

A true pericardial effusion, however, can be observed on routine fetal ultrasound throughout gestation. It seems to occur in approximately 2% of all pregnancies [24], but its exact incidence and significance is not clearly understood, because it can be associated with a wide spectrum of aetiologies from severe genetic and chromosomal diseases to transient, “normal” forms [25]. Isolated pericardial effusion has been associated with COVID-19 in adults [3], children [6], and fetuses [7].

In our study, we observed mostly anterior pericardial effusions with a maximal thickness of 3 to 5 mm in otherwise normal fetal hearts, with no haemodynamic compromise.

Because this observation coincided with the massive immunization program of pregnant women, which started in May

2021 in our city, we hypothesized that this finding could reflect a fetal inflammatory response to the transferred antibodies from the maternal immunization process.

The May immunization program used only the Pfizer vaccine. Most women in health professions had already received an AstraZeneca or CoronaVac shot earlier in the year, but still had their second shot, from May onwards, with the Pfizer vaccine. Some women might not have received any shots at the time of the fetal echocardiogram.

Because this report is a result of a clinical observation, no data were collected to determine the precise time interval between maternal immunization or the type of vaccine used and the development of fetal pericardial effusion. A follow-up study is being conducted to clarify these points.

Some serious adverse events have been reported after mRNA vaccine application in different age groups, and this raised concerns about their safety and efficacy, particularly in more vulnerable groups such the mother-fetus dyad [11, 12].

A recent review, however, found no increased adverse pregnancy outcomes after vaccination, and concluded that the benefits of maternal antibodies transferred through the placenta outweigh any known or potential risks [26].

Prior to this current observation, and similar to other centres, a sporadic finding of fetal pericardial effusion was occasionally documented in otherwise normal fetuses. They were generally small, with no haemodynamic compromise, and tended to disappear spontaneously. Perhaps they reflected transient, mild, inflammatory responses to maternal-fetus antibody transfer from other types of non-mRNA vaccines.

As massive immunization programs are being conducted for pregnant women in different parts of the world, our report may prompt other researchers to observe their populations, conduct similar studies, and expand knowledge for mothers and babies during and after the COVID-19 pandemic.

## Conclusions

A small increase in the number of cardiac malformations was observed since the beginning of the COVID-19 pandemic; however, it may reflect only changes in referral patterns for fetal echocardiography during the period.

More importantly, from the striking increase in fetal pericardial effusions, we raised the hypothesis of an inflammatory response to the maternal COVID-19 vaccine, which could mean that the fetuses were being effectively immunized in-utero. This would be reassuring; however, further studies are needed to determine if such a causal relationship exists and its potential mid- to long-term implications, or if our findings were simply a fortuitous association.

## Acknowledgements

The authors would like to thank all the staff members of the Maternal-Fetal Cardiac Unit at the Royal Portuguese Hospital for their support during the preparation of the manuscript.

## Conflict of interest

The authors declare no conflict of interest.

## REFERENCES

1. Barouki R, Kogevinas M, Audouze K, Belesova K, Bergman A, Birnbaum L, et al. The COVID-19 pandemic and global environmental change: Emerging research needs. *Environ Int* 2021; 146: 106272..
2. Sauer F, Dagrenat C, Couppie P, Jochum G, Leddet P, D'Amario D, et al. Pericardial effusion in patients with COVID-19: case series. *Eur Hear J Case Rep* 2020; 4 (F11): 1-7.
3. Fox K, Prokup JA, Butson K, Jordan K. Acute effusive pericarditis: a late complication of COVID-19. *Cureus* 2020; 12: e9074.
4. Raymond TT, Das A, Manzuri S, Ehrett S, Guleserian K, Brenes J. Pediatric COVID-19 and pericarditis presenting with acute pericardial tamponade. *World J Pediatr Congenit Hear Surg* 2020; 11: 802-804.
5. Valverde I, Singh Y, Sanchez-De-Toledo J, Theocharis P, Chikermane A, Di Filippo S, et al. Acute cardiovascular manifestations in 286 children with multisystem inflammatory syndrome associated with COVID-19 infection in Europe. *Circulation* 2021; 143: 21-32.
6. Gokalp S, Çilsal E, Yukcu B, Yolcu C, Akkoc G, Guzelas A. A case of a very large haemorrhagic pericardial effusion in an adolescent patient with COVID-19 infection. *Cardiol Young* 2021; 31: 842-844.
7. Lima ARO, Cardoso CC, Bentim PRB, Voloch CM, Rossi ÁD, da Costa RMMSC, et al. Maternal SARS-CoV-2 infection associated to systemic inflammatory response and pericardial effusion in the newborn: a case report. *J Pediatric Infect Dis Soc* 2021; 10: 536-539.
8. Koskela U, Helve O, Sarvikivi E, Helminen M, Nieminen T, Peltola V, et al. Multi-inflammatory syndrome and Kawasaki disease in children during the COVID-19 pandemic: a nationwide register-based study and time series analysis. *Acta Paediatr I* 2021; 110: 3063-3068.
9. Haussner W, Derosa AP, Haussner D, Tran J, Torres-lavoro J, Kamler J, et al. COVID-19 associated myocarditis: a systematic review. *Am J Emerg Med* 2021; 51: 150-155.
10. Perez Y, Levy ER, Joshi AY, Virk A, Rodriguez-Porcel M, Johnson M, et al. Myocarditis following COVID-19 mRNA vaccine: a case series and incidence rate determination. *Clin Infect Dis* 2021; ciab926.
11. Shimabukuro TT, Kim SY, Myers TR, Moro PL, Oduybo T, Panagiotakopoulos L, et al. Preliminary findings of mRNA COVID-19 vaccine safety in pregnant persons. *N Engl J Med* 2021; 384: 2273-2282.
12. Wainstock T, Yoles I, Sergienko R, Sheiner E. Prenatal maternal COVID-19 vaccination and pregnancy outcomes. *Vaccine* 2021; 39: 6037-6040.
13. Juan J, Gil MM, Rong Z, Zhang Y, Yang H, Poon LC. Effect of coronavirus disease 2019 (COVID-19) on maternal, perinatal and neonatal outcome: systematic review. *Ultrasound Obstet Gynecol* 2020; 56: 15-27.
14. Racicot K, Mor G. Risks associated with viral infections during pregnancy. *J Clin Invest* 2017; 127: 1591-1599.
15. Megli CJ, Coyne CB. Infections at the maternal-fetal interface: an overview of pathogenesis and defence. *Nat Rev Microbiol* 2022; 20: 67-82.
16. Cordeiro CN, Tsimis M, Burd I. Infections and brain development. *Obstet Gynecol Surv* 2015; 70: 644-655.
17. Shi L, Tu N, Patterson PH. Maternal influenza infection is likely to alter fetal brain development indirectly: the virus is not detected in the fetus. *Int J Dev Neurosci* 2005; 23: 299-305.
18. Schwartz DA, Morotti D. Placental pathology of COVID-19 with and without fetal and neonatal infection: trophoblast necrosis and chronic histiocytic intervillitis as risk factors for transplacental transmission of SARS-CoV-2. *Viruses* 2020; 12: 1308.
19. Ramalho C, Monterroso J, Simões J, Brandão O, Montenegro N. Human herpes virus 6 causing myocarditis in a fetus: an infectious cause to a congenital heart defect. *J Clin Pathol* 2011; 64: 733-734.
20. Das BB. A neonate with Acute heart failure: chromosomally integrated human herpesvirus 6-associated dilated cardiomyopathy. *J Pediatr* 2015; 167: 188-92.e1.
21. Oliveira KF de, Oliveira JF de, Wernet M, Paschoini MC, Ruiz MT. Vertical transmission and COVID-19: a scoping review. *Rev Bras Enferm* 2021; 74 (Suppl 1): e20200849.

22. Jeanty P, Romero R, Hobbins JC. Fetal pericardial fluid: a normal finding of the second half of gestation. *Am J Obstet Gynecol* 1984; 149: 529-532.
23. Aoekkasit O, Uerpaiojkit B. Doppler velocimetry of fetal pericardial fluid. *Int J Gynecol Obstet* 2009; 106: 19-22.
24. Dizon-Townson DS, Dildy GA, Clark SL. A prospective evaluation of fetal pericardial fluid in 506 second-trimester low-risk pregnancies. *Obstet Gynecol* 1997; 90: 958-961.
25. Azancot A, Diehl R, Dorgeret S, Sebag G, Baumann C, Vuillard E, et al. Isolated pericardial effusion in the human fetus: a report of three cases. *Prenat Diagn* 2003; 23: 193-197.
26. Chen F, Zhu S, Dai Z, Hao L, Luan C, Guo Q, et al. Effects of COVID-19 and mRNA vaccines on human fertility. *Hum Reprod* 2021; 37: 5-13.

#### Division of work:

All authors contributed equally to the preparation of this article.

**Sandra da Silva Mattos** (ORCID: 0000-0003-0896-3568): research concept and design, collection and/or assembly of data, data analysis and interpretation, writing the article, critical revision of the article, final approval of the article.

**Maria Tereza Bernardino Chaves** (ORCID: 0000-0002-2905-0023): collection and/or assembly of data, data analysis and interpretation, writing the article, final approval of the article.

**Carolina Paim Freitas** (ORCID: 0000-0001-7223-3653): data analysis and interpretation, critical revision of the article, final approval of the article.

**Rossana Severi** (ORCID: 0000-0003-1777-8989): collection and/or assembly of data, critical revision of the article, final approval of the article.

**Petra Brissant** (ORCID: 0000-0003-2910-4770): data analysis and interpretation, critical revision of the article, final approval of the article.

**Daniela Davino** (ORCID: 0000-0002-8089-1098): collection and/or assembly of data, data analysis and interpretation, final approval of the article.

**Vinicius Souto-Maior** (ORCID: 0000-0003-2782-9364): research concept and design, data analysis and interpretation, writing the article, critical revision of the article, final approval of the article.