


## Case report

# Massive fetal cardiac rhabdomyoma treated with transplacental sirolimus



Zoetta McLoughlin<sup>1</sup> , Melanie Kathol<sup>2</sup> , Amanda McIntosh<sup>2</sup> 

<sup>1</sup>Pediatrics, Children's Mercy Hospital, Kansas City, United States

<sup>2</sup>Pediatric and Fetal Cardiology, Ward Family Heart Center, Children's Mercy Hospital, Kansas City, United States

## Abstract

Cardiac rhabdomyomas, the most common type of fetal cardiac tumor, can grow prenatally, in rare instances leading to heart failure and fetal demise. In severe cases, there have been reports of successful treatment with transplacental mechanistic target of rapamycin inhibitor (mTORi) therapy, specifically sirolimus. However, given the small number of published cases, the dosing regimen and safety profile of sirolimus in pregnancy for this indication remain undefined. This case details successful treatment with sirolimus therapy in a fetus with a massive septal cardiac rhabdomyoma leading to left ventricular cavity obliteration and left ventricular outflow tract (LVOT) obstruction with resulting fetal hydrops. A mother with a previous child with tuberous sclerosis complex presented for evaluation of rapidly enlarging fetal cardiac masses in the second trimester. Due to fetal hemodynamic compromise by 30 weeks gestational age (GA), the mother was initiated on oral sirolimus therapy. Two weeks after initiation of therapy, mass size and fetal hydrops had significantly improved. Oligohydramnios developed at 36 weeks GA, prompting delivery of a live-born infant appropriate for GA. Oligohydramnios has never been reported with maternal sirolimus use. With this case, we confirm previously described dosing regimens for treatment and describe the safety profile of sirolimus in pregnancy based on current national registry data. We also highlight the need for maternal and fetal monitoring after treatment initiation.

**Key words:** sirolimus, rhabdomyoma, mTORi, hydrops, oligohydramnios.

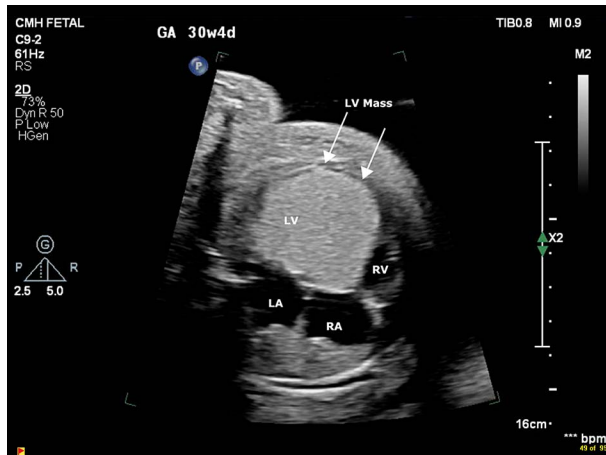### Corresponding author:

Amanda McIntosh MD  
Pediatric and Fetal Cardiology  
Ward Family Heart Center  
Children's Mercy Hospital  
2401 Gilham Rd, 64108  
Kansas City, United States  
e-mail: [ammcintosh@cmh.edu](mailto:ammcintosh@cmh.edu)

## Introduction

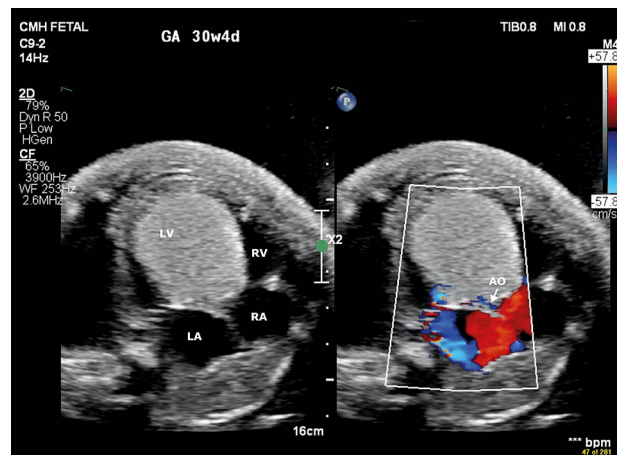
Fetal cardiac rhabdomyomas, typically secondary to tuberous sclerosis complex, are generally noted in the second trimester and often grow until 30-32 weeks gestational age (GA), with spontaneous regression possible in the third trimester and after birth [1, 2]. Transplacental therapy with maternal oral mechanistic target of rapamycin inhibitor (mTORi) use initiated in

the third trimester has been successful in several documented cases at reducing tumor size, with rare reports of fetal growth restriction and no serious adverse effects documented [1-5]. In this case, given findings of fetal hydrops with ventricular dysfunction and left ventricular outflow tract (LVOT) obstruction with concern for impending fetal demise, transplacental sirolimus was initiated with good tumor response.



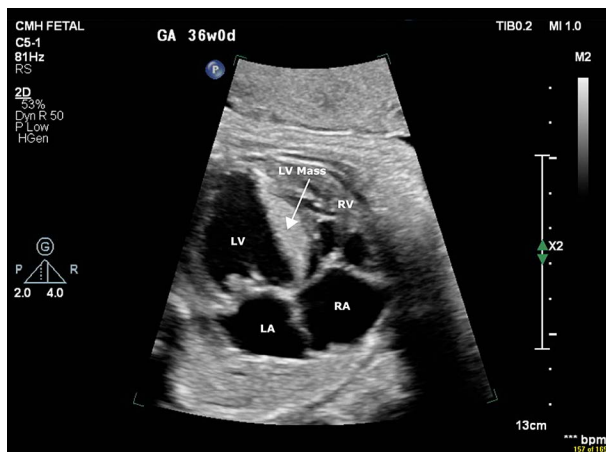
**Figure 1.** 2-Dimensional imaging at 30 weeks gestational age demonstrates massive rhabdomyoma originating from left ventricular septum, 76 × 57 mm (300 × 300 DPI)

LV – left ventricle, LA – left atrium, RV – right ventricle, RA – right atrium



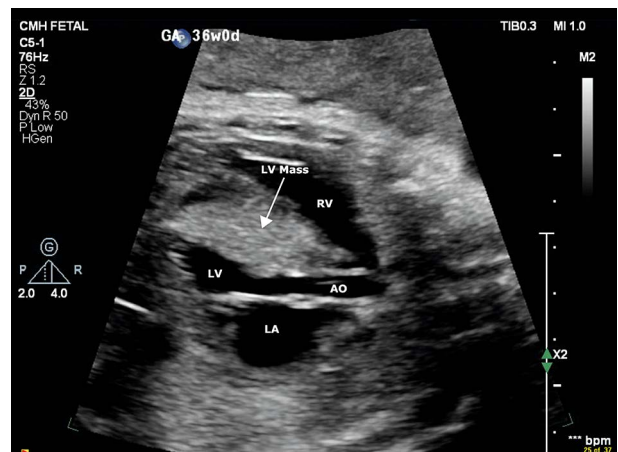**Figure 2.** 2-Dimensional and color Doppler imaging at 30 weeks gestational age demonstrates rhabdomyoma nearly obliterating left ventricular cavity and left ventricular outflow tract with moderate to severe mitral regurgitation, 76 × 57 mm (300 × 300 DPI)

LV – left ventricle, LA – left atrium, RV – right ventricle, RA – right atrium, AO – aorta



**Figure 3.** 2-Dimensional imaging at 36 weeks gestational age demonstrates significantly decreased size of rhabdomyoma and increased left ventricular cavity size, 76 × 57 mm (300 × 300 DPI)

LV – left ventricle, LA – left atrium, RV – right ventricle, RA – right atrium



**Figure 4.** 2-Dimensional imaging at 36 weeks gestational age demonstrates improved caliber of left ventricular outflow tract, 76 × 57 mm (300 × 300 DPI)

LV – left ventricle, LA – left atrium, RV – right ventricle, RA – right atrium, AO – aorta

## Case report

A gravida 3 para 2 mother at 26 weeks GA with history of chronic hypertension, anxiety, and gestational diabetes presented to the fetal cardiology clinic for evaluation of cardiac masses progressing in size. Initial fetal echocardiogram showed a large 2.1 × 2.1 × 2.6 cm echogenic mass adherent to the interventricular septum extending from the left ventricular apex to base. The mass protruded into the LVOT and abutted the anterior leaflet of the mitral valve, causing severe LVOT obstruction. Systolic function of the left ventricular free wall was mildly depressed with moderate mitral regurgitation, mild to moderate tricuspid regurgitation, normal right ventricular systolic function, and no right ventricular outflow tract obstruction. There were no arrhythmias or pericardial effusion. At 27 weeks GA, a fetal magnetic resonance imaging study was performed, which demonstrated trace pericardial and pleural effusion, ascites, skin edema, and scrotal edema concerning

for development of hydrops, confirmed on obstetric ultrasound. Consideration of maternal sirolimus therapy was discussed, however mother preferred to continue observation at that time. Weekly follow-up demonstrated progressive growth of the mass and hydrops. Amniotic fluid indices increased from 24.6 cm to 36.2 cm, consistent with polyhydramnios. Fetal biophysical profiles remained reassuring. By 30 weeks GA, the mass had increased in size to 4.4 × 4.4 cm with moderate to severe mitral and tricuspid regurgitation and severe hydrops (Figures 1 and 2).

Severe narrowing of the LVOT was still present, with preserved antegrade flow across the aortic valve and aortic arch. There was moderate to severe left ventricular and mild right ventricular systolic dysfunction. Sirolimus was initiated at a dose of 2 mg/m<sup>2</sup>/day divided twice daily. Trough levels were measured at 5 days, targeting 10–12 ng/ml. Complete metabolic panel, complete blood count, and lipid panel were obtained at initiation and weekly thereafter. Inpatient monitoring, twice

weekly evaluation for fetal growth and well-being, and weekly fetal echocardiograms were performed. The fetal growth rate remained normal. A decrease in the size of the mass was noted 2 weeks after sirolimus initiation with subsequent decrease in the amount of hydrops. By 36 weeks GA, the mass size had significantly decreased with an increase in left ventricular cavity size (Figures 3 and 4).

Oligohydramnios was also noted at 36 weeks GA (amniotic fluid index decreased to 2.5 cm); thus, the fetus was delivered via repeat Cesarean section. The infant required intubation and prostaglandin initiation after delivery due to inadequate cardiac output that was due to left ventricular systolic dysfunction. Prostaglandin was discontinued by 24 hours of life, and the infant was maintained on low-dose epinephrine and milrinone along with oral everolimus with gradual transition to oral heart failure medications. The infant was discharged at 6 weeks of life. At 3 months of life, the mass measured  $0.9 \times 1.5$  cm with no LVOT obstruction. There was mild dynamic right ventricular outflow tract obstruction, normal left ventricular size with mild left ventricular dysfunction (left ventricular ejection fraction of 51%), trivial mitral regurgitation, normal tricuspid valve function, and normal right heart size and function. Post-natal genetic testing confirmed diagnosis of tuberous sclerosis complex.

## Conclusions

As demonstrated in this case, mTORi therapy is thought to reduce tumor size by slowing cell growth and proliferation. However, maternal use of mTORi therapy is also thought to increase risk of fetal growth restriction due to effects on transfer of substrates including fatty acids, glucose, and amino acids, and possible resulting placental insufficiency [6]. As mentioned in one large case series investigating prognostic factors relating to fetal cardiac tumors, use of mTORi therapy is still isolated and has an unknown safety profile [7]. Transplant Pregnancy Registry International data through 2020 does provide reassuring support that sirolimus exposure during all stages of pregnancy does not appear to correlate with congenital fetal anomalies [8]. Reported maternal sirolimus dosing regimens have ranged from 1 mg/day to 6 mg/day. A consensus dosing regimen for transplacental treatment of fetal cardiac rhabdomyoma has not yet been defined [1]. Our patient was treated with 2 mg/m<sup>2</sup>/day divided twice daily with excellent tumor response and fetal clinical improvement. Development of fetal oligohydramnios has never been reported in these cases and is an important clinical concern to be aware of in monitoring during transplacental sirolimus use. While data are still limited regarding maternal and fetal safety and efficaciousness, we report a single case of fetal cardiac rhabdomyoma with hemodynamic compromise that was safely and effectively treated via transplacental mTORi therapy.

## Conflict of interest

The authors declare no conflict of interest.

## REFERENCES

1. Ebrahimi-Fakhari D, Stires G, Hahn E, Krueger D, Franz DN. Prenatal sirolimus treatment for rhabdomyomas in tuberous sclerosis. *Pediatr Neurol* 2021; 125: 26-31.
2. Park H, Chang CS, Choi SJ, Oh SY, Roh CR. Sirolimus therapy for fetal cardiac rhabdomyoma in a pregnant woman with tuberous sclerosis. *Obstet Gynecol Sci* 2019; 62: 280-284.
3. Vachon-Marceau C, Guerra V, Jaeggi E, Chau V, Ryan G, Van Mieghem T. In-utero treatment of large symptomatic rhabdomyoma with sirolimus. *Ultrasound Obstet Gynecol* 2019; 53: 420-421.
4. Pluym ID, Sklansky M, Wu JY, Afshar Y, Holliman K, Devore GR, et al. Fetal cardiac rhabdomyomas treated with maternal sirolimus. *Prenat Diagn* 2020; 40: 358-364.
5. Barnes BT, Procaccini D, Crino J, Blakemore K, Sekar P, Sagaser KG, et al. Maternal sirolimus therapy for fetal cardiac rhabdomyomas. *N Engl J Med* 2018; 378: 1844-1845.
6. Tshering S, Dorji N, Youden S, Wangchuk D. Maternal sirolimus therapy and fetal growth restriction. *Arch Clin Cases* 2021; 8: 19-24.
7. Strzelecka I, Sylwestrzak O, Krekora M, Przysło Ł, Gach A, Respondek-Liberska M. Fetal cardiac tumours in a referral prenatal cardiology centre – series of 37 cases with neonatal follow-up. *Prenat Cardio* 2019; 1: 20-27.
8. Transplant Pregnancy Registry International (TPRI). 2020 annual report. Philadelphia (PA): Gift of Life Institute; 2021 Oct. 24 p.14-15. Available from: <https://www.transplantpregnancyregistry.org>.

### Division of work:

**Zoetta McLoughlin** (ORCID: 0009-0009-1644-6940): collection and/or assembly of data, data analysis and interpretation, writing the article, critical revision of the article, final approval of the article.

**Melanie Kathol** (ORCID: 0009-0007-4139-9969): collection and/or assembly of data, data analysis and interpretation.

**Amanda McIntosh** (ORCID: 0000-0002-6423-1874): research concept and design, collection and/or assembly of data, data analysis and interpretation, writing the article, critical revision of the article, final approval of the article.