

Ring annuloplasty and successful mitral valve repair in a staphylococcal endocarditis case with bilobular saccular mycotic aneurysm at cerebral artery and frontal region infarction. Secondary to septic emboli

Cengiz Özbek, Ufuk Yetkin, Mehmet Bademci, Nagihan Karahan, Ali Gürbüz

Izmir Atatürk Training and Research Hospital, Department of Cardiovascular Surgery, Izmir, Turkey

Submitted: 5 June 2007

Accepted: 16 September 2007

Arch Med Sci 2008; 4, 1: 94–99
Copyright © 2008 Termedia & Banach

Corresponding author:

Doç. Dr. Ufuk Yetkin
1379 Sok. No: 9
Burç Apt. D: 13
35220, Alsancak
İzmir, Turkey
Phone: +90 505 3124906
Fax: +90 232 2434848
E-mail: ufuk_yetkin@yahoo.fr

Abstract

Staphylococcus is the aetiological agent in 1/3 of infective endocarditis(IE) cases. It has a high virulence and prognosis is poor due to severe intracardiac injury and frequent embolic complications. Leaflets are the most frequently affected part in mitral valve endocarditis. Following the endocarditis, many structural anomalies such as vegetations, destruction, regurgitation and calcific deposits on leaflets can develop. Embolism due to vegetations or infected tissues is the most frequent complication and is closely related to prognosis. Post mortem studies have shown that the brain embolization rate is up to 40%. Our case was a methicillin-sensitive coagulase negative staphylococcal (MSCONS) IE and had two very rare cerebral complications. We present our diagnostic approach and successful mitral valve repair technique. Surgery for infective endocarditis is potentially life saving. Successful management requires a multidisciplinary approach involving microbiologists, cardiologists, and cardiothoracic surgeons. Frequency of staphylococcal endocarditis has increased progressively in the last twenty years. Medical treatment alone is not sufficient for radical therapy and surgery is necessary. Antibiotic and surgery combination is the best and most effective treatment method. Survival is positively affected and quality of life is increased in long term.

Key words: infective endocarditis, *Staphylococcus aureus*, brain embolization, septic embolic cerebral infarction, mycotic arterial aneurysm.

Introduction

The investigation and management of infective endocarditis in the developed world have changed radically over the past 30 years [1, 2]. Non-invasive imaging, molecular science, diagnostic protocols, and curative surgery have all become commonplace, yet the incidence remains unchanged and annual mortality approaches 40% [3]. Cardiac complications of IE develop at valves or the perivalvular region. In association with tissue loss, staphylococcus frequently causes tear, erosion, perforation and calcific depositions at leaflets. Non-cardiac complications include emboli due to vegetations. Left-sided endocarditis can be complicated with brain, kidney, spleen and intestine infarction and/or systemic embolism associated with mycotic arterial aneurysm or abscess [4]. In active IE cerebral signs are more prominent than visceral signs and embolism is the most frequent

(22 to 43%) complication, closely related to prognosis [4, 5]. Surgery is needed in approximately 50% of patients who develop infective endocarditis, and careful timing is essential to ensure a good outcome [1]. In this article, we present our diagnostic approach and mitral valve repair technique in a MSCONS IE case with two rare cerebral complications.

Case report

Our patient was a 53-year old man. Six months before referring to our clinic for operation, he was admitted to another hospital for loss of appetite, weight loss and weakness. Diagnosis was pyelonephritis and parenteral antibiotherapy and outpatient clinic control was recommended for mitral valve prolapsus and 3° regurgitation. In the next three months he lost 20 kg and malign factors were investigated in another institute. His pathology results were: ESR 103 mm/hour, haematocrit 30.2%, CRP 24 mg/l and erythrocytes were hypochromic and microcytic. The transthoracic echocardiography (TTE) showed that his mild mitral regurgitation progressed and a 15 × 20 mm mobile vegetation developed at the posterior mitral leaflet. Also, mitral maximum gradient secondary to mitral regurgitation increased to 18.2 mm Hg (Figure 1). Diameter of left atrium (42 mm) and left ventricle (50/35 mm) were widened. Left ventricle EF was 60%. Pulmonary arterial pressure was 45/19 mm Hg and echocardiographic score was found to be 9. There was 1-2° tricuspid regurgitation. Other valves' functions were normal. He was in New York Heart Association (NYHA) functional class III-IV at presentation. He was hospitalized urgently in our Cardiology Clinic due to those subacute infective endocarditis symptoms. After emergent Infectious Disease consultation 24 millionU/day crystalline penicillin and 160 mg/day parenteral gentamicin were started. Two days later haemoculture was positive for MSCONS and drugs were replaced with ceftriaxone 3 g/day + gentamicin 160 mg/day. Brucella and salmonella serological tests were negative. His fever persisted at 38.3°C and treatment was changed to 4 × 500 mg/day imipenem + rifampicin 1 × 600 mg/day. When the 6th week of the last parenteral antibiotherapy ended, vegetation diameter did not improve in weekly echocardiographic controls, and ESR was 65 mm/hour, CRP was 9.6 mg/l and WBC was 8600. He went under operation.

His coronary arteriography was normal. Further investigations with cerebral MR angiography showed bilobulated saccular aneurysm at left middle cerebral arterial bifurcation level, which was consistent with mycotic aneurysm secondary to septic embolization (Figure 2). In addition, multiple infarction images characterized by gyral thickness

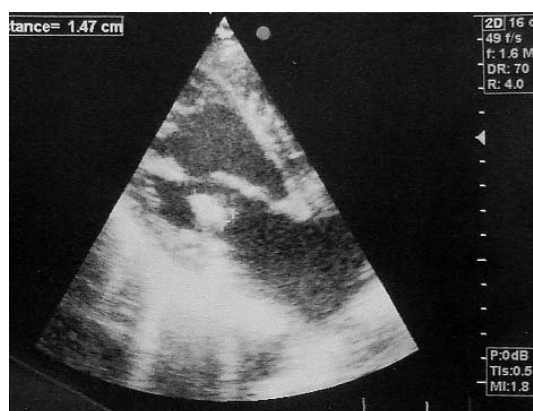


Figure 1. TTE image of mobile vegetation on posterior leaflet, at first hospital admission

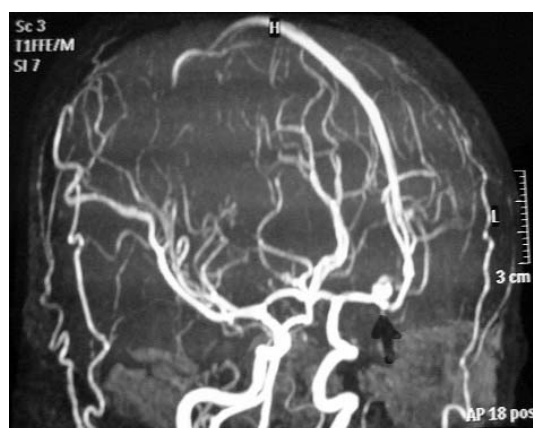


Figure 2. Cerebral MR angiography image of bilobular saccular aneurysm. At left middle cerebral artery bifurcation

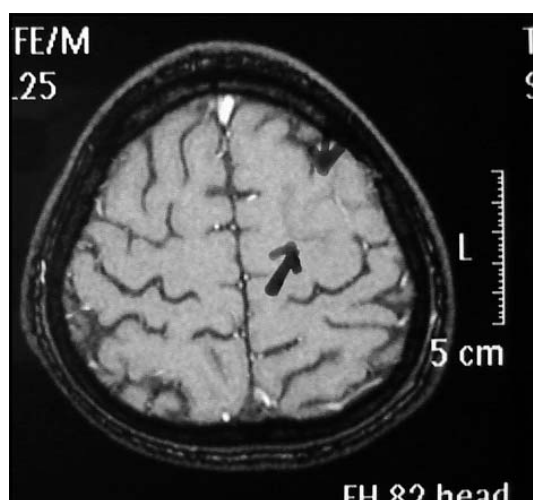


Figure 3. At vertex level of left posterior frontal region, cerebral MRI of multiple infarctions

and oedema in the left posterior frontal region and vertex level could be consistent with the same aetiology (Figure 3). Neurosurgical consultation did not recommend emergent surgery. Outpatient clinic control was recommended after the



Figure 4. Vegetative formations on torn basal chordae at P1 region of posterior mitral leaflet

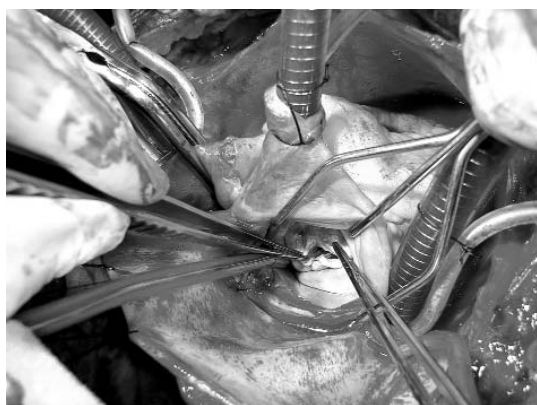


Figure 5. Calcific formation at anterior leaflet

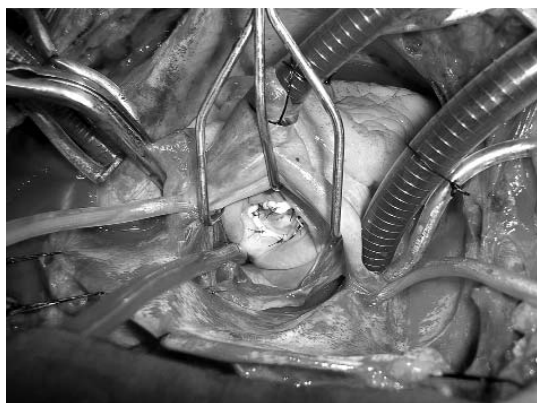

Figure 6. Valve competence and closure were excellent with saline solution test

isothermic blood cardioplegia from the aortic root, cardiac arrest was established. Hypothermia was moderate (28°C). A vent was placed via the right superior pulmonary vein. Standard left atriotomy was made from the interatrial junction. The mitral valve was approached via a standard left atriotomy parallel to the interatrial sulcus. Cooley's retractor was positioned for optimal exposure. The entire valvular apparatus was carefully examined in order to assess the feasibility of reconstructive surgery and to plan the operative technique. The valvular apparatus was then mobilized as an entire unit with a nerve hook in order to assess tissue flexibility and to identify leaflet restriction. There were vegetative formations on a torn basal chorda in the posterior leaflet P1 region near the anterolateral commissure (Figure 4). In the A2 region of the anterior leaflet there was calcific formation, extending to the left atrium and limited to the endocardial layer of the leaflet (Figure 5). Calcific vegetative formation of the anterior leaflet was stripped without harming the leaflet. Vegetation in the posterior part was extirpated with broken basal chordae extensions. Chordae counts of both anterior and posterior leaflets were sufficient. Because of resected posterior leaflet's chordae, unilateral segmental annuloplasty was performed to the posteromedial commissure. This procedure may also be used to achieve better approximation of leaflet tissue with the placement of mattress stitches at the commissures. We tested the valve competence after this step on observing valve closure while the left ventricular cavity was filled with saline solution. There was no saline regurgitation. From a surgical point of view, a flexible ring reduces the tension of the sutures, decreasing the likelihood of ring dehiscence. The ring can also be split. This is particularly useful in those cases in which the surgeon doubts the quality of the repair. For these reasons we performed mitral ring annuloplasty with H608H31 Duran flexible ring model H608H, 31 mm. We re-tested the valve competence after this step on observing valve closure with saline solution. Valve competence and closure were excellent (Figure 6). Left atriotomy was closed in standard fashion. Postoperative rhythm was sinus. He did not require inotropic support during weaning from cardiopulmonary bypass and early postoperative period. The volume of blood transfused was 2 units. The quantity of mediastinal drainage was 450 cc. He was extubated after intubation of 6 hours duration and stayed in intensive care for 2 days. The hospital stay was 10 days. Infectious Disease consultation recommended 10 more days of oral 1 × 400 mg/day cefixime after discharge. Chest X-ray showed optimal configuration of the ring (Figure 7). Postoperatively on the discharge day and after 2 months an echocardiographic investigation

IE treatment ended. Thorax and abdominal CT and MRI were normal.

He was operated on under endotracheal general anaesthesia and in the supine position. Following a median sternotomy, the pericard was opened longitudinally. After heparinization, extra-corporeal circulation was established between the venae cavae and the ascending aorta. A cross clamp was placed on the aorta and by antegrade intermittent

revealed minimal non-significant regurgitation for the repaired mitral valve (Figure 8). Postoperatively, the mitral valve area was found to be 3.76 cm² by pressure half-time echocardiography (Figure 9). The mean gradient of the mitral valve was 4.42 mm Hg. The functional capacity of our patient improved dramatically and he was in NYHA functional class I. We found no postoperative cardiac decompensation symptoms in our patient during late follow-up and he was followed at our outpatient clinic without additional problems.

Discussion

The incidence of infective endocarditis is approximately 1.7-6.2 cases per 100 000 patient years [6]. Patients can have severe cardiac injuries after infective valve endocarditis. Staphylococcal IE is a severe, life-threatening infection and makes up 1/3 of all IE cases [7]. *Staph. aureus* is one of the most tissue-injuring bacteria along with *Serratia sp*, *Pseudomonas sp*, *Brucella* and *Candida sp*. If staphylococci are the aetiological agent of the infection, surgery requirement increases and prognosis is poor due to high virulence, severe intracardiac injury and frequent embolic complications [8].

The need for robust diagnostic criteria uniting these means of investigation was shown by the original Von Reyn criteria, published in the early 1980s and subsequently superseded by the Duke criteria in the 1990s in the light of improved echocardiographic techniques [9]. Despite the high sensitivity and specificity of these original criteria, subsequent modifications have been suggested to acknowledge the increasing prevalence of staphylococcal infection. These modified Duke criteria have now been adopted in the latest guidelines from the European Society of Cardiology [1, 10].

Given the need for prolonged antibiotic treatment in most patients with infective endocarditis, positive microbiological cultures and sensitivities are vitally important for successful management [1]. Current guidelines recommend that three sets of blood cultures are drawn one hour apart before the introduction of antibiotic treatment – the first two sets are positive in more than 90% of cases [10].

Vegetations can be determined in 13 to 78% during IE attacks with echocardiography and clinical symptoms are found in 10 to 50% [11]. Emboli risk is 5 times higher in native mitral valve endocarditis [12]. Necropsy studies showed that embolization rate is 60% in kidney, 44% in spleen, 40% in brain and 30% in coronary arteries [11]. Many established series had 2 to 3 times higher embolic complication rate with staphylococcal IE than other aetiologies [12]. Recent studies did not confirm the value of

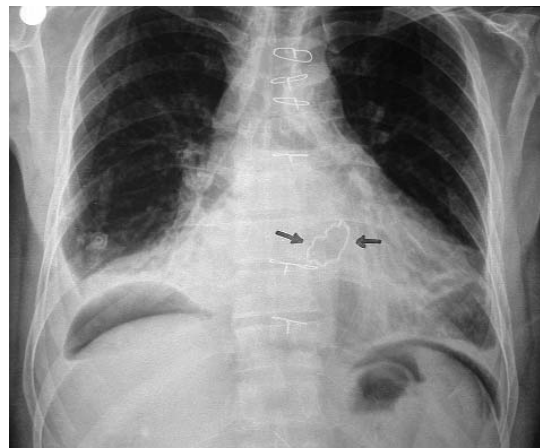


Figure 7. Postoperative chest X-ray showed optimal configuration of the ring

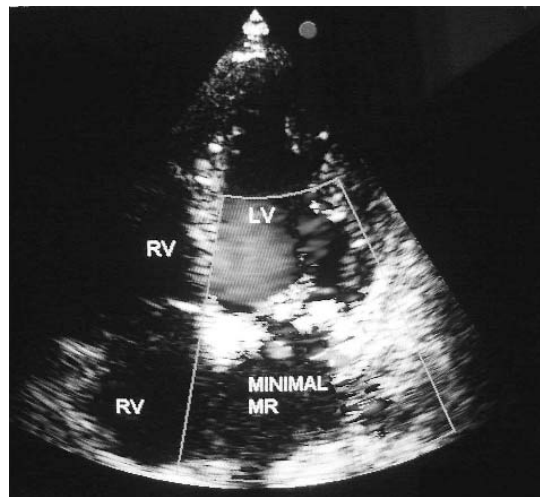


Figure 8. Postoperatively after 2 months an echocardiographic investigation revealed minimal mitral non-significant regurgitation

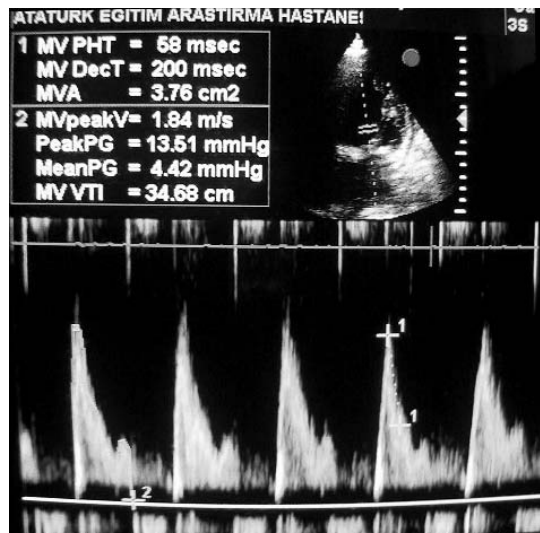


Figure 9. Postoperatively, the mitral valve area was found to be 3.76 cm²

Table I. Advantages of valve repair in native mitral valve endocarditis

Limits infective process
Prevents subvalvular apparatus
Prevents left ventricular function
Native valve tissue that is more resistant to infections remains instead of prosthesis
High re-infection risk due to prosthesis valve decreases
No perivalvular leak or valve regurgitation develop, as seen with prosthesis
Prevents the thromboembolic complications of a mechanical valve

echocardiography for embolism [13]. Still, >15 mm vegetation, determined with echocardiography at any location, is a definite embolism indicator [11]. In addition to morphology, mobility, persistence and rapid enlargement of the vegetation are absolute embolism risk factors [13]. According to our clinical approach we used antibiotic treatment for 6 weeks in endocarditis originated mobile masses and waited for at least 7 to 10 days without fever. But if a micro/macro embolus clinical table is seen during antibiotherapy in the lower or upper leg or cerebrum we prefer surgery although it is risky.

Surgery is often difficult and associated with high risk, not least because patients are frequently extremely sick with multisystem disease [1]. The first surgical treatment was performed in 1965 in an active IE patient and became effective in time [14]. Surgery is obligatory in at least 30% of active IE patients and in another 20 to 40% after healing [15].

From the 1970s, reconstructive surgery of the mitral valve was implanted definitively after the pioneering work of Carpentier [16]. Since then, clinical experience has shown that this conservative surgery involves minor hospital mortality and more satisfactory long-term clinical results [17]. Advantages of mitral valve repair in native mitral valve endocarditis are shown at Table I. Mitral valve reconstructive surgery without annuloplasty entails a high incidence of early failures [18]. The objectives of annuloplasty are: 1) to correct the annular dilatation, 2) to increase free edge coaptation, 3) to reinforce the annulus after a leaflet resection procedure, and 4) to prevent further annular dilatation. Flexible ring annuloplasties were introduced based on the principles of mitral valve reconstruction introduced by Carpentier, particularly after the discovery of the three-dimensional continuous movements of the valve annulus. A completely flexible Duran ring reduces the abnormally dilated annulus, allowing three dimensional configuration

of the mitral valve, and it was thought to be advantageous that the ring followed the changes of size and shape of the atrioventricular annulus in a physiological manner. Because our clinical results are consistent with the literature we prefer flexible rings instead of rigid or autologous pericardium.

In conclusion today operational mortality of 4 to 30% is an acceptable level. Five-year survival rate was 54% with medical treatment and 75% with medical and surgical combination [19]. Mitral valve endocarditis and MSCONS infections are the negative factors for long-term survival. As in our case, medical treatment protocol and elective surgery after control of infection decrease the short-term mortality and morbidity risk significantly.

References

1. Beynon RP, Bahl VK, Prendergast BD. Infective endocarditis. *BMJ* 2006; 333: 334-9.
2. Prendergast BD. The changing face of infective endocarditis. *Heart* 2006; 92: 879-85.
3. Cabell CH, Jollis JG, Peterson GE, et al. Changing patient characteristics and the effect on mortality in endocarditis. *Arch Intern Med* 2002; 162: 90-4.
4. Steckelberg JM, Murphy JG, Ballard D, et al. Emboli in infective endocarditis: the prognostic value of echocardiography. *Ann Intern Med* 1991; 114: 635-40.
5. Hart RG, Foster JW, Luther MF, Kanter MC. Stroke in infective endocarditis. *Stroke* 1990; 21: 695-700.
6. Mylonakis E, Calderwood SB. Infective endocarditis in adults. *N Engl J Med* 2001; 345: 1318-30.
7. Watanakunakorn C, Burkert T. Infective endocarditis at a large community teaching hospital 1980-1990. A review of 210 episodes. *Medicine (Baltimore)* 1993; 72: 90-102.
8. Nihoyannopoulos P, Oakley CM, Exadactylos N, Ribeiro P, Westaby S, Foale RA. Duration of symptoms and the effect of a more aggressive surgical policy: two factors affecting prognosis of infective endocarditis. *Eur Heart J* 1985; 6: 380-90.
9. Durack DT, Lukes AS, Bright DK. New criteria for diagnosis of infective endocarditis: utilization of specific echocardiographic findings. *Duke Endocarditis Service. Am J Med* 1994; 96: 200-9.
10. Horstkotte D, Follath F, Gutschik E, et al.; Task Force Members on Infective Endocarditis of the European Society of Cardiology; ESC Committee for Practice Guidelines (CPG); Document Reviewers. Guidelines on prevention, diagnosis and treatment of infective endocarditis executive summary; the task force on infective endocarditis of the European Society of Cardiology. *Eur Heart J* 2004; 25: 267-76.
11. Di Salvo G, Habib G, Pergola V, et al. Echocardiography predicts embolic events in infective endocarditis. *J Am Coll Cardiol* 2001; 37: 1069-76.
12. Steckelberg JM, Murphy JG, Ballard D, et al. Emboli in infective endocarditis: the prognostic value of echocardiography. *Ann Intern Med* 1991; 114: 635-40.
13. Vuille C, Nidorf M, Weyman AE, Picard MH. Natural history of vegetations during successful medical treatment of endocarditis. *Am Heart J* 1994; 128: 1200-9.
14. Wallace AG, Young WG, Osterhout S. Treatment of acute bacterial endocarditis by valve excision and replacement. *Circulation* 1965; 31: 450-3.

15. Jault F, Gandjbakhch I, Rama A, et al. Active native valve endocarditis: determinants of operative death and late mortality. *Ann Thorac Surg* 1997; 63: 1737-41.
16. Carpentier A. La valvuloplastie reconstructive: une nouvelle technique de valvuloplastie mitrale. *Press Med* 1968; 77: 251-3.
17. Antunes MJ, Magalhaes MP, Colsen PR, Kinsley RH. Valvuloplasty for rheumatic mitral valve disease. *J Thorac Cardiovasc Surg* 1987; 94: 44-56.
18. Deloche A, Jebara VA, Relland JY, et al. Valve repair with Carpentier techniques: the second decade. *J Thorac Cardiovasc Surg* 1990; 99: 990-1002.
19. Baumgartner FJ, Omari BO, Robertson JM, et al. Annular abscesses in surgical endocarditis: anatomic, clinical and operative features. *Ann Thorac Surg* 2000; 70: 442-7.