

Abdominal aortic aneurysmectomy in renal transplant recipients

Roberto Jiménez Gil, Francisco Morant Gimeno

Vascular Surgeon, Servicio de Cirugía Vascular, Hospital General Universitario de Alicante, Alicante, Spain

Submitted: 9 May 2008

Accepted: 11 August 2008

Arch Med Sci 2009; 5, 1: 111-114
Copyright © 2009 Termedia & Banach

Corresponding author:

Roberto Jiménez Gil, MD
Servicio de Angiología
y Cirugía Vascular
Hospital General
Universitario de Alicante
Avda/Pintor Baeza s/n
03010 Alicante (España)
Phone: 965938300
Fax: 965938329
E-mail: jimenez_rob@gva.es

Abstract

An increasing number of patients with kidney transplants are found to develop abdominal aortic aneurysm (AAA) in the post-transplant period. Aortic surgery in these patients places the pelvic allograft at risk for ischaemic damage. We report successful repair of two AAA in renal transplant recipients using cold graft perfusion and local hypothermia to protect the renal allograft during aortic cross-clamping. Conventional AAA surgery in patients with a kidney transplant is feasible without impairing renal function. In situ cold perfusion represents a safe method of renal protection with low risk of atheromatous embolization. Likewise, endovascular techniques may be an option in selected cases.

Key words: aortic aneurysm, abdominal, kidney transplantation, kidney cortex necrosis, infusions, intra-arterial, warm ischaemia.

Introduction

Cardiovascular diseases are the main cause of death among renal transplant recipients. The prevalence of abdominal aortic aneurysm (AAA) in patients with renal transplant is 1.01 to 6.7% [1]. *De novo* AAA develops in the transplant population in younger subjects and has faster enlargement, suggesting that haemodialysis length, hypertension, dyslipidaemia and steroid therapy may play a role. The incidence of acute renal failure after aortic surgery has ranged from 1 to 8% in elective cases [2], and in patients with mild or moderate degree of renal dysfunction the morbidity rates are higher than in patients with normal renal function [3]. Given the lack of collateralization of renal allografts, they are more susceptible to ischaemic injury than native kidneys. We report our experience in the management of these patients.

Case report

In the last 2 years two AAA were detected in renal transplant recipients. The first case is a 47-year-old man who had a right-sided renal transplantation 3 years earlier for the treatment of end-stage renal failure caused by chronic glomerulonephritis. He had precedents of arterial hypertension, dyslipidaemia and lumbar arthrodesis. A 4-cm AAA was detected 2 years earlier by echography and when it reached 5.5 cm confirmed by CT was sent for vascular repair. Through a transperitoneal approach an AAA with little calcified neck was dissected. Resection

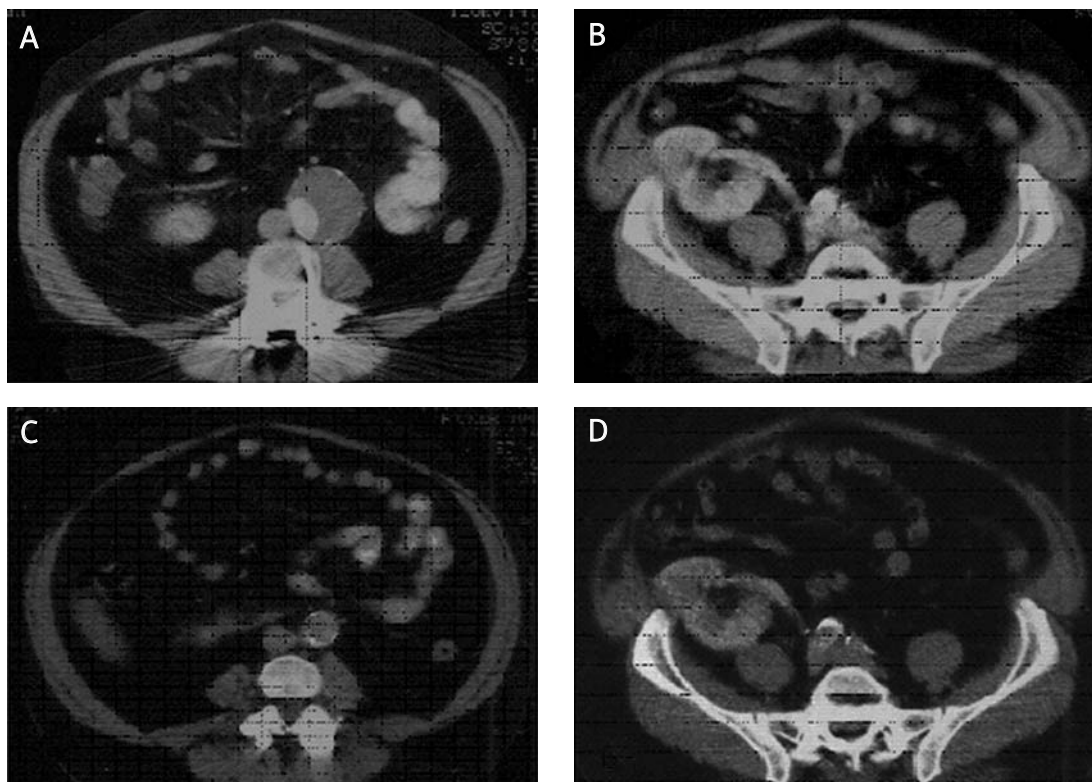


Figure 1 (Case n° 1). Preoperative CT scan shows the infrarenal AAA (A), and the transplanted kidney in the right pelvis (B). Computed tomography scan 1.5 years later showing the aorto-aortic prosthesis (C), and the patent transplant renal artery from the right iliac artery, with adequate parenchymal nephrogram (D)

of the aneurysm was performed and an aorto-aortic 18 mm Dacron graft was inserted. To preserve renal graft function during the aortic cross-clamping cold perfusion with heparinized 4° ringer lactate through a cannula inserted into the right iliac artery and local hypothermia with sterile ice were used. Intraoperative care included furosemide, mannitol and standard fluid administration; broad-spectrum antibiotic therapy was used.

The second case is a 63-year-old man with a right-sided kidney transplant 3 years earlier, when he had a 3.5 cm AAA; when it grew to 5.8 cm he was sent for vascular repair. The preoperative tests were acceptable. Through a midline incision the aneurysm was exposed, cold renal perfusion and local hypothermia were used, and an 18 mm straight Dacron graft was inserted. The immunosuppressive treatment and antibiotic therapy was controlled to prevent rejection or infectious complications.

Renal function did not change after the operation (preoperative serum creatinine levels were 1.56 and 2.18 mg/dl; postoperative 1.74 and 2.19 mg/dl respectively). The two patients are doing well, with good graft functioning after a follow-up of 1.5 and 2 years respectively.

Discussion

The aortic clamp during AAA repair may cause ischaemia of the renal graft and diverse procedures have been performed to preserve the function of the transplanted organ. Successful surgical repair of AAA in patients with a transplanted kidney has been reported without any form of renal transplant protection, with judicious clamping and rapid anastomosis, although the warm ischaemia time of the allograft should not take longer than 60 min [4]. This option could be made difficult by the possibility of finding a very diseased calcific or malacious aortic wall due to dialysis and immunosuppressive therapy. Lacombe suggested a double proximal clamp technique, which allows continuation of the retrograde flow from lumbar, inferior mesenteric and iliac arteries to perfuse the kidneys [2]. The aortic back pressure after aortic cross-clamping is between 35 and 60 mm Hg, and experimentally, a renal blood flow under a low arterial pressure of only 25 mm Hg is adequate for organ survival [2].

Renal ischaemia during aortic cross-clamping can be effectively reduced by cold graft perfusion and local hypothermia, as in our case. The renal oxygen

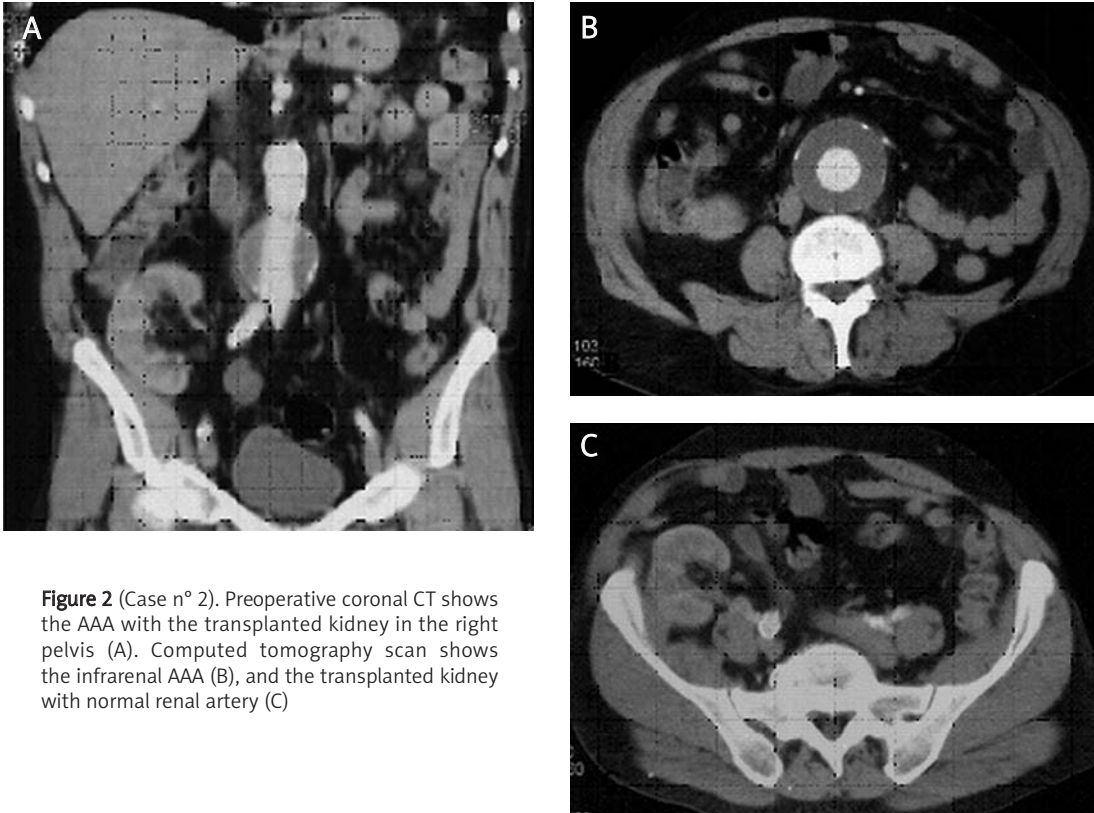


Figure 2 (Case n° 2). Preoperative coronal CT shows the AAA with the transplanted kidney in the right pelvis (A). Computed tomography scan shows the infrarenal AAA (B), and the transplanted kidney with normal renal artery (C)

consumption is reduced to 15% in hypothermia at 20°C and less than 5% at 10°C. Perfusion in situ with a 4°C solution reduces the cortical temperature to 13°C in 5 min, and a parenchyma temperature of 15-20°C allows approximately 2 h of reversible ischemia [1, 2]. Externally, kidneys are also packed with ice slush to provide additional protection, and the use of other adjuncts such as heparin may be helpful [5]. Intraoperatively forced diuresis with mannitol and furosemide is commonly used.

Temporary bypasses or shunts are performed from the axillary or subclavian artery or from the abdominal aorta above the aneurysm, or less frequently from the left atrial cavity or ascending aorta to the iliac or femoral vessels [6-8]. A temporary extra-anatomic shunt maintains renal transplant perfusion when conventional AAA repair is required. A shunt with partial extracorporeal circulation and pulsatile cold blood perfusion needs systemic anticoagulation; a shunt with centrifugal pump or a Gott shunt (heparin coated) does not need anticoagulation [1]. However, all these procedures entail possible distal arterial dissection or embolization and may increase the risk of haemorrhagic or infectious complications [1, 6]. When performing distal anastomosis on the aortic bifurcation proves difficult, in cases of iliac aneurysms or the need for femoral jump graft, renal perfusion must be assured.

The technique of *ex vivo* renal perfusion has been abandoned because of the risks of removing the transplant. Renal perfusion with a cardiopulmonary bypass pump oxygenator by cannulation of the femoral artery and vein is also low used [2, 8].

Endovascular repair in transplant recipients could avoid prolonged graft ischaemia during the aortic cross-clamping, with a reduction in systemic complications and in the hospitalization length. However, there is a risk of vascular damage at the graft anastomotic site, so, if implant dislocation occurs, graft thrombosis may happen [2, 9, 10]. The decision to implant a bifurcated or an aorto-uni-iliac device depends on the anatomical characteristics of the aneurysm. The bifurcated stent graft maintains in-line flow to the renal transplant. The larger delivery system for the main body of the graft can be inserted *via* the contralateral iliac artery. On the other hand, the aorto-uni-iliac system has the potential disadvantages of an extra-anatomic approach, such as anastomotic stenosis, graft infection [11].

Standard open surgery without adjunctive shunts or bypasses remains a viable treatment option for these patients. Renal ischaemia during aortic cross-clamping can be effectively reduced by cold graft perfusion and local hypothermia. In

addition, the potential risk of atheromatous embolization to the transplanted kidney is less than for other temporary procedures of shunt or bypass. The endovascular technique may be used for patients who meet the anatomical criteria for endovascular repair and are at high risk for a conventional operation.

References

1. Favi E, Citterio F, Tondolo V, et al. Abdominal aortic aneurysm in renal transplant recipients. *Transplant Proc* 2005; 37: 2488-90.
2. Waikar HD, Neelakandhan KS, Ravimandalam K. Abdominal aortic aneurysmectomy in a patient with bilateral renal autotransplants. *J Cardiothorac Vasc Anesth* 1995; 9: 66-70.
3. Sever K, Kiziltan F, Basaran M, et al. The surgical treatment of abdominal aortic aneurysms in patients with light to moderate renal dysfunction. *Acta Chir Belg* 2004; 104: 695-9.
4. Skelly CL, Farmer AJ, Curi MA, et al. Aortic reconstruction in patients with functioning renal allografts. *Ann Vasc Surg* 2002; 16: 779-83.
5. Botta GC, Capocasale E, Rubini P, Tondo S. Resection of an aortic aneurysm in a renal transplant recipient using hypothermic perfusion. *Nephrol Dial Transplant* 1999; 14: 1295-6.
6. Bui TD, Wilson SE, Gordon IL, Fujitani RM, Carson J, Montgomery RS. Renal function after elective infrarenal aortic aneurysm repair in patients with pelvic kidneys. *Ann Vasc Surg* 2007; 21: 143-8.
7. Kashyap VS, Quiñones-Baldrich WJ. Abdominal aortic aneurysm repair in patients with renal allografts. *Ann Vasc Surg* 1999; 13: 199-203.
8. Lepäntalo M, Biancari F, Edgren J, Eklund B, Salmela K. Treatment options in the management of abdominal aortic aneurysm in patients with renal transplant. *Eur J Vasc Endovasc Surg* 1999; 18: 176-8.
9. Khanmoradi K, Brewster DC, Haddad FF, Cho SI. Endovascular repair of abdominal aortic aneurysm in a kidney transplant with 4-year follow-up. *Surgery* 2004; 136: 103.
10. Ailawadi G, Bedi A, Williams DM, Stanley JC, Upchurch GR Jr. Endovascular treatment of aortic aneurysms in patients with renal transplants. *J Vasc Surg* 2003; 37: 693-6.
11. Karkos CD, McMahon G, Fishwick G, Lambert K, Bagga A, McCarthy MJ. Endovascular abdominal aortic aneurysm repair in the presence of a kidney transplant: therapeutic considerations. *Cardiovasc Intervent Radiol* 2006; 29: 248-88.