

The role of intraoperative transesophageal echocardiography in tricuspid valve annuloplasty – 15 years follow-up (1988-2003)

Anna Kośmider, Maciej Banach, Janusz Zastónka, Ryszard Jaszewski, Andrzej Walczak, Radostaw Zwoliński, Maciej Kośmider

Department of Cardiac Surgery, Medical University Hospital No 3, Medical University in Lodz, Poland

Submitted: 11 January 2005

Accepted: 2 April 2005

Arch Med Sci 2005; 1, 1: 48-54

Corresponding author:

Anna Kośmider, MD PhD
Department of Cardiac Surgery,
Medical University of Lodz
Sterlinga 1/3; 91-425 Lodz, Poland
Phone/fax: +48 42 633 15 58
E-mail: maciej.banach@kardiolog.pl

Abstract

Objectives: Tricuspid valve regurgitation is usually secondary and results from the changes in geometry of tricuspid annulus, dilatation or overload of right atrium and right ventricle. The aim of the study was the assessment of early and long-term results of tricuspid valve annuloplasty performed in the Department of Cardiac Surgery in Lodz, Poland between 1988-2003.

Design: The study group consisted of 267 patients with tricuspid valve regurgitation. Tricuspid valve annuloplasty was performed using two methods: De Vega in 70 patients (26.2%) and Revuelta in 197 patients (73.8%). All patients were referred to tricuspid surgery on the ground of classic echocardiography and in 92 cases transoesophageal echocardiography was necessary to verify diagnosis. Intraoperative transoesophageal echocardiography was performed in 162 patients (60,7%).

Results: Throughout the long-term follow-up rates of patients with good result of tricuspid annuloplasty were: 86% after 5 years, 45% after 12 years, and 40% after 15 years. Since 1997, due to excellent results, tricuspid annuloplasty has been performed using Revuelta procedure only. Within 6-years follow-up after tricuspid annuloplasty a necessity of reoperation was observed in 19 patients (7.1%) from a subgroup without intraoperative transoesophageal echocardiography and in only 2 (0.75%) from a subgroup with transoesophageal echocardiography monitoring.

Conclusion: Intraoperative transoesophageal echocardiography seems to be a method of choice in assessment of tricuspid annuloplasty efficacy which was confirmed by the long-term outcomes. Tricuspid valve annuloplasty using Revuelta procedure, intraoperatively verified by transoesophageal echocardiography, is currently a standard method in our department. Pulmonary hypertension and deteriorated systolic and diastolic right ventricular function yield with worse long-term results.

Key words: revuelta procedure, transoesophageal echocardiography, tricuspid valve annuloplasty, tricuspid valve regurgitation.

Introduction

Tricuspid valve dysfunction is not usually accompanied by leaflets malformation. Tricuspid insufficiency is generally secondary and it is caused by a dilatation or geometry changes of tricuspid annulus due to right ventricle enlargement and is connected with the increase of right ventricle systolic and diastolic pressure. It is most frequently combined with

Table I. The demographical and clinical characteristics of the study group (n=267)

Characteristic	n (%)
Sex – female/male	212 (79.4)/55 (20.6)
Age (years)	35-74 mean 54±8,4
History of previous cardiac surgery	
Mitral commissurotomy	62 (23.2)
Mitral bioprosthesis implantation	23 (8.6)
Mitral mechanical valve implantation	13 (4.9)
Mitral and aortic mechanical valve implantation	4 (1.5)

rheumatic mitral or aortic valve disease [1, 2, 3]. Less frequently tricuspid regurgitation is a result of rheumatic inflammation of the leaflets, pathological changes in Marfan's disease, infective endocarditis, tricuspid valve prolapse and is associated with congenital heart diseases, such as: Ebstein's anomaly, atrial septal defect and others.

Recently, echocardiography is a based method of evaluation of tricuspid valve morphology and function and allows to diagnose other abnormalities influencing its dysfunction. Echocardiography, along with clinical symptoms, helps to establish the best moment of surgical treatment and to choose proper surgical method [2, 4-6].

Until now there have been only few studies comparing the techniques of tricuspid valve annuloplasty and ways of monitoring of valvular tightness after operation. In many cases the study outcomes are totally opposed [7-10].

The aim of our study was to assess early and long-term results of tricuspid valve annuloplasty depending on the surgery technique (De Vega vs. Revuelta annuloplasty) and the ways of intraoperative monitoring of valvular tightness (transesophageal echocardiography – TEE vs. "water" competence test and direct palpation of the valve). Some selected clinical and echocardiographic parameters depending on the presence of pulmonary hypertension and time elapsed from the operation were also analyzed.

According to recent results the introduction of intraoperative transoesophageal echocardiography presents the further improvement in treatment of tricuspid valve dysfunction [10-14].

Material and methods

267 patients with tricuspid valve incompetence subjected for tricuspid annuloplasty at the Department of Cardiac Surgery, Medical University in Lodz, Poland, between 1988 and 2003 were involved to the study. The clinical characteristics of engaged patients is shown in Tables I, II and III.

The grade of tricuspid insufficiency was assessed with commonly regarded echocardiographic

Table II. Tricuspid insufficiency coexisting with other valvular defects (n=237 – 88.7%)

	n (%)
Mitral valve defect	211 (79)
Aortic valve defect	7 (2.6)
Mitral and aortic valve defect	19 (7.1)

Table III. Tricuspid insufficiency not coexisting with other valvular defects (n=18 – 6.7%)

	n (%)
Infectious endocarditis	8 (3)
Ebstein anomaly	3 (1.1)
Tricuspid valvular leaflets prolapse	1 (0.4)
Atrial septal defect type II	6 (2.2)

methods [1, 2, 4, 5, 12] including pulsating, continuous and color marked Doppler technique. Measures of the tricuspid incompetence included: reach of regurgitation wave in the right atrium, area of regurgitation wave and its relation to a total area of the right atrium, diameter of regurgitation gate (vena contracta) at the level of a free edge of the valve obtained in color marked Doppler echocardiography, proximal zones of convergence (PISA – *Proximal Isovelocity Surface Area*), reflux of contrasted blood into inferior caval vein.

Systolic pulmonary pressure, dimensions of right atrium and right ventricle as well as its systolic and diastolic function were also assessed [1, 2].

In the preoperative period transthoracic echocardiography (TTE) was performed in all examined patients and in 92 (34.5%) of them the findings were verified using transesophageal echocardiography. Intraoperative TEE was performed to assess the efficacy of the annuloplasty in 162 patients (60.7%). Early after the surgery (days) all patients the control TTE was performed and it was repeated twice or three times during the follow-up. Throughout the follow-up TEE was performed in selected cases (41 patients – 15.4%) in order to verify the significance of tricuspid incompetence detected

Table IV. Surgical procedures performed in the study group

Types of procedures	n (%)
Mitral valve replacement	205 (76.7)
Mitral valve replacement and coronary artery by-pass grafting	18 (6.7)
Aortic valve replacement	7 (2.6)
Aortic valve replacement and coronary artery by-pass grafting	5 (1.9)
Mitral and aortic valve replacement	19 (7.1)
Mitral and aortic valve replacement and coronary artery by-pass grafting	4 (1.5)
Surgical closure of atrial septal defect	6 (2.2)
Correction of Ebstein anomaly	3 (1.1)

in TTE. The incompetence of third or fourth degree was considered to be significant [1, 3, 12]. Only 30 of 267 patients (11.2%) underwent isolated tricuspid annuloplasty (see Table IV).

All 267 patients who underwent tricuspid annuloplasty were divided into two study groups:

- Group I – 162 patients operated between 1991 and 2003, monitored intraoperatively with TEE;
- Group II – 105 patients operated between 1988 and 2003 without intraoperative TEE monitoring.

The efficacy of tricuspid annuloplasty was assessed intraoperatively with water test and direct palpation in 201 (75.3%) patients and with TEE method in 162 patients (60.7%). Direct intraatrial palpation and water tightness test occurred to be unreliable and insufficient methods of postoperative assessment of significant residual tricuspid incompetence as they were enabled to evaluate of potential tricuspid stenosis resulting from the annuloplasty [12, 15].

Tricuspid annuloplasty was performed with either De Vega (classical) method using continuous suture (70 patients – 26.2%) or Revuelta (segmental) method using interrupted sutures (197 patients – 73.8%) (Figures 1 and 2).

De Vega procedure: The tricuspid valve was exposed through a right atriotomy and tested for incompetence by injecting saline into the right ventricle. A pledgetted annuloplasty suture of 3-0 or 4-0 polypropylene was started at the anterosseptal commissure and sewn intermittently to the junction of the annulus and the right ventricle along the anterior and posterior leaflets until just past the posteroseptal commissure. Another pledget was placed and the suturing was reversed along the posterior and anterior leaflets 1 to 2 mm from the first row alternating the suture technique until the original pledget at the anterosseptal commissure was reached.

Revuelta procedure: After having the tricuspid valve carefully visualized and the tricuspid leaflets inspected, the tricuspid ring is identified by gentle traction of the anterior leaflet of the tricuspid valve with the valve hook, then the first stitch is placed using 2/0 pledgetted suture in the region of the posteroseptal commissure to protect the coronary sinus from being injured. The next series of stitches are placed in counter-clockwise manner. The interrupted stitches follow the line that demarcates the tricuspid ring and are placed until the region of

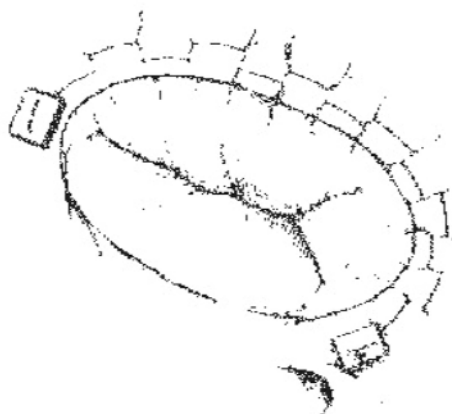


Figure 1. Tricuspid annuloplasty with De Vega (classical) method

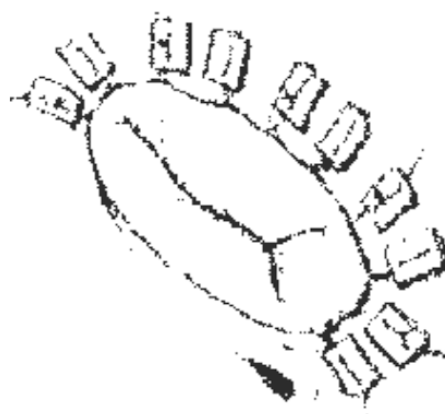


Figure 2. Tricuspid annuloplasty with Revuelta (segmental) method

Table V. Modification of operation techniques (18 patients – 6.7%)

	n (%) (patients)
Implantation of artificial ring – Carpentier-Edwards or Jomed	8 (3)
Tricuspid valve replacement	5 (1.9)
Reimplantation of artificial mitral valvae due to dysfunction	3 (1.1)
Thrombus removal from artificial mitral valvae	2 (0.75)

the anteroseptal commissure is reached. In general, 5 or 6 stitches are needed to complete the annuloplasty. The annuloplasty must include the portion of the annulus corresponding to the anterior and posterior leaflets of the tricuspid valve.

Statistical analysis was performed using Pearson's chi-squared test and two-sample test for fractions. Comparing continuous variables the statistical analysis was performed using Student's t test.

Results

Intraoperative mortality rate was 3.7% (10 patients) and early postoperative in-hospital mortality rate was 0.75% (2 patients). The main causes of death were thromboembolic complications and low cardiac output (e. g. due to intraoperative cardiac infarct). Throughout 15-years follow-up the rate of patients with good result of tricuspid annuloplasty, evaluated after 5, 12 and 15 years, defined as absence of tricuspid incompetence or as first or second degree incompetence was 86%, 45% and 40% respectively (Figure 3). During mean follow-up of 6 years the necessity of reoperation due to significant tricuspid incompetence was observed in 19 patients (7.1%) from group II (without intraoperative TEE) and in only 2 patients (0.75%) from group I (with TEE). Due to very good outcomes, since 1997 tricuspid annuloplasties have been performed using Revuelta method only (Figure 4).

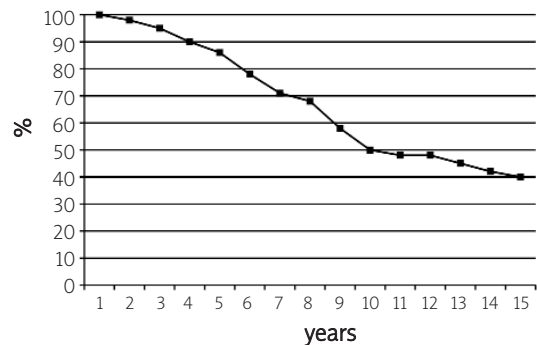
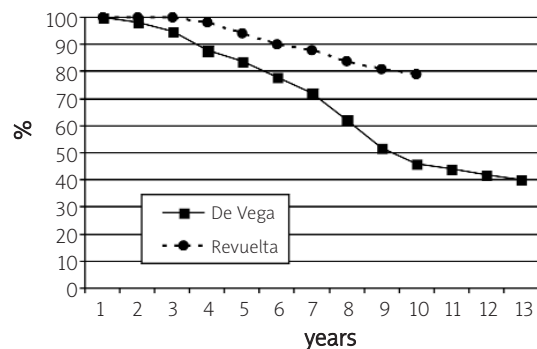
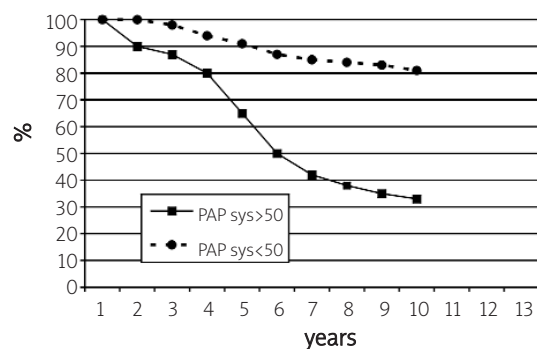
Mean time of heart defect duration of one or many valves from diagnosis to operation was 3.4 years (from 1 to 25 years). We observed that the longer the time from valve defect diagnosis to surgical treatment, the worse early and long-term results.

A significant disadvantageous influence of pulmonary hypertension on long-term results of tricuspid annuloplasty were also observed (Figure 5).

However no relations were observed between early and long-term results of tricuspid annuloplasty and other echocardiographic parameters. On the basis of intraoperative TEE the primary qualification and surgical procedure were changed in 18 patients (6.7%) (Table V).

Discussion

Proceeding in tricuspid valve defect depends on its etiology and clinical state of the patient. Thanks

**Figure 3.** Percentage of patients with good results of tricuspid annuloplasty (15 years follow-up)**Figure 4.** Percentage of patients with good results of tricuspid annuloplasty depending on method (De Vega or Revuelta)**Figure 5.** Percentage of patients with good results of tricuspid annuloplasty depending on pulmonary arterial pressure (PAP sys – systolic pulmonary arterial pressure).

to intraoperative TEE it is possible to choose the optimal technique of tricuspid annuloplasty and in this way improve outcomes of surgical treatment of advanced tricuspid valve incompetence [1, 2, 5, 7, 8, 11, 12]. In case of significantly destroyed leaflets the annuloplasty may occur impossible to perform and tricuspid valve replacement using bioprosthesis or artificial mechanical valve may be necessary.

In case of significant relative tricuspid incompetence, secondary to other valvular defects (most frequently to mitral stenosis) tricuspid valve repair should be performed simultaneously with the correction of the basic defect [3, 12, 15, 17]. Since the bringing of two-dimension and Doppler echocardiography into assessment of tricuspid valve, the indications for tricuspid valve surgery have been clear-cut and have not aroused controversies [1, 2, 7-12, 15, 16].

In a recently published work of McCarthy et al., the authors compared durability of tricuspid valve annuloplasty techniques, identified risk factors for repair failure and characterized survival, reoperation and functional class of surviving patients. 790 patients, who underwent tricuspid valve annuloplasty for functional regurgitation using 4 techniques: Carpentier-Edwards semi-rigid ring, Cosgrove-Edwards flexible band, De Vega procedure and customized semicircular Peri-Guard annuloplasty, were engaged to the study. Regurgitation severity was stable across time with the Carpentier-Edwards ring, increased slowly with the Cosgrove-Edwards band and rose more rapidly with the De Vega and Peri-Guard procedures. Risk factors for worsening regurgitation included: higher preoperative regurgitation grade, poor left ventricular function, permanent pacemaker and technique of valvular repair other than ring annuloplasty. The authors suggested that tricuspid valve annuloplasty did not consistently eliminate functional regurgitation and across time regurgitation increased importantly after Peri-Guard and De Vega annuloplasties [7].

Analysis of nineteen years' results of De Vega's tricuspid annuloplasty for functional tricuspid regurgitation was carried out by Morishita et al. 408 patients who underwent De Vega's tricuspid annuloplasty were engaged to the study. Within 30 postoperative days the authors ascertained 3.4% early deaths. There were also 15.4% late deaths during the follow-up period. The survival rate at 15 years after operation was 74.0%. In reverse to McCarthy et al. study, mentioned above, the authors concluded that De Vega's tricuspid annuloplasty was an effective and reliable procedure of choice for secondary tricuspid regurgitation with annular dilatation [8].

In the study of Carrier et al. the authors evaluated whether to use biological or mechanical prostheses and whether to repair or replace the tricuspid valve during primary and reoperative triple valve surgery. They used either CarboMedics or Carpentier-

Edwards heart valves. Aortic valve replacement was performed with CarboMedics prostheses and Carpentier-Edwards prostheses. Tricuspid valve repair consisted of annuloplasty with the Bex linear reducer, the Carpentier-Edwards ring or the De Vega technique. Tricuspid valve replacement was carried out using the Carpentier-Edwards pericardial prostheses. The 30-day mortality was 17% and 12% in patients with primary and reoperative surgery, respectively and patient survival averaged 80%±7%, 75%±8% and 41%±15% and 70%±7%, 57%±9% and 50%±10%, respectively 1, 5, and 10 years following surgery. The authors recapitulated that triple valve surgery, either as a primary or a reoperative procedure, results in acceptable long-term survival with both mechanical and biological prostheses [11].

Early- and long-term results of Revuelta annuloplasty were much better than in the group of patients who underwent De Vega annuloplasty ($p < 0.05$). This is the main reason that nowadays we use only the Revuelta method in our Department [3, 8-11, 18].

Dynamic development of transoesophageal echocardiography fell on the eighties but only in the nineties followed the further extension of the technique application in cardiac surgery – intraoperative TEE [6, 9, 12-14, 16, 19, 20]. Intraoperative TEE is usually performed as an elective monitoring but sometimes (in case of intraoperative or early postoperative complications) it is used in emergency [6, 9, 12, 14, 16, 19-21]. Elective monitoring allows to choose optimal operative technique and best operating procedure. It helps also to assess its efficacy [3, 14, 16, 17, 20]. In case of incomplete preoperative diagnosis, this method enables to verify pathological changes intraoperatively and, if necessary, to modify the surgical procedure, which was confirmed by the authors' observations. The possibility of early assessment of left ventricular function directly after cardiac surgery is of special importance and may help to make proper therapeutic decisions in the operating room and in the Intensive Care Unit (ICU) [6, 16, 20, 21]. In many scientific works authors emphasized the role of transoesophageal echocardiography (TEE) in analyzing tricuspid valve repair results [9]. In the article of De Simone et al. the authors reviewed the role of echocardiography in tricuspid valve repair by analyzing the results of three clinical studies. The first investigation was performed for assessing the results of two surgical techniques of patients who underwent De Vega's suture annuloplasty or Carpentier-Edwards ring implantation. The patients were studied by color Doppler echocardiography after a mean follow-up of 28.7±11.1 months. The results showed lower degree of tricuspid valve regurgitation in the group of patients who underwent De Vega annuloplasty. In the second study, patients with moderate to severe tricuspid regurgitation underwent De Vega's

annuloplasty. After cardiopulmonary bypass the tension on the suture was adjusted until the surgeon could not feel any regurgitant jet by the intraatrial palpation; subsequently, the tension was further adjusted under guidance of TEE. The data obtained by the traditional palpation were compared with the data obtained by TEE. A significant reduction of residual tricuspid regurgitation was acquired by TEE comparing to the data obtained by intraatrial palpation. The results showed that application of TEE was able to optimize the De Vega's annuloplasty by reducing residual tricuspid regurgitation. In the third study authors investigated tricuspid valve regurgitation commonly observed after orthotropic cardiac transplantation (HTX). The aim of the study was to evaluate the degree of regurgitation and all patients undergoing HTX were studied intraoperatively by TEE. The results showed that tricuspid regurgitation occurs in most patients immediately after HTX. De Simone suggested that the above mentioned clinical investigations confirmed a many-sided, essential role of TEE in tricuspid valve repair. It provides not only a useful diagnostic tool for evaluating residual regurgitation, but it may actively guide the surgical procedures and contribute to improve the surgical technique [16]. Authors of this study observed also a great usefulness of intraoperative TEE in choice of the optimal surgical procedures and in case of the necessity of carrying out another cardiosurgical procedure and improving effects of annuloplasty [3, 9, 12, 15, 16, 19, 22]. The outcomes' analysis in the big cohort of patients who underwent tricuspid annuloplasty allowed to identify the most effective surgical method of tricuspid insufficiency treatment – the Revuelta annuloplasty. Throughout a mean follow-up of 6 years, in patients with intraoperative TEE monitoring, only two cases (0.75%) of significant tricuspid insufficiency recurrence requiring the reoperation were observed. During the same follow-up period, in the group without TEE monitoring, in which only water competence test and direct palpation were used to assess the efficacy of tricuspid annuloplasty, the rate of reoperation due to significant tricuspid insufficiency was 7.1% (19 patients). The similar observations were also published by the other authors [7, 8, 11, 12, 15, 16]. Intraoperative TEE during a few last years became the routine performed test, which allowed to identify a group of patients whose cardiosurgical procedures were extended and intraoperative indications were changed. The long-term results of tricuspid annuloplasty depend on the grade of pulmonary hypertension [10, 12, 15] and such observations were confirmed by the authors of this study. No relations were observed, however, between early- and long-term results of tricuspid annuloplasty and other echocardiographic parameters [2, 3].

The worse early and long-term outcomes in the group of patients with longer duration of heart defect can be combined with higher blood pressure in pulmonary artery, larger size of the right ventricle and atrium and secondary changes in the respiratory system [7-9, 11, 16].

Conclusions

- Intraoperative TEE monitoring of tricuspid annuloplasty should be a gold standard as it exactly evaluates the effect of the surgery and influences significantly improvement of early- and long-terms results after the annuloplasty.
- The optimal method of surgical correction of tricuspid insufficiency is Revuelta annuloplasty.
- The predictor of worse long-term results of tricuspid annuloplasty is pulmonary hypertension.

References

1. Bohmeke Th. Weberk. Echokardiografia. Wydawnictwo Lekarskie PZWL, Warszawa 2000: 133-136.
2. Feigenbaum H. Echocardiography. Lea and Febiger. A Waverly Company, The United States 1994: 293-297.
3. Maciejewski M, Zaslonka J, Moczak R et al. Śródoperacyjne, przezprzełykowe, echokardiograficzne badanie dopplerowskie i jego wpływ na wyniki anuloplastyki zastawki trójdzielnej. *Kardol Pol* 1996; 44: 125-33.
4. Loperfido F, Lombardo A, Amico CM, Vigna C, Testa M, Rossi E et al. Doppler analysis of portal vein flow in tricuspid regurgitation. *J Heart Valve Dis* 1993; 2: 174-83.
5. Mijatake K, Okamoto M, Kinoshita N, Ohta M, Kozuka T, Sakakibara H et al. Evaluation of tricuspid regurgitation by pulsed Doppler and two-dimensional echocardiography. *Circulation* 1982; 66: 777-84.
6. Loperfido F, De Santis F, Solfanelli N, Pennestri F, Mazzari M. Tricuspid regurgitation due to sinus of Valsalva-right heart fistula diagnosed by two-dimensional echocardiography. *Chest* 1984; 86 (3): 501-3.
7. McCarthy PM, Bhudia SK, Rajeswaran J, Hoercher KJ, Lytle BW, Cosgrove DM et al. Tricuspid valve repair: durability and risk factors for failure. *J Thorac Cardiovasc Surg* 2004; 127: 674-85.
8. Morishita A, Kitamura M, Noji S, Aomi S, Endo M, Koyanagi H. Long-term results after De Vega's tricuspid annuloplasty. *J Cardiovasc Surg (Torino)* 2002; 43: 773-7.
9. De Simone R, Lange R, Tanzeem A, Hagl S. Adjustable De Vega tricuspid valve annuloplasty guided by transesophageal echocardiography. *Ann Thorac Surg* 1995; 59: 1272.
10. Bajzer CT, Stewart WJ, Cosgrove DM, Azzam SJ, Arheart KL, Klein AL et al. Tricuspid valve surgery and intraoperative echocardiography: factors affecting survival, clinical outcome, and echocardiographic success *J Am Coll Cardiol* 1998; 32 (4): 1023-31.
11. Carrier M, Pellerin M, Bouchard D, Perrault LP, Cartier R, Hebert Y et al. Long-term results with triple valve surgery. *Ann Thorac Surg* 2002; 73: 44-7.
12. De Simone R, Lange R, Tanzeem A, Gams E, Hagl S et al. Adjustable tricuspid valve annuloplasty assisted by intraoperative transesophageal color Doppler echocardiography. *Am J Cardiol* 1993; 71: 926-31.
13. Bonato R, Pittarello D, Armellini G, Scalia D, Sorbara C. The value of transesophageal echocardiography during cardiac surgery. *Minerva Anestesiol* 2000; 66 (9): 661-4.

14. Kallmeyer IJ, Collard CD, Fox JA, Body SC, Shernan SK. The safety of intraoperative transesophageal echocardiography; a case series of 7200 cardiac surgical patients. *Anesth Analg* 2001; 92 (5): 1126-30.
15. De Simone R, Lange R, Tanzeem A, Tanzeem A, Hagl S. Intraoperative transesophageal echocardiography for the evaluation of mitral, aortic and tricuspid valve repair. A tool to optimize the surgical outcome. *Eur J Cardiothorac Surg* 1992; 6: 665-73.
16. De Simone R, Lange R, Iacono A, Hagl S. Role of transesophageal echocardiography in tricuspid valve repair. *Cardiologia* 1994; 39: 87-101.
17. Couture P, Denault AY, McKenty S, Boudreault D, Plante F, Perron R et al. Impact of routine use of intraoperative transesophageal echocardiography during cardiac surgery: *Can J Anaesth* 2000; 47 (1): 20-6.
18. Duran CM, Kumar N, Prabhakar G, Ge Z, Bianchi S, Gometza B. Vanishing De Vega annuloplasty for functional regurgitation. *J Thorac Cardiovas Surg* 1993; 106: 609-13.
19. Mishra M, Chauhan R, Sharma KK, Dhar A, Bhise M, Dhole S et al. Real-time intraoperative transesophageal echocardiography – how useful? Experience of 5,016 cases. *J Cardiothorac Vasc Anesth* 1998; 12 (6): 625-32.
20. Shanewise JS, Cheung AT, Aronson S, Stewart WJ, Weiss RL, Mark JB et al. ASE/SCA Guidelines for Performing a Comprehensive Intraoperative Multiplan Transesophageal Echocardiography Examination: Recommendations of the American Society of Echocardiography Council for Intraoperative Echocardiography and the Society of Cardiovascular Anesthesiologists Task Force for Certification in Perioperative Transesophageal Echocardiography: *Anesth Analg* 1999; 89: 870-84.
21. Skiles JA, Griffin BP. Transesophageal Echocardiographic (TEE) evaluation of ventricular function. *Cardiol Clin* 2000; 18 (4): 681-97.
22. Click RL, Abel MD, Schaff HV. Intraoperative transesophageal echocardiography: 5-year prospective review of impact on surgical management: *Mayo Clin Proc* 2000; 75 (3): 241-7.