

# Pulmonary hypoplasia and congenital renal anomalies

Caroline May, Anne Greenough

Division of Allergy, Asthma and Lung Biology, Guy's, King's and St Thomas' School of Medicine, King's College London

**Submitted:** 11 February 2006

**Accepted:** 2 March 2006

Arch Med Sci 2006; 2, 1: 6-9

Copyright © 2006 Termedia & Banach

**Corresponding author:**

Professor Anne Greenough  
4<sup>th</sup> Floor Golden Jubilee Wing  
King's College Hospital  
Denmark Hill, London  
SE5 9RJ, UK  
Phone: +44 20 7346 3037  
Fax: +44 20 7346 8284  
E-mail: anne.greenough@kcl.ac.uk

## Abstract

The association of pulmonary hypoplasia with bilateral renal agenesis is well recognised. It is important, however, for clinicians to be aware that pulmonary hypoplasia does occur with other congenital renal anomalies and worsens the prognosis.

The aims of this review are to highlight other kidney and associated pulmonary abnormalities, describe the mechanisms of abnormal lung growth associated with renal anomalies and to discuss the relative merits of antenatal diagnostic and possible therapeutic interventions.

Pulmonary hypoplasia most commonly occurs in fetuses with bladder outlet obstruction, but also in those with bilateral renal dysplasia/hypoplasia and multicystic kidneys. Possible mechanisms include reduced amniotic fluid volume and renal proline production and thoracic compression. Antenatally, pulmonary hypoplasia may be predicted by oligohydramnios or the presence of ex-renal compression abnormalities. Assessment of the thoracic or lung size by two-dimensional ultrasound examination is insufficiently specific, but calculation of the thoracic to head ratio may prove a more accurate method of diagnosis of fetal pulmonary hypoplasia. Magnetic resonance imaging evaluation of fetal lung volume is expensive and has limited patient acceptability; three-dimensional ultrasonography may prove a better option, but ultrasonography can be inaccurate if there is oligohydramnios. Antenatal therapeutic intervention is directed at relieving urinary tract obstruction, but vesico-amniotic shunting has a high morbidity and whether it improves the pulmonary outcome of fetuses with renal anomalies requires quantitative evaluation.

It is essential if appropriate counselling is to be undertaken, to determine if a fetus with renal anomalies has associated pulmonary maldevelopment.

**Key words:** lung growth, oligohydramnios, ultrasonography.

## Introduction

The association of fatal pulmonary hypoplasia with bilateral renal agenesis has been recognised for many years [1]. The common features associated with those anomalies are known as the Potter's syndrome: oligohydramnios, characteristic facial abnormalities, including low set floppy ears, a small chin, a flattened nose, hypertelorism and epicanthic folds [2] and limb defects including talipes equinovarus and flexion contractures [3]. It is now appreciated that fatal pulmonary hypoplasia occurs with other congenital renal anomalies. Data from the Northern Congenital Abnormality Survey highlighted that a high (19.6%) proportion of pregnancies, in which a congenital anomaly of the fetal urinary tract had been identified, failed to produce a living child [4]. A fatal outcome was commonest with bilateral renal agenesis and bladder outlet

obstruction, but also occurred with bilateral renal dysplasia/hypoplasia and multicystic kidney [4]. We have reviewed the literature, our aim being to describe possible mechanisms of abnormal lung development in fetuses with congenital renal anomalies and, in particular, discuss the relative merits of diagnostic tests for pulmonary hypoplasia and whether antenatal interventions successfully prevent the development of pulmonary hypoplasia.

### **Mechanisms of abnormal lung growth**

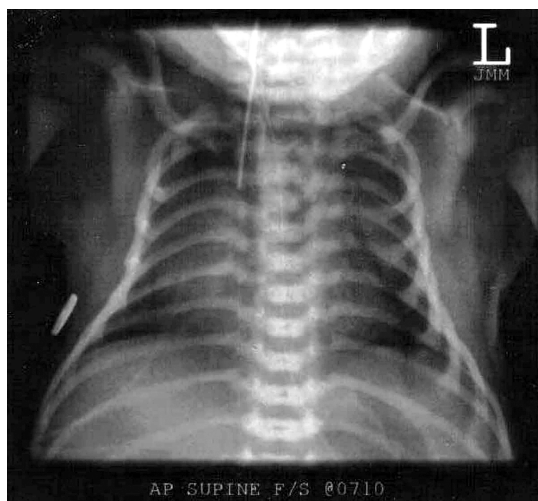
Pulmonary hypoplasia occurs in fetuses with renal anomalies when there has been reduced amniotic fluid volume. Experimental production of oligohydramnios either by chronic drainage of amniotic fluid [5] or urinary tract obstruction [6] results in the development of pulmonary hypoplasia. Oligohydramnios may impair lung growth by thoracic compression [7], but there may be other mechanisms. Fetal breathing movements are essential for normal antenatal lung growth [8] and fetal breathing movements were found to be significantly lower in patients with oligohydramnios due to prolonged preterm and premature rupture of the membranes [9]. Absence of fetal breathing movements, however is not an invariable association of oligohydramnios [10] and, in an animal model, reduction in fetal breathing movements and amniotic fluid volume had additive effects with regard to producing severe lung disease [11]. Normal antenatal lung growth is also dependent on fetal lung fluid secretion. It has been suggested that if there is oligohydramnios, compression of the fetal thorax could squeeze out lung liquid. In oligohydramnios due to premature membrane rupture however, the amniotic fluid pressures were found to be below or at the limit of the normal range [12]. As a consequence, it has been proposed that the pulmonary hypoplasia associated with oligohydramnios in premature and prolonged membrane rupture may result from excess loss of lung liquid due to the reduction in amniotic pressure and hence an increase in the alveolar-amniotic pressure gradient [12]. The amniotic fluid pressure in pregnancies in which the oligohydramnios is due to a fetal renal anomaly, however, has not been reported. It has also been suggested that factors other than oligohydramnios may also be responsible for the abnormal lung growth in fetuses with renal anomalies, for example a reduction in proline production by the kidney [13]. In pulmonary hypoplasia associated with oligohydramnios not due to renal agenesis, however, hydroxyproline levels can be high [14]. In addition, pulmonary hypoplasia was only found in infants dying perinatally with urinary tract abnormalities if there had been fetal anuria [14].

### **Diagnosis of pulmonary hypoplasia**

Accurate antenatal and neonatal diagnosis of pulmonary hypoplasia is important to ensure accurate counselling of parents and provision of appropriate management of the patient. Diagnosis of severe pulmonary hypoplasia antenatally means that the parents can be offered the option of pregnancy termination. Parents also need to be aware that infants with pulmonary problems are less likely to do well on a dialysis programme. Data from the North American Paediatric Renal Transplant Cooperative Study demonstrated pulmonary disease and/or hypoplasia was twice as common in the non-survivors [15]. The effect of pulmonary disease on mortality was most pronounced in children younger than three months at dialysis initiation [14].

#### **Antenatal diagnosis**

Analysis of the Northern Congenital Abnormality Survey database regarding fatal outcomes in congenital renal anomalies demonstrated a change in the timing of the pregnancy losses [4]. Since 1995 and the inception of specialised fetal medicine units, more pregnancies were terminated and fewer deaths occurred postnatally, suggesting an increased confidence in antenatal diagnosis. Nevertheless, although many methods of antenatal diagnosis of pulmonary hypoplasia have been investigated, the results are variable. Severe oligohydramnios persisting for more than two weeks is associated with a poor fetal outcome (90% mortality) in pregnancies complicated by premature rupture of the membranes prior to 25 weeks of gestation [16]. Longstanding oligohydramnios in fetuses with renal anomalies is also usually associated with pulmonary insufficiency, but this is not invariable [17]. Ultrasound demonstration of the compression features (extra renal manifestations of Potter's syndrome) that occur in pregnancies complicated by oligohydramnios also can indicate pulmonary hypoplasia. Perinatal lethal renal disease however, can occur without such abnormalities in a twin pregnancy, when the other twin has normal renal function and can maintain sufficient amniotic fluid. This can occur in twin and multifetal gestations sharing amniotic fluid, for example monoamniotic twins [18], but has also rarely been reported in diamniotic twins [19]. The predictive value of the quantity and quality of fetal breathing movements (FBM) to the development of pulmonary hypoplasia has been vigorously disputed, the conflicting results presented probably reflect use of different definitions of FBM [20], different diagnostic criteria for pulmonary hypoplasia and/or failure to control for the many factors which affect FBM [1]. Nevertheless, most data suggest the presence or absence of FBM on an isolated examination does not predict or confirm pulmonary hypoplasia, but the



**Fig 1.** The chest radiograph demonstrates small volume lung fields, a bell shaped thorax and a chest wall that is disproportionately small with respect to the abdomen. Antenatally the infant had findings consistent with lower urinary tract obstruction; a thick walled bladder, bilateral hydronephrosis and increased echogenicity of the renal parenchyma; there was anhydramnios. Postnatally the infant had bilateral talipes, a small chest and a very low functional residual capacity of 9.3 ml/kg (normal range 24-36 ml/kg [23]). The infant died of pulmonary hypoplasia

persistent absence of FBM over several weeks is a poor prognostic sign [21]. Whether, such an association holds true if a fetus has a renal anomaly remains to be tested.

There have been many studies attempting to predict pulmonary hypoplasia by measuring the size of the lungs by ultrasonography. Using two-dimensional ultrasound measurements a variety of reference ranges have been made [22-25]. The measurements made include the thoracic circumference and the lung length and relating the thoracic size to the biparietal diameter, head circumference, abdominal circumference or femur length. Their sensitivity and specificity in predicting pulmonary hypoplasia, however, has been variable [26]. In infants with a congenital diaphragmatic hernia and an intrathoracic liver, the most accurately predictive assessment has been comparison of the lung to head ratio; a ratio of greater than 1.4 being associated with 100% survival, but a ratio of less than 1.0 with 100% mortality [27]. Such measurements are more difficult to make in the presence of oligohydramnios, although ultrasound visualisation can be improved by amnioinfusion to restore amniotic fluid volume [28]. Fetal lung volume assessment by magnetic resonance imaging (MRI) is unlikely to be helpful on a routine basis, because of relatively long acquisition times, high costs and limited acceptance by pregnancy women [1]. In contrast, three-dimensional ultrasonography is fast,

easy and acceptable, but limiting factors to an accurate ultrasound examination include severe obesity and oligohydramnios [29].

### Postnatal diagnosis

Postnatally, pulmonary hypoplasia is suspected in an infant who immediately after birth has severe respiratory insufficiency and requires high ventilatory pressures. The chest radiograph (figure) will demonstrate small volume lung fields with elevated diaphragmatic domes, downward sloping ribs and a bell shaped thorax [30], in addition, the chest wall is disproportionately small with respect to the abdomen. Infants with pulmonary hypoplasia have small non-compliant lungs, thus assessment of the infant's lung volumes using an inert gas dilution technique can give further confirmatory evidence. The true size of the lungs, however, cannot be estimated by such a technique if other lung disease is present.

### Antenatal interventions

Antenatal interventions to try and prevent pulmonary hypoplasia in infants with renal anomalies include relieving the oligohydramnios by amnioinfusion or by bypassing the urinary tract obstruction. In animal models, saline infusion to restore normal amniotic fluid volume after experimental urinary tract obstruction resulted in less hypoplasia of the lungs [7]. In a single case of bilateral renal agenesis, serial amnioinfusion was associated with no pulmonary hypoplasia and fetal compression [31]. Clearly, such an intervention does not influence any renal impairment progression and thus decompression of the renal tract is likely to be more beneficial. Indeed, in a fetal lamb model, in which lower urinary tract obstruction was induced by ligating the urethra and urachus, marsupialisation of the bladder to decompress the kidneys resulted in adequate alveolar development and reduced renal damage [32]. Intrauterine therapy includes vesico-amniotic shunting (placing a pigtail shunt between the fetal bladder and amniotic cavity under ultrasound guidance) and fetal cystoscopy. Review of 169 cases of vesico-amniotic shunting [33], however, demonstrated only 47% perinatal survival and 45% shunt related complications. In the successful cases end stage renal disease occurred in 40% [33] and in another series a high proportion required frequent interventions in childhood [34]. Oligohydramnios present before shunt placement (56% mortality) and failure to restore amniotic fluid volume (100% mortality) were signs of a particularly poor prognosis [33]. An alternative approach has been to undertake laser therapy during fetal cystoscopy to disrupt posterior urethral valves [35], but this may result in damage to nearby bowel. The impact on pulmonary development of neither intervention has been quantitatively evaluated in infants.

### Acknowledgements

Dr Caroline May is supported by the Charles Wolfson Trust. We thank Mrs Deirdre Gibbons for secretarial assistance and Dr Maria Sellars for reviewing the chest radiograph.

### References

- Harrison MR, Nakayama DK, Noall R, de Lorimier AA. Correction of congenital hydronephrosis in utero II. Decompression reverses the effects of obstruction on the fetal lung and urinary tract. *J Pediatr Surg* 1982; 17: 965-74.
- Schwarz RD, Stephens FD, Cussen LJ. The pathogenesis of renal dysplasia. II. The significance of lateral and medial ectopy of the ureteric orifice. *Invest Urol* 1981; 19: 97-100.
- Bain AD, Scott JS. Renal agenesis and severe urinary tract dysplasia: a review of 50 cases, with particular reference to the associated anomalies. *Br Med J* 1960; 5176: 841-6.
- Greenough A, Blott M, Nicolaidis K, Campbell S. Interpretation of fetal breathing movements in oligohydramnios due to membrane rupture. *Lancet* 1988; 1: 182-3.
- Sutherland RS. Diamniotic twin gestation discordant for renal dysplasia and oligohydramnios. *Urology* 1999; 54: 1097.
- Vintzileos AM, Campbell WA, Rodis JF, Nochimson DJ, Pinette MG, Petrikovsky BM. Comparison of six different ultrasonographic methods for predicting lethal fetal pulmonary hypoplasia. *Am J Obstet Gynecol* 1989; 161: 606-12.
- Leonidas JC, Bhan I, Beatty EC. Radiographic chest contour and pulmonary air leaks in oligohydramnios-related pulmonary hypoplasia (Potter's syndrome). *Invest Radiol* 1982; 17: 6-10.
- Schwarz RD, Stephens FD, Cussen LJ. The pathogenesis of renal dysplasia. I. Quantification of hypoplasia and dysplasia. *Invest Urol* 1981; 19: 94-6.
- Wigglesworth JS, Desai R. Is fetal respiratory function a major determinant of perinatal survival? *Lancet* 1982; 1: 264-7.
- Morris S, Akima S, Dahlstrom JE, Ellwood D, Kent A, Falk MC. Renal tubular dysgenesis and neonatal hemochromatosis without pulmonary hypoplasia. *Pediatr Nephrol* 2004; 19: 341-4.
- Thompson PJ, Greenough A, Dykes E, Nicolaidis KH. Impaired respiratory function in infants with anterior abdominal wall defects. *J Pediatr Surg* 1993; 28: 664-6.
- Chan FY, Borzi P, Cincotta R, Burke J, Tudehope D. Limb constriction as a complication of intra-uterine vesico-amniotic shunt: fetoscopic release. *Fetal Diagn Ther* 2002; 17: 315-20.
- Hislop A, Hey E, Reid L. The lungs in congenital bilateral renal agenesis and dysplasia. *Arch Dis Child* 1979; 54: 32-38.
- Laudy JA, Wladimiroff JW. The fetal lung. 2: Pulmonary hypoplasia. *Ultrasound Obstet Gynecol* 2000; 16: 482-94.
- Roberts AB, Goldstein I, Romero R, Hobbins JC. Fetal breathing movements after preterm premature rupture of membranes. *Am J Obstet Gynecol* 1991; 164: 821-5.
- Adzick NS, Harrison MR, Glick PL, Villa RL, Finkbeiner W. Experimental pulmonary hypoplasia and oligohydramnios: relative contributions of lung fluid and fetal breathing movements. *J Pediatr Surg* 1984; 19: 658-65.
- Nakayama DK, Glick PL, Harrison MR, Villa RL, Noall R. Experimental pulmonary hypoplasia due to oligohydramnios and its reversal by relieving thoracic compression. *J Pediatr Surg* 1983; 18: 347-53.
- Schwarz RD, Stephens FD, Cussen LJ. The pathogenesis of renal dysplasia. III. Complete and incomplete urinary obstruction. *Invest Urol* 1981; 19: 101-3.
- Cameron D, Lupton BA, Farquharson D, Hiruki T. Amnioinfusions in renal agenesis. *Obstet Gynecol* 1994; 83: 872-6.
- Lauria MR, Gonik B, Romero R. Pulmonary hypoplasia: pathogenesis, diagnosis, and antenatal prediction. *Obstet Gynecol* 1995; 86: 466-75.
- Cilento BG Jr, Benacerraf BR, Mandell J. Prenatal and postnatal findings in monochorionic, monoamniotic twins discordant for bilateral renal agenesis-dysgenesis (perinatal lethal renal disease). *J Urol* 1994; 151: 1034-5.
- Bahmaie A, Hughes SW, Clark T, et al. Serial fetal lung volume measurement using three-dimensional ultrasound. *Ultrasound Obstet Gynecol* 2000; 16: 154-8.
- Blott M, Greenough A, Nicolaidis KH. Fetal breathing movements in pregnancies complicated by premature membrane rupture in the second trimester. *Early Hum Dev* 1990; 21: 41-8.
- Harrison MR, Ross N, Noall R, de Lorimier AA. Correction of congenital hydronephrosis in utero. I. The model: fetal urethral obstruction produces hydronephrosis and pulmonary hypoplasia in fetal lambs. *J Pediatr Surg* 1983; 18: 247-56.
- Kilbride HW, Yeast J, Thibeault DW. Defining limits of survival: lethal pulmonary hypoplasia after midtrimester premature rupture of membranes. *Am J Obstet Gynecol* 1996; 175: 675-81.
- Wood EG, Hand M, Briscoe DM, Donaldson LA, Yiu V, Harley FL, et al. Risk factors for mortality in infants and young children on dialysis. *Am J Kidney Dis* 2001; 37: 573-9.
- Freedman AL, Johnson MP, Smith CA, Gonzalez R, Evans MI. Long-term outcome in children after antenatal intervention for obstructive uropathies. *Lancet* 1999; 354: 374-7.
- Northern Regional Survey Steering Group. Fetal abnormality: an audit of its recognition and management. *Arch Dis Child* 1992; 67: 770-4.
- Perlman M, Levin M. Fetal pulmonary hypoplasia, anuria, and oligohydramnios: clinicopathologic observations and review of the literature. *Am J Obstet Gynecol* 1974; 118: 1119-23.
- Potter EL. Facial characteristics of infants with bilateral renal agenesis. *Am J Obstet Gynaecol* 1946; 51: 885-8.
- Moretti M, Sibai BM. Maternal and perinatal outcome of expectant management of premature rupture of membranes in the midtrimester. *Am J Obstet Gynecol* 1988; 159: 390-6.
- Bunduki V, Saldanha LB, Sadek L, Miguelez J, Miyadahira S, Zugaib M. Fetal renal biopsies in obstructive uropathy: feasibility and clinical correlations—preliminary results. *Prenat Diagn* 1998; 18: 101-9.
- Quintero RA, Johnson MP, Romero R, Smith C, Arias F, Guevara-Zuloaga F, et al. In-utero percutaneous cystoscopy in the management of fetal lower obstructive uropathy. *Lancet* 1995; 346: 537-40.
- Fisk NM, Ronderos-Dumit D, Soliani A, Nicolini U, Vaughan J, Rodeck CH. Diagnostic and therapeutic transabdominal amnioinfusion in oligohydramnios. *Obstet Gynecol* 1991; 78: 270-8.
- Laudy JA, Van Gucht M, Van Dooren MF, Wladimiroff JW, Tibboel D. Congenital diaphragmatic hernia: an evaluation of the prognostic value of the lung-to-head ratio and other prenatal parameters. *Prenat Diagn* 2003; 23: 634-9.