

BNP in the differential diagnosis of amiodarone-induced pulmonary toxicity: a case report and review of the literature

Marcin Grabowski^{1,2}, Łukasz A. Małek¹, Grzegorz Karpiński¹, Krzysztof J. Filipiak¹, Grzegorz Opolski¹

¹1st Department of Cardiology, Medical University of Warsaw, Poland

²Department of Medical Informatics, Medical University of Warsaw, Poland

Submitted: 30 March 2006

Accepted: 21 April 2006

Arch Med Sci 2006; 2, 2: 131-133

Copyright © 2006 Termedia & Banach

Corresponding author:

Marcin Grabowski, MD

1st Department of Cardiology

Medical University of Warsaw

Central University Hospital

Banacha 1a

02-097 Warsaw, Poland

Phone +48 22 599 19 58

Fax +48 22 599 19 57

E-mail:

marcin.grabowski@amwaw.edu.pl

Abstract

A 70-year old man with a history of surgically treated lung cancer, ST-elevation myocardial infarction treated with primary angioplasty, congestive heart failure, and on treatment with amiodarone was admitted to the intensive care unit due to exacerbation of dyspnea. We propose a differential diagnosis of acute congestive heart failure and amiodarone-induced pulmonary toxicity with the use of B-type natriuretic peptide (BNP) plasma concentration analysis. The case report is followed by a literature review.

Key words: amiodarone, adverse reactions, natriuretic peptide, differential diagnosis.

Case report

A 70-year old man was admitted to the intensive care unit due to exacerbation of chronic dyspnea recently at rest. Two years earlier the patient underwent ST-elevation anterior wall myocardial infarction treated with primary angioplasty of the left descending coronary artery with stent implantation. Myocardial infarction was complicated by early ventricular fibrillation, acute heart failure and paroxysmal atrial fibrillation. Echocardiography at that time revealed ejection fraction of 22%. During hospitalization the patient was diagnosed with upper left pulmonary lobe tumor which was treated successfully with surgery 3 months later. Prior to lobectomy elective balloon angioplasty of significant stenosis in the right coronary artery was performed. Since the myocardial infarction the patient has been treated with amiodarone.

Currently on admission the patient was at generally poor condition, cyanotic, short-of-breath at rest, without peripheral edemas, heart rate regular 70 beats per minute and no signs of congestions over the lungs with diffuse crepitations on auscultation. On electrocardiogram: sinus rhythm, left anterior fascicular block, dextrogyria and signs of right ventricular overload. Chest X-ray revealed no evident congestion but signs of pulmonary fibrosis (Figure 1) were disclosed on high resolution computed tomography scans (Figure 2). Biochemical tests and morphology were normal. B-type natriuretic peptide (BNP) level was 81 pg/ml (normal range 0-100 pg/ml). Echocardiography showed advanced pulmonary hypertension and ejection fraction of 50%. Plethysmography showed decreased total lung capacity of 53%.

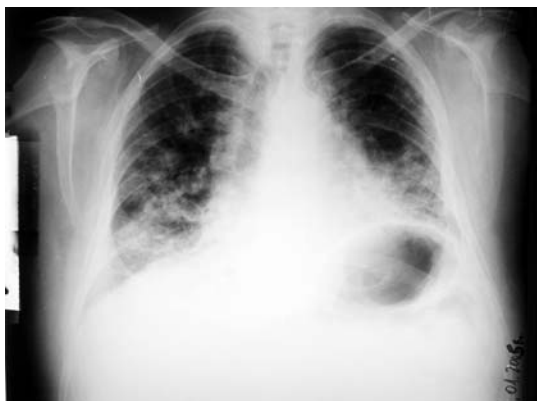

Figure 1. Admission chest X-ray. Status after partial resection of the left lung. Diffused ground-glass opacities in middle and inferior lung sections characteristic of pulmonary fibrosis. A small amount of fluid in the left thoracic cavity

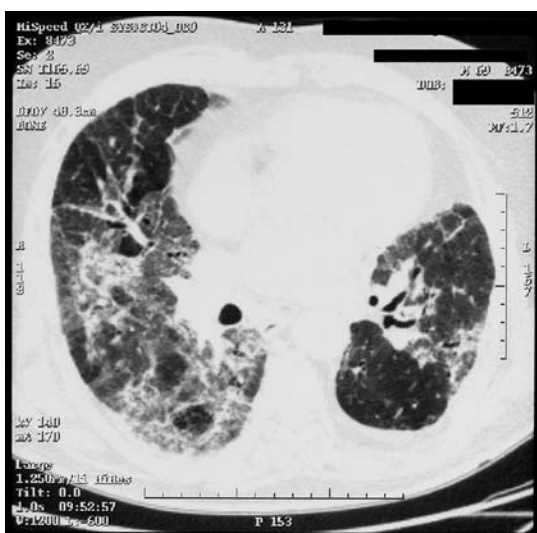


Figure 2. High resolution chest computed tomography (HRCT). Status after partial resection of the left lung. Bilateral interstitial and alveolar opacifications with high-attenuating pleural-parenchymal consolidations and bronchial dilatations characteristic of pulmonary fibrosis

Taking in consideration the clinical picture and examination results we made a diagnosis of amiodarone-induced pulmonary toxicity. Amiodarone was stopped and prednisolone with an initial dose of 45 mg per day was administered with improvement of the general condition and dyspnea.

Discussion

To our knowledge, our study is the first report of BNP analysis application into the differential diagnosis of amiodarone-induced pulmonary toxicity. Exacerbation of heart failure remains the main alternative diagnosis in this group of patients often presenting new or worsened dyspnea. BNP is a well established and valuable diagnostic

marker of heart failure and improves evaluation of acute dyspnea as presented in the Breathing Not Properly Study [1]. According to the recently published algorithm in patients presenting with acute shortness of breath serum NT-proBNP concentrations <300 pg/ml exclude the diagnosis of acute CHF with a negative predictive value of 98% [2]. Amiodarone treatment associated with a progressive decrease in serum brain natriuretic peptide was previously described as a marker of drug effectiveness and favorable prognosis but it was never used in the differential diagnosis of adverse reaction to this drug [3, 4]. Presence of clinical symptoms in the patient with inconsistent radiographic image and lack of white blood cell count elevation make the diagnosis of pulmonary toxicity difficult [5]. That is why decline in total lung capacity coexisting with serum concentrations of BNP within a normal range (<100 pg/ml) or lack of BNP elevation compared to previous assessments in a patient with normal LVEF and signs of pulmonary hypertension on echocardiography leads towards a diagnosis of amiodarone-induced lung disease.

Several previously published studies addressed the problem of thoracic and non-thoracic surgery as risk factors of amiodarone toxicity [6, 7]. Most of them reported a high incidence of acute respiratory distress syndrome in patients treated with amiodarone in prophylaxis of postoperative atrial fibrillation. None of them presented a case with the late onset of pulmonary toxicity. We cannot exclude that this is a casual finding, but lobe resection may limit the pulmonary reserve making those patients more susceptible to the future development of pulmonary toxicity. Only one prospective, randomized, placebo-controlled trial of 519 patients with congestive heart failure compared the velocity of diffusion capacity loss among patients with chronic obstructive pulmonary disease receiving amiodarone or placebo, finding no statistical differences [8]. Studies on amiodarone administration in patients after thoracic operations are needed and till we know their results amiodarone therapy in this group of patients should be monitored more carefully.

Amiodarone cessation with the following corticosteroid therapy proved to be an effective treatment of pulmonary toxicity as demonstrated by the symptoms withdrawal and positive clinical examinations results [9].

In the end indications for amiodarone treatment in cardiovascular patients should be considered more carefully, especially regarding the results of the large The Sudden Cardiac Death in Heart Failure Trial (SCD-HeFT) trial which seriously doubted amiodarone positive influence on survival in patients with congestive heart failure [10].

References

1. McCullough PA, Nowak RM, McCord J, Hollander JE, Herrmann HC, Steg PG, et al. B-type natriuretic peptide and clinical judgment in emergency diagnosis of heart failure: analysis from Breathing Not Properly (BNP) Multinational Study. *Circulation* 2002; 106: 416-22.
2. Januzzi JL Jr, Camargo CA, Anwaruddin S, Baggish AL, Chen AA, Krauser DG, et al. The N-terminal Pro-BNP investigation of dyspnea in the emergency department (PRIDE) study. *Am J Cardiol* 2005; 95: 948-54.
3. Shiga T, Hosaka F, Wakaumi M, Matsuda N, Tanizaki K, Kajimoto K, et al. Amiodarone decreases plasma brain natriuretic peptide level in patients with heart failure and ventricular tachyarrhythmia. *Cardiovasc Drugs Ther* 2003; 17: 325-33.
4. Takemura K, Yasumura Y, Hirooka K, Hanatani A, Nakatani S, Komamura K, et al. Low-dose amiodarone for patients with advanced heart failure who are intolerant of beta-blockers. *Circ J* 2002; 66: 441-4.
5. Martin WJ, Rosenow EC. Amiodarone pulmonary toxicity. Recognition and pathogenesis (Part I). *Chest* 1988; 93: 1067-75.
6. Van Mieghem W, Coolen L, Malysse I, Lacquet LM, Deneffe GJ, Demedts MG. Amiodarone and the development of ARDS after lung surgery. *Chest* 1994; 105: 1642-5.
7. Ashrafian H, Davey P. Is amiodarone an underrecognized cause of acute respiratory failure in the ICU? *Chest* 2001; 120: 275-82.
8. Singh SN, Fisher SG, Deedwania PC, Rohatgi P, Singh BN, Fletcher RD. Pulmonary effect of amiodarone in patients with heart failure. The Congestive Heart Failure-Survival Trial of Antiarrhythmic Therapy (CHF-STAT) Investigators (Veterans Affairs Cooperative Study No. 320). *J Am Coll Cardiol* 1997; 30: 514-7.
9. Ott MC, Khoo A, Leventhal JP, Paterick TE, Burger CD. Pulmonary toxicity in patients receiving low-dose amiodarone. *Chest* 2003; 123: 646-51.
10. Bardy GH, Lee KL, Mark DB, Poole JE, Packer DL, Boineau R, et al.; Sudden Cardiac Death in Heart Failure Trial (SCD-HeFT) Investigators. Amiodarone or an implantable cardioverter-defibrillator for congestive heart failure. *N Engl J Med* 2005; 352: 225-37.