

# Cholinesterase inhibitors for Parkinson's disease-related visual hallucinations unresponsive to atypical antipsychotics

Tomasz Sobow

Department of Old Age Psychiatry and Psychotic Disorders,  
Medical University of Lodz, Poland

**Submitted:** 22 August 2006

**Accepted:** 25 February 2007

Arch Med Sci 2007; 3, 1: 69-72

Copyright © 2007 Termedia & Banach

**Corresponding author:**

Tomasz Sobow, MD, PhD  
Department of Old Age Psychiatry  
and Psychotic Disorders  
Medical University of Lodz  
Central Teaching Hospital  
Czechoslowacka 8/10  
92-216 Lodz, Poland  
E-mail: tmsobow@csk.umed.lodz.pl

## Abstract

**Introduction:** Considering lack of accepted guideline in cases of Parkinson's disease-related visual hallucinations with poor response or intolerance to antipsychotics, and their possible cholinergic pathogenesis, the trial with cholinesterase inhibitors seems to be legitimated.

**Material and methods:** Five patients with PD (with or without dementia) complicated by VH and unresponsive to atypical antipsychotics were offered a 12-week, open-label trial of a cholinesterase inhibitor.

**Results:** All 5 subjects completed the trial with no major adverse effects and, noteworthy, no discontinuations due to adverse events. VH resolved in 4 subjects and were markedly diminished in one person. Neither changes in UPDRS scores nor exaggeration of subjective complaints about extrapyramidal symptoms were noted during treatment.

**Conclusions:** Cholinesterase inhibitors, rivastigmine or donepezil, might represent a useful alternative to antipsychotics for patients with PD accompanied by VH even in the absence of dementia.

**Key words:** cholinesterase inhibitors, rivastigmine, donepezil, Parkinson's disease, hallucinations, clinical trial, open label.

## Introduction

Psychotic symptoms in Parkinson's disease (PD) are relatively frequent and their treatment is problematic. A recommended partial discontinuation of anti-parkinsonian drugs is commonly ineffective while the use of antipsychotics (including atypicals) bears substantial risk of motor functions worsening. Moreover, many psychotic PD patients are also cognitively impaired, which makes drug interventions even more challenging [1].

Cholinergic deficiency in PD-dementia (PDD), as well as in pathologically related dementia with Lewy bodies (DLB), has been shown to be even greater than in Alzheimer's disease, for which cholinesterase inhibitors (ChEI) are standard first-line treatment [2]. In several controlled studies, ChEI have been successfully used in PDD patients [3, 4] and there is some preliminary evidence that patients with psychotic symptoms (particularly visual hallucinations) might respond even better than those without [5]. Finally, there are several case reports showing that psychotic symptoms in PD (with or without dementia) as well as in DLB may be ameliorated with donepezil or rivastigmine [6-9]. Despite these encouraging reports the use of cholinesterase inhibitors for neuropsychiatric complications in PD (and

PDD) remains controversial and it is not clear whether a clear clinically significant effect in addition to statistically significant differences really exists.

Here we report the successful use of rivastigmine or donepezil in 5 patients with visual hallucinations in PD clinically unresponsive to atypical antipsychotics.

## Material and methods

Five patients (4 men, mean age  $79 \pm 2.2$  years) evaluated at the Outpatient Unit of the Department of Old Age Psychiatry and Psychotic Disorders with long-standing Parkinson's disease (with or without dementia) accompanied by visual hallucinations (VH) previously unresponsive to atypical antipsychotics were offered a trial of cholinesterase inhibitor, rivastigmine (4 patients) or donepezil (1 patient). All patients were diagnosed clinically by at least one consultant neurologist and in accordance with the Parkinson's Disease Society Brain Bank criteria for Parkinson's disease. Motor dysfunction was assessed with a motor subscale of the Unified Parkinson's Disease Rating Scale (UPDRS, maximum of 64 points, the more points the worse the patient's status) and global disease severity with Hoehn-Yahr staging system (range of score 1 to 5, 5 being the most advanced stage). Cognitive status was screened with the Mini Mental State Examination (MMSE, maximum of 30 points, the fewer points the worse the patient's status) and dementia was diagnosed according to the ICD-10 criteria for dementia in Parkinson's disease. Delirium was excluded as a possible cause of hallucinations in all subjects. VH were evaluated using item 2 (hallucinations) of the Neuropsychiatric Inventory (NPI); both severity (0 to 3 points scale) and frequency (0 to 4 points scale) were assessed and the

arithmetic product (severity times frequency scores; VH-NPI) calculated. Patients were considered unresponsive to antipsychotic treatments when either they experienced intolerable side effects (most notably worsening of parkinsonism in the case of haloperidol, sulpiride, risperidon and olanzapine; sedation and falls in the case of olanzapine, haloperidol, thioridazine and quetiapine) or no clinically meaningful improvement was observed despite at least 4 weeks of well-tolerable dose (all cases treated with clozapine or quetiapine). Detailed clinical characteristics of patients are provided in the Table I.

Rivastigmine was prescribed at an initial dose of 3 mg per day (in two doses) and donepezil of 5 mg per day (bedtime). Dose escalation (after at least two weeks of treatment) was possible after phone or personal contact with patients and/or their caregivers to, respectively, 6 and 10 mg per day. Patients were clinically evaluated after 6 and 12 weeks for the presence of hallucinations and, additionally, changes in UPDRS, MMSE and VH-NPI as well as any adverse events (including their possible relationship to ChEI treatment) emerging during the trial.

## Results

All subjects completed the trial and no adverse events-related discontinuations occurred. General tolerability of ChEI treatment in our patients was good and there were no discontinuations due to adverse events. One patient (treated with rivastigmine) experienced nausea and appetite loss that resolved after 2 weeks without intervention. The patient on donepezil experienced headaches that responded to low doses of paracetamol and ceased after 3-4 weeks

**Table I.** Baseline demographic and clinical characteristics of 5 patients treated

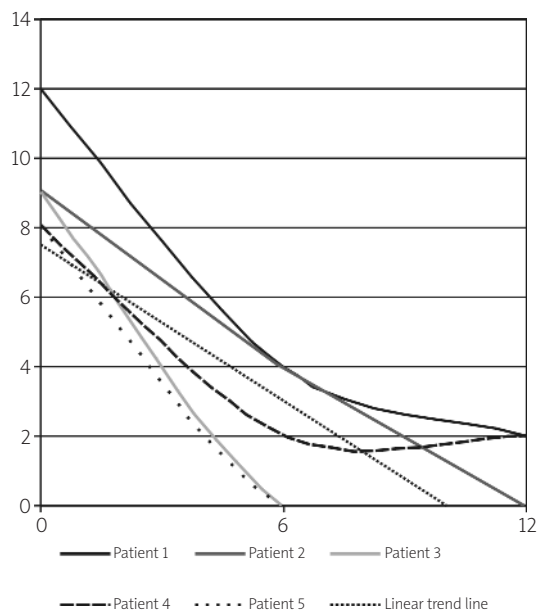
N	Patients' age and gender	Disease duration (years)	Hoehn-Yahr stage of PD	UPDRS (motor subscale) score	MMSE score	Previous antipsychotic treatments (max dose used in mg)	VH-NPI hallucination item score (frequency times severity)
1	76, male	8	3	20	21	Olanzapine (5), quetiapine (200), clozapine (75)	12
2	77, female	8	4	26	26	Risperidone (2), clozapine (37,5)	9
3	82, male	12	4	29	28	Sulpiride (250), quetiapine (150)	9
4	74, male	9	3	19	20	Olanzapine (5), clozapine (62,5)	8
5	86, male	16	3	22	19	Haloperidol (2), thioridazine (125), quetiapine (225)	8
Mean values:							
	age $79 \pm 2.2$	$8.6 \pm 1$	N/A	$23.2 \pm 2$	$22.8 \pm 2$	N/A	$9.2 \pm 0.7$

of treatment. Interestingly, doses of ChEI used were low in comparison to those used in Alzheimer's disease treatment (5 mg/day in the case of donepezil and 3 (3 patients) to 6 (1 patient) mg/day in the case of rivastigmine).

After 6 weeks of treatment VH resolved completely in 2 subjects (1 on rivastigmine and 1 on donepezil), usually within the first 2 weeks of trial, and in 3 patients (on rivastigmine) VH persisted but their frequency and/or severity were markedly diminished as measured by change in VH-NPI (mean VH-NPI score  $2.0 \pm 0.9$  versus  $9.2 \pm 0.7$  at baseline, Wilcoxon matched-pairs sign rank test,  $p=0.06$ ). After an additional 6 weeks VH resolved in two further subjects while in one patient they persisted but were transient and appeared only at dawn (mean VH-NPI score at 12 weeks  $0.8 \pm 0.5$  versus  $9.2 \pm 0.7$  at baseline, Wilcoxon matched-pairs sign rank test,  $p=0.06$ ; for individual changes in VH-NPI scores over time see chart). In 3 subjects complete discontinuation of antipsychotics was possible, while in two others (patients 1 and 4) 6.25 and 12.5 mg of clozapine daily was enough to control symptoms. Neither changes in UPDRS scores nor exaggeration of subjective complaints about extrapyramidal symptoms were noted during treatment (mean score at 12 weeks  $22.4 \pm 2.1$  as compared to  $23.2 \pm 1.9$  at baseline, not significant, Wilcoxon matched-pairs sign rank test,  $p=0.25$ ). MMSE scores tended to be higher at the end of the trial than at baseline ( $23.8 \pm 1.4$  versus  $22.8 \pm 1.9$ , not significant, Wilcoxon matched-pairs sign rank test,  $p=0.2$ ).

## Discussion

Previous studies, including randomized trials in demented patients with DLB and PD, have rather consistently shown that cholinesterase inhibitors are effective in alleviating psychotic symptoms (mainly visual hallucinations) in those problematic subjects [3, 10]. Here, we have shown that ChEI might also be helpful in hallucinating PD subjects even in the absence of dementia. Not only did patients respond clinically but also antipsychotic drugs could be discontinued or their doses markedly reduced. Moreover, no extrapyramidal symptoms exaggeration was observed and general tolerability of ChEI, as measured by treatment-emergent adverse effects profile, was good. Interestingly, very low to low doses of ChEI were sufficient in all cases, which quite naturally might have resulted in a very good tolerability. It must be noted, however, that no worsening in movement could have also been observed due to discontinuation of previous antipsychotic treatments. However, this seems to be rather unlikely since in all cases the last neuroleptic used (quetiapine or clozapine) has itself very low EPS risk. These observations then seem to be clinically important since antipsychotics (both



**Figure.** Individual trajectories of response to treatment. Weeks of treatment (axis X), NPI-VH scores (axis Y). Note marked improvement during first 6 weeks (in all subjects) and additional benefit of treatment continuation during next 12 weeks (in the majority of subjects).

classical neuroleptics and atypicals) are often badly tolerated in patients with PD and might be hazardous (due to putatively increased risk of stroke) in demented elderly patients. ChEI might be an interesting alternative or, particularly taking into account a possible pathogenesis of visual hallucinations in PD, even drugs of choice in both demented and non-demented PD subjects with VH [1, 2]. The use of low doses of ChEI and waiting patiently for their clinical effectiveness might be helpful in avoiding non-tolerance, including gastrointestinal symptoms (in the study of Emre et al. [3] nearly 1 in 7 patients vomited) and extrapyramidal symptoms worsening.

## Conclusions

Cautious use of ChEI in cases of VH in the course of PD unresponsive to antipsychotics (including atypicals) might be an interesting alternative treatment of these patients, even in the absence of dementia.

## References

- Weintraub D, Stern MB. Psychiatric complications in Parkinson disease. *Am J Geriatr Psychiatry* 2005; 13: 844-51.
- Bohnen NI, Kaufer DI, Ivancic LS, et al. Cortical cholinergic function is more severely affected in parkinsonian dementia than in Alzheimer disease: an in vivo positron emission tomographic study. *Arch Neurol* 2003; 60: 1745-8.
- Emre M, Aarsland D, Albanese A, et al. Rivastigmine for dementia associated with Parkinson's disease. *N Engl J Med* 2004; 351: 2509-18.

4. Maidment I, Fox C, Boustani M. Cholinesterase inhibitors for Parkinson's disease dementia. *Cochrane Database Syst Rev* 2006; (1): CD004747.
5. Reading PJ, Luce AK, McKeith IG. Rivastigmine in the treatment of parkinsonian psychosis and cognitive impairment: preliminary findings from an open trial. *Mov Disord* 2001; 16: 1171-4.
6. Bergman J, Lerner V. Successful use of donepezil for the treatment of psychotic symptoms in patients with Parkinson's disease. *Clin Neuropharmacol* 2002; 25: 107-10.
7. Bullock R, Cameron A. Rivastigmine for the treatment of dementia and visual hallucinations associated with Parkinson's disease: a case series. *Curr Med Res Opin* 2002; 18: 258-64.
8. Kurita A, Ochiai Y, Kono Y, Suzuki M, Inoue K. The beneficial effect of donepezil on visual hallucinations in three patients with Parkinson's disease. *J Geriatr Psychiatry Neurol* 2003; 16: 184-8.
9. Rovers JM, Dautzenberg PL, ter Brugge JP. Rivastigmine als ondersteuning bij het dilemma van de behandeling van hallucinaties optredend bij ziekte van Parkinson. *Tijdschr Gerontol Geriatr*. 2006; 37: 117-20.
10. Simard M, van Reekum R. The acetylcholinesterase inhibitors for treatment of cognitive and behavioral symptoms in dementia with Lewy bodies. *J Neuropsychiatry Clin Neurosci* 2004; 16(4): 409-25.