

Necrobiosis lipidica and cutaneous anaesthesia: immunohistochemical study of neural fibres

Angel Fernandez-Flores

The Service of Anatomic Pathology, Hospital El Bierzo, and the Service of Cellular Pathology, Clinica Ponferrada. Ponferrada, Spain

Folia Neuropathol 2008; 46 (2): 154-157

Abstract

Background: Cutaneous anaesthesia in necrobiosis lipidica (NL) has been attributed to the destruction of nerve fibres by the inflammatory process. In the 1980s, one study demonstrated a decrease in S100 positive neural fibres as proof of this. Thermalgic information is mainly dependent on small fibres, either myelinated or unmyelinated, and S100 protein is expressed by Schwann cells.

Objective: We designed an immunohistochemical study with anti-neurofilament and peripherin in 5 cases of NL, in order to investigate if there was a decrease of axons in NL.

Methods: We reviewed 5 cases of NL and performed an immunohistochemical study on all of them, with neurofilaments and peripherin antibody in sections of 4 µm.

Slides were examined under a conventional light microscope, and we searched for the presence of fibres in the necrobiotic areas, as well as in the periphery of the necrobiotic areas. Controls for both markers were also used.

Results: The median number of nerve fibres in the control biopsies was 5.2 per mm². The nerve fibres were absent in the central part of the necrotic foci, and only scattered fibres were evidenced in the periphery of the foci. Myelinated nerve trunks seemed to be hypertrophied in the areas located between the necrotic foci.

Conclusions: The absence of nerve fibres in the central areas of the necrotic foci of NL might explain the anaesthesia which is present in many patients with that disease.

Key words: Necrobiosis lipidica, A-delta fibres, C-fibres, small nerve fibres.

Introduction

Cutaneous anaesthesia is a common characteristic of NL. It was attributed to the destruction of nerve fibres by the inflammatory process, and a decrease in S100 positive neural fibres was presented as proof of this [1].

Nevertheless, we know nowadays that thermalgic information is mainly dependent on small fibres, either

myelinated or unmyelinated. S100 protein is expressed by Schwann cells [2], and therefore it is not the best option to evaluate the unmyelinated fibres, in which one Schwann cell is shared by several axons. Even a significant decrease in axons would not necessarily equal a decrease in Schwann cells, and conversely, a decrease in Schwann cells would not necessarily equal a decrease in axons.

Communicating author:

Angel Fernandez-Flores, MD, PhD, S. Patología Celular, Clinica Ponferrada, Avenida Galicia 1, 24400 Ponferrada, Spain, tel.: +34 987 42 37 32, fax: +34 987 42 91 02, Email: gpyauflowerlion@terra.es

Table I. Clinical details of patients

Case	Age	Gender	Diabetes	Time since diagnosis of diabetes	Location of lesions	Time since the first lesions appeared	Other details of interest
1	84	male	type 2	12 years	chest, forehead and right arm	3 months	alcoholic hepatopathy, multinodular goiter
2	68	female	type 1	14 years	right leg	36 months	–
3	19	female	type 1	11 years	right leg	24 months	–
4	35	male	type 1	15 years	both legs	24 months	–
5	78	female	type 2	unknown	both calves	12 months	dementia

We designed an immunohistochemical study with anti-neurofilament and peripherin, in 5 cases of NL, in order to investigate if there was a decrease of axons in cutaneous lesions.

Materials and Methods

We reviewed 5 cases of NL from our archives, and performed an immunohistochemical study on all of them, with neurofilaments (DakoCytomation neurofilament protein, mouse anti-human, clone 2F11, code N1591) in all of them. We also immunostained with peripherin antibody (Novocastra IgG2b mouse polyclonal antibody, clone PJM50). For that, sections of 4 µm were obtained from paraffin-embedded tissue.

Slides were examined under a conventional light microscope, and we searched for the presence of fibres in the necrobiotic areas, as well as in the periphery of the necrobiotic areas. We used a micrometer in order to count the number of positive fibres per mm². In the control biopsies, 10 dermal fields of 1 mm² were selected, and the immunopositive sections of nerve fibres were counted. The average number of nerve fibres per mm² in the dermis of control biopsies was obtained by calculating the median of all the cases.

We used four controls of both markers, two skin biopsies randomly selected (one from the breast, and one from the concha). They were supposed to be used in the comparative study of the count of nerve fibres with the necrotic areas, which eventually was not needed as seen later on.

Results

The median number of nerve fibres in the control biopsies was 5.2 per mm².

The ages, genders and other relevant clinical aspects of the patients are shown in Table I.

At first view, myelinated nerve trunks seemed to be hypertrophied in the areas located between the necrotic foci, while nerve fibres seemed to be absent in the necrotic areas (Fig. 1). With a closer inspection at a higher resolution, three main characteristics were evident. First, the nerve fibres were difficult to find in the necrotic areas, and they seemed to be totally absent in the central part of the necrotic foci. Second, some scattered necrotic fibres could be seen in the peripheral part of the necrotic foci. Third, the number of fibres was preserved in the inflammatory area surrounding the necrotic foci (Fig. 3). Due to the total absence of fibres in the central areas of the foci, the comparison with the dermal nerve density of the controls was not needed.

Discussion

Cutaneous anaesthesia is a common characteristic of necrobiosis lipoidica (NL) [1,3].

In 1988, a pioneer study with immunohistochemistry demonstrated that S100 positive cutaneous nerves were fewer in the skin lesions of NL [1]. Since then, many reports and classical textbooks have assumed that the destruction of the nerve fibres was the main mechanism in the pathogenesis of the anaesthesia in NL. There are nevertheless several paradoxes concerning this subject. In the first place, anaesthesia is not present in all lesions of NL, and they can even be very painful in up to 25% of cases. On the other hand, anaesthesia is a characteristic of many areas of diabetic patients (with or without NL), due to peripheral neuropathy [4]. Moreover we know nowadays that thermalgic information is mainly carried by A-delta fibres and C-fibres [5]. Although A-delta fibres are myelinated, C fibres are unmyelinated. Paradoxically,

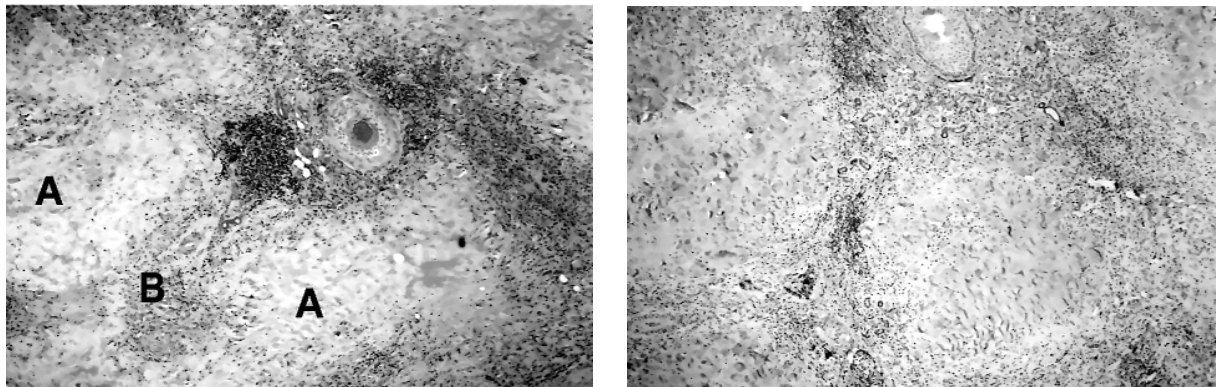


Fig. 1. The images show necrobiotic foci (A), stained with haematoxylin-eosin (left) as well as immunostained for neurofilaments (right). At this magnification, nerve trunks can only be evidenced at the internecrotic areas, and they present a hypertrophied aspect (B)

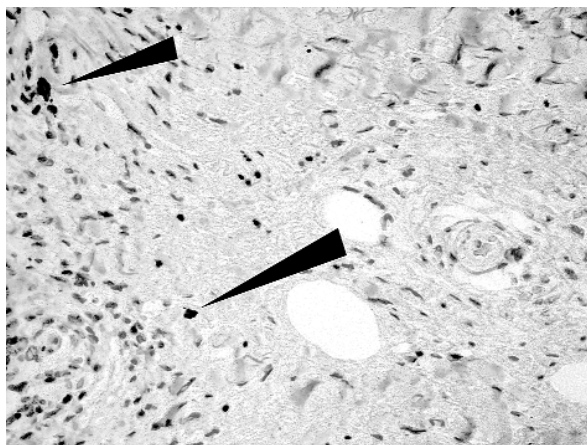


Fig. 2. At the periphery of the necrobiotic foci, some scattered fibres were evident (immunostaining for peripherin)

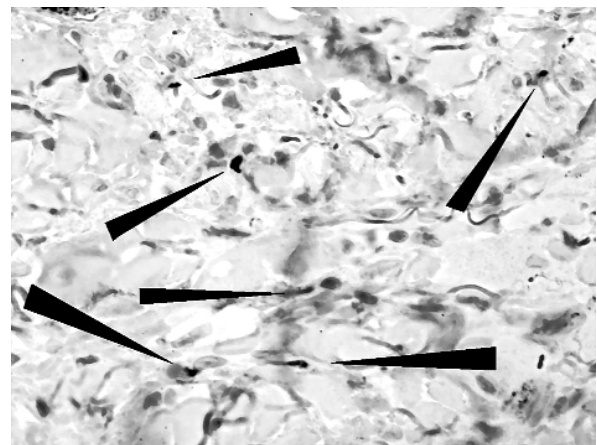


Fig. 3. In the inflammatory areas outside the necrobiotic foci, the fibres were easily evidenced, in comparison to the total absence in the necrobiotic foci

S100 protein is expressed by Schwann cells [2], and therefore it is not the best option to evaluate the unmyelinated fibres, in which one Schwann cell is shared by several axons. Even a significant decrease in axons would not necessarily equal a decrease in Schwann cells, and conversely, a decrease in Schwann cells would not necessarily equal a decrease in axons. Moreover, type 2 diabetes has been associated with an increase in denervated Schwann cells in animals [6], a fact that would not be detected by S-100 antibody.

Evaluation of the nerve fibre density in skin biopsy is becoming more usual as a test which is contributory to the diagnosis of many neuropathies [7-9]. Some reports have shown a correlation between a decrease in nerve fibre density and sensory loss [10].

In our study, we used antibodies against neurofilament which, since they are expressed by neural fibres, are more reliable in the evaluation of fibre density than S100 antibody. We also used antibodies against peripherin, which recognises a type of neurofilament mainly present in the peripheral nervous system. Studies with antibodies against neurofilaments have been demonstrated by some groups to be perfectly valid for quantification of nerve fibre density [11]. Nevertheless, it should be mentioned that most groups are using the anti-protein-gene-product 9.5 (PGP 9.5) in these types of quantification studies [5,9,12].

Although some groups have defended the use of thick sections (up to 50 μm) [9], thinner sections have also been shown to be valid [12].

The quantification of the nerve fibres by using a regular light microscope, independent of image analysis systems, has been shown to be perfectly reliable and statistically acceptable [13].

We must stress the fact that we evaluated the positive dots of sections of nerve fibres. That means that if the same fibre was sectioned three times on its way up to the epidermis, it would have been counted three times in our study, in spite of being the same fibre. On the other hand, some mathematical models have been used to calculate the real number of axons per mm² once a count with immunohistochemistry has been done [12]. The number of *intraepidermal* axons according to those formulae has been estimated at around 291 per mm² [12]. The much lower number of positive dermal nerves in our control cases is not only due to the evaluation of *dermal* nerves instead of epidermal, but also due to the thinner sections that we used (4 µm).

Our study demonstrates that there seems to be a gradient of nerve fibre density from the centre of the necrotic foci (with no fibres) to the surrounding inflammatory tissue (with preservation of the fibres). Apparently, it could be hypothesized then that following the necrosis, nerve fibre destruction might be the reason for the anaesthesia of some patients with NL. We wonder if there might be any relationship between the apparent hypertrophy of the nerve trunks that was evidenced between the necrotic foci, and the pain that a significant percentage of patients with NL can feel.

References

1. Boulton AJ, Cutfield RG, Abouganem D, Angus E, Flynn HW, Skyler JS, Penneys NS. Necrobiosis lipoidica diabetorum: a clinicopathologic study. *J Am Acad Dermatol* 1988; 18: 530-537.
2. Chien HF, Tseng TJ, Lin WM, Yang CC, Chang YC, Chen RC, Hsieh ST. Quantitative pathology of cutaneous nerve terminal degeneration in the human skin. *Acta Neuropathol (Berl)* 2001; 102: 455-461.
3. Hoitsma E, Reulen JPH, de Baets M, Drent M, Spaans F, Faber CG. Small fiber neuropathy: a common and important clinical disorder. *J Neurol Sci* 2004; 227: 119-130.
4. Kamiya H, Murakawa Y, Zhang W, Sima AAF. Unmyelinated fiber sensory neuropathy differs in type 1 and type 2 diabetes. *Diabetes Metab Res Rev* 2005; 21: 448-458.
5. Koskinen M, Hietaharju A, Kyläniemi M, Peltola J, Rantala I, Udd B, Haapasalo H. A quantitative method for the assessment of intraepidermal nerve fibers in small-fiber neuropathy. *J Neurol* 2005; 252: 789-794.
6. Lauria G, Borgna M, Morbin M, Lombardi R, Mazzoleni G, Sghirlanzoni A, Pareyson D. Tubule and neurofilament immunoreactivity in human hairy skin: markers for intraepithelial nerve fibers. *Muscle Nerve* 2004; 30: 310-316.
7. Lauria G, Cornblath DR, Johansson O, McArthur JC, Mellgren SI, Nolano M. EFNS guidelines on the use of skin biopsy in the diagnosis of peripheral neuropathy. *Eur J Neurol* 2005; 12: 747-758.
8. Mann RJ, Harman RR. Cutaneous anesthesia in necrobiosis lipoidica. *Br J Dermatol* 1984; 110: 323-325.
9. Singer W, Spies JM, MacArthur J, Low J, Griffin JW, Nickander KK, Gordon V, Low PA. Prospective evaluation of somatic and autonomic small fibers in selected autonomic neuropathies. *Neurology* 2004; 62: 612-618.
10. Tillman TK, Graves JW. 65-year-old woman with painful leg ulcers. *Mayo Clin Pro* 2002; 77: 965-968.
11. Vanstapel M-J, Gatter KC, de Wolf-Peeters C, Mason DY, Desmet VD. New sites of human S-100 immunoreactivity detected with monoclonal antibodies. *Am J Clin Pathol* 1986; 85: 160-168.
12. Walk D, Wendelschafer-Crabb G, Davey C, Kennedy WR. Concordance between epidermal nerve fiber density and sensory examination in patients with symptoms of idiopathic small fiber neuropathy. *J Neurol Sci* 2007; 255: 23-26.
13. Winkler AS, Ejskjaer N, Edmons M, Watkins PJ. Dissociated sensory loss in diabetic autonomic neuropathy. *Diabet Med* 2000; 17: 457-462.