

# Complications of severe cerebral amyloid angiopathy in the course of dementia with Lewy bodies. A case report

Tadeusz Mendel<sup>1</sup>, Ewa Bertrand<sup>2</sup>, Grażyna M. Szpak<sup>2</sup>, Tomasz Stępień<sup>2</sup>, Teresa Wierzba-Bobrowicz<sup>2</sup>

<sup>1</sup>Second Department of Neurology, Institute of Psychiatry and Neurology, Warsaw, Poland, <sup>2</sup>Department of Neuropathology, Institute of Psychiatry and Neurology, Warsaw, Poland

*Folia Neuropathol* 2010; 48 (4): 293-299

## Abstract

A 68-year-old male who suffered from dementia, progressing for four months without Parkinson's symptoms, was admitted to the Department of Neurology because of vertigo, slight left hand paresis and positive Romberg test. During hospitalization the patient's status deteriorated. The intracerebral lobar haemorrhage, subarachnoid haemorrhage and ischaemic lesions observed on CT scans suggested the clinical diagnosis of CAA. He died after 53 days due to pneumonia. On macroscopic examination, the brain showed general cortical atrophy and ventricular dilatation. Frontal lobar haemorrhage and focal subarachnoid haemorrhage were seen on the brain autopsy. Microscopic observation demonstrated neuronal loss and microspangiosis in the hippocampus, severe neuronal loss and depigmentation in the substantia nigra pars compacta and locus coeruleus. Lewy bodies were visible in the substantia nigra and amyloid angiopathy, predominantly severe CAA according to the Vonsattel scale, in the meningeal and cortical vessels. In the presented case, the microscopic findings were typical for DLB with concomitant severe CAA. In progressive dementia, neurological deterioration, presence of lobar hemorrhagic infarcts and ischaemic lesions suggest CAA coexistent with DLB and/or AD.

**Key words:** cerebral amyloid angiopathy, dementia with Lewy bodies, intracerebral haemorrhage.

## Introduction

Cerebral amyloid angiopathy (CAA) is a progressive degenerative process of leptomeningeal and brain parenchymal vessels caused by accumulation of amyloid deposits in their walls [3,30,39,45].

Amyloid deposition is a prominent feature of numerous brain disorders, in which amyloid fibrils are found in blood vessel walls, the neuropil and neurons. These include Alzheimer's disease (AD), neurologically asymptomatic amyloidosis, Parkinson dementia of

Guam, dementia with Lewy bodies (DLB), hereditary cerebral haemorrhage with amyloidosis of Dutch origin (HCHWA-D), hereditary cerebral haemorrhage with amyloidosis of Icelandic origin (HCHWA-I), AD changes associated with Down's syndrome (DS) and sporadic cerebral amyloid angiopathy [1,7,11,12,18,19,41,48].

CAA has a fundamental aspect of many pathologies leading to dementia. Brain lobar haemorrhage and/or necrosis are common in this condition, but focal subarachnoid haemorrhage is rare [26].

## Communicating author:

Tadeusz Mendel MD, PhD, Second Department of Neurology, Institute of Psychiatry and Neurology, ul. Sobieskiego 9, 02-957 Warsaw, Poland, phone +48 22 458 28 27, e-mail: mendel@ipin.edu.pl

Deposits of  $\beta$ -amyloid, the fibrillogenic product of the cell surface protein A $\beta$ PP (amyloid- $\beta$  protein precursor), occur in the cerebral cortex of patients with DLB [5,25,49]. Amyloid deposits occur in the common form, which is defined by changes consistent with diffuse Lewy body (DLBc) disease accompanied by AD, and also in a pure form (DLBp), in which neurofibrillary tangles are absent [4].

The number of publications on this subject is very limited [24,49].

The aim of this study was to analyse morphological changes in a patient with DLB co-existing with CAA and multiple changes, such as hemorrhagic infarct, subarachnoid haemorrhage and ischaemic cerebral lesions.

### Case report

A 68-year-old male who suffered from dementia progressing for four months, without Parkinson's symptoms, was admitted to the Department of Neurology. He was treated with risperidone and donepezil. On admission he showed vertigo, slight left hand paresis, central left facial nerve paresis and liability of his Romberg test. During previous months he had two episodes of transient ischaemic attacks, manifested by left hemiparesis with left facial nerve central paresis and decreased consciousness. During hospitalization the patient's status suddenly deteriorated, he lost consciousness and quadriparesis was observed. CT scan revealed hemorrhagic infarct in the right frontal lobe, superficial haematoma on the surface of the frontal lobe, subarachnoid haemorrhage and multiple ischaemic lesions. Angio-CT and angiog-

raphy showed no abnormality. EEG showed no pathological discharges. The intracerebral haemorrhage, subarachnoid haemorrhage and ischaemic lesions observed on CT scans suggested the clinical diagnosis of CAA. He died after 53 days due to pneumonia.

### Methods

The brain autopsy material was fixed in 4% paraformaldehyde in 0.1 M phosphate-buffer saline and embedded in paraffin. The specimens were stained with H&E, PAS, Congo red, Klüver-Barrera methods and immunohistochemically with the following antibodies: neurofilaments (NFTs, Novocastra, 1 : 50), tau (DAKO, 1 : 200),  $\beta$ -amyloid 40 (A $\beta$  40) (Serotec, 1 : 250),  $\beta$ -amyloid (A $\beta$  42) (Serotec 1 : 250) and  $\alpha$ -synuclein (Novocastra, 1 : 30). The grade of CAA was assessed according to Vonsattel [46]. The type and grade of DLB were classified according to Consortium [34].

### Results

On macroscopic examination, the brain showed general cortical atrophy and ventricular dilatation. Frontal lobar haemorrhage and focal subarachnoid haemorrhage were seen on the brain autopsy (Fig. 1). We observed slight paleness of the substantia nigra in the mesencephalon.

Microscopic observation demonstrated neuronal loss and microspangiosis in the hippocampus, and severe neuronal loss and depigmentation in the substantia nigra pars compacta and locus coeruleus. Lewy bodies were visible in the substantia nigra (Fig. 2).

Neuronal loss and  $\alpha$ -synuclein-positive Lewy bodies (LBs) and Lewy neurites were observed in the

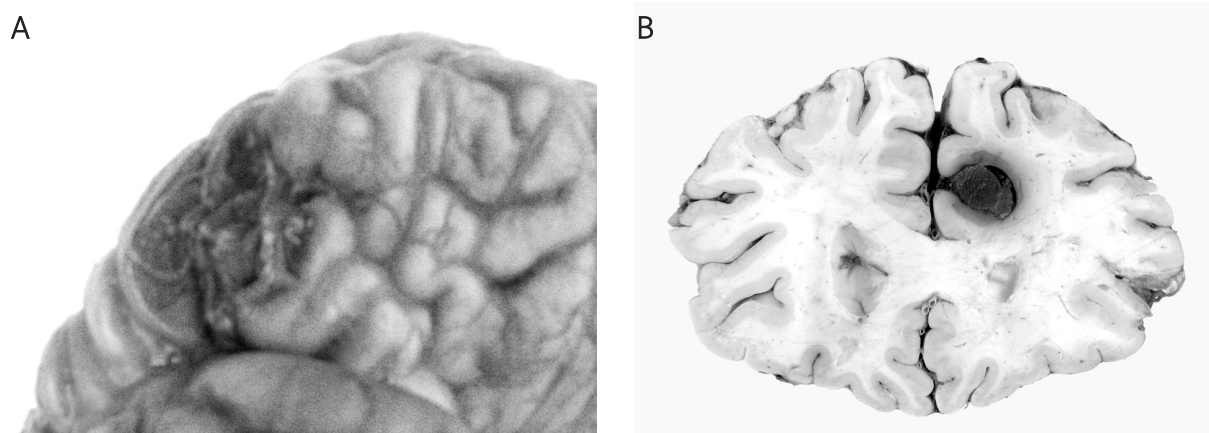


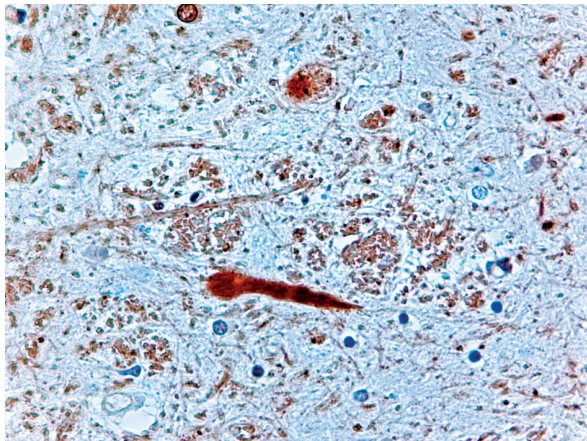
Fig. 1. Frontal lobe. Macroscopic examination. A) Focal subarachnoid hemorrhage. B) The lobar hemorrhage.



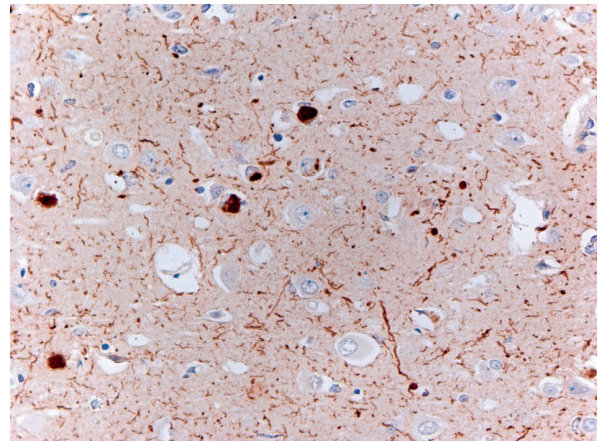
brainstem and in the temporal lobe, particularly in the entorhinal cortex (Fig. 3). The presence of amyloid plaques consistent with AD pathology was revealed.

Numerous amyloid plaques were visible in the temporal lobe (Fig. 4A). Neurofibrillary tangles in the temporal lobe, particularly in the entorhinal cortex, were observed (Fig. 4B). Amyloid angiopathy, predominantly severe CAA according to the Vonsattel scale,

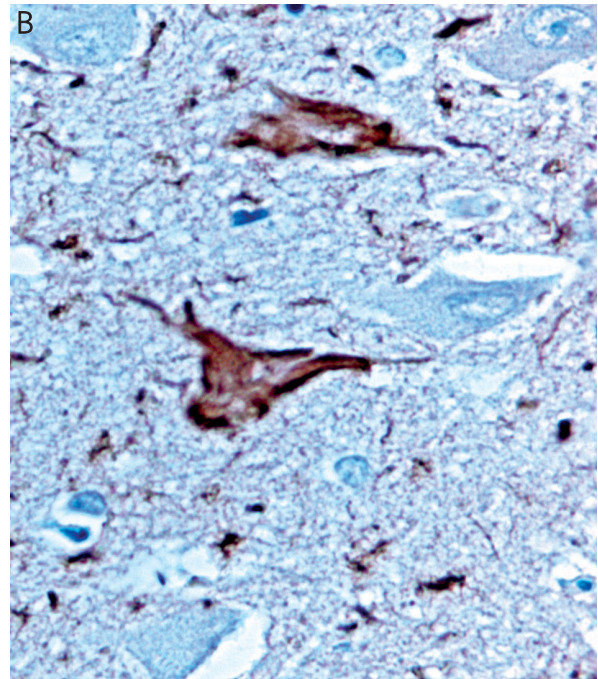
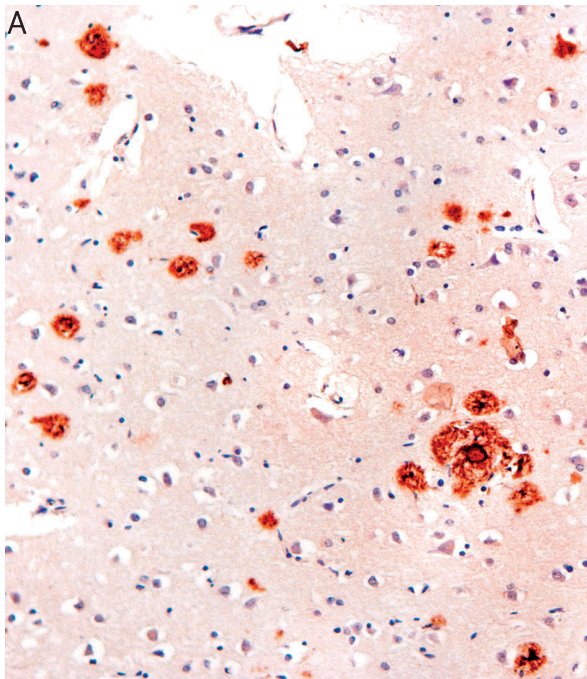
were found in the meningeal and cortical vessels (Fig. 5A). A characteristic picture of severe cerebral amyloid angiopathy, named "double barrel", could be observed using Congo red staining (Fig. 5B). Many other different ischaemic and hemorrhagic changes with different time of onset were revealed in the patient's brain. Disperse microinfarcts in the neocortex and in the white matter as a complication of



**Fig. 2.** Lewy bodies in the substantia nigra.  $\alpha$ -synuclein.  $\times 200$ .



**Fig. 3.** Temporal lobe. Lewy bodies and Lewy neurites.  $\alpha$ -synuclein.  $\times 100$ .



**Fig. 4.** Temporal lobe. **A)** Amyloid plaques  $\times 200$ .  $\beta$ -amyloid 42.  $\times 200$ . **B)** Neurofibrillary tangles. Tau-protein.  $\times 400$ .



severe CAA were observed (Fig. 6). In addition, lobar infarct in the temporal lobe (Fig. 7) and frontal lobar hemorrhagic infarct in the cortico-subcortical region were revealed (Fig. 8). Amyloid overloaded meningeal vessels at the border of the hemorrhagic lobar infarct (Fig. 9) and amyloid overloaded cortical vessels at the border of the brain pale infarct area were observed (Fig. 10).

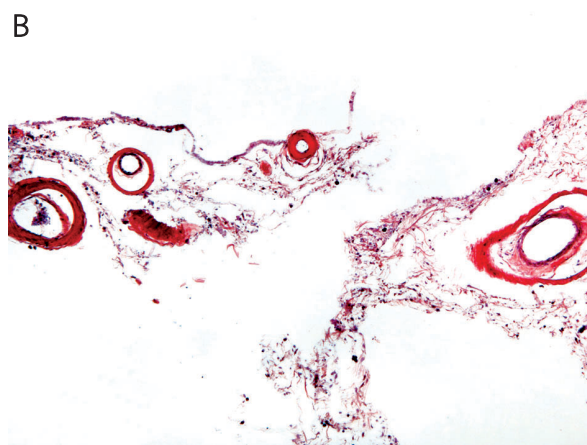
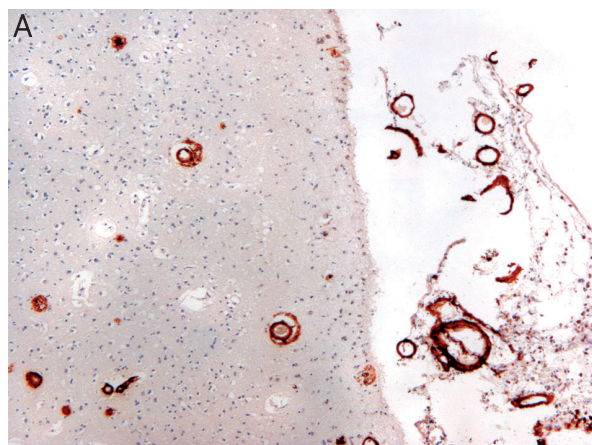
## Discussion

Dementia with Lewy bodies represents the second largest neuropathological subgroup of neurodegenerative dementia after Alzheimer's disease in the elderly [6,34]. A 30.5% prevalence of DLB is registered

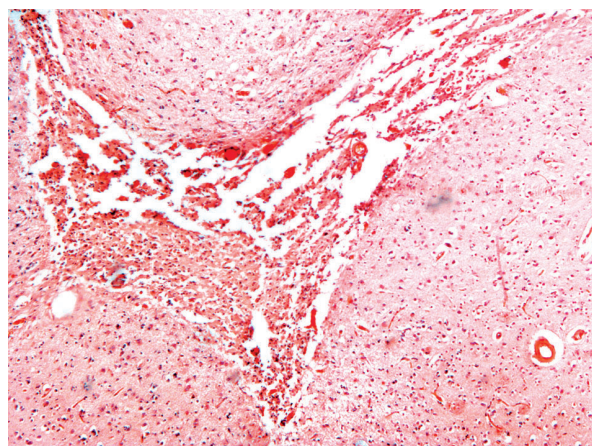
among dementia patients, whereas its annual incidence in the general population is 0.1% [36,50].

Although most patients have sporadic DLB, a small number of DLB families have been described, suggesting that genetic factors may contribute to DLB pathogenesis [8].

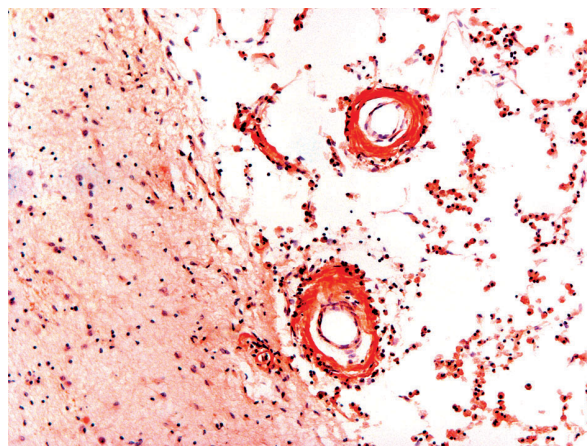
DLB patients present progressive dementia, recurrent visual hallucinations and parkinsonism. Features suggestive for DLB are REM sleep disorder, severe neuroleptic sensitivity and low dopamine reuptake in basal ganglia upon functional imaging. Repeated falls, transient loss of consciousness, severe autonomic dysfunction and depression can confirm a clinical diagnosis of DLB [13,21,34]. Clinically, only progressive dementia and decreased consciousness



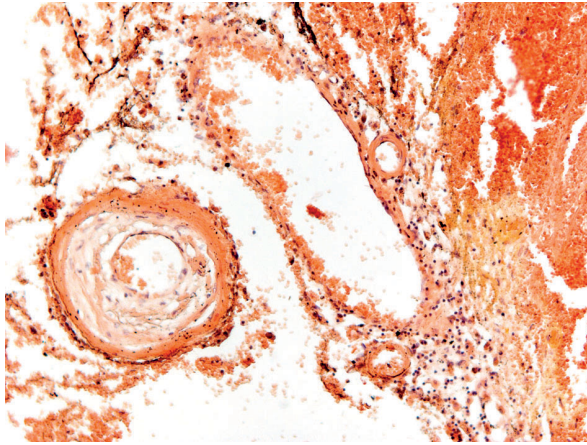
**Fig. 5. A)** Amyloid angiopathy in the meningeal and cortical vessels.  $\beta$ -amyloid 40.  $\times 100$ . **B)** Various stages of arterial CAA severity with "double barrel". Congo red.  $\times 200$ .



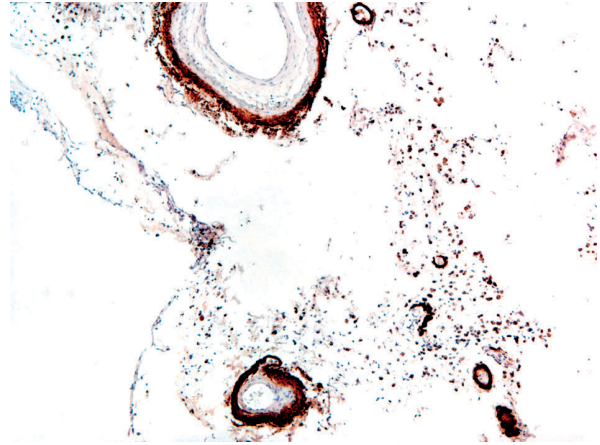
**Fig. 6.** Temporal lobe. Pale microinfarct in the white matter. Congo red.  $\times 100$ .



**Fig. 7.** Temporal lobe. CAA in area of infarct in stage of advanced resorption. Congo red.  $\times 100$ .



**Fig. 8.** Frontal lobe. CAA in the hemorrhagic infarct. Van Gieson.  $\times 100$ .



**Fig. 9.** Amyloid overloaded meningeal vessels in the border of hemorrhagic lobar infarct.  $\beta$ -amyloid 40.  $\times 100$ .

were observed in our patient. Neuropathologically, DLB is classified into three types, brainstem-predominant, limbic (transitional) and neocortical (also known as diffuse Lewy body disease), depending on the distribution and density of Lewy bodies (LB) [27,34].

In the literature the most frequently used terms are “diffuse Lewy body disease” (DLBD), “Lewy body variant of Alzheimer’s disease” (LBV) and “senile dementia of Lewy body type” (SDLT). These terms are interchangeable [22,28,29].

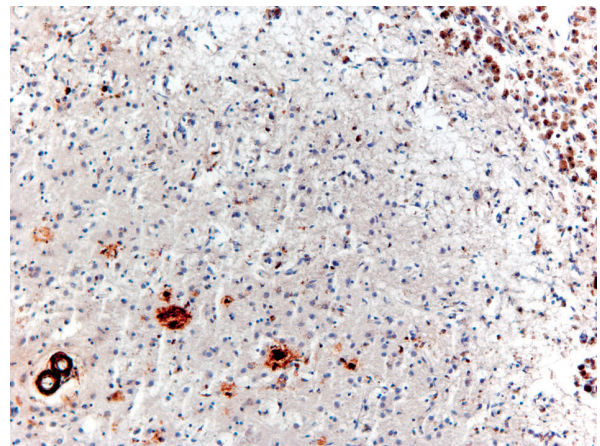
DLB with no AD changes is known as the pure form of DLB (DLBp), whereas DLB associated with AD is recognized as the common form of DLB (DLBc). However, none of the 201 autopsies in the CERAD study showed Lewy bodies without concomitant AD changes [22].

Little is known about the aetiology of DLB. DLB is generally a sporadic disorder, and is considered to be a complex disorder, resulting from the interaction between genetic and environmental risk factors. Most studies have reported DLB as autosomal dominant, rarely as a recessive trait [10,15,37,44,47].

Molecular genetic studies have identified several mutations associated with DLB, suggesting a large genetic heterogeneity in the development of DLB.

The  $\epsilon$  allele of the apolipoprotein E gene (APOE) is the major genetic risk factor for AD and also can be a risk factor for DLB [2,5,8,14,38,40].

Parkinson disease (PD) and DLB are characterized by the presence of intracytoplasmic neuronal inclusions called Lewy bodies (LBs) and  $\alpha$ -synuclein-



**Fig. 10.** Temporal lobe. Amyloid overloaded cortical vessels in the border of the brain pale infarct area.  $\beta$ -amyloid 40.  $\times 100$ .

containing aberrant neurites in the substantia nigra pars compacta, locus coeruleus and other selected nuclei of the brain stem, and also in several nuclei of the basal forebrain and hippocampus [6,20,23, 24,31,38,40]. DLB is also characterized by a widespread distribution of LBs and  $\alpha$ -synuclein-containing neurites in the cerebral cortex [20,22,35]. Amyloid plaques and neurofibrillary tangles are frequent in DLB [16,22,32-34,42,43].

Alzheimer’s disease is an amyloidopathy in view of the central role of  $\beta$ -amyloid accumulation, but it also shares features of tauopathy because of its neurofibrillary tangles, which are composed of hyperphosphorylated tau protein. Diseases including PD, DLB and multiple system atrophy (MSA), which exhib-



it  $\alpha$ -synuclein lesions, are termed “synucleinopathies” [9,17,42,43].

The relationships between DLB, PD and AD are complex and incompletely understood. Genetic studies indicate that DLB cases tend to share many risk factors for AD [22,25].

Many elderly demented patients with Lewy body pathology have autopsy findings which are compatible with a diagnosis of DLB or can be interpreted as “AD with incidental Lewy bodies” or “Parkinson’s dementia”.

The final diagnosis of DLB in our patient was made postmortem on the basis of typical histological changes in association with progressive intellectual decline and decreased consciousness as a clinical manifestation of the disease. Focal subarachnoid haemorrhage and superficial and hemorrhagic lobar as well as ischaemic cerebral lesions were seen on the brain autopsy.

In the presented case, the microscopic findings were typical of DLB with concomitant severe CAA. Severe CAA is a cause of many pathologies, such as intracerebral haemorrhage and focal subarachnoid haemorrhage or brain ischaemic changes, leading to fatal outcome. Our patient met the criteria of the common form of dementia with Lewy bodies, due to the presence of numerous Lewy bodies in the brain stem and cortex.

In cases of progressive dementia, neurological deterioration, presence of lobar hemorrhagic infarcts and ischaemic lesions suggest the coexistence of CAA with DLB and/or AD.

## References

1. Armstrong RA. Spatial correlations between  $\beta$ -amyloid (A $\beta$ ) deposits and blood vessels in familial Alzheimer’s disease. *Folia Neuropathol* 2008; 46: 241-248.
2. Arai H, Higuchi S, Muramatsu T, Iwatsubo T, Sasaki H, Trojanowski JQ. Apolipoprotein E gene in diffuse Lewy body disease with or without co-existing Alzheimer’s disease. *Lancet* 1994; 344: 1307.
3. Attems J. Sporadic cerebral amyloid angiopathy: pathology, clinical implications, and possible pathomechanisms. *Acta Neuropathol* 2005; 110: 345-359.
4. Barrachina M, Dalfo E, Puig B, Vidal N, Freixes M, Castano E, Ferrer I. Amyloid- $\beta$  deposition in the cerebral cortex in Dementia with Lewy bodies is accompanied by a relative increase in A $\beta$ PP mRNA isoforms containing the Kunitz protease inhibitor. *Neurochem Inter* 2005; 46: 253-260.
5. Benjamin R, Leake A, Edwardson JA, McKeith IG, Ince PG, Perry RH, Morris CM. Apolipoprotein E genes in Lewy body and Parkinson’s disease. *Lancet* 1994; 343: 1565.
6. Bertrand E, Lechowicz W, Szpak GM, Lewandowska E, Dymecki J, Wierzba-Bobrowicz T. Limbic neuropathology in idiopathic Parkinson’s disease with concomitant dementia. *Folia Neuropathol* 2004; 42: 141-150.
7. Bertrand E, Lewandowska E, Stępień T, Szpak GM, Pasennik E, Modzelewska J. Amyloid angiopathy in idiopathic Parkinson’s disease. Immunohistochemical and ultrastructural study. *Folia Neuropathol* 2008; 46: 255-270.
8. Bogaerts V, Engalborghs S, Kumar-Singh S, Goossens D, Pickut B, van der Zee J, Slegers K, Peeters K, Martin J-J, Del-Favero J, Gasser T, Dickson DW, Wszolek ZK, De Deyn PP, Theuns J, van Broeckhoven Ch. A novel locus for dementia with Lewy bodies: a clinically and genetically heterogeneous disorder. *Brain* 2007; 130: 2277-2291.
9. Burn DJ. Cortical Lewy body disease. *J Neurol Neurosurg Psychiatry* 2004; 75: 175-178.
10. Denson MA, Wszolek ZK, Pfeiffer RF, Wszolek EK, Paschall TM, McComb RD. Familial parkinsonism, dementia, and Lewy body disease: study of family G. *Ann Neurol* 1997; 42: 638-643.
11. Donahue JE, Khurana JS, Adelman LS. Intracerebral hemorrhage in two patients with Down’s syndrome and cerebral amyloid angiopathy. *Acta Neuropathol* 1998; 95: 213-216.
12. Ellis RJ, Olichney JM, Thal LJ, Mirra SS, Morris JC, Beekly D, Heyman A. Cerebral amyloid angiopathy in the brains of patients with Alzheimer’s disease: The CERAD experience, part XV. *Neurology* 1996; 46: 1592-1596.
13. Frank C. Dementia with Lewy bodies. Review of diagnosis and pharmacologic management. *CPF* 2003; 49: 1304-1311.
14. Galasko D, Saitoh T, Xia Y, Thal LJ, Katzman R, Hill LR, Hansen L. The apolipoprotein E allele  $\epsilon$ 4 is overrepresented in patients with the Lewy body variant of Alzheimer’s disease. *Neurology* 1994; 44: 1950-1951.
15. Galvin JE, Lee SL, Perry A, Havlioglu N, McKeel DW, Jr, Morris JC. Familial dementia with Lewy bodies: clinicopathologic analysis of two kindreds. *Neurology* 2002; 59: 1079-1082.
16. Gibb WR, Esiri MM, Lees AJ. Clinical and pathological features of diffuse cortical Lewy body disease (Lewy body dementia). *Brain* 1987; 110: 1131-1153.
17. Hashimoto M, Masliah E. Alpha-synuclein in Lewy body disease and Alzheimer’s disease. *Brain Pathol* 1999; 9: 707-720.
18. Head E, Lott IT. Down syndrome and beta-amyloid deposition. *Curr Opin Neurol* 2004; 17: 95-100.
19. Heyman A, Fillenbaum GG, Gearing M, Mirra SS, Welsh-Bohmer KA, Peterson B, Pieper C. Comparison of Lewy body variant of Alzheimer’s disease. Consortium to establish a registry for Alzheimer’s disease, Part XIX. *Neurology* 1999; 52: 1839-1844.
20. Hurting HU, Trojanowski JQ, Galvin J, Ewbank D, Schmidt ML, Lee VMY, Clark CM, Glosser G, Stern MB, Gollomp SM, Arnold SE. Alpha-synuclein cortical Lewy bodies correlate with dementia in Parkinson’s disease. *Neurology* 2000; 54: 1916-1921.
21. Imamura T, Hirono N, Hashimoto M, Shimomura T, Tanimukai S, Kazui H, Hanihara T, Mori E. Clinical diagnosis of dementia with Lewy bodies in a Japanese Dementia Registry. *Dement Geriatr Cogn Disord* 1999; 10: 210-216.
22. Ince PG, Perry EK, Morris CM. Dementia with Lewy bodies. A distinct non-Alzheimer dementia syndrome? *Brain Pathol* 1998; 8: 299-324.

23. Jellinger KA. Disturbance of the nigro-amygdaloid connections in dementia with Lewy bodies. *J Neurol Sci* 2002; 193: 157-158.
24. Jellinger KA, Attems J. Cerebral amyloid angiopathy in Lewy body disease. *J Neurol Transm* 2008; 115: 473-482.
25. Jellinger KA, Attems J. Prevalence and impact of vascular and Alzheimer pathologies in Lewy body disease. *Acta Neuropathol* 2008; 115: 427-436.
26. Katoh M, Yoshino M, Asaoka K, Aoki T, Imamura H, Kashiwazaki D, Takano K, Aida T. A restricted subarachnoid hemorrhage in the cortical sulcus in cerebral amyloid angiopathy: could it be a warning sign? *Surg Neurol* 2007; 68: 457-460.
27. Kosaka K, Yoshimura M, Ikeda K, Budka H. Diffuse type of Lewy body disease: progressive dementia with abundant cortical Lewy bodies and single changes of waring degree – A new disease? *Clinical Neuropathol* 1984; 3: 185-192.
28. Kosaka K. Diffuse Lewy body disease in Japan. *J Neurol* 1990; 237: 197-204.
29. Kövari E, Horvath J, Bouros C. Neuropathology of Lewy bodies disorders. *Brain Res Bull* 2009; 80: 203-210.
30. Kumar-Singh S. Cerebral amyloid angiopathy: pathogenetic mechanisms and link to dense amyloid plaques. *Genes Brain Behavior* 2008; 7 (Suppl 1): 67-82.
31. Lashley T, Holton JL, Gray E, Kirkham K, O'Sullivan SS, Hilbing A, Wood NW, Lees AJ, Revesz T. Cortical  $\alpha$ -synuclein load is associated with amyloid- $\beta$  plaque burden in a subset of Parkinson's disease patients. *Acta Neuropathol* 2008; 115: 417-425.
32. Lippa CF, Smith TW, Swearer JM. Alzheimer's disease and Lewy body disease: a comparative clinicopathological study. *Ann Neurol* 1994; 35: 81-88.
33. Love S. Neuropathological investigation of dementia: A guide for neurologists. *J Neurol Neurosurg Psychiatry* 2005; 76 (Suppl V): 8-14.
34. McKeith IG, Dickson DW, Lowe J, Emre M, O'Brien JT, Feldman H, Cummings J, Duda JE, Lippa C, Perry EK, Aarsland D, Arai H, Ballard CG, Boeve B, Burn DJ, Costa D, Del Ser T, Dubois B, Galasko D, Gauthier S, Goetz CG, Gomes-Tortosa E, Halliday G, Hansen LA, Hardy J, Iwatsubo T, Kalaria RN, Kaufer D, Kenny RA, Korczyn A, Kosaka K, Lee VMY, Lees A, Litvan I, Londo E, Lopez OL, Minoshima S, Mizuno Y, Molina JA, Mukaetova-Ladinska EB, Pasquier F, Perry RH, Schulz JB, Trojanowski JQ, Yamada M, for the Consortium on DLB. Diagnosis and management of dementia with Lewy bodies. Third report of the DLB consortium. *Neurology* 2005; 65: 1863-1872.
35. McKeith I, Mintzer J, Aarsland D, Burn D, Chiu H, Cohen-Mansfield J, Dickson D, Dubois B, Duda JE, Feldman H, Gauthier S, Halliday G, Lawor B, Lippa C, Lopez OL, Machado JC, O'Brien J, Playfer J, Reid W. Dementia with Lewy bodies. *Lancet Neurol* 2004; 3: 19-28.
36. Miech RA, Breitner JC, Zandi PP, Khachaturian AS, Anthony JC, Mayer L. Incidence of AD may decline in the early 90s for men, later for women: The Cache County Study. *Neurology* 2002; 58: 209-218.
37. Ohara K, Takauchi S, Kakai M, Morimura Y, Nakajima T, Morita Y. Familial dementia with Lewy bodies. *Clin Neuropathol* 1999; 18: 232-239.
38. Olichney JM, Hansen LA, Galasko D, Saitoh T, Hofstetter CR, Katzman R, Thal LJ. The apolipoprotein E 4 allele is associated with increased neuritic plaques and cerebral amyloid angiopathy in Alzheimer's disease and Lewy bodies variant. *Neurology* 1996; 47: 190-196.
39. Rensink AA, de Waal RM, Kremer B, Verbeek MM. Pathogenesis of cerebral amyloid angiopathy. *Brain Res Rev* 2003; 43: 207-223.
40. Rosenberg CK, Cummings TJ, Saunders AM, Widico C, McIntyre LM, Hulette CM. Dementia with Lewy bodies and Alzheimer's disease. *Acta Neuropathol* 2001; 102: 621-626.
41. Styczyńska M, Strosznajder JB, Religa D, Chodakowska-Żebrowska M, Pfeiffer A, Gabryelewicz T, Czapski GA, Kobryś M, Karciauskas G, Barcikowska M. Association between genetic and environmental factors and the risk of Alzheimer's disease. *Folia Neuropathol* 2008; 46: 249-254.
42. Szpak GM, Lewandowska E, Lechowicz W, Bertrand E, Wierzbobrowicz T, Gwiazda E, Pasennik E, Kosno-Kruszewska E, Lipczyńska-Łojkowska W, Bocheńska A, Fiszler U. Lewy body variant of Alzheimer's disease and Alzheimer's disease: a comparative immunohistochemical study. *Folia Neuropathol* 2001; 39: 63-71.
43. Szpak GM, Lechowicz W, Lewandowska E, Bertrand E, Wierzbobrowicz T, Gwiazda E, Schmidt-Sidor B, Dymecki J. Neurones and microglia in central nervous system immune response to degenerative processes. Part I: Alzheimer's disease and Lewy body variant of Alzheimer's disease. Quantitative study. *Folia Neuropathol* 2001; 39: 181-192.
44. Tsuang DW, Dalan A, Eugenio CJ, Poorkaj P, Limprasert P, La Spada AR, Steinbart EJ, Bird TD, Leverenz JB. Familial dementia with Lewy bodies. A clinical and neuropathological study of 2 families. *Arch Neurol* 2002; 59: 1622-1630.
45. Vinters HV. Cerebral amyloid angiopathy. A critical review. *Stroke* 1987; 18: 311-324.
46. Vonsattel JPG, Myers RH, Hedley-Whyte ET, Ropper AH, Bird ED, Richardson EP. Cerebral amyloid angiopathy without and with cerebral hemorrhages: A comparative histological study. *Ann Neurol* 1991; 30: 637-649.
47. Waters CH, Miller CA. Autosomal dominant Lewy body parkinsonism in a four-generation family. *Ann Neurol* 1994; 35: 59-64.
48. Wisniewski KE, Wisniewski HM, Wen GY. Occurrence of neuropathological changes and dementia of Alzheimer's disease in Down's syndrome. *Ann Neurol* 1985; 17: 278-282.
49. Wu E, Lipton RB, Dickson DW. Amyloid angiopathy in diffuse Lewy body disease. *Neurology* 1992; 42: 2131-2135.
50. Zaccai J, McCracken C, Brayne C. A systematic review of prevalence and incidence studies of dementia with Lewy bodies. *Age Ageing* 2005; 34: 561-566.