

Prenatal exposure of diclofenac sodium affects morphology but not axon number of the median nerve of rats

Ebru Ayranci¹, Berrin Zuhale Altunkaynak¹, Abit Aktaş², Murat Ç. Rağbetli³, Suleyman Kaplan¹

¹Department of Histology and Embryology, Medical Faculty, Ondokuz Mayıs University, Samsun, Turkey, ²Departments of Histology and Embryology, School of Veterinary, Istanbul University, Istanbul, Turkey, ³Departments of Histology and Embryology, Medical Faculty, Yüzüncü Yıl University, Van, Turkey

Folia Neuropathol 2013; 51 (1): 76-86

DOI: 10.5114/fn.2013.34199

Abstract

The present study examined the effect of DS exposure on median nerve development in rats during prenatal life. Pregnant female rats were divided into three groups: a control group, a saline group and a DS group. Offspring of these animals were divided into 2 subgroups: 4 weeks old and 20 weeks old. Nerve samples were taken from the right legs and evaluated using stereological techniques in terms of the axon number, axon cross-sectional area, and myelin thickness. No drug-dependent macroscopic abnormality was observed in the nerve. No differences were noted for axon number in the control, saline, and DS groups of the same age and gender. No gender difference was found for axon number or axon area between the other matched groups. In conclusion, prenatal exposure to diclofenac sodium does not affect axon number in rats, but can alter the morphology of the male and female median nerve.

Key words: diclofenac sodium, prenatal, stereology, 2D disector, median nerve, rat.

Introduction

Nonsteroidal anti-inflammatory drugs (NSAIDs) are commonly used for alleviation of pain, inflammation, and fever although they may have several side effects, such as gastrointestinal damage and platelet dysfunction [8,20]. One known mechanism by which NSAIDs decrease inflammatory pain is inhibition of the cyclooxygenase pathway, which results in reduction in the local production of arachidonic acid metabolites. A desensitization of nociceptors caused by lowered release of prostaglandins is then seen in the inflamed region [1]. One NSAID, diclofenac sodium (DS), decreases availability of intracellular arachidonic acid, thereby reducing the production of leukotrienes by cells that participate in the inflammatory process [7,20]. On the other hand, DS also suppresses sodium currents in a dose-

dependent manner. The analgesic activity of DS therefore arises by inhibition of cyclooxygenase but also by inhibition of sodium currents in the neurons [13,26]. In addition, DS has proved useful for the prevention of myocardial infarction and stroke, probably through its inhibition of platelet aggregation [3,23].

NSAID drugs, although effective, have a restricted usage due to foetal side effects that include constriction of the ductus arteriosus, renal dysfunction, oligohydramnios, and neonatal complications, which are particularly observed after prolonged therapy [2,15]. These drugs can cause serious side effects to the gastrointestinal tract. Long-term NSAID therapy usually induces clinically silent enteropathy that is characterized by increased intestinal permeability and inflammation. NSAIDs can also induce small bowel ulcers that infrequently lead to acute bleeding, perforation, or chronic

Communicating author:

Suleyman Kaplan, Dept. of Histology and Embryology, Ondokuz Mayıs University School of Medicine, TR-55139 Samsun, Turkey, phone/fax: +90 362 312 19 19, ext. 2265, e-mail: skaplan@omu.edu.tr

scarring responsible for diaphragm-like strictures. At the colon and rectum, NSAID usage can result in *de novo* lesions such as nonspecific colitis and rectitis, ulcers, and diaphragm-like structures [25]. During NSAID treatment 10-12% of patients suffer from dyspepsia and up to 1% of patients develop severe gastrointestinal complications (ulcer, bleeding, and perforation) [4].

In addition to these common NSAID side effects, DS that is one of NSAID prevents the cell cycle at the G₀/G₁ phase, thereby inducing cytotoxicity and cell death [6]. DS not only inhibits proliferation of neural stem cells but also suppresses their differentiation into neurons [12].

Although these side effects have been widely reported [18,27], little is known about the effect of NSAIDs on the development of the central nervous system or the peripheral nervous system. We previously reported a toxic effect of DS on sciatic nerve, pyramidal and granular cells of hippocampus, and Purkinje cells of male rats but not female rats following prenatal exposure [5,10,16,19]. These studies showed that the toxic effects of prenatal exposure to DS are gender dependent. On the other hand, DS has also been reported to exert a neuroprotective effect by reducing the nerve root dysfunction induced by compression [7]. New experiments are therefore needed to explain this discrepancy between studies and to evaluate the effects of anti-inflammatory drugs on the development of tissues and organs.

Although the side effects of DS on a number of tissues and organs have been mentioned, information on the effects of DS is scarce regarding the development of the peripheral nervous system. To our knowledge, no previous experimental studies have evaluated the effects of anti-inflammatory drugs like DS on the rat median nerve development. The aim of the present study was therefore to investigate the effect of prenatal exposure of DS on development of the median nerve in male and female rats.

Material and methods

Animals and experimental design

This study used adult male and female Wistar albino rats (150-200 g) obtained from the Surgical Research Centre of Yüzüncü Yıl University and mated overnight in separate standard plastic cages. The presence of a vaginal plug the next morning was taken as confirmation of pregnancy. The pregnant animals were housed in standard plastic cages on sawdust bedding in an

air-conditioned room at 20°C under a 12/12h light/dark cycle and were fed *ad libitum*. After mating, pregnant female rats were separated into control, saline, and diclofenac sodium (DS) groups. The control group was not exposed to any drug. The DS group received DS (Voltaren, 75 mg/3 ml) at a dose of 1 mg/kg daily, injected intraperitoneally beginning from the 5th day after mating to the 20th day of pregnancy. The saline group received 1 ml/kg saline intraperitoneally during the same period. After delivery, both male and female offspring were separated to three main groups (control, saline, and DS). Each main group was also divided to two subgroups that were 4 and 20 weeks old. Each subgroup contained male and female offspring ($n = 5$ offspring in each group). Offspring in the each group ($n = 5$) was taken from different litter as suggested in Maurissen [14], i.e. one male or female per litter was used for making of a group of this experiment. At the end of the 4th and 20th weeks, animals were anaesthetized with intra-peritoneal urethane injection (1.25 g/kg) and intracardially perfused with neutral formalin. After perfusion-fixation, the median nerves were unilaterally removed and processed for light microscopy and stereological analysis.

Histological and ultrastructural analysis

The median nerve samples were stretched longitudinally on cardboard using a needle and then fixed with 2.5% glutaraldehyde in 0.1 M phosphate buffer (pH 7.4) for 4-6 h in 4°C. After fixation, nerve samples were rinsed twice in phosphate buffer (pH 7.4) and post-fixed in 1% osmium tetroxide for 2 h. Specimens were then dehydrated in an increasing alcohol series and transferred to propylene oxide for 16 min.

The tissue was then embedded for 48 h using an Epon Embedding Kit. Silicon embedding moulds were used for preparing tissue blocks, which were all consecutively numbered. Semi-thin sections at 1 µm thickness were cut with an ultra microtome (Super Nova Reichert-Yung) and stained with toluidine blue (1% aqueous solution).

Stereological analysis

Stereological analysis of median nerves was done at a stereological workstation that consisted of a personal computer, computer-controlled motorized specimen stage, image capture card, CCD digital camera, and light microscope. Stereological analyses were performed for axon number, myelin thickness, and axon

cross-sectional area. The measurement and recording of stereological data and the capture of digital images of sections was made using a software program (CAST-GRID, Computer Assisted Stereological Toolbox).

A two-dimensional isotropic uniform random nucleator was used for estimation of cross-sectional area and the thickness of myelin sheet, using an oil objective (100x, NA 1.35) at a final magnification of 5111. A schematic drawing of the sampling, estimation, and measurement processes is shown in Fig. 1.

Statistical analysis

Distribution of variables was checked for compliance with a Shapiro-Wilk test. Homogeneity of variables was analysed by Levene's test. Since the variances were not homogeneous, the data were analysed by a Kruskal-Wallis one way analysis of variance by ranks test. Multiple comparisons between group pairs were then carried out according to the Dunn test. Results were expressed as a number of observations (n), mean \pm SEM,

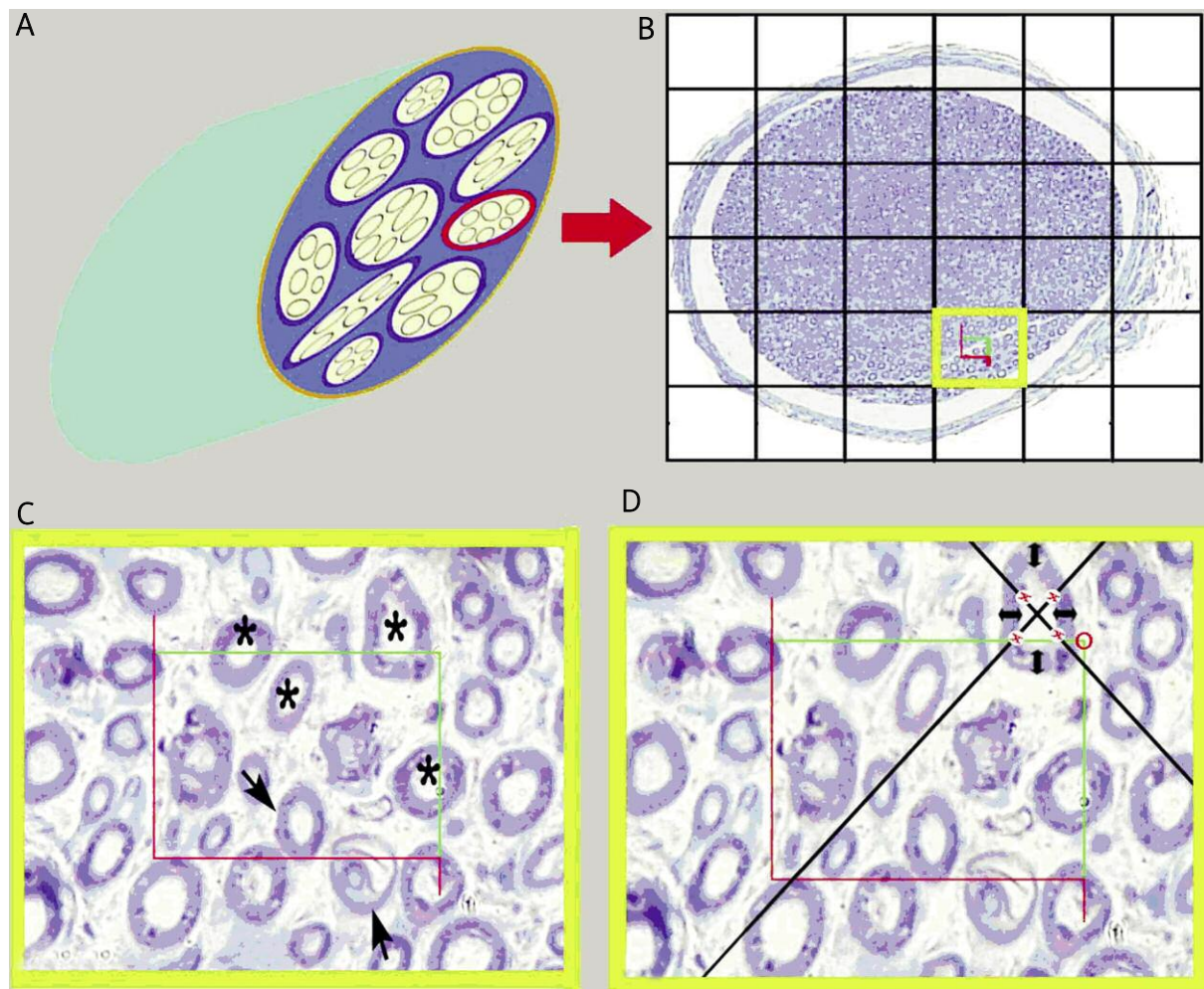


Fig. 1. Estimation of the number, area, and thickness of the myelin sheath of an axon. **A)** Schematic three dimensional illustration of a median nerve; **B)** an example of area sampling by light microscopy of a median nerve section at low magnification (x4); **C)** an unbiased counting frame superimposed on a median nerve view at high magnification (x100) for axon counting. The left and bottom edges of the frame are designated as forbidden lines. If any axon touches these lines, they are excluded from the counting. The upper and right edges of the frame are designated as inclusion lines. Any axons touching these lines and located inside the frame are counted. (*) indicates an included axon and (→) indicates an excluded axon. **D)** An unbiased counting frame superimposed on a median nerve view at high magnification (x100) for estimation of the area and thickness of the myelin sheath. (x) indicates an axon that has had its area estimated; (↔) indicates an axon that has had its myelin sheath thickness estimated.

or median (M). A *p* value less than 0.05 was considered statistically significant. Statistical analysis was performed using SPSS 13.0 for Windows.

Results

Histological results

Examination of the median nerve sections of 4-week-old and 20-week-old rats from the control, saline, and DS groups showed that these nerves are composed of one fascicle (Figs. 2 and 3). Whole fascicle is surrounded by an epineurium, which is a thick and fibrous structure. Each nerve fibre is surrounded by an

endoneurium. Most of the axons are myelinated and delineation of myelin is clearly seen. Very high irregularity in the borders of axons and axonal degeneration were seen in the DS group compared to the control and saline groups (Figs. 2 and 3).

Stereological results

Effect of substances and ages

Axon number

A comparison of myelinated axon number of the control, saline, and DS groups of the 4-week-old male, 4-week-old female, 20-week-old male, and 20-week-

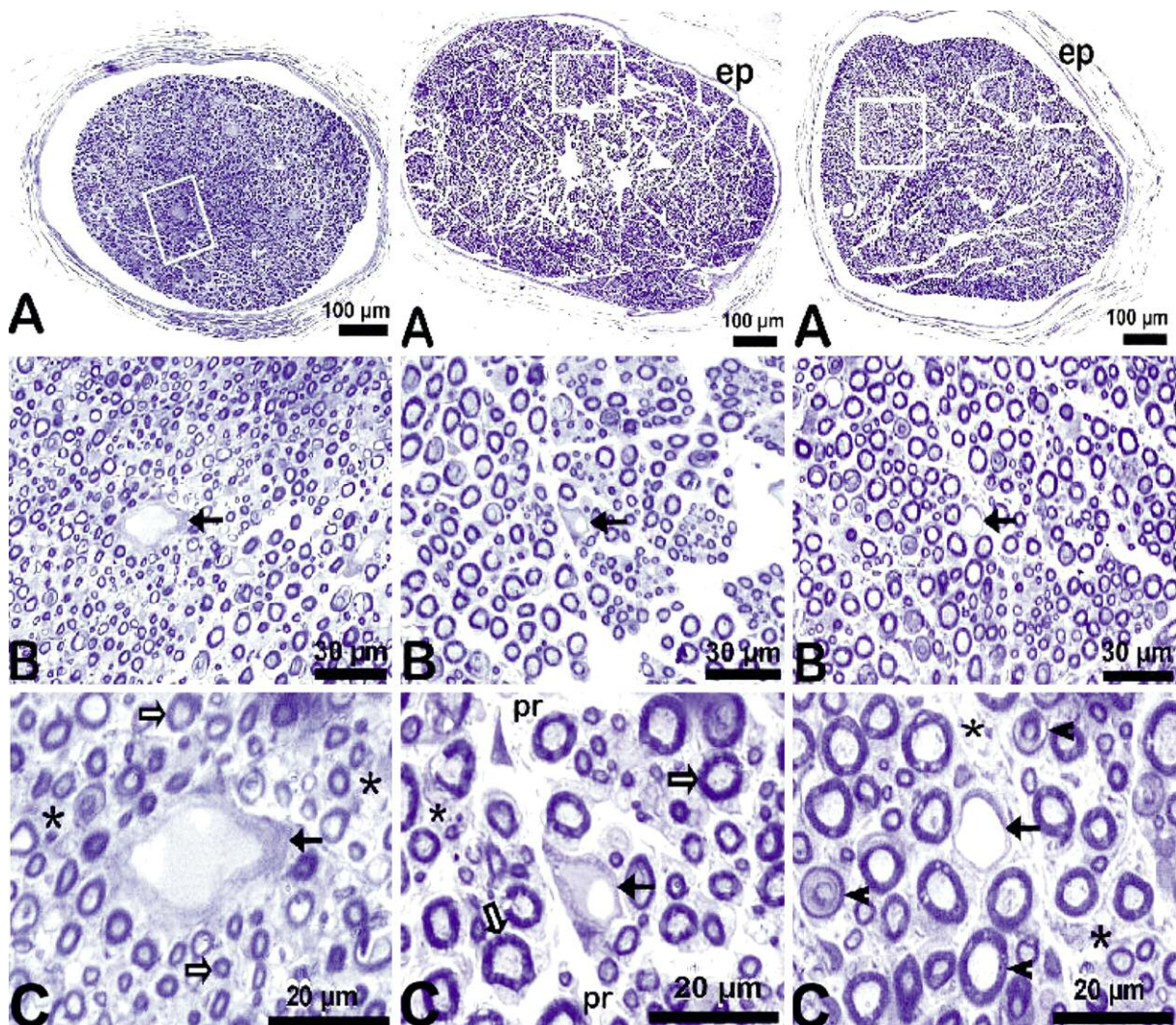


Fig. 2. Light micrographs of the control (left column), saline (middle column), and DS (right column) groups of 4-week-old (juvenile) rats; ep – epineurium, pr – perineurium, * – endoneurium, ← – veins, ⇒ – healthy axons, ◀ – degenerated axons. Toluidine blue staining.

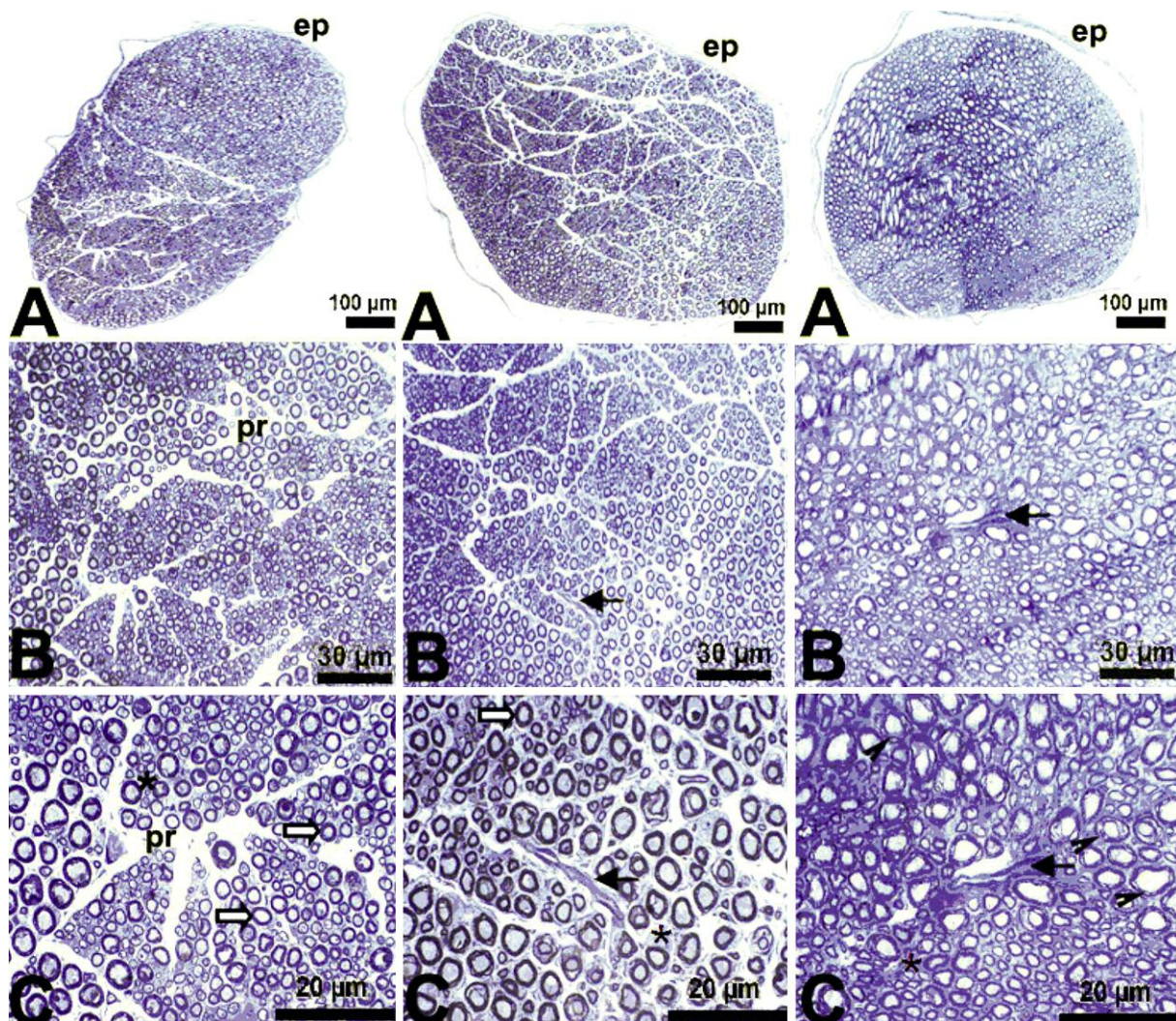


Fig. 3. Light micrographs of the control, saline, and DS groups of 20-week-old (aged) rats; ep – epineurium, pr – perineurium, * – endoneurium; ← – veins, ⇒ – healthy axons, ◀ – degenerated axons. Toluidine blue staining.

old female rats showed no significant differences between any of the groups with respect to age ($p > 0.05$) (Figs. 4 and 5).

A comparison of 4-week-old and 20-week-old rats in the control, saline, and DS groups indicated that 20-week-old males in the saline group had more nerve fibers than the 4-week-old males in the saline group (Fig. 4). In the females, significantly more myelinated nerve fibers were found in 4-week-old control vs. 20-week-old control rats; between 4-week-old saline vs. 20-week-old saline treated rats; and between 4-week-old DS vs. 20-week-old DS rats (Fig. 5). These results may indicate that some unmyelinated nerve fibers gain myelin sheaths and/or some unrecognised

myelinated nerve fibers could be more readily seen after obtaining a thick myelin sheath. The number of myelinated axons may be increased in the aged animals. This pronounced increase in myelinated axon number from the early postnatal to late postnatal life in the female gender was not seen in the male gender, except in the saline group.

Axon cross-sectional area

A comparison of 4-week-old (juvenile) male rats from the control, saline, and DS groups showed that the area of axon cross section was larger for the saline group than for the control group ($p < 0.05$) (Fig. 6). Apart from this

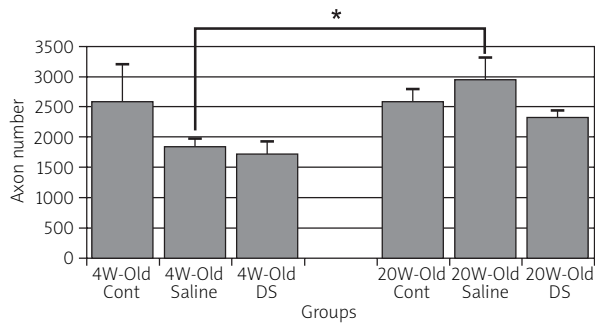


Fig. 4. Number of myelinated axons of 4-week-old (juvenile) and 20-week-old (aged) male rats (mean \pm SEM). No significant difference was seen between control, saline, and DS groups of juvenile rats or between similar groups of aged rats. In the saline group, more axons were found in the aged group than in the juvenile group, $*p < 0.05$.

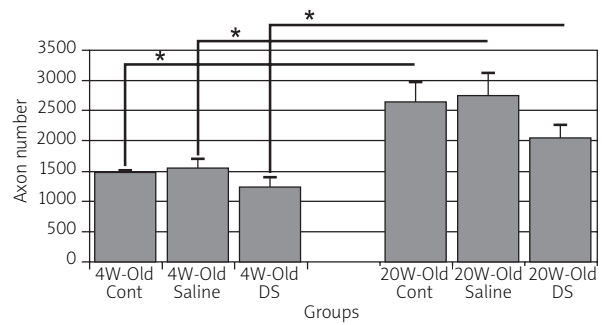


Fig. 5. Number of myelinated axons of 4-week-old (juvenile) and 20-week-old (aged) female rats (mean \pm SEM). No significant difference was found between control, saline, and DS groups of juvenile rats or between similar groups of aged rats. Aged groups have more axons than the juvenile groups when matched groups are compared, $*p < 0.05$.

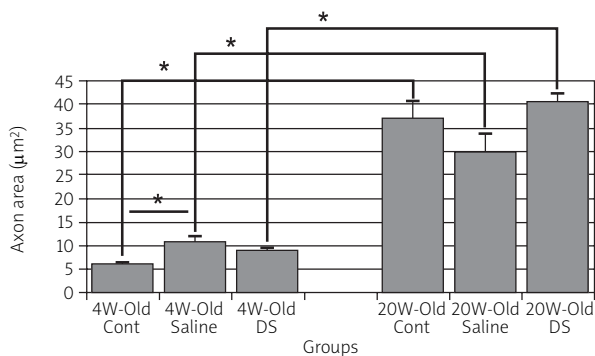


Fig. 6. Cross-sectional area of axons among 4-week-old (juvenile) and 20-week-old (aged) male rats (mean \pm SEM). A significant difference was found between the control and saline groups of 4-week-old male rats. On the other hand, no significant difference was observed between control and DS groups of 4-week-old rats. A similar result was found when 20-week-old groups were compared. A comparison of matched juvenile and aged groups showed that aged rats had more axons than the juvenile rats, $*p < 0.05$.

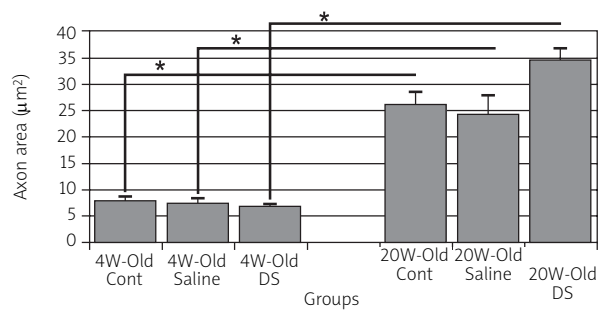


Fig. 7. Cross-sectional area of axons of 4-week-old (juvenile) and 20-week-old (aged) female rats. No significant differences were observed among groups of 4-week-old rats or among groups of 20-week-old rats. A comparison of matched juvenile and aged groups indicated that aged groups have a larger axonal area than the juvenile groups (mean \pm SEM), $*p < 0.05$.

group, no significant differences were found between the 4-week-old and aged groups (Figs. 6 and 7).

A comparison of 4-week-old control, saline, and DS groups with 20-week-old groups of the control, saline, and DS rats showed that 20-week-old male and female rats had a larger axon cross-sectional area than the 4-week-old groups (Figs. 6 and 7). This finding is a result of nerve growth.

Myelin thickness

A comparison of 4-week-old male rats in the control, saline, and DS groups showed that both saline and DS groups had a thicker myelin sheath than the control group ($p < 0.05$). On the other hand, a comparison of 20-week-old male rats of the control, saline, and DS groups showed no significant differences in myelin sheath thickness (Fig. 8). No difference was found in

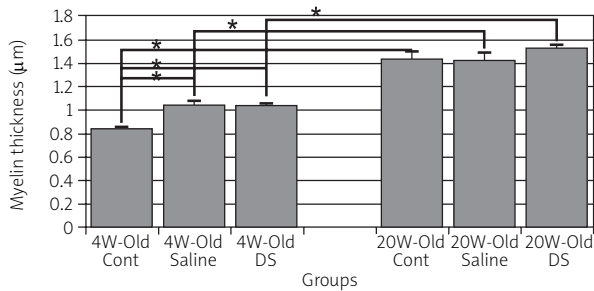


Fig. 8. Thickness of myelin sheath of axons in 4-week-old and 20-week-old male rats. Myelin sheaths of the saline and DS 4-week-old (juvenile) groups are significantly thicker than the control group. These differences were not found among 20-week-old (aged) groups. A comparison of matched juvenile and aged groups indicated that male aged rats had a thicker myelin sheath than juvenile rats (mean ± SEM), * $p < 0.05$.

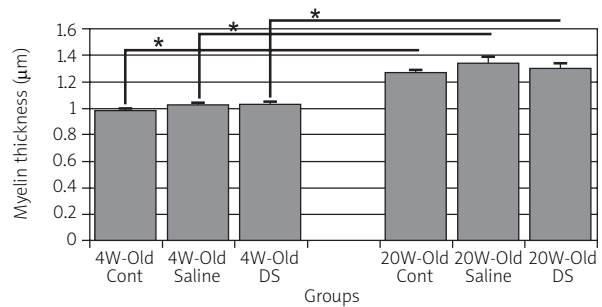


Fig. 9. Thickness of the myelin sheath of axons in 4-week-old (juvenile) and 20-week-old (aged) female rats. The control, saline, and DS groups showed no significant differences among the same age groups. A comparison of matched juvenile rats with aged rats showed that the aged groups had a thicker myelin sheath than the juvenile groups (mean ± SEM), * $p < 0.05$.

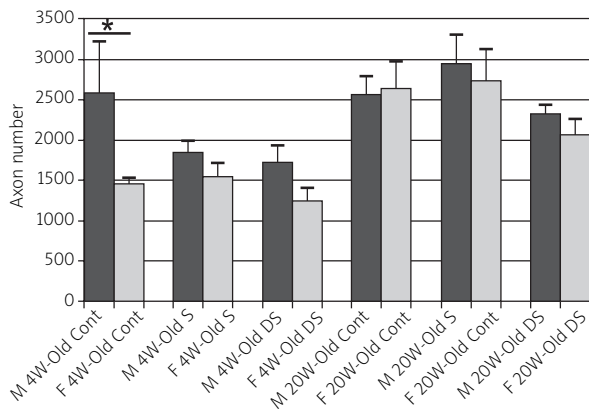


Fig. 10. A comparison of axon number in the median nerve of male and female rats (mean ± SEM), * $p < 0.05$.

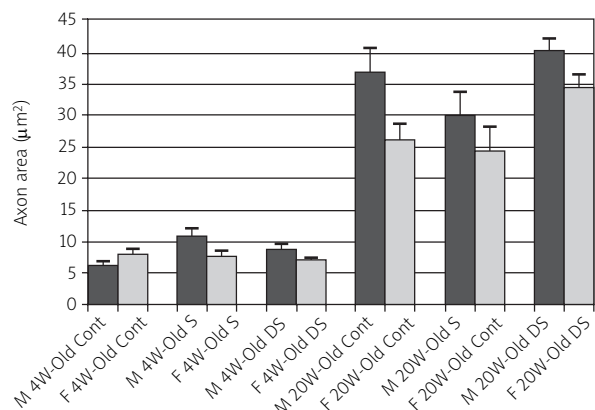


Fig. 11. A comparison of axon cross-sectional area of the median nerve of male and female rats (mean ± SEM).

the myelin sheath thickness among the 4-week-old female rats of the control, saline, and DS groups or for the 20-week-old rats (Fig. 9).

A comparison of 4-week-old rats of the control, saline, and DS groups with 20-week-old rats of the control, saline and DS groups indicated that 20-week-old male and female rats had a thicker myelin sheath than 4-week-old rats ($p < 0.05$) (Figs. 8 and 9).

Comparison of gender Axon number

A comparison of myelinated axon number between male and female rats showed a significant difference only between the 4-week-old control male and female rats ($p < 0.05$); the other matched groups showed no differences (Fig. 10).

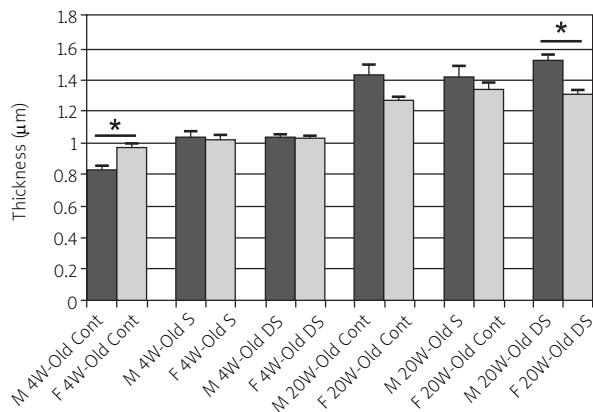


Fig. 12. A comparison of myelin thickness in the median nerve of male and female rats (mean ± SEM), * $p < 0.05$.

Axon cross-sectional area

The axon cross-sectional area was compared between male and female rats. No significant difference was found between the groups of male and female rats ($p > 0.05$) (Fig. 11). This indicated no gender effect on axon area.

Myelin sheath thickness

Myelin sheath thickness was compared between male and female rats. A significant difference was found between the 4-week-old male and female rats in the control group and also between 20-week-old male and female rats from the DS group ($p < 0.05$) (Fig. 12). Other matched groups showed no significant differences.

CE and CV values are summarised in Table I and II.

Discussion

Maternal DS consumption should be avoided during pregnancy since the newborn may be affected by severe pulmonary hypertension and hypertrophic cardiomyopathy with closed ductus arteriosus [24]. Inan *et al.* showed that DS has a side effect of bursting pressures of the colonic anastomoses and hydroxyproline content of the perianastomotic tissue in rats [11]. In rats, prenatal stress may induce cell loss in the granule cells of the hippocampus preferentially in females compared to males, and this may be a sex-specific predisposing factor for the development of depression in

Table I. Estimation of the number of axons, cross-sectional area of axon and myelin sheath in the median nerve

4-week-old male	Axon number	SEM	Cross-sectional area of axon	SEM	Myelin thickness	SEM
DS	1719	20.21	8.81	0.68	1.035	0.026
Saline	1830	148.56	10.68	1.25	1.041	0.032
Control	2575	641.26	6.26	0.26	0.837	0.019
4-week-old female						
DS	1236	168.44	6.97	0.41	1.028	0.020
Saline	1546	162.74	7.65	0.82	1.023	0.019
Control	1455	65.66	7.93	0.88	0.979	0.018
20-week-old male						
DS	2319	111.66	40.41	1.73	1.528	0.026
Saline	2945	370.48	29.82	3.83	1.422	0.062
Control	2551	232.43	36.84	3.82	1.435	0.059
20-week-old female						
DS	2053	200.62	34.52	2.15	1.30	0.0343
Saline	2740	385.19	24.34	3.66	1.34	0.0389
Control	2636	341.48	26.10	2.41	1.27	0.0252

Table II. Sampled axon number, coefficient of error (CE) and coefficient of variation (CV) of stereological analysis of axon counting, cross-sectional area of axon and myelin thickness measurements in the median nerves

	Axon number			Cross-sectional area of axon			Myelin thickness		
	Cont	Saline	DS	Cont	Saline	DS	Cont	Saline	DS
4-week-old male									
Number of sampled axon	959	1251	1120	95	130	84	95	130	84
CE	0.03	0.03	0.03	0.1	0.09	0.1	0.1	0.09	0.01
CV	0.56	0.18	0.26	0.09	0.03	0.02	0.05	0.07	0.05
20-week-old male									
Number of sampled axon	949	1096	863	202	200	168	202	200	168
CE	0.03	0.03	0.03	0.07	0.07	0.08	0.07	0.07	0.08
CV	0.22	0.31	0.12	0.25	0.31	0.1	0.1	0.1	0.04
4-week-old female									
Number of sampled axon	524	575	460	66	60	59	66	60	59
CE	0.04	0.04	0.05	0.1	0.1	0.1	0.1	0.1	0.1
CV	0.1	0.3	0.3	0.3	0.3	0.1	0.05	0.05	0.04
20-week-old female									
Number of sampled axon	981	1020	764	93	87	66	93	87	66
CE	0.03	0.03	0.04	0.1	0.1	0.1	0.1	0.1	0.1
CV	0.3	0.3	0.2	0.2	0.4	0.2	0.05	0.07	0.06

adulthood [22]. DS may show its neurotoxic effects through not only growth inhibition but also differentiation inhibition. The differences in DS cytotoxic effects in two culture media suggest that drug cytotoxicity may be related to oxidative stress [21].

A great discrepancy is seen for the effects of NSAIDs on tissue and organs in the literature. NSAIDs have been reported to suppress cell proliferation in the spinal cord and dorsal root ganglia by affecting cells cycle regulators, since DS, in contrast to other NSAIDs, was observed to inhibit the differentiation of neuronal stem cells into neurons and also to suppress cell proliferation via the induction of apoptosis [6,13]. Therefore, DS appears to have some negative effects on the development and differentiation of nerve cells. A neurotoxic effect of prenatal exposure of DS on the central nervous system was reported in the granular and pyramidal cells of the hippocampus and in the Purkinje cells of the cerebellum [10,17,19].

A comparison of juvenile male rats from the control, saline, and DS groups showed that the cross-sectional

area of axon was larger for the saline group than the control group ($p < 0.05$), but not for the DS group. Such difference was not seen in the aged groups. This result may suggest that an increased cross-sectional area seen in the juvenile saline group is a transient structure, since it was not observed in the aged groups.

A comparison of 4-week-old male rats in the control, saline, and DS groups showed that both saline and DS groups had a thicker myelin sheath than the control group ($p < 0.05$). On the other hand, a comparison of 20-week-old male rats of the control, saline, and DS groups showed no significant differences in myelin sheath thickness.

A similar result was found in the myelin sheath thickness among the 4-week-old female rats of the control, saline, and DS groups as seen in 20-week-old male rats and also the same for the 20-week-old female rats. These results may indicate that an increased myelin sheath thickness seen in the juvenile saline group is a transient form, since it would not be observed in the aged groups.

In the literature, many studies have reported biochemical, pathological, and molecular features of peripheral nerves. Few of these mention the morphological and/or developmental characteristics of these nerves. The neurotoxic effects of DS on the sciatic nerve were investigated in rats exposed to DS during the gestational period [5], and a substantial axon loss was found in the nerve in DS-exposed groups. In contrast, in the present study, no significant difference was found regarding axon number among the control, saline, and DS groups, which included both male and female rats ($p > 0.05$). However, the cross-sectional area of the axon and the thickness of the myelin sheath showed significant differences among some groups ($p < 0.05$). These results may suggest that the structure of median nerve axons, rather than their number, is more susceptible to DS disruption. Gender differences were also evident in the 4-week-old male and female rats, as the control groups were significantly different from each other in terms of axon number and myelin sheath thickness. The meaning of this finding may be that the median nerve development, and especially myelination in early life, may be processed at different rates in male and female rats; but this difference may be eliminated over time.

Although the male rats of the control group had more axons than the female rats in early life (4 weeks old); this difference between males and females disappeared at the later life stage (20 weeks old). This may indicate that in early life stages, most of the axons of male rats develop their myelin sheaths more rapidly than axons of female rats. On the other hand, the same group of female rats (4-week-old control females) had a thicker myelin sheath than the male rats (4-week-old control males). In contrast, 20-week-old DS male rats had thicker myelin sheaths than the matched female group, which indicated changes that occurred later in life in the DS groups.

In the present experiment, we used stereological techniques for nerve analysis. These techniques are reliable, since they are designed to obtain unbiased quantitative results of the size, shape, and number of many biological objects. When these methods are properly used, they provide important contributions to experiments in biological research [9]. In this respect, our results may indicate real changes in the tissue and our comments on the nerve fibre morphology would be valid.

In summary, no drug-dependent macroscopic abnormality of nerves was observed, as the axon num-

ber and axon cross-sectional area of the control, saline, and DS rats of the same age and same gender groups were not different from each other. A comparison of 20-week-old groups with 4-week-old groups with respect to axon number, area, and myelin thickness of the matched groups of the same gender showed that most of the parameters of the aged groups are higher than those of the juvenile groups. A comparison of the axon number between the two genders showed that the juvenile control male has more axons than the juvenile control female. In conclusion, prenatal exposure to diclofenac sodium does not affect axon number but it does result in some alterations of the morphology of rat median nerves. The pharmacological and pathophysiological mechanisms involved in these treatments should be investigated further.

Acknowledgements

This study was supported by the Research Foundation of Ondokuz Mayıs University (S. Kaplan, PYO.TIP.1904.09.046.)

References

1. Acosta MC, Luna C, Graff G, Meseguer VM, Viana F, Gallar J, Belmonte C. Comparative effects of the nonsteroidal anti-inflammatory drug nepafenac on corneal sensory nerve fibers responding to chemical irritation. *Invest Ophthalmol Vis Sci* 2007; 48: 182-188.
2. Auer M, Brezinka C, Eller P, Luze K, Schweigmann U, Schwärzler P. Prenatal diagnosis of intrauterine premature closure of the ductus arteriosus following maternal diclofenac application. *Ultrasound Obstet Gynecol* 2004; 23: 513-516.
3. Bannwarth B, Berenbaum F. Clinical pharmacology of lumiracoxib, a second-generation cyclooxygenase 2 selective inhibitor. *Expert Opin Investig Drugs* 2005; 14: 521-533.
4. Bures J, Rejchrt S, Kopáčová M, Siroký M. Effects of nonsteroidal anti-inflammatory agents on the gastrointestinal tract. *Cas Lek Cesk* 2002; 141: 673-679.
5. Canan S, Aktas A, Ulkay MB, Colakoglu S, Ragbetli MC, Ayyildiz M, Geuna S, Kaplan S. Prenatal exposure to a non-steroidal anti-inflammatory drug or saline solution impairs sciatic nerve morphology: a stereological and histological study. *Int J Dev Neurosci* 2008; 26: 733-738.
6. Chang JK, Wang GJ, Tsai ST, Ho ML. Nonsteroidal anti-inflammatory drug effects on osteoblastic cell cycle, cytotoxicity, and cell death. *Connect Tissue Res* 2005; 46: 200-210.
7. Corneffjord M, Olmarker K, Otani K, Rydevik B. Effects of diclofenac and ketoprofen on nerve conduction velocity in experimental nerve root compression. *Spine (Phila Pa 1976)* 2001; 26: 2193-2197.
8. Davey PG. Overview of drug interactions with the quinolones. *J Antimicrob Chemother* 1988; 22 Suppl C: 97-107.
9. Geuna S, Tos P, Battiston B, Guglielmo R. Verification of the two dimensional disector, a method for the unbiased estimation

- of density and number of myelinated nerve fibers in peripheral nerves. *Ann Anat* 2000; 182: 23-34.
10. Gokcimen A, Rağbetli MÇ, Baş O, Tunc AT, Aslan H, Yazıcı AC, Kaplan S. Effect A of prenatal exposure to an anti-inflammatory drug on neuron number in cornu ammonis and dentate gyrus of the rat hippocampus: a stereological study. *Brain Res* 2006; 1127: 185-192.
 11. Inan A, Koca C, Sen M. Effects of diclofenac sodium on bursting pressures of anastomoses and hydroxyproline contents of perianastomotic tissues in a laboratory study. *Int J Surg* 2006; 4: 222-227.
 12. Kudo C, Kori M, Matsuzaki K, Yamai K, Nakajima A, Shibuya A, Niwa H, Kamisaki Y, Wada K. Diclofenac inhibits proliferation and differentiation of neural stem cells. *Biochem Pharmacol* 2003; 66: 289-295.
 13. Lee HM, Kim HI, Shin YK, Lee CS, Park M, Song JH. Diclofenac inhibition of sodium currents in rat dorsal root ganglion neurons. *Brain Res* 2003; 992: 120-127.
 14. Maurissen J. Practical considerations on the design, execution and analysis of developmental neurotoxicity studies to be published in *Neurotoxicology and Teratology*. *Neurotoxic Teratol* 2010; 32: 121-123.
 15. Moise KJ, Huhta JC, Sharif DS, Ou CN, Kirshon B, Wasserstrum N, Cano L. Indomethacin in the treatment of premature labor. Effects on the fetal ductus arteriosus. *N Engl J Med* 1988; 319: 327-331.
 16. Odacı E, Cihan OF, Aslan H, Rağbetli MC, Kaplan S. Prenatal diclofenac sodium administration increases the number of Purkinje cells in female rats: a stereological study. *Int J Devl Neuroscience* 2010; 28: 145-151.
 17. Özyurt B, Kesici H, Alici SK, Yılmaz S, Odacı E, Aslan H, Rağbetli MÇ, Kaplan S. Prenatal exposure to diclofenac sodium changes the morphology of the male rat cervical spinal cord: A stereological and histopathological study. *Neurotoxicol Teratol* 2011; 33: 282-287.
 18. Rağbetli C, Aydinlioglu A, Kara M, Rağbetli MC, İlhan F. Effects of diclofenac sodium on the rat liver in postnatal period. *J Anim Vet Adv* 2009; 8-9: 1761-1764.
 19. Rağbetli MC, Özyurt B, Aslan H, Odacı E, Gokcimen A, Sahin B, Kaplan S. Effect of prenatal exposure to diclofenac sodium on Purkinje cell numbers in rat cerebellum: a stereological study. *Brain Res* 2007; 1174: 130-135.
 20. Rainsford KD, Kean WF, Ehrlich GE. Review of the pharmaceutical properties and clinical effects of the topical NSAID formulation, diclofenac epolamine. *Curr Med Res Opin* 2008; 24: 2967-2992.
 21. Rajabalian S, Meimandi MS, Badinloo M. Diclofenac inhibits proliferation but not NGF-induced differentiation of PC12 cells. *Pak J Pharm Sci* 2009; 22: 259-262.
 22. Schmitz C, Rhodes ME, Bludau M, Kaplan S, Ong P, Ueffing I, Vehoff J, Korr H, Frye CA. Depression: reduced number of granule cells in the hippocampus of female, but not male, rats due to prenatal restraint stress. *Mol Psych* 2002; 7: 810-813.
 23. Segev S, Rehavi M, Rubinstein E. Quinolones, theophylline, and diclofenac interactions with the gamma-aminobutyric acid receptor. *Antimicrob Agents Chemother* 1988; 32: 1624-1626.
 24. Siu KL, Lee WH. Maternal diclofenac sodium ingestion and severe neonatal pulmonary hypertension. *J Paediatr Child Health* 2004; 40: 152-153.
 25. Thieffn G, Beaugerie L. Toxic effects of nonsteroidal antiinflammatory drugs on the small bowel, colon, and rectum. *Joint Bone Spine* 2005; 72: 286-294.
 26. Vermillion ST, Scardo JA, Lashus AG, Wiles HB. The effect of indomethacin tocolysis on fetal ductus arteriosus constriction with advancing gestational age. *Am J Obstet Gynecol* 1997; 177: 256-259.
 27. Yasmeen T, Qureshi GS, Perveen S. Adverse effects of diclofenac sodium on renal parenchyma of adult albino rats. *J Pak Med Assoc* 2007; 57: 349-351.