

# Clinical and neuroimaging correlation of movement disorders in multiple sclerosis: case series and review of the literature

Anna Potulska-Chromik<sup>1</sup>, Monika Rudzinska<sup>2</sup>, Monika Nojszewska<sup>1</sup>, Aleksandra Podlecka-Piętowska<sup>1</sup>,  
Andrzej Szczudlik<sup>2</sup>, Beata Zakrzewska-Pniewska<sup>1</sup>, Marek Gołębiowski<sup>3</sup>

<sup>1</sup>Department of Neurology, Medical University of Warsaw, Warsaw, <sup>2</sup>Department of Neurology, Collegium Medicum Jagiellonian University, Krakow, <sup>3</sup>1<sup>st</sup> Department of Clinical Radiology, Medical University of Warsaw, Warsaw, Poland

*Folia Neuropathol* 2014; 52 (1): 92-100

DOI: 10.5114/fn.2014.41747

## Abstract

Multiple sclerosis (MS) is a chronic inflammatory demyelinating disease of the central nervous system, in which movement disorders (MD) have been reported very rarely. Anatomopathological studies of MS indicate two main processes: inflammation and neurodegeneration. The occurrence of the movement disorders symptoms in MS revises the question of aetiology of these two diseases. During the 10 years of observation in our out-patient clinic and MS units we examined about 2500 patients with clinically definite MS diagnosed according to the revised McDonald's criteria. Only in 10 cases we found coexistence of MS and MD signs. Below we present rare cases of patients with coexistence of MS and chorea, pseudoathetosis, dystonia and parkinsonism. Searching for the strategic focal lesion in our case series showed demyelinating plaques placed in the thalamus most often. Detailed analysis of the clinical, pharmacological and neuroimaging correlations may help to explain the character of movement disorders in MS.

**Key words:** multiple sclerosis, movement disorders, dystonia, parkinsonism, chorea, pseudoathetosis.

## Introduction

The multiple sclerosis (MS) is an autoimmune disorder associated with several pathophysiological mechanisms such as inflammation, demyelination, axonal/neuronal damage, gliosis, remyelination and repair mechanisms, oxidative injury and excitotoxicity. Heterogeneity in the phenotypic expression of MS is related to these processes, which are not uniformly represented in patient population, even at the same stage of the disease [14].

The clinical symptomatology presenting as transient pyramidal, sensory, cerebellar signs, usually is very characteristic in most cases of MS. In this study we present rare cases of MS with coexistence of a wide spectrum of movement disorders (MD), including MD occurring as a presenting symptom of MS. The occurrence of the movement disorders symptoms in multiple sclerosis revises the question of aetiology of these two disorders. After detailed clinical and neuroimaging analyses of our patients we proposed an algorithm, which can help to find

## Communicating author:

Prof. Marek Gołębiowski, 1<sup>st</sup> Department of Clinical Radiology, Medical University of Warsaw, 5 Chałubińskiego Str., 02-004 Warsaw, Poland, e-mail: marek.golebiowski@wum.edu.pl

the association between inflammatory or/and neurodegenerative damage occurring in MS and MD.

## Material and methods

During the 10 years of observation in our out-patient clinic and MS units we examined about 2500 patients with clinically definite MS diagnosed according to the revised McDonald's criteria [10]. Only in 10 cases we found coexistence of MS and MD signs. In all presented patients, the past medical history including exposure to neuroleptics, neurotoxin or head trauma was negative. Wilson's disease, neuroacanthocytosis, thyroid dysfunction and neuroborreliosis were also excluded. Below we present the clinical picture of our patients.

### Movement disorders as a presenting symptom of multiple sclerosis

#### Case 1

A 45-year-old man complained of involuntary movements which appeared in the upper limbs and then progressed to the head, trunk and lower limbs, irritability and memory problems, which started insidiously. His brother revealed a 24-year-history of MS with relapsing/remitting episodes of cerebellar symptoms and lower limb paresis.

Neurological examination revealed increased mood, uninhibited behaviour, choreic movement of the face, trunk and limbs more remarkable in upper limbs, motor tics of the face and arms, bilaterally decreased

muscle tone and brisk deep tendon reflexes, lower limbs ataxia, impaired tandem gait. The choreic movement exacerbated during walking or other voluntary movements and under stress.

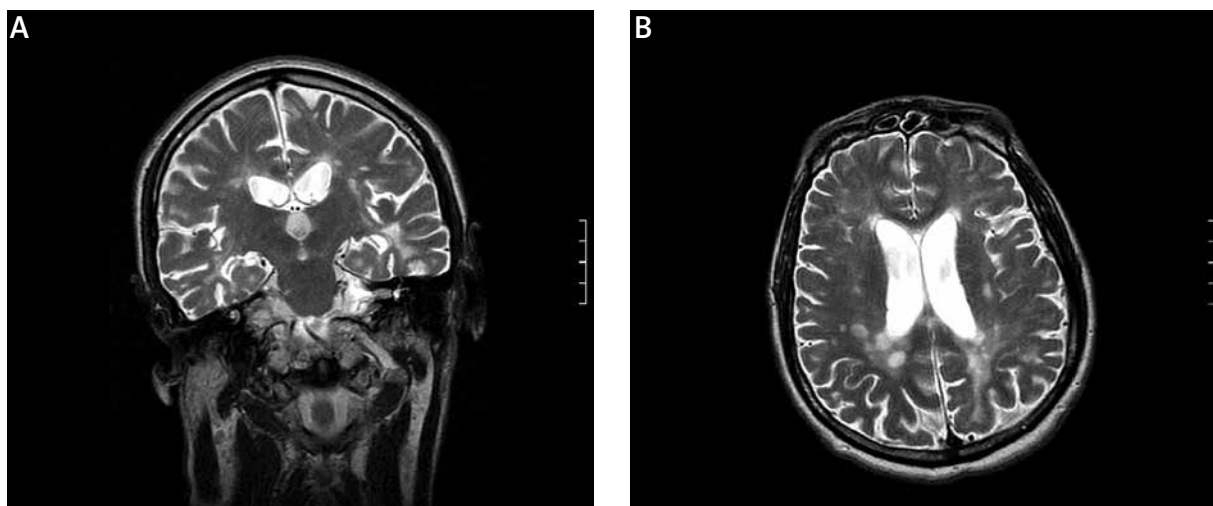
Genetic tests for Huntington disease and tests for metachromatic leucodystrophy and lupus erythematosus were negative. The activity of protein C and antithrombin III and concentration of protein S were within normal limits. Neuropsychological examination showed an early stage of dementia, with frontal and subcortical dysfunctions. Finally, the patient was diagnosed with a familial, primary progressive multiple sclerosis of unusual symptomatology: involuntary movements, cognitive impairment (dementia) and mood disorder (Fig. 1).

#### Case 2

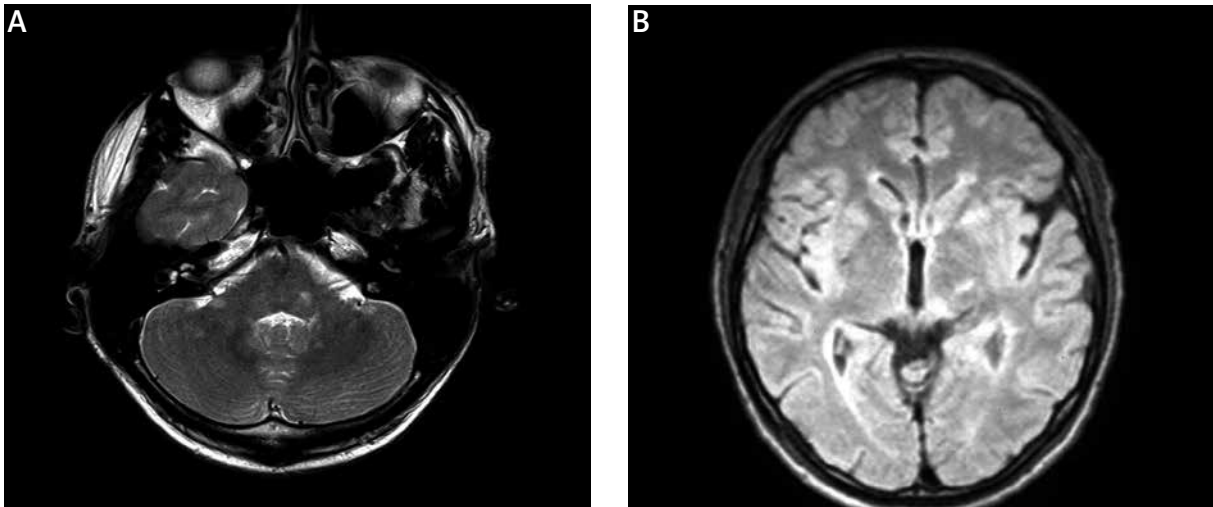
A 33-year-old man was being examined at a neurological department because of persistent involuntary rotation of the head to the right side and head tremor. These symptoms began five years before admission and the disease was slowly progressive. The symptoms reminded a focal cervical dystonia (torticollis).

The neurological examination revealed also lack of left abdominal reflexes and bilaterally absent plantar responses.

Finally, after 2 relapses of the disease he was diagnosed according to the McDonald's criteria with relapsing-remitting MS with cervical dystonia as a presenting symptom (Fig. 2).



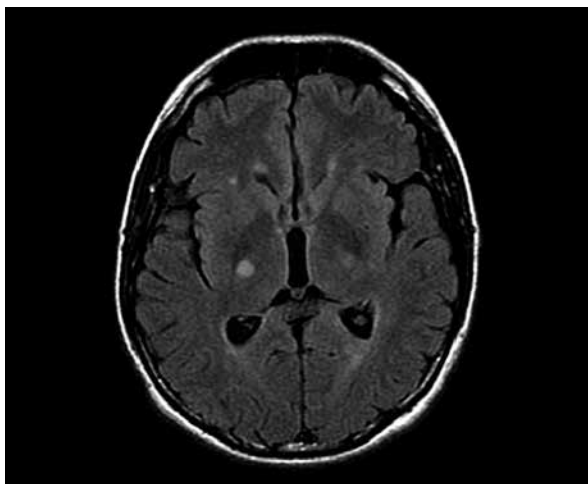
**Fig. 1.** Case 1. **A)** Coronal and **B)** axial T2 MR images show multiple focal periventricular/subcortical hyperintense lesions compatible with demyelinating plaques.



**Fig. 2.** Case 2. **A)** Axial FLAIR and **B)** T2 MR images demonstrate demyelinating lesions in the cerebellum, left thalamus and periventricular area.

### Case 3

A 32-year-old man complained of involuntary movements of the left upper and lower limbs accompanied by severe pain, lasting for 3 weeks. Symptoms started insidiously, lasted 5-10 seconds, usually occurred several times a day initiated by fatigue or voluntary movements of the limbs. On neurological examination the patient presented with mild left side paresis, brisk tendon reflexes in the left lower limb, bilateral flexor plantar reflex. Movements first appeared in the arm, then slowly progressed to the forearm and hand causing painful dystonic posture



**Fig. 3.** Case 3. Axial FLAIR MR image shows some bilateral, periventricular focal T2 hyperintensities localized also in the right thalamus and subsular area.

and spread to the left side of the trunk and to the left lower limb proximally (the thigh).

We diagnosed MS of an unusual symptomatology: involuntary movements similar to muscle spasms accompanied by dystonia. The diagnosis was confirmed by MRI with gadolinium and CSF study (Fig. 3).

### Case 4

A 39-year-old woman was being diagnosed in our out-patient clinic because of a 5-year history of the voice and head tremor. She also noticed excessive blinking of the eyes, tendency to the neck rotation to the left side and general fatigability. Neurological examination showed mild cervical dystonia with rotation of 20 degrees to the left side (torticollis), slight dysmetria in the left upper limb, lack of the plantar and all abdominal reflexes bilaterally. Over the subsequent year she experienced 3 relapses of the disease with cerebellar and motor signs. She was qualified to the interferon therapy with marked improvement (no relapses during 1-year therapy were observed), however 3 months after finishing this treatment the patient noticed progression of cervical dystonia.

### Movement disorders in the course of the multiple sclerosis

### Case 5

A 37-year-old woman with a 5-year history of MS complained of tremor and disability of the right hand, which had started insidiously and slowly progressed.

On neurological examination the patient presented with stiffness, slowness and rest tremor on the right side of the body, deep tendon reflexes were very brisk, exaggerated on the left side, Babinski sign was observed bilaterally.

Genetic tests for early-onset Parkinson's disease (PARK2, DJ-1, PINK) were negative.

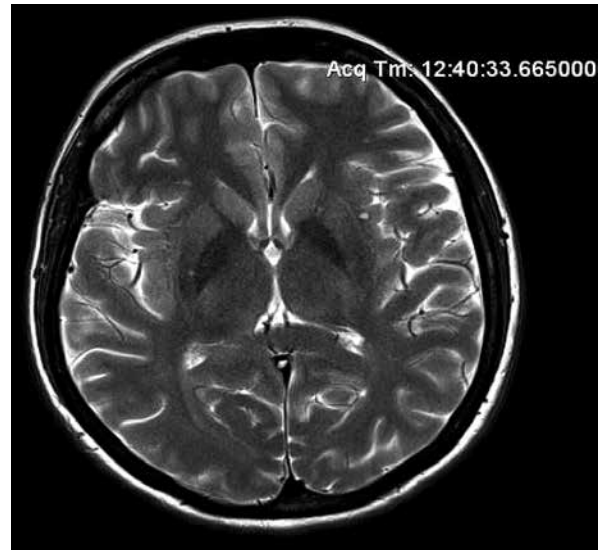
She observed improvement after ropinirole 4 mg/day. After 2 months she stopped the therapy by mistake without any consequences. Tremor reappeared during the next relapse of the disease. She responded very well to corticosteroid therapy (Fig. 4).

#### Case 6

A 43-year-old woman was diagnosed with multiple sclerosis in 2006 after an episode of the left retrobulbar optic neuritis. In May 2010, she had sudden onset of involuntary movements in the right hand coexisting with pain of the forearm. On her physical examination, there was reduced deep sensation in the right hand with associated pseudoathetotic movements (Fig. 5).

#### Case 7

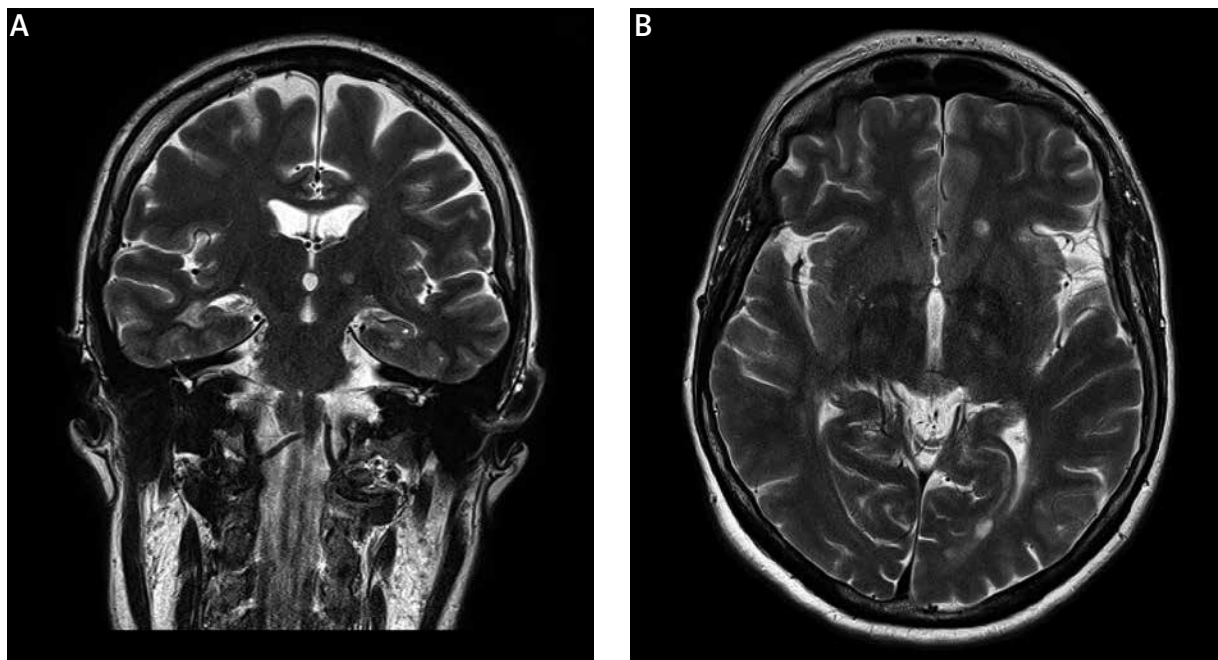
A 51-year-old woman with a 28-year history of MS presented to our unit with dystonia of the left



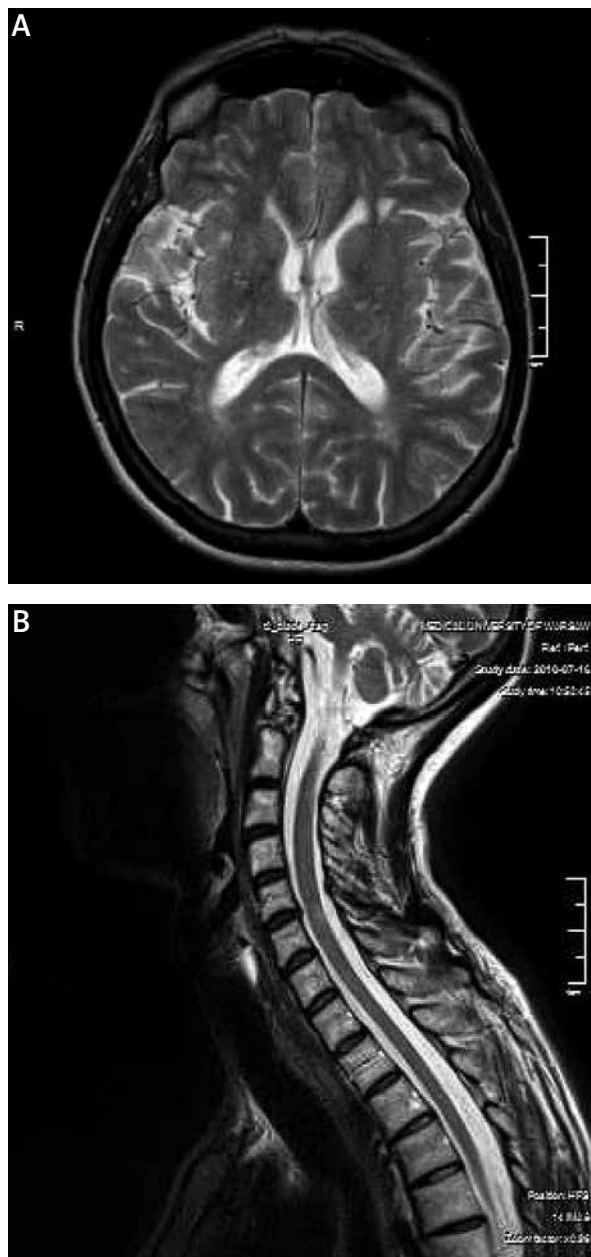
**Fig. 4.** Case 5. Axial T2 image shows two small demyelinating lesions in the putamen of the right lentiform nucleus and left subinsular area.

hand. She had relapsing-remitting MS with sensory, motor and visual symptoms and signs.

In 2003, she observed involuntary movements and cramp of her left hand, which was diagnosed as symptomatic focal dystonia (Fig. 6).



**Fig. 5.** Case 6. A) Coronal and B) axial MRI T2 images show demyelinating lesions in both thalami, periventricular and cortico-subcortical area.



**Fig. 6.** Case 7. **A)** Axial T2 MR image shows multiple foci of hyperintense signal in both thalami and periventricular/subcortical white matter; **B)** Cervical MRI revealed few intramedullary demyelinating plaques and discopathy at the C4/C5 level.

#### Case 8

A 66-year-old woman with a 30-year history of MS presented with blepharospasm. Treatment with botulinum toxin has been effective with a significant long-lasting improvement after transient right

ptosis 5 days after treatment. Currently, the patient experiences only excessive blinking and she does not need any additional treatment.

#### Case 9

A 58-year-old woman with a 27-year history of MS experienced excessive blinking and involuntary spasm of both orbicularis eye muscles, diagnosed as a blepharospasm. Treatment of blepharospasm with botulinum toxin repeated every 5 months was slightly effective.

#### Case 10

A 57-year-old woman with an 18-year history of a very benign course of relapsing-remitting MS presented with dystonic tremor of the head with slight rotation to the left side and right hand dystonia resembling writer's cramp (Fig. 7).

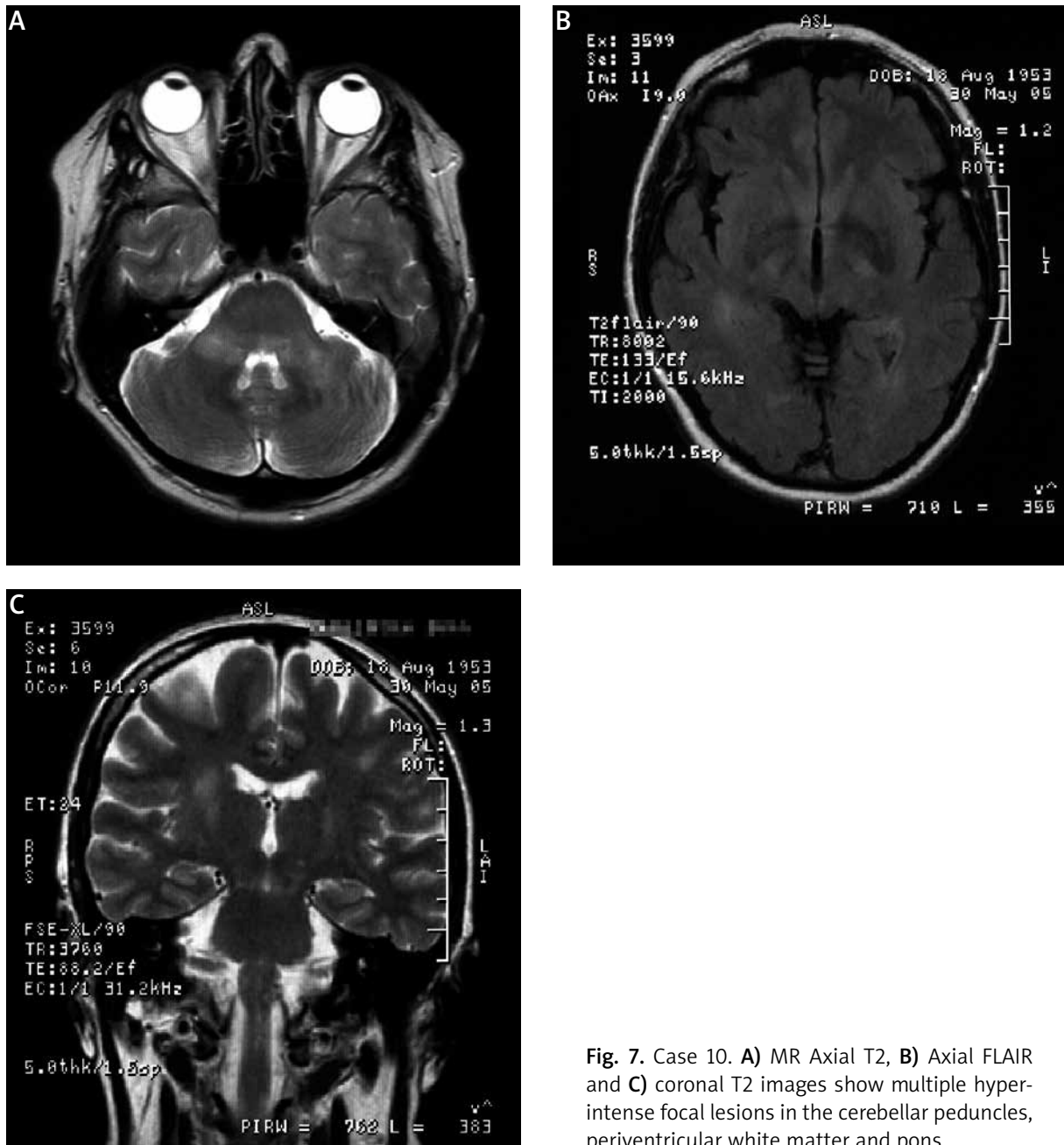
### Results

All details, i.e. MS course, type of MD, MRI findings as well as response to the therapy are summarized in Table I.

### Discussion

Movement disorders symptomatology is rare in MS. In some cases, even very experienced physicians are diverted from the diagnosis of MS by the presence of unusual symptoms derived from basal ganglia or autonomic nervous system lesions [11], although occasional involvement of the basal ganglia was reported [8-10,18].

Moreover, these unusual findings are still very challenging in looking for neuropathological basis for dystonia, chorea and parkinsonism. In the literature, causal or coincidental association of these two disorders was discussed. To the best of our knowledge, chorea has been reported in only few cases, almost always during the course of the diagnosed MS. Demyelinating lesions were usually situated in the basal ganglia (striatum). In our case 1 with chorea as a presenting symptom of MS, neuroimaging revealed typical demyelinating changes in the periventricular white matter, most remarkable in the frontal and parietal lobes and in the left cerebellar hemisphere without any significant correlation with the extrapyramidal tract. Although chorea and ticks did not respond to neuroleptic treatment, their severity was



**Fig. 7.** Case 10. **A)** MR Axial T2, **B)** Axial FLAIR and **C)** coronal T2 images show multiple hyperintense focal lesions in the cerebellar peduncles, periventricular white matter and pons.

slightly temporarily diminished on corticosteroid therapy. The positive response to this treatment does not allow to exclude causal relationship between chorea and MS.

Paroxysmal symptoms (dysarthria, ataxia, paresthesia, pain, itching, pain, hemiparesis) as presenting symptoms were also described in MS. Tuzun *et al.* [19] reported that clusters of paroxysmal symptoms usually tend to occur early in the course of the disease. Espir and Millac [2] postulated that “paroxysms result

from a degree of demyelination insufficient to give persistent deficit, but rendering axons hypersensitive to minor stresses”. Paroxysmal symptoms, especially the spasm, probably result from ephaptic transmission between a sensory pathway and the corticospinal tract. Response to the corticosteroids observed in our case 3 indicates the inflammatory/demyelinating mechanism of this disorder.

Cervical dystonia as a presenting symptom of MS has been also reported very rarely [13], however spas-

**Table 1.** Clinical signs, MRI features and response to specific therapy in our group of patients

Patients	MS course	Type of movement disorder	Localization of hyperintense focal lesions in MRI possibly related to the movement disorders*	MRI findings reported in the literature	Positive response to MS therapy (corticosteroids/interferon)	Positive response to movement disorders therapy
Case 1	primary progressive	chorea	only typical for MS	thalamus, lentiform nucleus [12] caudate nucleus [5]	yes/not available	neuroleptics – no
Case 2	relapsing-remitting	dystonia	thalamus, cerebellar peduncles	caudate nucleus, putamen [17], pallidum [18], midbrain [9], pontomesencephalic junction [17], cervical spinal cord [3]	yes/yes	botulinum toxin – no (side effects)
Case 3	relapsing-remitting	paroxysmal dystonia of the limb	the right thalamus, brainstem, midbrain, pons, cerebellar peduncle	thalamus, lentiform nuclei [18], cervical spinal cord [20]	yes/yes	baclofen – no
Case 4	relapsing-remitting	dystonia	cervical spinal cord at the level C1/C2	as in case 2	no/yes	botulinum toxin – yes
Case 5	relapsing-remitting	parkinsonism on the right side	the right nucleus lentiformis	centrum semiovale, cerebellum, pons, internal capsule, thalamus, bilateral pallidum, substantia nigra, red nucleus [18]	yes	ropinirole – yes
Case 6	relapsing-remitting	pseudoathetosis	thalamus, nucleus lentiformis, medulla oblongata	C2-C5 spinal cord segments [4, 6] internal capsule, pallidum, mesencephalus, pons [16]	no	not available
Case 7	relapsing-remitting	hand dystonia	thalamus, cervical spinal cord C4-C5	thalamus and lentiform nuclei [17], cervical spinal cord [3]	no	botulinum toxin – yes
Case 8	secondary progressive	dystonia – blepharospasm	only typical for MS	parietal lobe [8]	no	botulinum toxin – yes
Case 9	secondary progressive	dystonia – blepharospasm	only typical for MS	parietal lobe [8]	the patient did not consent to the mitoxantrone therapy	botulinum toxin – yes
Case 10	relapsing-remitting	segmental dystonia (dystonic tremor of the head and task specific dystonia resembling writer's cramp of the right hand)	pons, cerebellar peduncles	as in case 2 and 7	no	not estimated

\*All patients fulfil radiological criteria of MS diagnosis (periventricular, juxtacortical and infratentorial lesions)

modic torticollis expressed during the course of the definite MS is found more frequently [5,17,18]. Subcortical grey matter contains myelinated fibers and plaques causing movement disorders can be found in the striatum, pallidum, thalamus and most commonly the brainstem. However, in the majority of reported cases, a relationship between plaque's location and movement disorders including dystonia was not stated [18]. In our group of patients, a possible association between location of the lesion and dystonia was found in case 2, 4, 7 and 10. In case 8 and 9 only diffuse periventricular lesions were found, probably not related to the blepharospasm, however clinical observation with long-lasting improvement in case 8 may suggest an autoimmune inflammatory origin. Brain MRI of patients 7 and 10 with dystonia of the upper limb showed lesions located in the periventricular white matter as well as in thalamus and pons. A hyperintensive focus in the cervical spinal cord was found in case 4 (cervical dystonia and voice tremor) and 7 (hand dystonia). Magnetic resonance imaging of the cervical spinal cord in case 10 revealed only discopathy at the level of C4/C5 and C5/C6 presumably not related to the movement disorders.

Pseudoathetosis is also a very rare symptom in MS. In our patient, transient involuntary movements of the right hand with coexisting loss of proprioception, clinically indistinguishable from athetosis were diagnosed as pseudoathetosis. Sharp *et al.* [15] postulated that this symptom is usually due to lesion

of the proprioception pathway resulting in the dysfunction of the integration of the deep sensation with motor function with location in the striatum. Magnetic resonance imaging scan of our patient 6 revealed multiple foci in the basal ganglia, and thalamus. Location as well as resembling of the symptoms after 3 months may suggest its autoimmune origin.

There are several reports found in historic neurologic literature of parkinsonian tremor in the course of MS. In two cases reported by Mao *et al.*, no correlations between location of demyelinating lesion and parkinsonism were observed [5]. Remitting parkinsonism presented with focal hypersignal in immediate vicinity of the extrapyramidal tract strongly suggest possibility of a relationship between these two disorders. In our case, a suspected lesion was located in the right nucleus lentiformis. Response to a dopaminergic agonist was very satisfactory in this patient but treatment with corticosteroids during relapse brought to light complete resolution of parkinsonian tremor. It could be explained by hypothesis that PD symptoms may be aggravated by MS plaques, thus explaining the good response to corticosteroids in reported patients.

Next postulated association between parkinsonism and MS suggested that repeated perivenous demyelination in pigmented neurons may provoke chromatolysis and myelinoclastic process in substantia nigra causing PD [7].

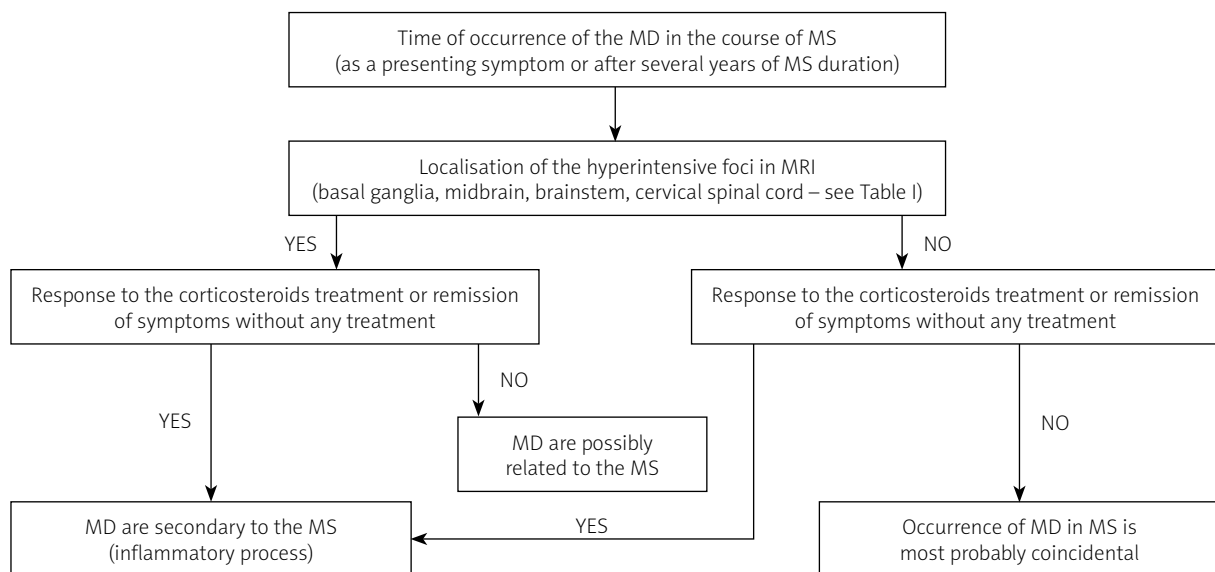


Fig. 8. Algorithm of searching for a causal relationship between movement disorders and multiple sclerosis.



A recently reported case of dystonia/parkinsonism as a presenting symptom of primary progressive MS syndrome showed one more explanation of the association between MD and MS [1,7]. In primary progressive MS both autoimmunological/inflammatory as well as neurodegenerative pathomechanisms are considered. Delgado *et al.* [1] found human anti basal ganglia antibodies in their reported case. This observation confirmed a possible causal relationship between MD and MS. Moreover, during the course of MS, the risk of MD occurrence may increase because neurodegeneration known to be responsible for movement disorders start to be much more pronounced comparing to the inflammatory process. On the other hand, demyelinating lesions are diffuse in time and space and progression of the disease is a risk factor for the new plaques and new, even atypical, symptoms.

In conclusion, searching for the strategic focal lesion in patients with MD and MS might be difficult because of the limitation of the neuroimaging methods. Our case series showed demyelinating plaques placed in the thalamus most often. In the future more accurate methods of magnetic resonance imaging may help find even small lesions in the extrapyramidal tract. Another interesting explanation of the association between MD and MS is response to the treatment. Below we present an algorithm which may help to explain the causal relationship and origin of the symptoms (Fig. 8).

In our opinion, MD are very often secondary to the demyelinating or neurodegenerative process occurring in MS. We suggest that this association should be considered in each case individually. Patients presented in this paper and cases reported in the literature show that MD in MS may have heterogeneous mechanisms and course.

## References

1. Delgado S, Baez S, Singer C, Sengun C, Sheremata WA, Papapetropoulos S. Parkinsonism/dystonia syndrome secondary to multiple sclerosis with anti-basal-ganglia antibodies. *Mov Disord* 2009; 24: 309-311.
2. Espir M, Millac P. Paroxysmal brain stem dysfunction in multiple sclerosis. *Br Med J* 1972; 18: 1503.
3. Klostermann W, Vieregge P, Kömpf D. Spasmodic torticollis in multiple sclerosis: significance of an upper cervical spinal cord lesion. *Mov Disord* 1993; 8: 234-236.
4. Lu CS, Tsai CH, Chiu HC, Yip PK. Pseudoathetosis as a presenting symptom of spinal multiple sclerosis. *J Formos Med Assoc* 1992; 91: 106-109.
5. Mao CC, Gancher ST, Herndon RM. Movement disorders in multiple sclerosis. *Mov Disord* 1988; 3: 109-116.
6. Nagano T, Mizoi R, Watanabe I, Tomi H, Sunohara N. A case of multiple sclerosis manifesting piano playing movement. *Rinsho Shinkeigaku* 1993; 33: 442-445 (abstract).
7. Nelson DA, Paulson GW. Idiopathic Parkinson's disease(s) may follow subclinical episodes of perivenous demyelination. *Med Hypotheses* 2002; 59: 762-769.
8. Nociti V, Bentivoglio AR, Frisullo G, Fasano A, Soleti F, Iorio R, Loria G, Patanella AK, Marti A, Tartaglione T, Tonali PA, Batocchi AP. Movement disorders in multiple sclerosis: Causal or coincidental association? *Mult Scler* 2009; 14: 1284-1287.
9. Plant GT, Kermode AG, du Boulay EP, McDonald WI. Spasmodic torticollis due to a midbrain lesion in a case of multiple sclerosis. *Mov Disord* 1989; 4: 359-362.
10. Polman CH, Reingold SC, Banwell B, Clanet M, Cohen JA, Filippi M, Fujihara K, Havrdova E, Hutchinson M, Kappos L, Lublin FD, Montalban X, O'Connor P, Sandberg-Wollheim M, Thompson AJ, Waubant E, Weinshenker B, Wolinsky JS. Diagnostic criteria for multiple sclerosis: 2010 revisions to the 'McDonald Criteria'. *Ann Neurol* 2011; 69: 292-302.
11. Poser CM, Brinar BB. Diagnostic criteria for multiple sclerosis. *Clin Neurol Neurosurg* 2001; 103: 1-11.
12. Roos RA, Wintzen AR, Vielvoye G, Polder TW. Paroxysmal kinesiogenic choreoathetosis as presenting symptom of multiple sclerosis. *J Neurol Neurosurg Psychiatry* 1991; 54: 657-658.
13. Rüegg SJ, Bühlmann M, Renaud S, Steck AJ, Kappos L, Fuhr P. Cervical dystonia as first manifestation of multiple sclerosis. *J Neurol* 2004; 251: 1408-1410.
14. Seven A, Aslan M, Incir S, Altıntaş A. Evaluation of oxidative and nitrosative stress in relapsing remitting multiple sclerosis: effect of corticosteroid therapy. *Folia Neuropathol* 2013; 51: 56-64.
15. Sharp FR, Rando TA, Greenberg SA, Brown L, Sagar SM. Pseudochoreoathetosis: movement associated with loss of proprioception. *Arch Neurol* 1994; 51: 1103-1109.
16. Spitz M, Costa Machado AA, Carvalho Rdo C, Maia FM, Haddad MS, Calegari D, Scaff M, Reis Barbosa E. Pseudoathetosis: report of three patients. *Mov Disord* 2006; 21: 1520-1522.
17. Svetel M, Ivanović N, Marinković J, Jović J, Dragasević N, Kostić VS. Characteristics of dystonic movements in primary and symptomatic dystonias. *J Neurol Neurosurg Psychiatry* 2004; 75: 329-330.
18. Tranchant C, Bhatia KP, Marsden CD. Movement disorders in multiple sclerosis. *Mov Disord* 1995; 10: 418-423.
19. Tüzün E, Akman-Demir G, Eraksoy M. Paroxysmal attacks in multiple sclerosis. *Mult Scler* 2001; 7: 40-43.
20. Uncini A, Di Muzio A, Thomas A, Lugaresi A, Gambi D. Hand dystonia secondary to cervical demyelinating lesion. *Acta Neurol Scand* 1994; 90: 51-55.