

Does apoptosis occur in amyotrophic lateral sclerosis? TUNEL experience from human Amyotrophic Lateral Sclerosis (ALS) tissues

Barbara Tomik¹, Dariusz Adamek², Piotr Pierchalski³, Steven Banares⁴, Aleksandra Duda³, Dorota Partyka¹, Wiesław Pawlik³, Józef Katuża², Stan Krajewski⁴, Andrzej Szczudlik¹

¹Department of Neurology, Jagiellonian University Medical College, Krakow Poland; ²Department of Neuropathology, Jagiellonian University Medical College, Krakow, Poland; ³Chair of Physiology, Jagiellonian University Medical College, Krakow, Poland; ⁴The Burnham Institute, La Jolla, USA

Folia Neuropathol 2005; 43 (2): 75-80

Abstract

The role that apoptosis plays in the pathogenesis of amyotrophic lateral sclerosis (ALS) is still unclear. From our autopsy samples, we have undertaken an effort to verify if apoptosis in ALS really occurs or if can at least be detected. The study was performed using TUNEL method for screening the apoptotic changes in the autopsy samples from 8 ALS cases compared with 16 control cases. No features of apoptosis (DNA cleavages) were noted in any of the investigated regions of the central nervous system in ALS cases as well as in controls. These preliminary results seem to support the reports, which deny the role of apoptosis in human ALS. The following investigations using additional methods will be performed for detection the apoptotic signals in ALS.

Key words: amyotrophic lateral sclerosis, humans, apoptosis, TUNEL

Introduction

Amyotrophic lateral sclerosis (ALS) is a progressive and fatal neurodegenerative disease characterized by selective loss of motor neurons in the motor cortex, brainstem, and spinal cord [13]. Unfortunately, there is no in vivo, satisfactory noninvasive tool that has excellent performance at assessing motor neuron functional status or number. The mechanisms of cell death for these motor neurons still remain unclear. Different hypotheses based on ALS stu-

dies in humans and on mouse models have varying different pathogenetic processes leading to neurodegeneration in ALS. Some examples of these hypotheses are defective function of glutamate system [18], oxidative stress and mitochondrial dysfunction [2,13,23], autoimmunity or neurotrophic deficit [1,22]. In about 5-10% of ALS, the mutations of the cytosolic Cu/Zn superoxide dismutase (SOD 1) have been found [5,14,18]. Recent studies suggest that the degeneration of motor neurons in ALS could be a form

Communicating author:

Barbara Tomik, MD PhD, Department of Neurology, Jagiellonian University Medical College, Botaniczna 3, 31-503 Krakow, Poland, tel. +48 12 424 86 00, fax +48 12 424 86 26, e-mail: tomik@neuro.cm-uj.krakow.pl

Table I. ALS patients characteristics (n= 8)

Age at death	65.2±4.2 yr (mean ±SD) (range: 61-72 yr)
Postmortem delay	21±4.3 h (range: 20-23 h)
Gender	female n=5, male n=3
Type of onset	bulbar onset n=3 limb onset n=5

of apoptotic cell death (programmed cell death, PCD) [2,3,6,8,10,12-14,23,25,26].

Apoptosis, in contrast to necrosis, a passive process, is an energy dependent process characterized by cytoplasmic membrane blebbing with cytoplasmic chromatin condensation and fragmentation and cell surface alterations [23]. The induction of apoptosis requires the activation of specific members of CED-3/ICE family proteases (caspases) [8,23]. There are two primary pathways of apoptosis induction leading to the cleavage of inactivate procaspases into active "protein-killers": (a) a pathway involving the activation of cell death receptors of the TNF family (e.g., Fas/CD95, type I TNF receptor and death receptor 3) and (b) the induction of the mitochondrial pathway. In the first case, coupling of death receptors with their ligands, leads finally to activation of procaspase-8. Activated caspase-8, in turn, switches on the downstream effector caspases such as caspase-3, -6, and -7 [10,23]. The induction of the mitochondrial pathway via intracellular stimuli (DNA damage or loss of growth factor signals), leads to the release of cytochrom c into the cytosol and the activation of apoptotic protease-activating factor-1 (Apaf-1) [10,23]. There is rapidly increasing evidence of mitochondrial control of the specific apoptosis pathways which may play a crucial role in mechanism of death of motor neurons in ALS [2,3,14,19]. However, it remains unknown whether neuronal death in ALS is due to apoptotic mechanisms. [7,23].

We have undertaken an effort to check in our own material whether apoptosis (DNA fragmentation) in ALS really occurs or at least whether apoptosis alone can be detected.

Material and methods

Frozen, unfixed samples taken during routine autopsies from the motor cortex, medulla and spinal cord of 8 patients who died from sporadic (no positive familial history of the disease) ALS and from 16 patients who died in years 2000-2004 due to other

diseases were stored consecutively and cryo preserved in minus 80°C. In addition to the samples taken and stored unfixed in minus 80°C, other samples were taken from the motor cortex, other regions of brain hemispheres, from basal ganglia, cerebellum, mid-brain, pons, medulla and three levels of spinal cord. These were fixed in formalin and routinely processed into paraffin blocks, cut by microtome and stained by HE and Kluver-Barrér methods for myelin. In slides from the motor cortex, medulla and spinal cord immunohistochemistry was applied with antibody against ubiquitin. In all ALS cases, patients died due to respiratory failure at the Neurological Department of Jagiellonian University in Krakow and were autopsy-confirmed according to El Escorial criteria [4]. Particularly, the histopathological examination of samples from spinal cords and medulla in all cases showed significant loss of motor neurons. The loss of neurons was predominately located in samples from the motor cortex and/or the typical palor of pyramidal tracts in slides stained for myelin was noted. In most cases, ubiquitin-positive inclusions were found either in anterior horns of spinal cord or in motor nuclei of cranial nerves of the medulla. They were usually in the form of small cytoplasmic Bunina-body-like or skein-type deposits. No Lewy-body type inclusions or any conspicuous Alzheimer-type pathology was found in any case. The control group consisted of two patients with stroke, two with subdural haematoma, three with non-Hodgkin's lymphoma, five with malignant glioma, two with metastatic tumor, one with GM2-gangliosidosis, and one with Jakob-Creutzfeldt disease. In all of these cases, no pathology consistent with the criteria for ALS was found. Jakob-Creutzfeldt disease was confirmed both by typical histopathological changes and by positive immunohistochemistry for proteinase-resistant prion protein. The mean age of death was 65.2±4.2 years in the ALS group and 63.7±2.2 years (mean ±SD) in the control group. The difference was not statistically significant. Brain tissue was taken from both groups with posmortem delay time between death and snap freezing 21±4.3 hours in ALS patients and 22.9±3.6 hours (mean ±SD) in the control group, again without significant difference (table I, II). The collection of brain samples were examined by TUNEL method for detection of apoptosis in 2004. The study was approved by the Bioethical Committee of Jagiellonian University, Krakow, KBET78/B/2001.

Table II. The control group characteristics (n=16)

Age at death	63.7±2.2 yr (mean ±SD) (range: 56-74 yr)
Postmortem delay	22.9±3.6 h, (range: 19-23 h)
Gender	female n=9, male n=7
Type of disease	stroke n=2, subdural haematoma n=2, non-Hodgkin's lymphoma n=3, malignant glioma n=5, metastatic tumor n=2, GM2-gangliosidosis n=1, Jakob-Creutzfeldt disease n=1

TUNEL method

Cleavage of genomic DNA during apoptosis may yield double-stranded, low molecular weight DNA fragments (mono- and oligonucleosomes) as well as single strand breaks ('nicks') in high molecular weight DNA. Those DNA strand breaks can be identified by labeling free 3'-OH termini with modified nucleotides in an enzymatic reaction.

Terminal deoxynucleotidyl transferase (TdT), which catalyzes polymerization of nucleotides to free 3'-OH DNA ends in a template-independent manner, is used to label DNA strand breaks. Fluorescein labels incorporated in nucleotide polymers were detected and quantitated by fluorescence microscopy. Frozen tissue sections were fixed for 20 minutes in 4% paraformaldehyde solution and washed twice for 30 minute in PBS at room temperature.

Slides were incubated in permeabilisation solution (0.1% TritonX100, 0.1% sodium citrate) for two minutes on ice and rinsed twice in PBS. Fifty milliliters of TUNEL reaction mix was added and slides were incubated for 60 minutes in a humidified dark chamber. Slides were rinsed three times in PBS. All TUNEL slides were screened directly for apoptotic neurons changes using the fluorescent microscope-computer system.

Results

Although significant neuron loss was evident in ALS cases, no features of apoptosis (DNA cleavages) were detected in any of the investigated regions of the central nervous system in ALS cases as well as in controls. In many neurons, conspicuous lipofuscin deposits with strong yellowish fluorescence were noted (see Fig. 1-7).

Discussion

Utilization of the TUNEL method demonstrated no features of apoptosis (DNA cleavages) in any of

the samples taken during autopsy from the motor cortex, medulla, and spinal cord of 8 ALS patients. No apoptosis was also detected in any of the compatible brain samples taken from the motor cortex, medulla, and spinal cord of the control group. Therefore, the question arises whether apoptosis is involved in neurodegeneration of human ALS, or whether we are unable to detect the apoptotic changes.

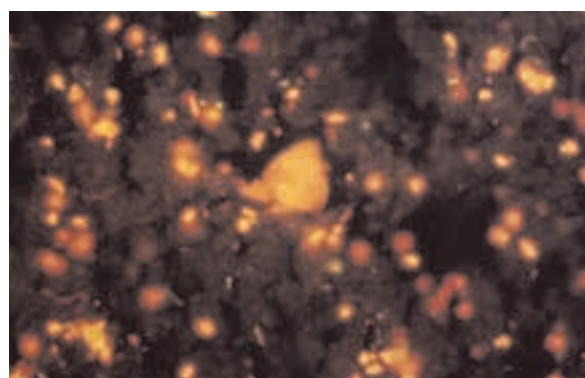


Fig. 1. ALS – anterior horn. Only one preserved large motor neuron is visible. Obj. magn. 20x

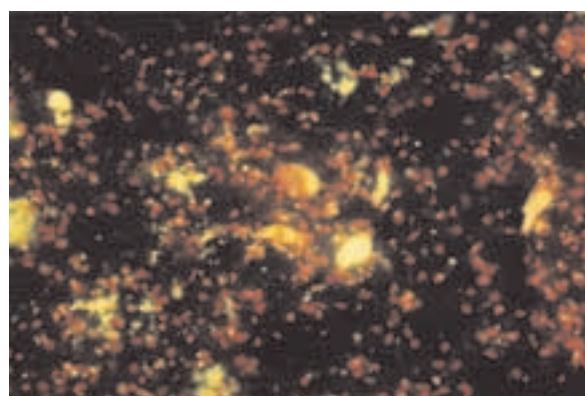


Fig. 2. ALS – anterior horn. A group of motor neurons, some of them rich in lipofuscin and showing different stages of degeneration, but apparently not signs of apoptosis. Obj. magn. 20x




Fig. 3. ALS – anterior horn. One of 2 motor neurons is being disintegrated but apparently not due to apoptosis. Obj. magn. 40x

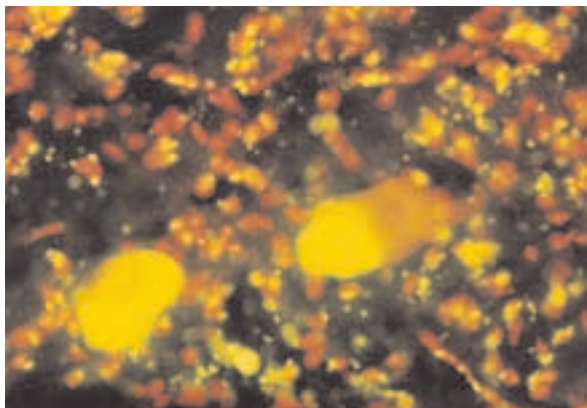


Fig. 4. ALS – anterior horn. Degeneration of motor neurons with chromatolysis and with lipofuscin overloading (relatively typical findings in ALS). Obj. magn. 40x

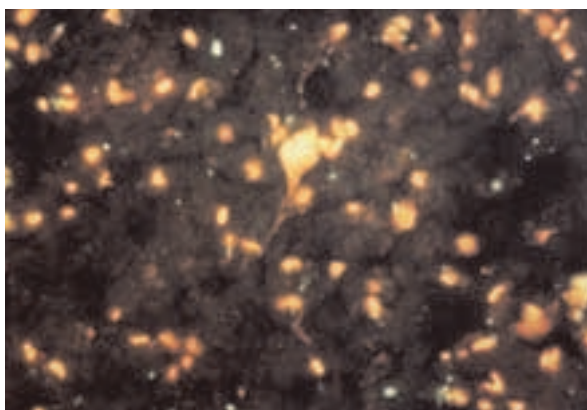


Fig. 5. ALS – motor cortex. Loss of neurons. Obj. magn. 20x

Most of the evidence suggesting a role for apoptosis in ALS involves study of the SOD1 protein using in vitro and mouse models [8,10,12-14]. There are conflicting data regarding the occurrence of apoptotic pathways in ALS in humans in the literature. In a chronic neurodegenerative disease such as ALS, conclusive evidence of apoptosis is likely to be difficult to detect, given the rapidity of the apoptotic cell death process in relation to the relatively slow time course of the disease [10]. However, Yoshiyama [29] has detected DNA fragmentation in autopsy spinal cord samples only from 9 ALS patients, but not in ten control samples. Also, Troost et al. [25,26] reported that examination of ALS spinal cord has shown evidence for apoptosis by TUNEL stain. Supportive studies of apoptotic related proteins have revealed decreased antiapoptotic Bcl-2 mRNA and increased proapoptotic Bax mRNA in spinal neurons [25,26]. Also Troost et al. [25] have found immunocytochemically increased Bcl-2 in the nuclei of neurons and in their cytoplasm in brain and spinal cord of ALS patients. Ekegren et al. [6] have showed upregulation of the cell death promoting protein Bax and increased DNA degradation, indicative of apoptosis, in spinal motor neurons of ALS patients. Martin et al. [13] detected the occurrence of intranucleosomal DNA fragmentation in affected ALS brain region (motor cortex, spinal cord) but not in spared brain regions such as somatosensory cortex. These results were confirmed by detection of intranucleosomal fragmentation of DNA in anterior horn gray matter of the spinal cord and motor cortex from ALS cases by gel electrophoresis [13].

In contrast, Migheli et al. [16,17] have failed to provide any evidence of intranucleosomal cleavage of DNA in postmortem tissue from human and animal ALS material. Also, He and Strong [9] reported that degenerating motor neurons in ALS, identified by ubiquitin immuno-reactivity, did not demonstrate the morphological characteristic of apoptosis and were not TUNEL positive or c-Jun immunoreactive. They demonstrated the lack of apoptosis in ALS spinal motor neurons and suggested that this observation does not relate to the utilization of post-mortem tissue in which apoptotic neurons may have been lost [9]. In 2001, Emabcher et al. [7], also did not find evidence for apoptosis as a major mechanism of motor neuronal cell death in sporadic ALS. They were studying the expression and distribution patterns of pro- and anti-apoptotic bcl-2 family mem-

bers as well as the executioner caspase-3 in post-mortem brain tissue of 8 sporadic ALS patients and 7 age-matched controls. The authors found that sparse motor neurons were immunoreactive for Bcl-2, Bax, Bak, and CM1 on serial sections through the spinal cord and motor cortex of singular ALS patients and controls, although there was no significant difference in the number of immunoreactive neurons between ALS and control groups.

Although the role of apoptosis in the loss of motor neurons in humans ALS remains controversial, the presented results seem to support the reports, which deny the role of apoptosis processes in human ALS [7,9,16,17]. This observation was also confirmed by negative results of clear apoptotic changes in human material from different neurodegeneration diseases such as PD and LBD [11,24,27,28]. On the other hand, it is noteworthy to mention that though TUNEL is a popular method for the detection of apoptotic cells, DNA fragmentation detected by in situ method (e.g., TUNEL) also occurs in nonapoptotic cell death such as necrosis [8]. Thus, the TUNEL method, a sensitive tool for detection of apoptosis, should be granted with limited credit.

Conclusions

Either apoptosis (detected by TUNEL) is not involved in pathogenesis of ALS, or the process of apoptosis is absent in the terminal stage of disease or else it is simply extremely elusive. The chances of catching 'a suspected culprit' may be small considering that apoptosis is a relatively rapid phenomenon and at the terminal stage of disease not many neurons remain in the most 'sensitive' regions of the central nervous system.

The presented study is a part of our ongoing work on the occurrence of apoptotic neurons changes and expression of pro-apoptotic, BH3 only proteins from the Bcl-2 protein family and their role in the induction of mitochondrial apoptosis in ALS.

Future directions

We are studying the expression of mRNA of Bcl-2, Bcl-x (L), Bax, Bad, Bak, Bid, Bik and ICE/kaspazy-1 by using rt-PCR method, and the expression of anti- and proapoptotic (Bcl-2 and Bcl-x (L) and Bax, Bad, Bak, Bid, Bik) proteins as well as the expression of the proteolytic proteins by using Western-blot now. The results will be published soon.

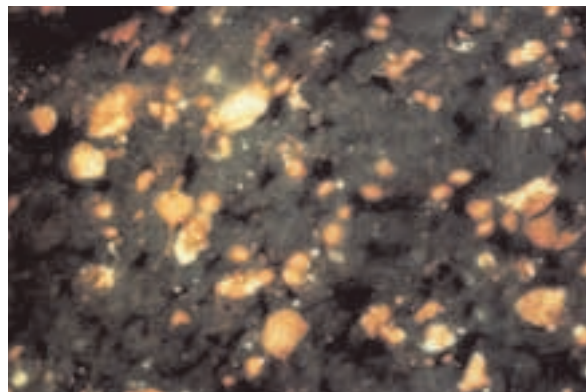


Fig. 6. Control case, – motor cortex. There is no apparent loss of neurons. Obj. magn. 20x

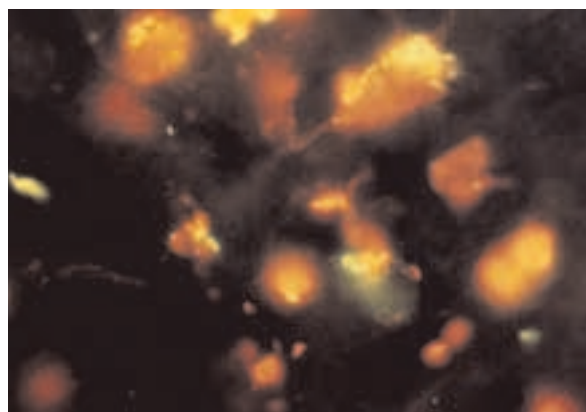


Fig. 7. Control case, anterior horn. No signs of the loss of neurons. Obj. magn. 40x

Acknowledgements

The work has been supported by grants from Polish Committee for Scientific Research (No KBN 3 P05A 014 22 and KBN 7-T11E-020-21) and NIH NS36821 for SK.

References

1. Appel SH. A unifying hypothesis for the cause of amyotrophic lateral sclerosis, parkinsonism, and Alzheimer disease. *Ann Neurol* 1981; 6: 499-505.
2. Beal MF. Mitochondria and the pathogenesis of ALS. *Brain* 2000; 123: 1291-1292.
3. Borthwick GM, Johnson MA, Ince PG, Shaw PJ, Turnbull DM. Mitochondrial enzyme activity in amyotrophic lateral sclerosis: implications for the role of mitochondria in neuronal cell death. *Ann Neurol* 1999; 46: 787-790.
4. Brooks. El Escorial World Federation of Neurology criteria for the diagnosis of amyotrophic lateral sclerosis. Subcommittee

- on Motor Neuron Diseases/Amyotrophic Lateral Sclerosis of the World Federation of Neurology Research Group on Neuromuscular Diseases and the El Escorial 'Clinical limits of amyotrophic lateral sclerosis' workshop contributors. *J Neurol Sci* 1994; 124 Suppl: 96-107.
5. Deng HX, Hentati A, Tainer JA, Iqbal Z, Cayabyab A, Hung WY, Getzoff ED, Hu P, Herzfeldt B, Roos RP. Amyotrophic lateral sclerosis and structural defects in Cu, Zn superoxide dismutase. *Science* 1993; 261: 1047-1051.
 6. Ekegren T, Grundstrom E, Lindholm D and Aquilonius SM. Upregulation of Bax protein and increased DNA degradation in ALS spinal cord motor neurons *Acta Neurol Scand* 1999; 100: 317-321.
 7. Embacher N, Kaufmann WA, Beer R, Maier H, Jellinger KA, Poewe W, Ransmayr G. Apoptosis signals in sporadic amyotrophic lateral sclerosis: an immunocytochemical study. *Acta Neuropathol (Berl)* 2001; 102: 426-434.
 8. Guegan C, Przedborski S. Programmed cell death in amyotrophic lateral sclerosis. *J Clin Invest* 2003; 111: 153-161.
 9. He BP, Strong MJ. Motor neuronal death in sporadic amyotrophic lateral sclerosis (ALS) is not apoptotic. A comparative study of ALS and chronic aluminium chloride neurotoxicity in New Zealand white rabbits. *Neuropathol Appl Neurobiol* 2000; 26: 150-160.
 10. Honig LS, Rosenberg RN. Apoptosis and neurologic disease. *Am J Med* 2000; 108: 317-330.
 11. Jellinger KA. Cell death mechanisms in Parkinson's disease. *J Neural Transm* 2000; 107: 1-29.
 12. Julien JP, Beaulieu JM. Cytoskeletal abnormalities in amyotrophic lateral sclerosis: beneficial or detrimental effects? *J Neurol Sci* 2000; 180: 7-14.
 13. Martin LJ, Kaiser A, Price AC. Motor neuron degeneration after sciatic nerve avulsion in adult rat evolves with oxidative stress and is apoptosis. *J Neurobiol* 1999; 40: 185-201.
 14. Martin LJ. p53 is abnormally elevated and active in the CNS of patients with amyotrophic lateral sclerosis. *Neurobiol Dis* 2000; 7: 613-622.
 15. Martin LJ, Price AC, Kaiser A, Shaikh AY, Liu Z. Mechanisms for neuronal degeneration in amyotrophic lateral sclerosis and in models of motor neuron death (Review). *Int J Mol Med* 2000; 5: 3-13.
 16. Migheli A, Cavalla P, Marino S, Schiffer D. A study of apoptosis in normal and pathologic nervous tissue after in situ end-labeling of DNA strand breaks. *J Neuropathol Exp Neurol* 1994; 53: 606-616.
 17. Migheli A, Atzori C, Piva R, Tortarolo M, Girelli M, Schiffer D, Bendotti C. Lack of apoptosis in mice with ALS. *Nat Med* 1999; 5: 966-967.
 18. Mulder DW, Kurland LT, Offord KP, Beard CM. Familial adult motor neuron disease: amyotrophic lateral sclerosis. *Neurology* 1986; 36: 511-517.
 19. Robberecht W. Oxidative stress in amyotrophic lateral sclerosis. *J Neurol* 2000; 247 Suppl 1: I1-6.
 20. Rosen DR, Siddique T, Patterson D, Figlewicz DA, Sapp P, Hentati A, Donaldson D, Goto J, O'Regan JP, Deng HX. Mutations in Cu/Zn superoxide dismutase gene are associated with familial amyotrophic lateral sclerosis. *Nature* 1993; 362: 59-62.
 21. Rothstein JD. Excitotoxicity and neurodegeneration in amyotrophic lateral sclerosis. *Clin Neurosci* 1995-96; 3: 348-359.
 22. Smith RG, Siklos L, Alexianu ME, Engelhardt JI, Mosier DR, Colom L, Habib Mohamed A, Appel SH. Autoimmunity and ALS. *Neurology* 1996; 47 (4 Suppl 2): S40-5.
 23. Strong MJ. The basic aspects of therapeutics in amyotrophic lateral sclerosis. *Pharmacol Ther* 2003; 98: 379-414.
 24. Tatton WG, Chalmers-Redman R, Brown D, Tatton N. Apoptosis in Parkinson's disease: signals for neuronal degradation. *Ann Neurol* 2003; 53 Suppl 3: S61-70.
 25. Troost D, Aten J, Morsink F and de Jong JM. Apoptosis in amyotrophic lateral sclerosis is not restricted to motor neurons. Bcl-2 expression is increased in unaffected post-central gyrus. *Neuropathol Appl Neurobiol* 1995; 21: 498-504.
 26. Troost D, Aten J, Morsink F and de Jong JM. Apoptosis in ALS is not restricted to motoneurons: Bcl-2 expression is increased in post-central cortex, adjacent to the affected motor cortex. *J Neurol Sci* 1995; 129 Suppl: 79-80.
 27. Tortosa A, Lopez E, Ferrer I. Bcl-2 and Bax proteins in Lewy bodies from patients with Parkinson's disease and Diffuse Lewy body disease. *Neurosci Lett* 1997; 238: 78-80.
 28. Wullner U, Kornhuber J, Weller M, Schulz JB, Loschmann PA, Riederer P, Klockgether T. Cell death and apoptosis regulating proteins in Parkinson's disease—a cautionary note. *Acta Neuropathol (Berl)* 1999; 97: 408-412.
 29. Yoshiyama Y, Yamada T, Asanuma K, Asahi T. Apoptosis related antigen, Le (Y) and nick-end labeling are positive in spinal motor neurons in amyotrophic lateral sclerosis. *Acta Neuropathol (Berl)* 1994; 88: 207-211.