

Paraneoplastic encephalomyelitis/sensory motor peripheral neuropathy – an autopsy case study

Barbara Gazic¹, Joze Pizem², Leja Dolenc-Groselj³, Viktor Svigelj³, Mara Popovic²

¹Department of Pathology, Institute of Oncology, Ljubljana, Slovenia; ²Medical Faculty, Institute of Pathology, University of Ljubljana, Slovenia; ³Department of Neurology, Medical Centre, Ljubljana, Slovenia

Folia Neuropathol 2005; 43 (2): 113-117

Abstract

Paraneoplastic neurological anti-Hu syndrome is one of the most frequent remote effects of cancer and usually manifests as encephalomyelitis combined with peripheral neuropathy. Subacute sensory neuronopathy, which results from the inflammatory destruction of sensory neurone cell bodies in the dorsal root ganglia, is thought to be the principal presentation of peripheral neuropathy. In addition to sensory involvement, evidence of motor nerve involvement is frequently found. The mechanisms of motor involvement remain largely unclear and there have been only a limited number of pathological studies. We present an autopsy case study of anti-Hu paraneoplastic encephalomyelitis/sensory-motor neuropathy, which confirms an inflammatory paraneoplastic destruction of sensory neuron cell bodies in the dorsal root ganglia and lower motor neurons in the spinal cord, as a cause of clinically rapidly progressive peripheral sensory-motor neuropathy.

Key words: *paraneoplastic syndrome, anti-Hu antibodies, motor neuropathy, encephalomyelitis*

Introduction

Paraneoplastic neurological anti-Hu syndrome is one of the most frequent remote manifestations of cancer and in 61-87% of cases is associated with, usually an occult, small cell lung cancer [3,4,6,7,9]. It manifests predominantly as encephalomyelitis combined with peripheral neuropathy and, rarely, encephalomyelitis alone or peripheral neuropathy alone [3,4,6]. Subacute sensory neuronopathy (SSN), which results from the inflammatory destruction of sensory neurone cell bodies in the dorsal root ganglia, is thought to be the principal presentation of

peripheral neuropathy [8]. In a published series of anti-Hu syndrome, peripheral neuropathy has been clinically found purely sensory in approximately 70%, sensory-motor in 10-40%, and even purely motor in rare cases. Motor involvement can be severe and can progress to a generalised weakness and respiratory insufficiency in a significant proportion of cases [4,6,7,9]. Moreover, in a recent study, it has been shown that the typical SSN pattern, consisting of a clinically and electrophysiologically pure sensory involvement, is relatively rarely encountered (30% of cases) and that in the majority of patients with

Communicating author:

Joze Pizem, Institute of Pathology, Medical Faculty, Korytkova 2, 1000 Ljubljana, Slovenia, phone +386 (0) 1 5437163; fax +386 (0) 1 5437104, e-mail: joze.pizem@mf.uni-lj.si

clinically pure sensory neuropathy, electrophysiological signs of motor nerve involvement are observed [3].

The frequent association of motor and sensory involvement in anti-Hu syndrome suggests that the pathological process is not restricted to the dorsal root ganglia and is probably more complex. Electrophysiological studies can give some insights into the pathological process; however, there have been only a limited number of pathological studies and information regarding motor nerve involvement remains insufficient [3].

We present an autopsy case study of anti-Hu paraneoplastic encephalomyelitis/sensory-motor neuropathy, which confirms an inflammatory paraneoplastic destruction of sensory neuron cell bodies in the dorsal root ganglia and lower motor neurons in the spinal cord, as a cause of clinically rapidly progressive peripheral sensory-motor neuropathy in an anti-Hu positive patient.

Materials and methods

Autopsy tissue samples were fixed in 10% formalin, embedded in paraffin and routinely stained with haematoxylin and eosin (H&E). Klüver-Barrera staining was performed to highlight myelin. Additionally, sural nerve specimens were frozen for immunofluorescence and fixed in 2.5% glutaraldehyd and osmium tetra oxide for semi thin and ultra thin sections.

Immunohistochemical analysis was performed using the avidin-biotin-peroxidase technique. The following primary antibodies (DakoCytomation, Denmark) were used: anti-CD3, anti-CD4, anti-CD8, anti-CD20, anti-CD68 and anti-neurofilament. Frozen sections of the sural nerve were stained with FITC-labelled antibodies (DakoCytomation, Denmark) to human IgA, IgG, IgM, C3, C1q and fibrin/fibrinogen.

Results

Clinical history

A 68-year-old woman with no previous history of neurological disease was admitted to the hospital with a two-month history of weight loss, parasthesias in the legs, cramps in the abdomen and a newly developed right facial nerve palsy. At the beginning of hospitalisation the patient seemed to understand simple questions and reactions were adequate but with occasional signs of mental disturbances. During hospitalisation the clinical picture worsened with

ascending parasthesias in the limbs and progressive paresis. Two weeks after admission, the patient became triparetic with absent miotatic reflexes and she needed mechanical ventilation. A cerebrospinal fluid analysis revealed albumino-cytological dissociation (proteins 1.19 g/l, 6 lymphocytes/ μ l). An acute poliradiculonevritis was suspected and the patient received intravenous immunoglobulins, followed by ten successive immuno-adsorption therapies, but the clinical situation even worsened.

Electromyographic studies two weeks after admission revealed a severe generalised sensory-motor axonal polyneuropathy, which progressed rapidly during next weeks. EEG was abnormal showing diffuse slowness of general activity, a finding compatible with diffuse encephalopathy. A CT scan showed a 5 mm large lesion in the upper lobe of the right lung, suspicious for a tumour. Because paraneoplastic syndrome was suspected, serum and CSF were examined for paraneoplastic antibodies. Anti-Hu antibodies (IgG) were found in both fluids, while other specific antineuronal antibodies, including anti-CV2, anti-Yo, anti-Ri and anti-Tr were negative. The patient died after four months of hospitalisation.

Pathological findings

At autopsy, a small cell carcinoma was found in the upper right lobe of the lung, measuring 15x20 mm and metastasizing into a regional lymph node. In the brain, single neuron destruction with neuronophagia, microglial nodules and perivascular inflammatory cell cuffing were common findings on haematoxilin and eosin stained sections, changes consistent with paraneoplastic encephalitis. Immunohistochemistry showed a predominance of CD8+ cytotoxic T-lymphocytes, some of them surrounding single neurons. Inflammatory changes and neuronal destruction were unevenly distributed; among histological samples examined, they were found in the hippocampus and basal ganglia but not in the cingulate gyrus and cerebellum. No metastatic infiltration of the brain or spinal cord was found.

In the spinal cord, Wallerian degeneration in the dorsal columns, highlighted by immunohistochemical staining with anti-neurofilament antibodies and myelin staining, was present. The number of alpha motor neurons in the anterior horns was prominently decreased in samples from cervical and thoracic segments (Fig. 1a), but the decrease was less

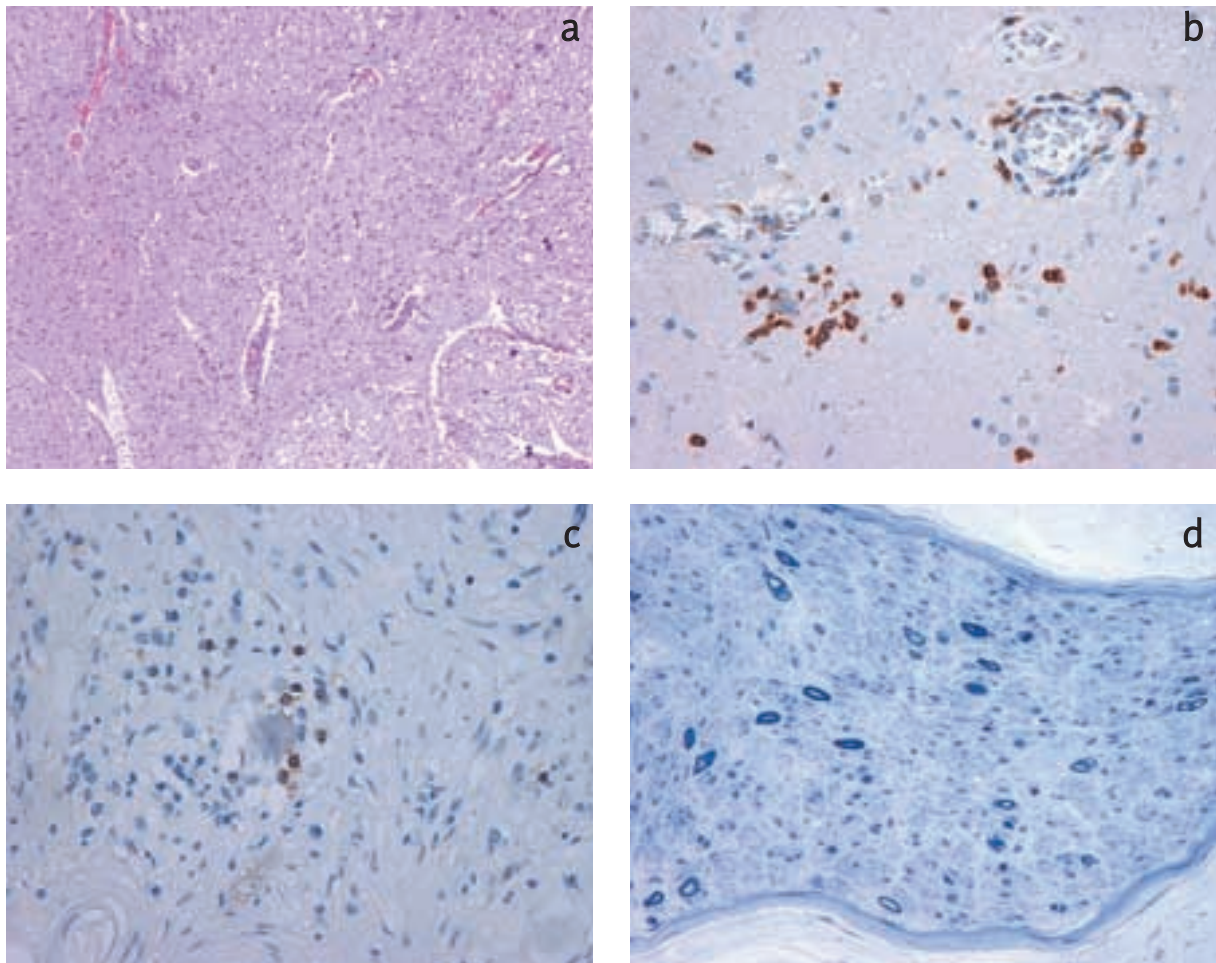


Fig. 1. Histopathological findings in the central and peripheral nervous system: **a.** Only a few alpha motor neurons in the anterior horns of the spinal cord (upper left part of the figure) are preserved (H&E); **b.** There is prominent infiltration of CD8+ cytotoxic T-lymphocytes, which attack an alpha motor neuron cell body (immunohistochemistry); **c.** An attack of CD8+ cytotoxic T-lymphocytes on dorsal root ganglion cells; **d.** On a semi thin section, the number of myelinated axons in the sural nerve is dramatically reduced; three regenerating clusters are noted

pronounced in the lumbar segment. Occasional small clusters of mononuclear cells were seen in the anterior horns and perivascular lymphocytic infiltrate was noted predominantly in the anterior horns and posterior columns. Immunohistochemistry revealed that among lymphocytes, CD8+ cytotoxic T-lymphocytes predominated and only very occasional CD4+ helper T- or B-lymphocytes were found, mostly around small vessels. CD8+ cells infiltrated predominantly the anterior horns and posterior columns, while they were less prominent or almost absent in other parts of the spinal cord. CD8+ cells were clustered around vessels and neurons in the

anterior horns, indicating an attack of CD8+ cells on alpha motor neurons (Fig. 1b). Glial proliferation and numerous CD68+ macrophages were seen throughout the spinal cord. Macrophages were most abundant in the posterior columns, somewhat less in the anterior horns and least in other parts of the spinal cord.

The number of ganglion cells in the dorsal root ganglia was decreased. Nageotte's nodules were formed on the sites of destroyed neurons. Focal mononuclear cell infiltration was present. Immunohistochemical staining showed numerous CD8+ cytotoxic T-lymphocytes, frequently in contact with sensory neurons (Fig. 1c), while CD4+ T- and

B-lymphocytes were very rare. Numerous CD68+ macrophages were present throughout the ganglion.

On semi thin and ultra thin sections, a dramatically decreased number of myelinated axons, without an obvious inflammatory reaction, was found in the sural nerve (Fig. 1d). Few signs of axonal regeneration (couples of myelinated axons), but no signs of remyelination were noted. Only occasional CD8+ T-cells were found in the endoneurium while CD4+ T- and B-cells were absent. There was only focal and inconspicuous perivascular inflammation and no deposition of immunoreactants.

In sensory and motor roots of different levels, the number of axons was obviously decreased. No inflammation was noted in H&E sections, although immunohistochemistry revealed some scattered CD8+ T-cells and an increased number of CD68+ macrophages in the endoneurium of motor and sensory roots.

Discussion

While SSN has been considered a classical manifestation of paraneoplastic peripheral neuropathy with anti-Hu antibodies, it is now clear that, in addition to sensory involvement, evidence of motor nerve involvement is frequently found as a clinically predominant, co-dominant, minor or silent manifestation [3,6].

Sensory neuropathy results from the destruction of sensory neurone cells in the dorsal root ganglia, mediated by an attack of the cell immune system, as evidenced by electrophysiological and histological studies. Inflammatory cell infiltrate, composed predominantly of CD8+ cytotoxic T lymphocytes and macrophages, along with ganglion cell destruction is found in dorsal root ganglia [3,8].

On the other hand, the mechanism of motor involvement remains largely unclear. In a recent study of 20 patients, electrophysiological evidence of motor nerve involvement was found in 53.3% of 145 motor nerves tested. Among them, an abnormal electrophysiological pattern was axonal/demyelinating in 50%, axonal/neuronal in 44% and demyelinating in 6% [3]. These findings indicate that pathological mechanisms of motor involvement are fairly complex and involve lower motor neurones at different levels and probably by different mechanisms. Based on very rare case report studies, several mechanisms have been suggested, including loss of the motor neurone in the anterior horn of the spinal cord, dysfunction of

the axon-Schwann cell relationship and nerve vasculitis leading to demyelination [1,3,5].

In a case of anti-Hu sensory-motor neuropathy, Eggers et al. found electrophysiological evidence of demyelination, perivascular lymphocytic infiltrate, lipid laden macrophages in the endo- and perineurium and a reduction of large myelinated fibres in a biopsy of the sural nerve. They suggested a microvasculitic pathogenetic mechanism [5]. Antoine et al. reported an autopsy case in which chronic demyelinating and remyelinating lesions, axonal degeneration and T-cell/macrophage infiltration in roots, plexus and nerves were superimposed on typical histopathological changes of paraneoplastic encephalomyelitis and SSN (inflammatory destruction of dorsal root ganglion cells) [1]. It remains unclear whether, in both cases, the pathological mechanism of peripheral neuropathy lies within the same spectrum and is reminiscent of chronic inflammatory demyelinating polyneuropathy [1,5,8]. Such reports show that other mechanisms than dorsal root neuron destruction exist, regardless of their true nature, but because of limited evidence it is not known whether they are common or merely coincidental findings. The peripheral nerve involvement may be explained by a specific immune response directed against still unknown peripheral nerve antigens, or depend on non-specific inflammatory mechanisms which can damage the axons or Schwann cells directly [3]. A mixed axonal/demyelinating sensory-motor neuropathy could be associated with the presence of other paraneoplastic antibodies in addition to anti-Hu, such as anti-CV2, which react with the peripheral nerve antigens, and the presence of such antibodies could modify the clinical picture [2].

Although motor neurone destruction in the spinal cord is considered to be the usual cause of the motor deficit in anti-Hu peripheral neuropathy, it has been histologically documented in only a few autopsy cases [4,8,10]. In the present autopsy case, we showed that two principal mechanisms were involved in the pathogenesis of peripheral sensory-motor polyneuropathy – dorsal root ganglionitis with destruction of ganglion cells and, predominantly anterior horn myelitis with destruction of alpha motor neurones. In both cases the destruction of neuron cell bodies seemed to be mediated by a direct attack of CD8+ cytotoxic T-lymphocytes. Destruction of alpha motor neurones can be considered a manifestation of encephalomyelitis, the location

and severity of which is known to vary among patients and usually involves multiple areas [6].

Two further findings in our case indicate that, in addition to the destruction of peripheral neuron cell bodies, pathological mechanisms at the level of the roots and peripheral nerves might play a role in the pathogenesis of paraneoplastic peripheral neuropathy. The signs of axonal regeneration in the sural nerve could indicate damage at the level of axons. The presence of CD8+ cytotoxic T-lymphocytes in the endoneurium of sural nerve and sensory as well as motor roots indicates an immune mediated mechanism, although its significance remains unclear.

Acknowledgments

We would like to thank dr. Francesco Grauss from Barcelona (Spain) for the testing of anti-neuronal antibodies.

References

1. Antoine JC, Mosnier JF, Honnorat J, Convers P, Absi L, Lapras J, Michel D. Paraneoplastic demyelinating neuropathy, subacute sensory neuropathy, and anti-Hu antibodies: clinicopathological study of an autopsy case. *Muscle Nerve* 1998; 21: 850-857.
2. Antoine JC, Honnorat J, Camdessanche JP, Magistris M, Absi L, Mosnier JF, Petiot P, Kopp N, Michel D. Paraneoplastic anti-CV2 antibodies react with peripheral nerve and are associated with a mixed axonal and demyelinating peripheral neuropathy. *Ann Neurol* 2001; 50: 688-691.
3. Camdessanche JP, Antoine JC, Honnorat J, Vial C, Petiot P, Convers P, Michel D. Paraneoplastic peripheral neuropathy associated with anti-Hu antibodies. A clinical and electrophysiological study of 20 patients. *Brain* 2002; 125: 166-175.
4. Dalmau J, Graus F, Rosenblum MK, Posner JB. Anti-Hu-associated paraneoplastic encephalomyelitis/sensory neuronopathy. A clinical study of 71 patients. *Medicine (Baltimore)* 1992; 71: 59-72.
5. Eggers C, Hagel C, Pfeiffer G. Anti-Hu-associated paraneoplastic sensory neuropathy with peripheral nerve demyelination and microvasculitis. *J Neurol Sciences* 1998; 155: 178-181.
6. Graus F, Keime-Guilbert F, Rene R, Benyahia B, Ribalta T, Ascaso C, Escaramis G, Delattre JY. Anti-Hu-associated paraneoplastic encephalomyelitis: analysis of 200 patients. *Brain* 2001; 124: 1138-1148.
7. Lucchinetti CF, Kimmel DW, Lennon VA. Paraneoplastic and oncologic profiles of patients seropositive for type 1 antineuronal nuclear autoantibodies. *Neurology* 1998; 50: 652-657.
8. Rudnicki S, Dalmau J. Paraneoplastic syndromes of the spinal cord, nerve, and muscle. *Muscle Nerve* 2000; 23: 1800-1818.
9. Smitt PS, Grefkens J, de Leeuw B, van den Bent M, van Putten W, Hooijkaas H, Vecht C. Survival and outcome in 73 anti-Hu positive patients with paraneoplastic encephalomyelitis/sensory neuronopathy. *J Neurol* 2002; 249: 745-763.
10. Verma A, Berger JR, Snodgrass S, Petito C. Motor neuron disease: a paraneoplastic process associated with anti-Hu antibody and small-cell lung carcinoma. *Ann Neurol* 1996; 40: 112-116.