

# Low-frequency repetitive transcranial magnetic stimulation to the right Broca mirror area for improving auditory comprehension in a sensory aphasia after stroke: a case report

Qing-qing Liu<sup>1</sup>, Wei-bo Li<sup>2</sup>, Zhen-biao Zhao<sup>3</sup>, Wei-guo Zhang<sup>4</sup>, Pei-yuan Lv<sup>5</sup>, Yu-hui Yang<sup>3</sup>, Yu Yin<sup>3</sup>

<sup>1</sup>Graduate School of Hebei Medical University, Shijiazhuang, China, <sup>2</sup>Department of Gastrointestinal Surgery, the Second Hospital of Hebei Medical University, Shijiazhuang, China, <sup>3</sup>Department of Rehabilitation, Hebei General Hospital, Shijiazhuang, China, <sup>4</sup>Hebei Medical University, Shijiazhuang, China, <sup>5</sup>Department of Neurology, Hebei General Hospital, Shijiazhuang, China

*Folia Neuropathol* 2022; 60 (2): 257-260

DOI: <https://doi.org/10.5114/fn.2022.118188>

## Abstract

Aphasia is a common consequence of stroke and repetitive transcranial magnetic stimulation (rTMS) may be a promising brain stimulation technique in the treatment of aphasia. However, there are few reports about the therapeutic effect of rTMS for Broca's area in patients with sensory aphasia. This study reported one stroke patient with sensory aphasia who received 6 treatment sessions of low-frequency rTMS before speech and language therapy. The target area was the Broca mirror area in the right hemisphere. After treatment, the auditory comprehension of the patient improved from 46 to 112, the naming improved from 18 to 32, and the AQ improved from 34.2 to 42.6. However, the level of functional language, spontaneous speech and repetition did not show obvious improvement.

**Key words:** repetitive transcranial magnetic stimulation, sensory aphasia, stroke, right hemisphere, functional language.

## Introduction

Aphasia is a common consequences of stroke [4,6]. Repetitive transcranial magnetic stimulation (rTMS) is a non-invasive brain stimulation technique that can alter the excitability of the cerebral cortex by applying different frequencies to promote the reorganization of the brain structure [11]. Many studies have shown that rTMS as an adjuvant therapy for aphasia can promote the language recovery [7,9]. However, no study reports the therapeutic effect of rTMS for Broca's area in the right hemisphere

with sensory aphasia. This study reported one case of rTMS acting on the Broca mirror area in the right hemisphere.

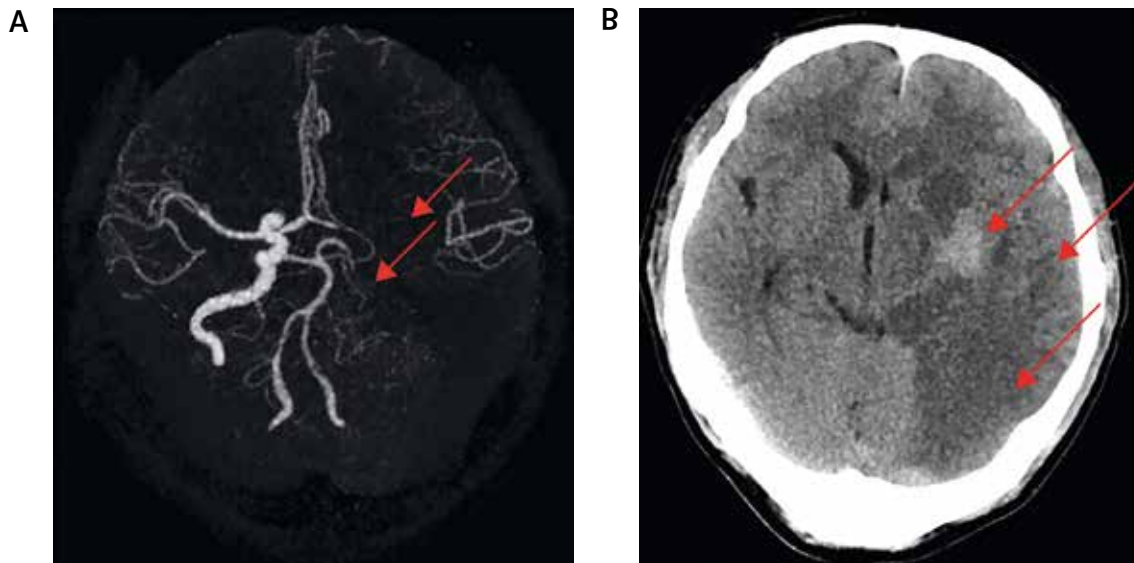
## Case presentation

### Participants

A 38-year-old man was admitted to our hospital for the first time on 16 June 2021 due to unconsciousness. Computed tomography angiography (CTA) results showed that the left internal carotid and left middle cerebral artery segments M1 to M3

## Communicating authors:

Yu Yin, Graduate School of Hebei Medical University, Rehabilitation Department, Hebei General Hospital, No. 348, Heping West Road, Xinhua District, Shijiazhuang, Hebei Province, 050000, China, phone: 17798093116, e-mail: yinyu-99@163.com; Wei-bo Li, Department of Gastrointestinal Surgery, the Second Hospital of Hebei Medical University, No. 215, Heping West Road, Xinhua District, Shijiazhuang, Hebei Province, 050000, China, phone: 17798093086, e-mail: liweibo-99@163.com



**Fig. 1.** Imaging data after the onset of stroke. **A)** Computed tomography angiography (CTA) showed that the left internal carotid and left middle cerebral artery segments M1 to M3 were not developed, as indicated by the red arrows, so the possibility of occlusion should be considered. **B)** Computed tomography (CT) showed a large area of infarcts in the temporal lobe, occipital lobe, and basal ganglia of the left hemisphere from onset, indicated by the red arrows.

were not developed, so the possibility of occlusion was considered (Fig. 1A). Computed tomography (CT) showed the patient had a large area of infarction on the left side of the brain (Fig. 1B). The decompressive craniectomy was performed on 17 June. The patient

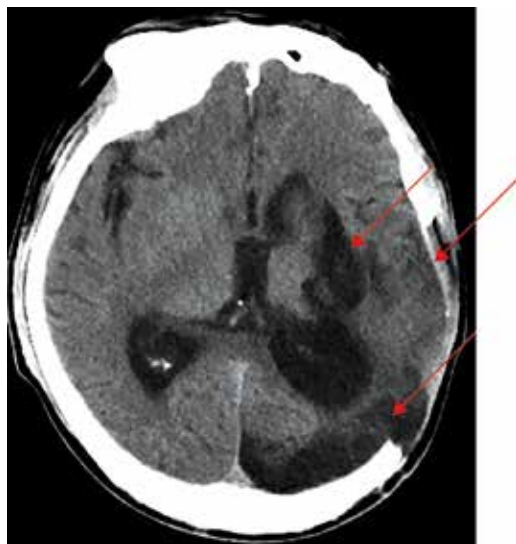was discharged when clinical symptoms improved, but language and limb dysfunction was still present.

On 7 October 2021, the patient was admitted to our hospital for the second time because he felt cold in his lower limbs. CTA results showed that he had embolism in the left limbs. CT showed that the patient had a large area of softening in the left temporal lobe, occipital lobe, and basal ganglia (Fig. 2). The type of aphasia for the patient was diagnosed with sensory aphasia by Western aphasia battery (WAB). Before treatment, his language performance was mainly poor on auditory comprehension and naming.

This case report was approved by the local institutional review board and the informed consent was obtained from the patient and his relatives.

### Repetitive TMS treatment

The rTMS was performed with a 90 mm figure-8 coil and a super rapid stimulator (Yiruide CCY-II, Wuhan, China). The target area of rTMS was the anterior portion of right pars triangularis (right Brodmann area 45), in the right Broca's homologue as cited in previous rTMS studies [5,9]. The intensity of rTMS was set at 90% of motor threshold (the lowest intensity that elicited a visible twitch in the left thenar muscles) for the right hemisphere. This stimulation



**Fig. 2.** Four months after the onset of stroke, a large area of softening appeared in the temporal lobe, occipital lobe, and basal ganglia of the left hemisphere, indicated by the red arrows.

protocol was 1 HZ, 1200 pulses, a session lasting for 20 min, once a day. The patient received 6 sessions of rTMS in hospital.

### Speech and language therapy

The patient received a 30-minute training once a day administered by a professional speech-language pathologist in a one-to-one setting in a relatively quiet room following rTMS treatment over 6 days.

### Evaluation of language function

The level of functional language was graded using the Boston Diagnostic Aphasia Examination (BDAE) scale. Spontaneous speech, auditory comprehension, repetition, naming, and aphasia quotient (AQ) were assessed by the WAB scale.

## Results

### Boston Diagnostic Aphasia Examination

After treatment, the patient's functional language level increased from 0 to 1 compared to the level before treatment. At 7 months of follow-up, the patient's functional language level increased from 1 to 2 compared to the level after treatment (Table I).

### Western aphasia battery

After treatment, the aphasic patient had an improvement for the auditory comprehension from 46 to 112, for the naming from 18 to 32, for the AQ from 34.2 to 42.6 compared to levels before treatment. However, there was almost no change between spontaneous speech and repetition.

At 7 months of follow-up, the aphasic patient had an improvement for the spontaneous speech from 8 to 11, the auditory comprehension from 112 to 142, for the naming from 32 to 63, and for the AQ from

42.6 to 61. However, there was almost no change in the repetition (Table I).

## Discussion

Several studies have shown that the right hemisphere is essential for the language recovery [10]. In this case, the patient had a large area of infarction in the temporal lobe and the course of the disease was in the subacute phase. At this time, the recovery of language function was mainly compensated by the right Wernicke mirror area [8]. Several studies have shown that low-frequency rTMS acting on a certain language area of the cerebral cortex can inhibit the activation of this area and increase the activation of its surrounding areas and other areas [1,2].

In this case, after treatment, the language ability of the patient was significantly improved in auditory comprehension, naming and AQ, the possible reason was that low-frequency rTMS inhibited the right Broca mirror area, facilitating the activation of the surrounding area, mainly the right Wernicke mirror area, and low-frequency rTMS acting on the right Broca mirror area could inhibit the activation of this site and facilitate the activation of the posterior area. However, the reasons why the repetition did not show a significant improvement may be due to the fact that repetition is a relatively complex process and this patient's posterior segment of the arcuate fasciculus may be damaged [3]. The reasons why the spontaneous speech did not show a significant improvement may be due to the fact that low-frequency rTMS hindered the improvement of spontaneous speech. Finally, the reason why functional language had not improved may be due to the fact that the treatment duration was only 6 days [6,9]. At 7 months of follow-up, the improvement in the patient's language function may be due to the following two reasons: one is due to the long-term efficacy of rTMS; the other is due to the

**Table I.** Outcome measures at baseline, after treatment, and at 7 months of follow-up

Test	T0 (baseline)	T1 (after 6 days)	T2 (7 months of follow-up)
BDAE			
Functional language level	0	1	2
WAB			
Spontaneous speech	8	8	11
Auditory comprehension	46	112	142
Repetition	50	55	61
Naming	18	32	63
AQ	34.2	42.6	61

BDAE – the Boston Diagnostic Aphasia Examination scale, WAB – Western aphasia battery, AQ – aphasia quotient

spontaneous recovery of language. Therefore, low-frequency rTMS may have a long-term effect lasting up to 7 months after treatment.

### Limitations

First, it was still unknown whether low-frequency rTMS on the right Broca mirror area can improve the level of functional language for the patient. Second, the improvement of language function cannot rule out the interference of spontaneous recovery. Third, this study included only 1 case of sensory aphasia and the sample size was limited.

### Conclusions

Applying low-frequency rTMS to the Broca mirror area in the right hemisphere may improve language function for sensory aphasia after stroke.

### Disclosure

The authors report no conflict of interest.

### References

1. Abo M, Kakuda W, Watanabe M, Morooka A, Kawakami K, Senoo A. Effectiveness of low-frequency rTMS and intensive speech therapy in poststroke patients with aphasia: a pilot study based on evaluation by fMRI in relation to type of aphasia. *Eur Neurol* 2012; 68: 199-208.
2. Barwood CH, Murdoch BE, Riek S, O'Sullivan JD, Wong A, Lloyd D, Whitworth A, Holland A, Ellery F, Hankey GJ, Cadilhac DA, Bernhardt J, VERSE Collaborative Group. Long term language recovery subsequent to low frequency rTMS in chronic non-fluent aphasia. *NeuroRehabilitation* 2013; 32: 915-928.
3. Berthier ML, Froudust WS, Dávila G, Nabrozidis A, de Mier RJYR, Gutiérrez A, De-Torres I, Ruiz-Cruces R, Alfaro F, García-Casares N. Dissociated repetition deficits in aphasia can reflect flexible interactions between left dorsal and ventral streams and gender-dimorphic architecture of the right dorsal stream. *Front Hum Neurosci* 2013; 7: 873.
4. Berthier ML. Poststroke aphasia: epidemiology, pathophysiology and treatment. *Drugs Aging* 2005; 22: 163-182.
5. Bucur M, Papagno C. Are transcranial brain stimulation effects long-lasting in post-stroke aphasia? A comparative systematic review and meta-analysis on naming performance. *Neurosci Biobehav Rev* 2019; 102: 264-289.
6. Godecke E, Armstrong E, Rai T, Ciccone N, Rose ML, Middleton S, Whitworth A, Holland A, Ellery F, Hankey GJ, Cadilhac DA, Bernhardt J, VERSE Collaborative Group. A randomized control trial of intensive aphasia therapy after acute stroke: The Very Early Rehabilitation for SpEech (VERSE) study. *Int J Stroke* 2021; 6: 556-572.
7. Hara T, Abo M, Kakita K, Mori Y, Yoshida M, Sasaki N. The effect of selective transcranial magnetic stimulation with functional near-infrared spectroscopy and intensive speech therapy on individuals with post-stroke aphasia. *Eur Neurol* 2017; 77: 186-194.
8. Hartwigsen G, Saur D. Neuroimaging of stroke recovery from aphasia – insights into plasticity of the human language network. *Neuroimage* 2019; 190: 14-31.
9. Harvey DY, Podell J, Turkeltaub PE, Faseyitan O, Coslett HB, Hamilton RH. Functional reorganization of right prefrontal cortex underlies sustained naming improvements in chronic aphasia via repetitive transcranial magnetic stimulation. *Cogn Behav Neurol* 2017; 30: 133-144.
10. Hu XY, Zhang T, Rajah GB, Stone C, Liu LX, He JJ, Shan L, Yang LY, Liu P, Gao F, Yang YQ, Wu XL, Ye CQ, Chen YD. Effects of different frequencies of repetitive transcranial magnetic stimulation in stroke patients with non-fluent aphasia: a randomized, sham-controlled study. *Neuro Res* 2018; 40: 459-465.
11. Ren C, Zhang G, Xu X, Hao JF, Fang H, Chen P, Li ZH, Ji YY, Cai QJ, Gao F. The Effect of rTMS over the different targets on language recovery in stroke patients with global aphasia: a randomized sham-controlled study. *Biomed Res Int* 2019; 2019: 4589056.