

Cerebral childhood and adolescent X-linked adrenoleukodystrophy. Clinical presentation, neurophysiological, neuroimaging and biochemical investigations

Małgorzata Zgorzalewicz-Stachowiak¹, Teresa Joanna Stradomska², Zuzanna Bartkowiak¹, Bożena Galas-Zgorzalewicz

¹Laboratory of Medical Diagnostics, Department of Preventive Medicine, University of Medical Sciences, Poznań, Poland; ²Department of Laboratory Diagnostics, The Children's Memorial Health Institute, Warsaw, Poland

Folia Neuropathol 2006; 44 (4): 319–326

Abstract

Clinical, neurophysiological, neuroimaging and biochemical studies were performed in five boys with childhood and adolescent form of cerebral X-ALD, which is a very rare disease in developmental age. In all patients, rapidly progressive spasticity, ataxia and mental deterioration were found. Seizures occurred in four of them. Additionally, visual and hearing impairment were observed in four and three patients respectively. Adrenal insufficiency was also diagnosed in four cases. MR revealed extensive demyelination located mainly symmetrically in the parieto-occipital areas, in one patient in whom asymmetrical lesions in that region were found. All patients had abnormal visual, brainstem and somatosensory evoked potentials recording, reflecting the central demyelination occurring in X-ALD. The clinical diagnosis in every case was confirmed by the significantly elevated concentration of very long chain fatty acids (VLCFA) measured in plasma in comparison to normal values.

Key words: Adrenoleukodystrophy, childhood cerebral form, adolescent cerebral form, evoked potentials, magnetic resonance imaging, very long chain fatty acids

Introduction

X-linked adrenoleukodystrophy (X-ALD), OMIM number 300100, is an inherited, recessive, neurodegenerative disease affecting brain white matter, adrenal cortex and testis. The genetic defect responsible for ALD has been located in Xq28, the terminal segment of the long arm of the X chromosome [12]. The disorder is connected with the accumulation of saturated very long chain fatty acids

(VLCFA, number of carbon atoms >22:0) in tissues and body fluids and is secondary to a defect in peroxisomal membrane transporting protein (ABCD1) – a member of the ATP-binding cassette transporter superfamily. X-ALD is diagnosed by detection of elevated VLCFA levels in plasma. The consequence of the accumulation of these fatty acids is demyelination in CNS, adrenocortical insufficiency and hypogonadism. X-ALD is considered to be very rare. It occurs at the

Communicating author:

Małgorzata Zgorzalewicz-Stachowiak, MD, PhD, Laboratory of Medical Diagnostics, Department of Preventive Medicine, University of Medical Sciences, 49 Przybyszewskiego Str., 60-355 Poznań, Poland, tel./fax +48 61 869 18 46, Email: neuro@amp.edu.pl

rate of 0.5 to 3.3 in 100,000 males [6,8,17,19,23]. The clinical phenotypes of X-ALD are variable. There are seven distinct clinical phenotypes ranging from cerebral forms, adrenomyeloneuropathy (AMN) to asymptomatic persons or isolated adrenal insufficiency without CNS involvement (Addison's disease only) (Table I). Cerebral X-ALD is further divided into childhood (CCALD), adolescent (AdolCALD) and adult form (ADCALD). The cerebral variants are classified on the basis of age of onset of the disease and rate of progress of neurological symptoms, and vary between 47% and 60.4% of all cases, in different countries (Table I) [8,13,16,17,23]. The disease rarely presents clinically before the age of 3 years and progresses according to several distinct phenotypes. Affected boys with CCALD present before the age of 10 years a rapidly progressive disorder with ataxia, spasticity, deafness, visual deficits, personality changes and seizures. The less common adolescent form after the age of 10 years demonstrates similar course [26]. Cerebral X-ALD is frequently associated with Addison's disease, but the primary adrenal insufficiency may precede, coexist or develop after neurological disturbances [10,13,16]. It may also remain as the only clinical expression of X-ALD. The disease is usually fatal within several years after onset of symptoms. In the diagnostic process of X-ALD neurophysiological testings are useful not only

in raising the detection rate of abnormal findings but also providing additional information about the functional state of separate affected pathways. Multimodality evoked potentials are not only useful in diagnostics of demyelinating processes in symptomatic patients but also of the highest importance as an objective tool in detecting subclinical CNS involvement in asymptomatic cases and carries of X-ALD [7,14,26].

Typical MR findings in the brain of X-ALD patients have been well documented recently and consist of bilateral white matter abnormalities. Typically they occur initially in the posterior cerebral regions and progress to parietal, temporal and frontal lobes sequentially. Such a pattern is found in approximately 80% of cases; therefore MR strongly suggests the diagnosis of X-ALD [7,11].

Atypical patterns of white matter involvement are often misdiagnosed or diagnosis is significantly delayed [3,13]. However, sporadic references to unilateral and other atypical abnormalities can be found in the literature [1,5,26].

Subjects and methods

Patients

We studied 5 boys with childhood onset (3 cases) and adolescent form of cerebral X-ALD

Table I. Distribution of X-ALD phenotypes in various countries

Phenotype	Age of onset [years]	Estimated relative frequency [%]				
		Spain [17]	USA [13]	Australia New Zealand [8]	Japan [23]	UK [16]
Childhood cerebral	3–10	33	39	52	29.9	31–35
Adolescent cerebral	11–21		6		9.1	4–7
Adult cerebral	adulthood	16	2	2	21.4	2–5
Adrenomyeloneuropathy	19–37	27	26	25	25.3	40–46
Olivopontocerebellar	adolescence or adulthood				8.4	1–2
Addison's only	common before 7.5	12	14	16		varies with age up to 50% in childhood
Asymptomatic	biochemical abnormality only	12	13	5	4.5	diminishes with age: common <4 years

(2 patients), who underwent clinical and laboratory investigations over the past decade at our institutions. The first symptoms of X-ALD in 3 boys with CCALD were observed at age of 5, 7 and 7.5 years and in two with AdolCALD at 11 and 12 years respectively. The boys presented developmental regression, behavioural decline and neurologic deficit to various degrees including alterations in vision or hearing. Seizures generalized or focal appeared in three patients. Adrenal insufficiency was manifested by bronze skin and hyperpigmentation of mucosa. Melanoderma was observed between 2 and 4 years before the appearance of the first neurological symptoms.

Laboratory investigations

On diagnosis of X-ALD the patients underwent neurophysiological and MR studies, VLCFA and cortisol assays. According to the IFCN (International Federation of Clinical Neurophysiology) guidelines, visual evoked potentials (VEP), brainstem auditory evoked potentials (BAEP) and somatosensory evoked potentials (SEP) were recorded. Nerve conduction studies (NCS) of median, ulnar, tibial and peroneal nerves was performed with standard methods using surface stimulating and recording electrodes. Registration was performed in a warm room (25°C) applying the Viking Quest system (Viasys Health Care-USA). Visual evoked potentials (VEP) were completed using the pattern of alternate white-and-black checkerboard. The size of one square was 1 cm on the screen, which corresponds with the angle of 36°. VEP were recorded with monocular and binocular system and the response was received for two active electrodes located laterally to the midline and above the occipital protuberance (O1-Fz and O2-Fz). The parameters for analysis were: latencies of maximum positive deflection P100, negative N75 deflection, preceding it and N145 deflection following it as well as N75/P100, P100/N145 amplitudes. Brainstem auditory evoked potentials (BAEP) were recorded from the top-head derivation to the region of the left ear mastoid process (A1) and the right ear (A2). The stimulus of "click" type was used, created by rectangular impulse with duration of 0.1 ms, impulse repetition rate 13 Hz and level of 100 dB peSPL. The following parameters were evaluated: morphology of the recording, absolute latencies of I wave (functional potential of n. VIII), III (pons), V (mesencephalon) and interlatencies

between waves I–III, III–V, I–V. Somatosensory evoked potentials (SEP) were elicited from median and tibial nerves. For median nerve SEP the active electrodes were placed at C3' and C4' (over the contralateral somatosensory cortex) and tibial nerve SEP were recorded from Cz', both referenced to Fpz. Nerves were stimulated by monophasic rectangular stimuli with duration of 0.2 ms. The stimulus intensity was adjusted to produce a noticeable muscle twitch. For examination of median nerves a bipolar electrode, located at the wrist, was used. During stimulation of tibial nerves the electrode was placed posteriorly to the medial malleolus. Two sets of at least 200 responses were averaged. Morphology, latency of N20 (median nerve) and P40 (tibial nerve) components were evaluated. NCS was evaluated from median nerve (recording electrode: over abductor pollicis brevis; stimulation site: wrist and elbow), ulnar nerve (recording electrode: over abductor digiti minimi; stimulation site: wrist and over ulnar nerve sulcus), peroneal nerve (recording electrode: extensor digitorum brevis; stimulation site: ankle and fibula head) and tibial nerve (recording electrode: abductor hallucis; stimulation site: medial malleolus and popliteal fossa). The following parameters were measured: nerve conduction velocity, distal latency (with the distance kept constant) and amplitude of response.

MR was performed with a Magnetom Impact 1.0 T unit (Siemens), using spino-echo sequences: T1, T2-weighted images in axial and sagittal planes (Department of Neuroradiology, Poznań University of Medical Sciences, Head of Department: Prof. Włodzimierz Paprzycki).

The VLCFA levels were determined in serum samples by gas chromatography analysis using the method as described previously in detail [22]. Serum cortisol concentrations were estimated using quantitative sequential immunometric assay.

For statistical analysis Statistica software (6.0 version) was used.

Results

The classification of the X-ALD phenotype in our patients was made on the basis of history and clinical findings, which are summarized in Table II. In patients with melanoderma low basal plasma cortisol levels ranged from 1.7 to 2.7 µg/dl, providing evidence for

Table II. Clinical characteristics of patients with childhood (CCALD) and adolescent (AdolCALD) form of X-ALD phenotypes

X-ALD phenotype	CCALD			AdolCALD		
	Patient No	1	2	3	4	5
Age of diagnosis (years)		8	9	10	13	16
Interval between onset and diagnosis (years)		3	2	2.5	2	4
Behavioural disturbances		+	+	+	+	+
Impaired cognition		+	+	+	+	+
Pyramidal tract involvement		+	+	+	+	+
Cerebellar symptoms		+			+	+
Visual disturbances		+		+	+	+
Hearing impairment		+	+			+
Seizures		+		+	+	+
Adrenal insufficiency		+			+	+

adrenal insufficiency. The cortisol concentration in the remaining two boys was within the normal values. To verify the clinical diagnosis neurophysiological and neuroimaging studies were performed. MR findings in three boys with CCALD revealed abnormal bilateral areas of increased hyperintensity in the splenium of the corpus callosum, in the optic radiation and parieto-occipital lobes consistent with demyelination of these structures. In patient No 4 aged 13 years with AdolCALD the MR pattern presented the hyperintensity localized mainly in occipital periventricular white matter but also in the optic radiation and in the corpus callosum similar to those changes found in CCALD patients (Fig. 1).

MR images in the second patient with AdolCALD, 16 years old with spastic quadriplegia, right sided predominant, have shown an asymmetrical extensive lesion particularly in the left parieto-occipital regions and posterior temporal lobe visible in T2 sequence. No mass effect was detected on the MR image, which could be mistaken for cerebral tumour (Fig. 2).

Multimodality evoked potentials and NCS are considered to be a useful tool for clinical diagnosis of X-ALD. Normative data for EP study were obtained from 60 healthy subjects at the same age. EP abnormalities were recorded in every patient with X-ALD. As a criterion of EP abnormalities 2.5 SD was

used and these significant delays of latencies were evaluated as abnormal results. VEP findings are summarized in Table III. Statistically significant prolongation of latencies N75, P100 and N145 in X-ALD patients in comparison to controls was found. VEP abnormalities were also manifested as a reduction of amplitudes N75/P100 and P100/N145. These changes occurred during monocular and binocular stimulation. The BAEP study in X-ALD patients revealed significant abnormalities in latencies of waves III and V as well as interpeaks I-III and III-V (Table IV). The median-nerve SEP recording in X-ALD patients showed prolongation of the N20 latencies obtained from the sides contralateral and ipsilateral to the stimulation. Also a significant delay in cortical latencies P40 for the tibial-nerve SEP in patients was found (Table V). Motor NCV was significantly decreased in comparison to controls. The values of NCV in X-ALD males were in the range 40–46 m/s and occurred in lower normal range. The changes predominated in the lower limb nerves (tibial and peroneal). The amplitudes and distal latencies were in the normal range in all examined cases (Tables VI and VII).

Finally in all patients the diagnosis was confirmed by the significantly ($p < 0.01$) elevated serum concentration of VLCFAs (Table VIII).

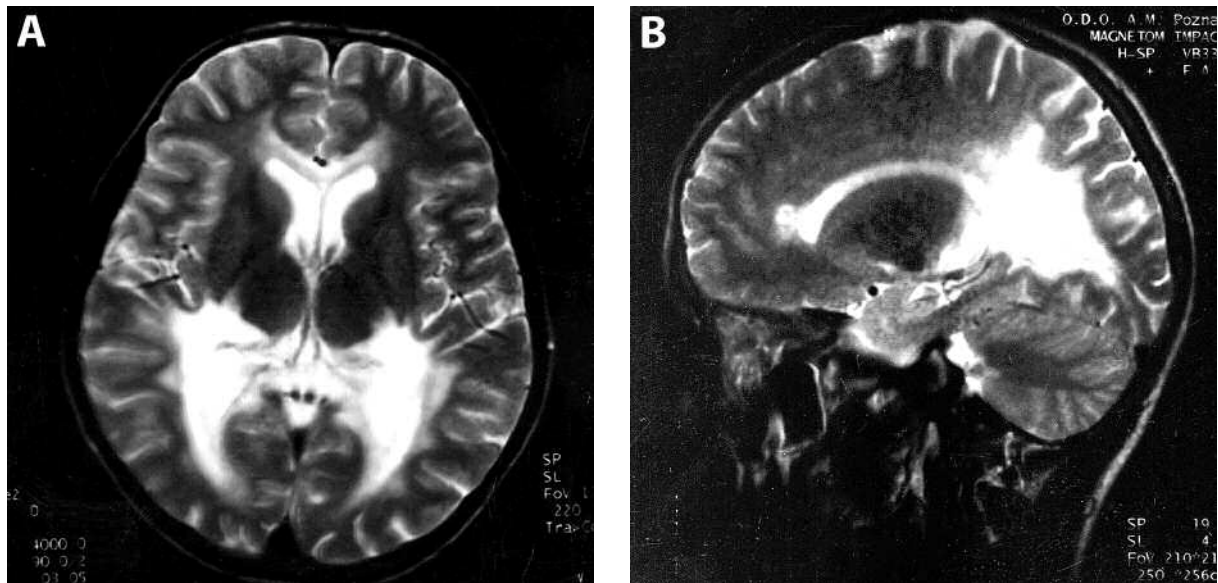


Fig. 1. Axial (A) and sagittal (B) T2-weighted MR images of 13-year-old boy with AdolCALD. Abnormal bilateral confluent high signal areas present in occipital periventricular region, the optic radiation and the splenium of the corpus callosum

Discussion

We present the clinical, neuroimaging, neurophysiological and biochemical investigations in five boys with childhood and adolescent form of X-ALD. The disease is very rarely diagnosed in developmental age as it was found in epidemiological studies in various countries [13,16,17,23]. In accordance with the rarity of X-ALD the final diagnosis is very often established in the advanced stages of the disease, when only symptomatic treatment can be applied. Especially young males, who have high risk of developing a rapidly progressive form of the disease, need complex diagnostic procedures combining neurological examination, neuroimaging, evoked potentials, neurographic recordings and biochemical studies. This may be useful for a better understanding of the prevalence and the natural course of CCALD and AdolCALD [23].

MR studies performed in our four cases have shown characteristic bilateral extensive demyelination in posterior brain white matter, especially in the parieto-occipital regions, in the optical radiation and the splenium of the corpus callosum, which are characteristic for this disorder and are likely causes of the neurological disturbances. Our results are fairly comparable to those reported by other authors [7,11,15,20,26]. This pattern is often associated with

alterations in the visual and auditory pathways and fronto-pontine-cortico-spinal projections [3,15]. The predominant findings may also be associated with

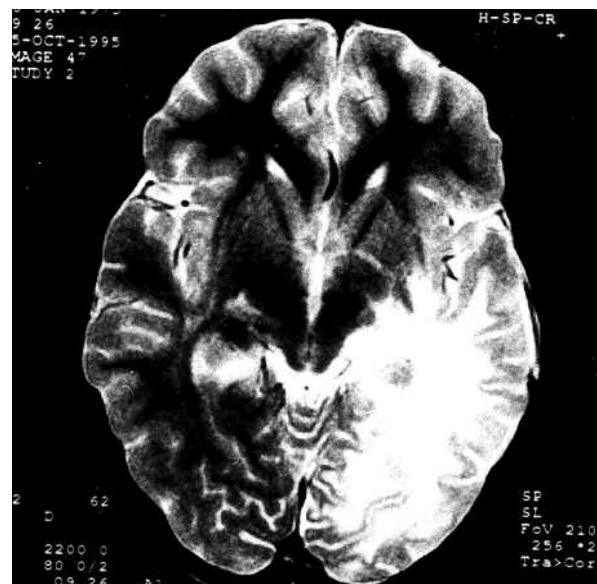


Fig. 2. Patient with AdolCALD 16 years old. Axial T2-weighted image showing asymmetrical extensive signals with no mass effect in the left parieto-occipital regions and posterior temporal lobe

Table III. Values of parameters of VEP recorded in patients with X-ALD and in control group

Stimulation	Binocular		Monocular			
			Right eye		Left eye	
Group	ALD	Control	ALD	Control	ALD	Control
Latencies (ms)						
N75	79.5±5.2	76.7±5.6	93.8±7.2*	76.5±7.2	92.9±4.7*	78.2±6.4
P100	113.1±10.9*	104.9±4.8	131.9±18.5*	106.1±4.5	125.0±12.4*	107.5±3.9
N145	151.9±15.9*	141.7±6.6	169.5±25.5*	142.8±8.2	157.2±17.3*	143.0±8.8
Amplitudes (µV)						
N75/P100	6.7±4.5*	10.4±3.6	6.3±2.5	6.6±2.7	4.7±2.4*	6.5±2.6
P100/N145	6.2±4.2*	12.2±4.9	5.7±2.5*	8.5±3.3	5.8±4.0*	8.9±3.7

Values are presented as mean ±SD.
* p<0.05

Table IV. Latencies and interlatencies of BAEP in examined groups

Group	ALD	Control
Latencies (ms)		
I	1.6±0.1	1.6±0.1
III	4.1±0.4*	3.7±0.1
V	6.0±0.6*	5.5±0.2
Interlatencies (ms)		
I-III	2.5±0.4*	2.1±0.1
III-V	1.8±0.3	1.8±0.1
I-V	4.3±0.6*	3.9±0.2

Values are presented as mean ±SD.
* p<0.05

Table VI. Values of parameters of NCS in patients with X-ALD and in control group

Parameters	ALD	Control
NCV [m/s]	43.9±12.7*	59.1±6.7
DLAT [ms]	5.6±3.2	5.9±0.3
AMPL [µV]	10.4±7.6	11.2±4.4

NCV – nerve conduction velocity; DLAT – distal latency; AMPL – amplitude.
Values are presented as mean ±SD.
* p<0.05

Table V. Latencies of SEP from median nerve (N20) and tibial nerve (P40) in patients with X-ALD and in control group

Group	ALD	Control
Latencies (ms)		
Median nerve N20	25.2±8.0*	18.3±0.9
Tibial nerve P40	53.7±4.5*	38.0±2.3

Values are presented as mean ±SD.
* p<0.05

progressive loss of cortical neurons resulting in focal and generalized brain atrophy in advanced stages of the disease [7,11]. Very rarely patients with X-ALD display unilateral lesion, which could be mistaken for brain tumour [1,5,13]. In such patients MR shows no mass effect, as in one of our cases. MR could also detect cerebral involvement in neurologically asymptomatic siblings and mothers of the affected boys [2,9]. As was described previously by one of us, MR revealed subtle high-signal lesions in the white matter surrounding the occipital horns and posterior parts of the bodies of the lateral ventricles in a 15-year-old boy, an asymptomatic brother of our patient № 3. MR imaging of their symptomatic mother showed demyelinating lesions in parieto-occipital regions more pronounced on the left side [4]. Hence the accurate, rapid diagnosis of X-ALD based on neuroimaging has

Table VII. Values of parameters of NCS in examined groups according to stimulated nerve

Parameters	Stimulated nerve			
	Median	Ulnar	Tibial	Peroneal
ALD				
NCV [m/s]	45.8±14.0	46.4±10.9*	41.0±13.8*	42.2±14.6*
DLAT [ms]	4.6±2.0	3.9±1.6	7.0±3.8	6.8±4.1
AMPL [µV]	9.1±4.6	10.3±2.7	16.7±11.3	4.7±3.0
Control group				
NCV [m/s]	62.8±8.7	66.3±8.8	52.3±6.9	56.1±8.7
DLAT [ms]	5.8±2.3	5.5±1.1	6.2±1.0	6.1±1.3
AMPL [µV]	9.4±5.3	11.8±3.3	17.1±5.3	6.6±2.1

NCV – nerve conduction velocity; DLAT – distal latency; AMPL – amplitude.
 Values are presented as mean ±SD.
 * *p*<0.05

an important implication for new future therapies as well for other family members.

Clinical examination revealed that visual and hearing disturbances were observed in three of our cases, whereas all patients had abnormalities in VEP, BAEP and SEP evoked potentials. The involvement of occipital white matter commonly found in MR images correlates with the significantly delayed VEP latencies. These results confirm demyelination in the postchiasmatic structures of the optic tract. Taking into account that components III and V of BAEP represent potentials generated in the pons and mesencephalon, the abnormalities in the latencies of these waves could be viewed as lesions within the central parts of the acoustic pathway. The prolonged latencies of median and tibial SEP also reflect demyelination in the CNS. Our neurophysiological findings in CCALD and AdolCALD are in agreement with the results described earlier. Due to the usefulness of evoked potentials in detecting clinically silent lesions also, their application was extended to studies in asymptomatic cases and X-ALD carriers [7,14,18,25,26].

According to many authors the application of precise and noninvasive diagnostic technique, in this instance the plasma assay of VLCFA, has demonstrated that X-ALD may be more common than was recognized in the past [13,22,24]. In all our patients the diagnosis was definitively confirmed by significant high concentration of two VLCFA: C_{24:0}

Table VIII. Serum VLCFA levels in cerebral form of X-ADL patients

Patients	VLCFA levels		
	C _{24:0} /C _{22:0}	C _{26:0} /C _{22:0}	C _{26:0} [µg/ml]
1	1.469	0.066	0.989
2	1.720	0.095	1.066
3	1.483	0.046	0.560
4	1.505	0.065	0.883
5	1.594	0.089	0.929
Control (36)	0.781±0.06	0.008±0.003	0.140±0.050

(lignoceric acid) and C_{26:0} (cerotic acid) as well as elevated ratios of C_{24:0}/C_{22:0} and C_{26:0}/C_{22:0}. Rapid and accurate diagnosis based on test on VLCFA concentration has great implications for the affected boys and since it is an X-linked disease for potentially many family members, especially in recognizing female carriers. High levels of VLCFA were estimated in 85–100% of examined heterozygotes [8,13,14,21].

Addison’s disease might be overlooked, although several patients manifest adrenal insufficiency as the first symptom, followed by neurological manifestations. Therefore it may be very important to test for X-ALD males with Addison’s disease, which in our three cases preceded the appearance of neurological symptoms. For this reason it is vitally

important to recognize early signs of the disease in initially asymptomatic children and adolescents who may be diagnosed by family screening.

References

1. Afifi AK, Menezes AH, Reed LA, Bell WE. Atypical presentation of X-linked childhood adrenoleukodystrophy with an unusual magnetic resonance imaging pattern. *J Child Neurol* 1996; 11: 497–499.
2. Aubourg P, Sellier N, Chaussain JL, Kalifa G. MRI detects cerebral involvement in neurologically asymptomatic patients with adrenoleukodystrophy. *Neurology* 1989; 39: 1619–1621.
3. Barkovich AJ, Ferriero DM, Bass N, Boyer R. Involvement of the pontomedullary corticospinal tracts: a useful finding in the diagnosis of X-linked adrenoleukodystrophy. *AJNR Am J Neuroradiol* 1997 Jan; 18: 95–100.
4. Bekiesinska-Figatowska M, Tyłki-Szymanska A, Walecki J, Stradomska TJ. MRI findings in an asymptomatic boy with X-linked adrenoleukodystrophy and his symptomatic mother. *Neuroradiology* 2001; 43: 951–952.
5. Close PJ, Sinnott SJ, Nolan KT. Adrenoleukodystrophy. A case report demonstrating unilateral abnormalities. *Pediatr Radiol* 1993; 23: 400–401.
6. Heim P, Claussen M, Hoffmann B, Conzelmann E, Gartner J, Harzer K, Hunneman DH, Kohler W, Kurlemann G, Kohlschutter A. Leukodystrophy incidence in Germany. *Am J Med Genet* 1997; 71: 475–478.
7. Jensen ME, Sawyer RW, Braun IF, Rizzo WB. MR imaging appearance of childhood adrenoleukodystrophy with auditory, visual, and motor pathway involvement. *Radiographics* 1990; 10: 53–66.
8. Kirk EP, Fletcher JM, Sharp P, Carey B, Poulos A. X-linked adrenoleukodystrophy: the Australasian experience. *Am J Med Genet* 1998; 76: 420–423.
9. Korenke GC, Fuchs S, Krasemann E, Doerr HG, Wilichowski E, Hunneman DH, Hanefeld F. Cerebral adrenoleukodystrophy (ALD) in only one of monozygotic twins with an identical ALD genotype. *Ann Neurol* 1996; 40: 254–257.
10. Korenke GC, Roth C, Krasemann E, Hufner M, Hunneman DH, Hanefeld F. Variability of endocrinological dysfunction in 55 patients with X-linked adrenoleukodystrophy: clinical, laboratory and genetic findings. *Eur J Endocrinol* 1997; 137: 10–12.
11. Melhem ER, Barker PB, Raymond GV, Moser HW. X-linked adrenoleukodystrophy in children: review of genetic, clinical, and MR imaging characteristics. *AJR Am J Roentgenol* 1999; 173: 1575–1581.
12. Migeon BR, Moser HW, Moser AB, Axelman J, Sillence D, Norum RA. Adrenoleukodystrophy: evidence for X-linkage, inactivation, and selection favoring the mutant allele in heterozygous cells. *Proc Natl Acad Sci USA* 1981; 78: 5066–5070.
13. Moser HW. Adrenoleukodystrophy: phenotype, genetics, pathogenesis and therapy. *Brain* 1997; 120: 1485–1508.
14. Restuccia D, Di Lazzaro V, Valeriani M, Oliviero A, Le Pera D, Colosimo C, Burdi N, Cappa M, Bertini E, Di Biase A, Tonali P. Neurophysiological abnormalities in adrenoleukodystrophy carriers. Evidence of different degrees of central nervous system involvement. *Brain* 1997; 120: 1139–1148.
15. Riva D, Bova SM, Bruzzone MG. Neuropsychological testing may predict early progression of asymptomatic adrenoleukodystrophy. *Neurology* 2000; 54: 1651–1655.
16. Ronghe MD, Barton J, Jardine PE, Crowne EC, Webster MH, Armitage M, Allen JT, Steward CG. The importance of testing for adrenoleukodystrophy in males with idiopathic Addison's disease. *Arch Dis Child* 2002; 86: 185–189.
17. Ruiz M, Coll MJ, Pampols T, Giros M. X-linked adrenoleukodystrophy: phenotype distribution and expression of ALDP in Spanish kindreds. *Am J Med Genet* 1998; 76: 415–419.
18. Schmidt S, Traber F, Block W, Keller E, Pohl C, von Oertzen J, Schild H, Schlegel U, Klockgether T. Phenotype assignment in symptomatic female carriers of X-linked adrenoleukodystrophy. *J Neurol* 2001; 248: 36–44.
19. Sereni C, Paturneau-Jouas M, Aubourg P, Baumann N, Feingold J. Adrenoleukodystrophy in France: an epidemiological study. *Neuroepidemiology* 1993; 12: 229–233.
20. Stephenson DJ, Bezman L, Raymond GV. Acute presentation of childhood adrenoleukodystrophy. *Neuropediatrics* 2000; 31: 293–297.
21. Stradomska TJ, Tyłki-Szymanska A. Decreasing serum VLCFA levels in ageing X-ALD female carriers. *J Inherit Metab Dis* 2001; 24: 851–857.
22. Stradomska TJ, Tyłki-Szymanska A. Examination of very long chain fatty acids in diagnosis of X-linked adrenoleukodystrophy. *Pediatr Pol* 1996; 71: 197–201.
23. Takemoto Y, Suzuki Y, Tamakoshi A, Onodera O, Tsuji S, Hashimoto T, Shimozawa N, Orii T, Kondo N. Epidemiology of X-linked adrenoleukodystrophy in Japan. *J Hum Genet* 2002; 47: 590–593.
24. Tobimatsu S, Fukui R, Kato M, Kobayashi T, Kuroiwa Y. Multimodality evoked potentials in patients and carriers with adrenoleukodystrophy and adrenomyeloneuropathy. *Electroencephalogr Clin Neurophysiol* 1985; 62: 18–24.
25. van Geel BM, Assies J, Wanders RJ, Barth PG. X-linked adrenoleukodystrophy: clinical presentation, diagnosis, and therapy. *J Neurol Neurosurg Psychiatry* 1997; 63: 4–14.
26. Zgorzalewicz M. Endogenous and exogenous evoked potentials in the most common neurologic syndromes during development. *Przegl Lek* 2001; 58 Suppl 1: 16–21.