

Radiation-induced brachial plexus neuropathy – aetiopathogenesis, risk factors, differential diagnostics, symptoms and treatment

Jerzy Gosk¹, Roman Rutowski^{1,2}, Paweł Reichert¹, Jerzy Rabczyński³

¹Department of Trauma and Hand Surgery, Medical University of Wrocław, Poland; ²Department of Sport Medicine, University of Physical Education of Wrocław, Poland; ³Department of Pathological Anatomy, Medical University of Wrocław, Poland

Folia Neuropathol 2007; 45 (1): 26-30

Abstract

The success of radiation oncology has led to longer patient survival. This provides a greater opportunity for radiation injuries of the peripheral nerves to develop. Brachial plexus neuropathy in cancer patients may result from either tumour recurrence or as a consequence of radiation therapy. Distinguishing between radiation injury and cancer disease recurrence as a cause of brachial plexus dysfunction may be difficult. In this article the most important principles of the differential diagnostics have been presented. Furthermore the aetiopathogenesis of brachial plexus neuropathy after radiotherapy has been discussed as well as main risk factors, symptoms of plexopathy and methods of treatment. It ought to be emphasized that complications of radiation therapy sometimes occur many years after treatment and this may create difficulties in initial diagnostics.

Key words: brachial plexus neuropathy, radiation therapy, fibrosis, cancer recurrence

Introduction

In the past, based on experimental studies, peripheral nerves were said to be relatively radioresistant due to their protected position, low metabolic rate and low reproductive capabilities [8,28]. However, the follow-up time was very short and it is possible that radiation injuries did not have an opportunity to develop [8]. The early effects occurring two days after irradiation of the peripheral nerves include: bioelectrical alterations, enzyme changes, abnormal microtubule assembly, and

altered vascular permeability [8,18]. Two phases of neuropathy following irradiation were described by Mendes and co-workers. The first phase includes changes in electrophysiology and histochemistry. The second, later phase is connected with fibrosis of the tissue surrounding the nerves [18]. Radiation therapy of the neck and axillary areas may result in brachial plexus injury [2,8,22,31]. Brachial plexopathy has been reported as a result of radiation therapy in the treatment of breast and lung cancer, lymphomas, as well as other neoplasms involving the neck, shoulder and upper thorax [2,4,15,22,30,31]. Radiation-induced

Communicating author:

Jerzy Gosk, Department of Trauma and Hand Surgery, Medical University of Wrocław, R. Traugutta 57/59, 50-417 Wrocław, Poland, tel.: +48 71 370 02 12, fax: +48 71 344 25 29, Email: chirurg@chirurg.am.wroc.pl

brachial plexopathy may be due to radiation damage of the nerve or due to compression of the nerve fibres by fibrosis of the supraclavicular and axillary connective tissue [10,30]. The fibrous connective tissue becomes more permanent, dense and inelastic [13]. Morphological changes in radiation-induced plexopathy include: necrosis and hyalinization of the media of small arteries, fibrous replacement of nerve fibres, demyelination and thickening of epi- and perineurium [8,20]. Infiltrating inflammatory cells, fibroblasts and large amounts of various extracellular matrix components are found in fibrotic degenerated connective tissue [10]. The incidence of brachial plexopathy increases with time after radiation [8,13]. The evolution of fibrosis is a slow process [13]. The median interval between radiotherapy and occurrence of brachial neuropathy has been reported to be 1-4 years [2,13,15,25], but also some neuropathies have occurred many years after completion of radiation treatment (from 6 to 22 years) [10,22,30,31]. Bajrovic and co-workers, based on clinical material consisting of 140 patients with breast cancer (19 of whom had had brachial plexopathy), established that the percentage of patients who were free from plexopathy was 96.1% after 5 years, 75.5% after 10 years, 72.1% after 15 years, and 46.0% after 19 years [1]. Early onset of brachial plexopathy during radiotherapy or 1-2 months after its completion has been observed by some authors [4,17,27,31]. Abnormal radiosensitivity of genetic origin was suggested as a possible cause of acute onset of brachial plexopathy occurring after only a few fractions [4]. Gerard and co-workers described acute ischaemic brachial plexus neuropathy due to occlusion of the subclavian artery during radiotherapy [7]. However, typical radiation-induced brachial plexus neuropathies occur after a latent period in patients with the following risk factors: high radiation doses, overlapping fields, increased dose in axilla due to a smaller separation at that point and concurrent chemotherapy [24,30]. The risk of brachial plexus damage was shown to increase with total radiation dose and dose per fraction [14,25]. The total tolerance dose (causing 5% of lesions within 5 years) for brachial plexus was suggested by Emami to be 60 Gy [6]. This observation was confirmed by Bajrovic and co-workers [1]. However, brachial plexus neuropathy was observed also after radiotherapy to a dose of 40 Gy in 20 fractions [30,31]. The incidence of brachial

plexus injury significantly increases with doses greater than 2 Gy per fraction [8]. Powell and co-workers observed patients treated with radiation therapy in two schemes. The first group of patients was given 3 Gy per fraction (total dose – 45 Gy) and the second group was given 1.8 Gy per fraction (total dose 54 Gy). After 5 1/2 years the incidence of brachial plexus lesions was 5.9% for the 3 Gy per fraction group and 1% for the 1.8 Gy per fraction group [25]. Salner and co-workers observed reversibility of mild neurological symptoms in patients treated to a dose of 50 Gy in 5 weeks. The median interval between radiotherapy and onset of symptoms was 4.5 months [27]. However, in the opinion of other authors the reversibility of injuries of the brachial plexus after radiotherapy is rather unlikely [1].

The main symptoms of radiation-induced brachial plexopathy include: sensory disorders (paresthesia, hypoesthesia), muscle atrophy and weakness, decreased muscle stretch reflexes, pain and oedema of the upper extremity [2,8,30,31]. Severity of symptoms may vary [2]. The LENT-SOMA scale is used to assess various grades of late effects after radiation therapy: grade 1 – mild sensory deficits, no pain; grade 2 – moderate sensory deficits, tolerable pain, mild arm weakness; grade 3 – continuous paraesthesia with incomplete motor paresis, pain medication required; grade 4 – complete motor paresis, excruciating pain, muscle atrophy [1]. Extremely rare is isolated motor dysfunction as described by Tallaksen and co-workers [29]. Radiation-induced brachial plexus injuries are found to be a progressive process. Patients with grade 1 or 2 lesions may progress to grade 3 or 4 during the observation period [1].

The differential diagnostics between radiation and tumour-induced brachial plexopathy is the main, difficult problem in medical practice [2,4,16,31]. The diagnosis is based on clinical examination, electromyography, CT and MR imaging and ultrasonographic examination [2,4,8,10,22,31]. The following clinical symptoms and factors are suggestive of radiation-induced brachial plexopathy: upper trunk of the brachial plexus involvement, no pain, lymphoedema, cutaneous radiation changes and doses of more than 60 Gy [15]. Greater risk for radiation injury of the upper trunk of the brachial plexus may be connected with anatomical conditions. The upper trunk has a longer course through the radiation field and has worse protection due to a lesser amount of tissue within the occipital triangle. The lower trunk is better protected

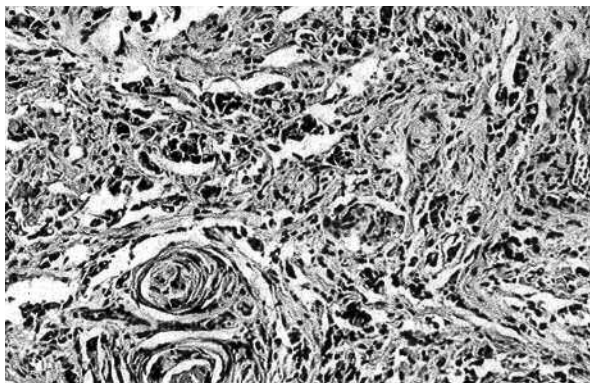


Fig. 1. ZJ 51 F. Patient with right breast cancer treated with breast amputation and radiotherapy (1994). Symptoms of brachial plexus injury occurred 7 years after treatment. Neurolysis of the brachial plexus and tissue collection for the histopathological exam were performed in 2001. Histopathological specimen result – carcinoma-tous infiltration of the neural trunk of the brachial plexus. Stain HE

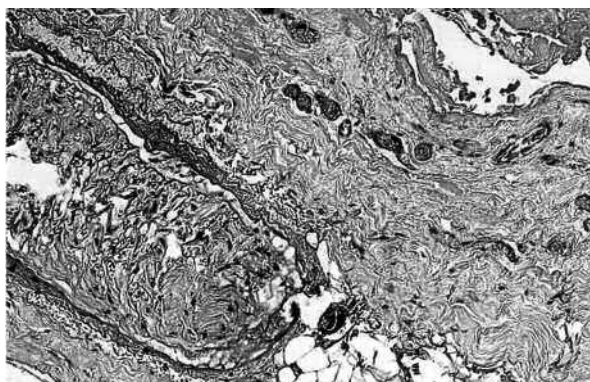


Fig. 2. GB 40 F. Patient with left breast cancer treated with breast amputation, chemotherapy and radiotherapy (2002). Symptoms of brachial plexus injury occurred 1 year after treatment. Neurolysis of the brachial plexus and tissue collection for the histopathological exam were performed in 2004. Histopathological specimen result – dense fibrous connective tissue encircles a single fascicle. Stain HE

by the clavicle [2]. The lower part of the brachial plexus injury, Horner's syndrome presence, severe pain, and total radiation dose less than 60 Gy are suggestive of tumour relapse [15]. These observations made by Kori were not fully confirmed by other authors. Radiotherapy may also cause injuries of the lower

trunk of the brachial plexus and pain is a frequent symptom of radiation-induced brachial plexopathy [30,31]. Therapeutic doses of radiation may lead to plexus injury [2,30].

The electromyographic findings in radiation-induced brachial plexopathy may include: reduction in amplitude, slowing of conduction velocity and increases in latency [2,4,30]. Myokymia has been observed on needle electromyography in patients with radiation-induced plexopathy. Tumour recurrence does not produce myokymia, but may be associated with denervation signs [26]. Currently EMG does not play an important role in discrimination between neoplastic and radiation-induced brachial plexus neuropathy [4,9]. CT was the first useful radiographic study which was able to show masses of the recurrent tumour [3,25]. Now MRI is the technique of choice to distinguish tumour relapse from injury after radiotherapy [4,10,31]. Radiation fibrosis may have both low and high signal intensities on T2-weighted images [20,31]. Reliable MRI signs of radiation-induced plexopathy were not identified in a study performed by Hoeller and co-workers. These authors concluded that the role of MRI seems to be the exclusion of tumour recurrence [10]. In some cases the diagnosis may be clarified with an ultrasonographic examination [22]. Certain diagnosis is based on histopathological examination. The material may be obtained by needle biopsies or by excision of the soft tissue near the brachial plexus during surgical exploration [13]. The result of the histopathological examination allowed the ultimate differential diagnostics between the possibility of malignant infiltration of the brachial plexus (Fig. 1) and radiation-induced fibrosis (Fig. 2) to be performed. The possibility of development of a neural sheath sarcoma after radiotherapy was also described [11].

The prevention of radiation-induced brachial plexus neuropathy is a difficult challenge. The aggressiveness of therapy must be balanced against the risk of recurrence [13]. The reduction of radiation field size and total dose were proposed to decrease the risk of late complication after radiotherapy [8]. Moody and Williams suggested reducing the total dose from 40 Gy to 32.5 Gy in the treatment of patients with lymphomas [19]. However, the success of radiotherapy depends on the total radiation dose and it is impossible to predict the late complications of this treatment [13]. The treatment of radiation-induced brachial plexus neuropathy depends on the grade of

severity of injury. In grades 1 and 2 conservative treatment is required which includes non-narcotic and narcotic analgesics and anaesthetic interventions [1,2,8]. Surgical exploration is fully justified in grades 3 and 4 [8,22,31]. It allows the neural elements to be released from fibrotic tissue and fibrosis of the vascular supply to the nerve to be prevented [8]. Omentoplasty was proposed by Narakas as a method of operative treatment in radiation-induced brachial plexopathy [21].

Chemotherapy was reported to increase the risk of brachial plexus lesions. Vinca alkaloids are neurotoxic due to their possibility of binding to tubulin in the axoplasm [5,13,30]. It reduces the slow component of anterograde axoplasmic transport and in consequence the nerves become more susceptible to chronic compression [5]. Olsen and co-workers observed that patients who received chemotherapy had a higher incidence of brachial plexopathy than those receiving radiation only [23]. In the study by Bajrovic et al. concurrent chemotherapy did not have an impact on the rate of brachial plexopathy [1]. Gillette and co-workers concluded that chemotherapy does not have a major impact on the increase of late soft tissue injury but may increase acute reactions [8]. Higher incidence of brachial plexopathy after radiotherapy was observed by Olsen et al. in younger patients [23]. In two independent studies Bajrovic et al. [1] and Johansson et al. [12] did not observe any differences for patients above or below the median age of 55 years.

Radiation-induced brachial plexus neuropathy is a rare but severe complication which may lead to devastating functional consequences [2,8,10]. Although radiation-induced injury is a problem that is diminishing with modern standards of radiotherapy technique, neurological syndromes may appear many years after radiation treatment [1,3].

References

- Bajrovic A, Rades D, Fehlauer F, Tribius S, Hoeller U, Rudat V, Jung H, Alberti W. Is there a life-long risk of brachial plexopathy after radiotherapy of supraclavicular lymph nodes in breast cancer patients? *Radiother Oncol* 2004; 71: 297-301.
- Brennan MJ. Breast cancer recurrence in a patient with a previous history of radiation injury of the brachial plexus: a case report. *Arch Phys Med Rehabil* 1995; 76: 974-976.
- Cascino TL, Kori S, Krol G, Foley KM. CT of the brachial plexus in the patients with cancer. *Neurology* 1983; 33: 1553-1557.
- Churn M, Clough V, Slater A. Early onset of bilateral brachial plexopathy during mantle radiotherapy for Hodgkin's disease. *Clin Oncol* 2000; 12: 289-291.
- Dellon AL, Swier P, Maloney CT, Livengood MS, Werter S. Chemotherapy-induced neuropathy: treatment by decompression of peripheral nerves. *Plast Reconstr Surg* 2004; 114: 478-483.
- Emami B, Lyman J, Brown A, Coia L, Goitein M, Munzenrider JE, Shank B, Solin LJ, Wesson M. Tolerance of normal tissue to therapeutic irradiation. *Int J Radiat Oncol Biol Phys* 1991; 21: 109-122.
- Gerard JM, Franck N, Moussa Z, Hildebrand J. Acute ischaemic brachial plexus neuropathy following radiation therapy. *Neurology* 1989; 39: 450-451.
- Gillette EL, Mahler PA, Powers BE, Gillette SM, Vujaskovic Z. Late radiation injury to muscle and peripheral nerves. *Int J Radiat Oncol Biol Phys* 1995; 31: 1309-1318.
- Harper CM, Thomas JE, Cascino TL, Litchy WJ. Distinction between neoplastic and radiation-induced brachial plexopathy, with emphasis on the role of EMG. *Neurology* 1989; 39: 502-506.
- Hoeller U, Bonacker M, Bajrovic A, Alberti W, Adam G. Radiation-induced plexopathy and fibrosis. Is magnetic resonance imaging the adequate diagnostic tool? *Strahlenther Onkol* 2004; 180: 650-654.
- Hussussian CJ, Mackinnon SE. Postradiation neural sheath sarcoma of the brachial plexus: a case report. *Ann Plast Surg* 1999; 43: 313-317.
- Johansson S, Svensson H, Larsson LG, Denekamp J. Brachial plexopathy after postoperative radiotherapy of breast cancer patients – a long term follow up. *Acta Oncol* 2000; 39: 373-382.
- Johansson S, Svensson H, Denekamp J. Timescale of evolution of late radiation injury after postoperative radiotherapy of breast cancer patients. *Int J Radiat Oncol Biol Phys* 2000; 48: 745-750.
- Johansson S, Svensson H, Denekamp J. Dose response and latency for radiation-induced fibrosis, edema, and neuropathy in breast cancer patients. *Int J Radiat Oncol Biol Phys* 2002; 52: 1207-1219.
- Kori SH, Foley KM, Posner JB. Brachial plexus lesions in patients with cancer: 100 cases. *Neurology* 1981; 31: 45-50.
- Lederman RJ, Wilbourn AJ. Brachial plexopathy: recurrent cancer or radiation? *Neurology* 1984; 34: 1331-1335.
- Malow BA, Dawson DM. Neuralgic amyotrophy in association with radiation therapy for Hodgkin's disease. *Neurology* 1991; 41: 440-441.
- Mendes DG, Nawalkar RR, Eldar S. Post-irradiation femoral neuropathy. *J Bone Joint Surg Am* 1991; 73: 137-140.
- Moody AM, Williams MV. Radiation dose in Hodgkin's disease: are we overtreating? *Clin Oncol* 1997; 9: 155-157.
- Moore NR, Dixon AK, Wheeler TK, Freer CE, Hall LD, Sims C. Axillary fibrosis or recurrent tumour. An MRI study in breast cancer. *Clin Radiol* 1990; 42: 42-46.
- Narakas AO. Operative treatment for radiation-induced and metastatic brachial plexopathy in 45 cases, 15 having an omentoplasty. *Bull Hosp Jt Dis Orthop Inst* 1984; 44: 354-375.
- Nich C, Bonnin P, Laredo JD, Sedel L. An uncommon form of delayed radio-induced brachial plexopathy. *Chir Main* 2005; 24: 48-51.
- Olsen NK, Pfeiffer P, Johannsen L, Schroder H, Rose C. Radiation-induced brachial plexopathy: neurological follow-up in 161 recurrence-free breast cancer patients. *Int J Radiat Oncol Biol Phys* 1993; 26: 43-49.

24. Pierce SM, Recht A, Lingos TI, Abner A, Vicini F, Silver B, Herzog A, Harris JR. Long term radiation complications following conservative surgery (CS) and radiation therapy (RT) in patients with early stage breast cancer. *Int J Radial Oncol Biol Phys* 1992; 23: 915-923.
25. Powell S, Cooke J, Parsons C. Radiation-induced brachial plexus injury: follow-up of two different fractionation schedules. *Radiother Oncol* 1990; 18: 213-220.
26. Roth G, Magistris MR, Le-Fort D, Desjacques P, Della Santa D. Post-radiation brachial plexopathy. Persistent conduction block. Myokymic discharges and cramps. *Rev Neurol* 1988; 144: 173-180.
27. Salner AL, Botnick LE, Herzog AG, Goldstein MA, Harris JR, Levene MB, Hellman S. Reversible brachial plexopathy following primary radiation therapy for breast cancer. *Cancer Treat Rep* 1981; 65: 797-802.
28. Salzberg CA, Salisbury RE. Thermal injury of peripheral nerve. In: Gelberman RH (ed.). *Operative nerve repair and reconstruction*. JB Lippincott Company, Philadelphia 1991; Vol. 1, pp. 671-678.
29. Tallaksen CM, Jetne V, Fossa S. Postradiation lower motor neuron syndrome – a case report and a brief literature review. *Acta Oncol* 1997; 36: 345-357.
30. Wadd NJ, Lucraft HH. Brachial plexus neuropathy following mantle radiotherapy. *Clin Oncol* 1998; 10: 399-400.
31. Wouter van Es H, Engelen AM, Witkamp TD, Ramos LM, Feldberg MA. Radiation-induced brachial plexopathy: MR imaging. *Skeletal Radiol* 1997; 26: 284-288.