

## Rare C-6 vertebral involvement in a child with histiocytosis X: Case report

Firouz Salehpour<sup>1</sup>, R. Shane Tubbs<sup>2</sup>, Sina Zarrintan<sup>3</sup>, Ali Meshkini<sup>1</sup>, Shahram Hadidchi<sup>1</sup>, Hojjat Pourfathi<sup>3</sup>,  
Ramin Azhough<sup>4</sup>, Asharf Fakhrouj<sup>5</sup>, James T. Goodrich<sup>6</sup>, Amir Afshin Khaki<sup>7</sup>

<sup>1</sup>Department of Neurosurgery, Imam Khomeini Hospital, Faculty of Medicine, Tabriz University of Medical Sciences, Tabriz, Iran; <sup>2</sup>Section of Pediatric Neurosurgery, University of Alabama at Birmingham and Children's Hospital, Birmingham, Alabama, USA; <sup>3</sup>Student Research Center and Faculty of Medicine, Tabriz University of Medical Sciences, Tabriz, Iran; <sup>4</sup>Department of Surgery, Faculty of Medicine, Tabriz University of Medical Sciences, Tabriz, Iran; <sup>5</sup>Department of Pathology, Imam Khomeini Hospital, Faculty of Medicine, Tabriz University of Medical Sciences, Tabriz, Iran; <sup>6</sup>Division of Pediatric Neurosurgery, Children's Hospital at Montefiore, Albert Einstein College of Medicine, New York, USA; <sup>7</sup>Department of Anatomical Sciences, Faculty of Medicine, Tabriz University of Medical Sciences, Tabriz, Iran

*Folia Neuropathol* 2007; 45 (2): 93-97

### Abstract

*The authors present a rare case of C-6 vertebral involvement in a 12-year-old boy with histiocytosis X. The patient presented with limitation in movements of neck and upper extremities. Computed tomography (CT) and magnetic resonance (MRI) imaging were used in the preoperative workup. Surgery was performed via an anterior cervical approach along with stabilization using a fibula strut graft and plate fixation. Pathological assessment showed infiltration of Langerhans cells accompanied by a mixture of many eosinophils, giant cells, neutrophils and foamy cells. The patient went on to make a full recovery with complete resolution of his motor weakness. In an extensive review of the literature there are very few cases of cervical histiocytosis X reported. In addition, surgical management of this type of lesion has rarely been discussed.*

**Key words:** histiocytosis X, eosinophilic granuloma, vertebral involvement, C-6 body lesion.

### Introduction

The term "histiocytosis X" was originally used to cover a spectrum of three diseases: eosinophilic granuloma, Hand-Schüller-Christian disease, and Letterer-Siwe disease. Hand-Schüller-Christian disease has become a synonym for multifocal Langerhans cell histiocytosis [LCG]. The term Langerhans' cell histio-

cytosis (LCH) [1-3,7,9,10,14] reflects the belief that this disease is a true "histiocytosis". Some prefer the term Langerhans' cell granulomatosis (LCG) to avoid confusion with the term histiocytosis X because there is some evidence to support the view that the Langerhans' cell is not a member of the mononuclear phagocyte system and hence not a tissue macrophage (or histiocyte) [8,15,18].

### Communicating author:

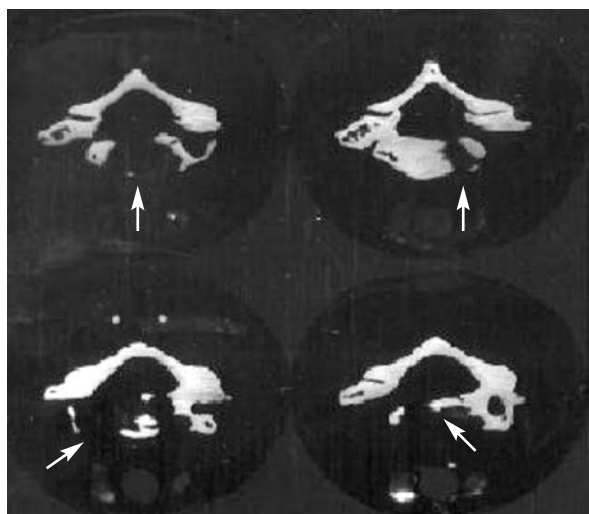
R. Shane Tubbs, PhD, Pediatric Neurosurgery, Children's Hospital, 1600 7th Avenue South ACC 400, Birmingham, Alabama 35233 USA, tel.: 205 939 99 14, fax: 205 939 99 72, Email: rstubbs@uab.edu

A patient with histiocytosis X requires local and systemic staging to differentiate isolated eosinophilic granulomas of the bone, multiple eosinophilic granulomas of the bone, and visceral disseminated disease. Medical management then varies according to the extension of the disease. Systemic chemotherapy may be indicated in patients with extraosseous lesions. Radiological investigations are recommended to look for instability of the spine. Lesions that are strictly confined to the vertebral body and reveal no instability would normally not require surgical treatment.

Histiocytosis X of the vertebral column is very rare. In a clinical situation, pathological alterations within the vertebral body should include a differential diagnosis of eosinophilic granuloma [11-13,19]. An unusual case of spinal cord compression caused by eosinophilic granuloma histiocytosis X of the vertebral body of C-6 in a 12-year-old boy was recently cared for in our department. Pathological examination revealed a rare case of an eosinophilic granuloma of the vertebral body of C6.

## Case report

The patient presented with weakness of both upper extremities along with severe limitation in range of motion at the neck. Neurological examination revealed motor weakness of 3/5 without atrophy in the distal upper extremities. The bicep/tricep deep tendon reflexes were normal. Computed tomography (CT) of the cervical spine revealed an expansile

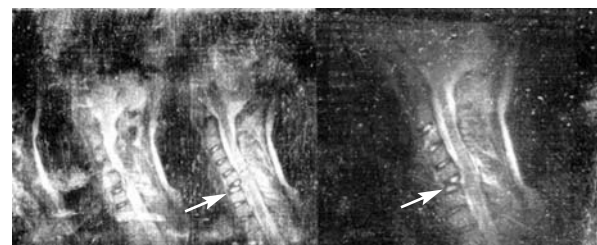


**Fig. 1.** CT of C-3 to C-6, an axial C-6 cut illustrates an expansive osteolytic lesion in the C-6 body

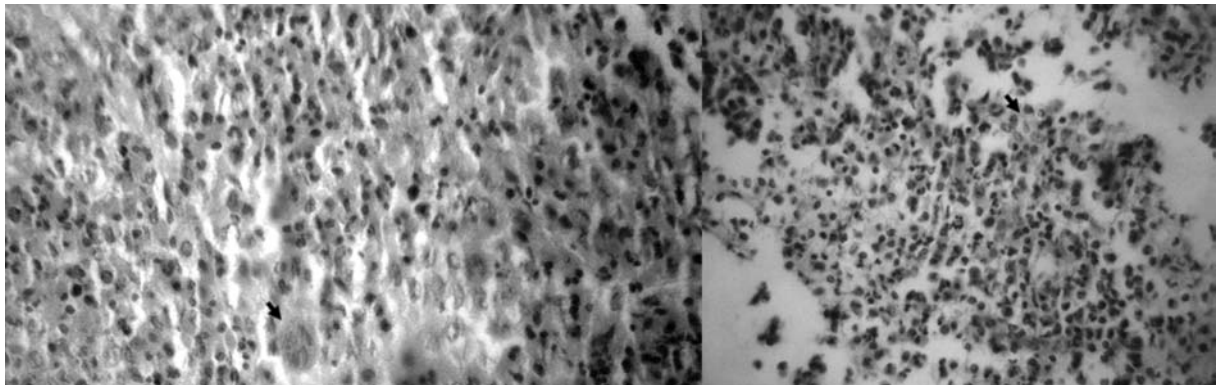
osteolytic lesion in the C-6 body. Loss of the C-6 body height was also noted. Of more concern was the finding of a narrowing of the spinal canal with cord compression secondary to the expansile lesion (Fig. 1). Magnetic resonance imaging revealed a straightening of the neck along with spinal cord compression secondary to soft tissue expansion of C-5 and C-6 (Fig. 2 left). An MRI with contrast was also performed; no contrast enhancement was noted (Fig. 2 right).

A comprehensive history was taken together with a complete physical examination. Lymphadenopathy, hepatomegaly, splenomegaly, and involvement of skin, other organ systems and the limbs were not evident. All investigations including history, physical examination, laboratory findings and radiological evaluations did not demonstrate any evident involvement in any other organs or systems. All the mentioned observations were in favour of a unifocal unisystem C-6 vertebral body lesion and therefore surgical removal of the mass was chosen as the most appropriate treatment.

An anterior cervical approach was used to reach the cervical spine. A C-6 corpectomy was completed; the spine was stabilized with placement of a fibular strut graft, which was stabilized with a plate. A C-6 body lesion biopsy was sent for pathological assessment. The pathology specimens showed fragments of bony tissue with infiltration of Langerhans cells accompanied by a mixture of eosinophils, giant cells, neutrophils and foamy cells (Fig. 3). The immunohistochemistry for S-100, positive in Langerhans cells, was performed to confirm the histiocytic origin of the process (Fig. 4). The patient made an uneventful recovery from surgery. Over the next three months, the patient's motor function demonstrated significant improvement with no new neurological deficits. Three months post operatively, there was no evidence of spinal cord compression on



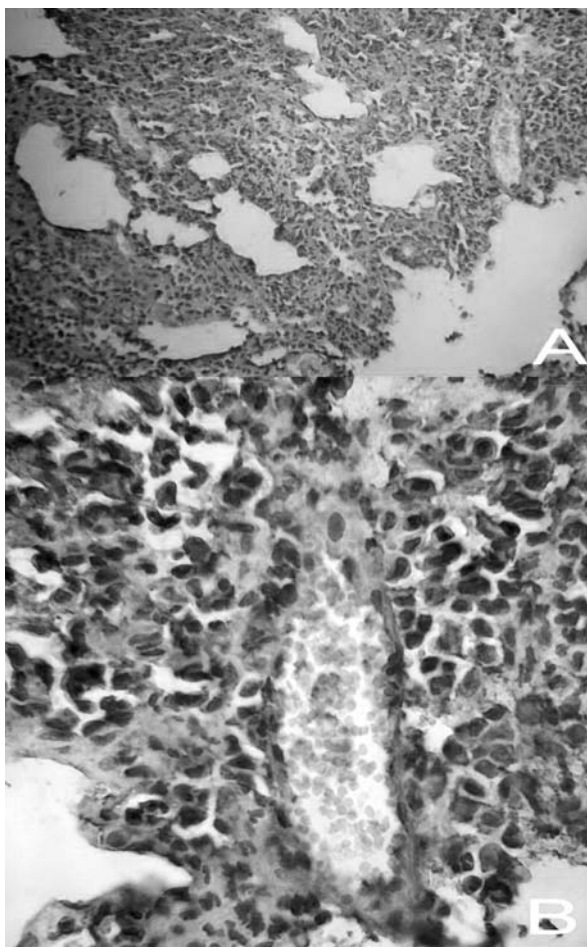
**Fig. 2.** Sagittal T<sub>1</sub>-weighted magnetic resonance imaging (left); MRI with contrast (right), note the lack of enhancement in the lesion



**Fig. 3.** Left: many eosinophils and some multinucleated giant cells. H & E 10 \* 10. Right: many eosinophils and some histiocytes with longitudinal grooves. H & E 10 \* 10

radiological images of the cervical spine (Fig. 5). Moreover, at three and twelve months after surgery, history, physical examination, laboratory tests, and

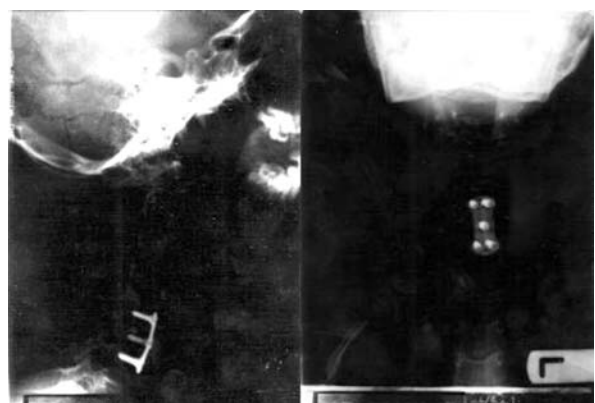radiological evaluations did not demonstrate any involvement in other organs, systems, bones or vertebrae.



**Fig. 4.** S-100 positive for nuclei and cytoplasm of Langerhans cells. (A) 10 \* 10; (B) 10 \* 40

## Discussion

We report a patient who had eosinophilic granuloma histiocytosis X with isolated C-6 vertebra involvement. Compression of the spinal cord resulted in upper extremity weakness involving both arms along with severe limitation of neck movements. In reviewing the literature, Gandolfi [11] reported an unusual case of spinal cord compression also caused by histiocytosis X of the vertebral body of T-7, which was surgically corrected. Greinacher and Gutjahr et al. [12] presented three children with histiocytosis X and vertebral involvement. These authors noted that even with vertebral destruction neurological abnormalities were not present. Boriani et al. [4] assessed thirty-five



**Fig. 5.** Cervical spine x-ray of the spine 3 months after surgery: anteroposterior (right); lateral (left). The fixation plate can be seen in both views

cases of vertebral histiocytosis with a total of 52 vertebrae affected. They noted that the diagnosis was based on radiology only in typical cases; and in cases of malignant neoplastic lesions, the diagnosis might be missed. These authors proposed orthotic stabilization and/or surgical treatment based on the extent of the lesion and the potential for further progression. Kayser et al. [17] reported six children with Langerhans cell histiocytosis who underwent operative treatment. These authors also noted that in cases of vertebral Langerhans cell histiocytosis, differentiating these lesions from spinal osteomyelitis may be difficult. In a recent study done by Brown et al. [5], of 8 children who were found to have vertebral Langerhans cell histiocytosis, the most common presenting complaint was back or neck pain. The thoracic vertebrae were most commonly affected followed equally by cervical and lumbar vertebrae. These authors advocated bracing, surgery, radiotherapy and chemotherapy depending on the severity of the presenting complaint. Cardon et al. [6] performed percutaneous vertebroplasty with acrylic cement in the treatment of a 25-year-old patient with Langerhans cell vertebral histiocytosis. These authors clearly emphasized that this technique should be reserved for adults only.

In various reviews of the literature a number of authors have discussed different cases of vertebral histiocytosis X with different backgrounds and diagnostic techniques. Treatment clearly varies according to the severity of the disease, the spread of the lesion, and any unusual progression. In our case, the vertebral involvement was in a cervical vertebra of which there are very few cases in the literature. To treat this patient we removed the affected vertebrae and placed a fibula strut graft which was fixated with a plate. Brown et al. [5] performed a similar surgery with a vertebral fusion in one child via a thoracotomy and debridement of the lesion followed by anterior strut grafting.

## Conclusions

Diagnosing histiocytosis in the paediatric spine may require several studies. A CT scan is helpful in localizing these lesions. An MRI should follow if there is any question of neural involvement. A biopsy is often helpful but should be done in the least invasive manner. In our case, the diagnosis was obtained from the patient's history and imaging techniques followed by assessment of pathological biopsy. The

surgical operation was based on the goal of cord decompression and additional stabilization using a fibular strut graft. The resolution of the neurological findings and the stabilization of the neck with the graft suggest this is a useful technique.

## References

1. Abellan Martinez MC, Mendez Martinez P, Sanchez Gascon F, Hernandez Martinez J, Sanchez Monton T, Romero Mas E. Pulmonary histiocytosis X. Report of a case and review of the literature. *An Med Interna* 2002; 19: 16-18.
2. Aster J. The Hematopoietic and Lymphoid Systems. In: Kumar V, Cotran RS, Robbins SL (eds). *Robbins Basic Pathology*. Saunders, Philadelphia 2003; pp. 441-442.
3. Bochenek G, Mejza F, Nizankowska-Mogilnicka E. Pulmonary histiocytosis X. *Pol Arch Med Wewn* 2003; 109: 633-639.
4. Boriani S, Donati D, Picci P, Savini R, Mancini AF, Lucchi A, Marchi N. Vertebral histiocytosis. *Chir Organi Mov* 1990; 75: 15-24.
5. Brown CW, Jarvis JG, Letts M, Carpenter B. Treatment and outcome of vertebral Langerhans cell histiocytosis at the Children's Hospital of Eastern Ontario. *Can J Surg* 2005; 48: 230-236.
6. Cardon T, Hachulla E, Flipo RM, Chastanet P, Rose C, Deprez X, Duquesnoy B, Delcambre B, Devulder B. Percutaneous vertebroplasty with acrylic cement in the treatment of a Langerhans cell vertebral histiocytosis. *Clin Rheumatol* 1994; 13: 518-521.
7. Coppes-Zantinga A, Egeler RM. The Langerhans cell histiocytosis X files revealed. *Br J Haematol* 2002; 116: 3-9.
8. Delobbe A, Durieu J, Duhamel A, Wallaert B. Determinants of survival in pulmonary Langerhans' cell granulomatosis (histiocytosis X). *Groupe d'Etude en Pathologie Interstitielle de la Societe de Pathologie Thoracique du Nord. Eur Respir J* 1996; 9: 2002-2006.
9. Fluri S, Gebbers JO. Langerhans cell histiocytosis: 50 years to histiocytosis X. *Schweiz Rundsch Med Prax* 2004; 93: 559-565.
10. Gabbay E, Dark JH, Ashcroft T, Milne D, Gibson GJ, Healy M, Corris PA. Recurrence of Langerhans' cell granulomatosis following lung transplantation. *Thorax* 1998; 53: 326-327.
11. Gandolfi A. Vertebral histiocytosis-X causing spinal cord compression. *Surg Neurol* 1983; 19: 369-372.
12. Greinacher I, Gutjahr P. Vertebral changes in histiocytosis x (author's transl). *Radiologe* 1978; 18: 228-232.
13. Gugliantini P, Orazi C, Boldrini R. Vertebral monostotic histiocytosis-X with intraspinal spread. Usefulness of CT. *Radiol Med (Torino)* 1989; 77: 697-700.
14. Habib SB, Congleton J, Carr D, Partridge J, Corrin B, Geddes DM, Banner N, Yacoub M, Burke M. Recurrence of recipient Langerhans' cell histiocytosis following bilateral lung transplantation. *Thorax* 1998; 53: 323-325.
15. Hage C, Willman CL, Favara BE, Isaacson PG. Langerhans' cell histiocytosis (histiocytosis X): immunophenotype and growth fraction. *Hum Pathol* 1993; 24: 840-845.
16. Jouve JL, Bollini G, Jacquemier M, Bouyala JM. 15 cases of vertebral involvement of histiocytosis X in children. Review of the literature. *Ann Pediatr (Paris)* 1991; 38: 167-174.

17. Kayser R, Mahlfeld K, Grasshoff H. Vertebral Langerhans-cell histiocytosis in childhood – a differential diagnosis of spinal osteomyelitis. *Klin Padiatr* 1999; 211: 399-402.
18. Lieberman PH, Jones CR, Steinman RM, Erlandson RA, Smith J, Gee T, Huvos A, Garin-Chesa P, Filippa DA, Urmacher C, Gangi MD, Sperber M. Langerhans cell (eosinophilic) granulomatosis. A clinicopathologic study encompassing 50 years. *Am J Surg Pathol* 1996; 20: 519-552.
19. Rigault P, Finidori G. Vertebral localizations of histiocytosis X. Orthopedic aspects. *Rev Chir Orthop Reparatrice Appar Mot* 1977; 63 Suppl 2: 190-194.