

# Snake-like hypermobile masses in three chambers of the heart: very unusual metastasis of squamous cell carcinoma

Çağdaş Akgüllü<sup>1</sup>, Sevil Önay<sup>1</sup>, Canten Tataroğlu<sup>2</sup>, Selim Durmaz<sup>3</sup>, Tuğba Özbek<sup>2</sup>

<sup>1</sup>Department of Cardiology, Faculty of Medicine, Adnan Menderes University, Aydın, Turkey

<sup>2</sup>Pathology Department, Faculty of Medicine, Adnan Menderes University, Aydın, Turkey

<sup>3</sup>Cardiovascular Surgery Department, Faculty of Medicine, Adnan Menderes University, Aydın, Turkey

Postep Kardiol Inter 2015; 11, 3 (41): 241–243

DOI: 10.5114/pwki.2015.54020

## Introduction

Metastatic disease of the heart is rare, with an incidence of 1.23% depending on the autopsy series [1]. Metastasis can occur in various ways: through the lymph system, direct extension, and hematogenous or intracavitary dissemination by direct extension via the caval or pulmonary veins. Cardiac metastases mostly involve the pericardium and with lower incidence the epicardium or the myocardium. However, only 5% of tumors affect the endocardium [2]. Pericardial invasion usually occurs through lymphatic propagation, while endocardial involvement mainly results from hematogenous dissemination [2]. This rare form of metastasis leading to intracavitary, endocardial, or valvular metastatic deposits mainly occurs in the right chambers and is only rarely seen in the left chambers. This is attributed to the filtering role of the pulmonary circulation and the slower flow in the right chambers [3].

We report a very rare case of squamous cell carcinoma-detected snake-like hypermobile metastatic intracardiac masses in three chambers of the heart from an unknown primary origin.

## Case report

At 8 years after coronary artery bypass graft surgery a 53-year-old man was admitted to the emergency room with sudden onset of dysarthria and left hemiparesis. His blood pressure was 130/70 mm Hg, and the pulse was regular with no pulsus paradoxus. Cardiac examination was normal except for a systolic ejection murmur. There was no marked jugular venous distention or edema of the extremities. Radial and dorsal pedis arteries were

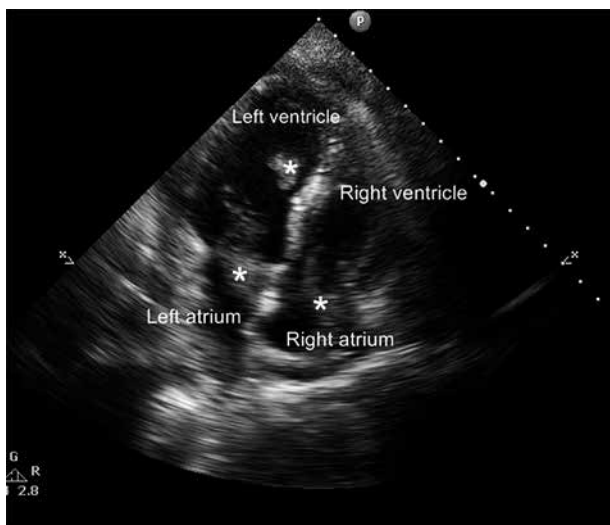
symmetrically palpable. Neurological examination revealed disturbance of consciousness, dysarthria, and left hemiparesis. Electrocardiography was normal except for the rare premature atrial contractions, and chest X-ray findings were in the normal ranges. His erythrocyte sedimentation rate was high (56 mm/h), but other laboratory data were in the normal ranges. Head magnetic resonance imaging (MRI) revealed multiple hyperintense lesions on the bilateral cerebral hemisphere. A low-molecular-weight heparin, enoxaparin was started. On the fourth day after he began to improve, gained his consciousness and was able to talk again, recurrent transient ischemic attacks (TIA) began to occur, causing transient loss of consciousness. For evaluation of the embolic source, we performed transthoracic echocardiography. Two-dimensional echocardiography showed highly mobile, snake-like structures with a slightly higher echodensity as compared to myocardium, in the right and the left atria as well as the left ventricular apical septum (Figure 1). There was moderate tricuspid valve regurgitation and minimal mitral valve regurgitations. Wall motions and echo densities as well as the pericardium were normal. Vena cava inferior was in normal calibration, and no mass was detected. A primary cardiac tumor or probable metastasis was suspected. We were planning to perform further diagnostic tests such as cardiac MRI, transthoracic echocardiography and computed tomography scanning of the body; however, the patient experienced a severe transient ischemic attack under anticoagulant therapy with a transient total loss of consciousness and transient respiratory failure. The patient was referred to neurologists and surgeons, and an urgent decision to operate was taken in order to prevent further severe stroke.

---

### Corresponding author:

Çağdaş Akgüllü, Department of Cardiology, Faculty of Medicine, Adnan Menderes University, Aytepe Mevkii, Merkez-Aydın 090100 Aydın, Turkey, phone: +90 5326540715, e-mail: cagdasakgullu@gmail.com

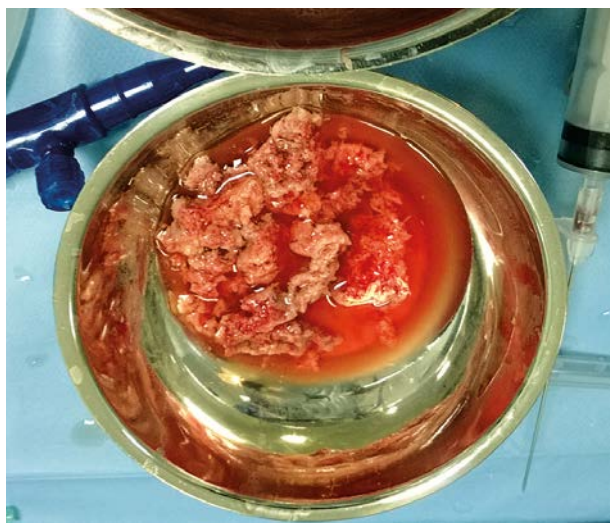
Received: 13.03.2014, accepted: 16.07.2014.



**Figure 1.** Image depicting snake-like hypermobile masses (asterisk) in three chambers of the heart (left atrium, right atrium and left ventricle)

Thus, the diagnostic tests were delayed to the post-operative period and surgery was planned to be done through the guidance of surgical exploration. An open excision of the cardiac masses was performed (Figure 2).

In the surgical exploration report it was stated that when the pericardium was opened there was not any gross pathology in the external surface of the heart. During the cannulation of the superior vena cava, the cannula encountered an internal force. The right atrium was thick with the palpation. The right atriotomy revealed a solid mass infiltration of the inner surface of the right atrium, reaching 2 cm thickness near the superior vena cava and 1 cm thickness near the inferior vena cava. There were also separate, nearly 1 cm width solid infiltrative regions both on the interatrial septum and near the aorta. After the resections of solid masses, the interatrial



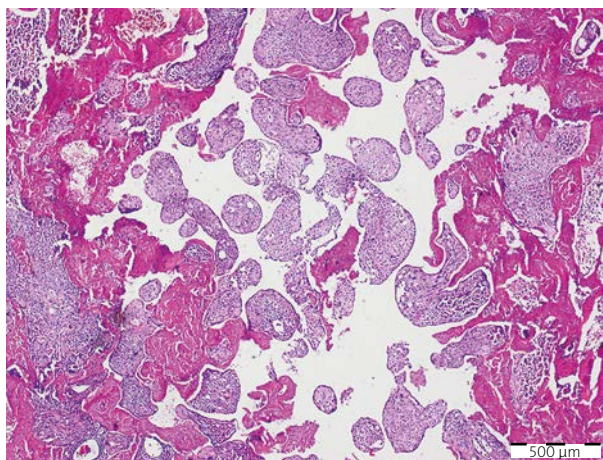
**Figure 2.** Macroscopic view of the cardiac masses after surgical extraction was performed

septum was opened. In the left atrium, there was a solid mass attached to the interatrial septum phenotypically similar to the ones in the right atrium. There was also a second solitary mass between the left auricula and the mitral annulus. Their resections were performed with part of the interatrial septum. The right ventricle was normal, but the interventricular septum was thick. There was a solid, phenotypically similar mass in the left ventricle tightly attached to the mid portion of the interventricular septum and spreading to the cavity. The interventricular septum was thick and infiltrated. The mass was resected with a small part of the septum, but further excessive resection was not performed.

The histopathology of the surgical specimen revealed each mass to be a cardiac metastasis of a highly differentiated squamous cell carcinoma from an unknown origin (Figure 3). Depending on the differentiation grade, the primary origin of the metastatic carcinoma was thought to be from the nasopharyngeal region or lungs, but it is hard to define the accurate region because of the lack of diagnostic tests. We also could not perform further diagnostic tests as the patient's hemodynamic status was constantly unstable in the post-operative period. In the post-operative period, low molecular weight heparin infusion therapy and dual antiplatelet therapy with clopidogrel and acetylsalicylic acid were continued as well as antibiotherapy with 1.5 g ampicillin/sulbactam 4 times a day. However, the patient died due to renal failure and sepsis at eight days after admission. After his death we did not obtain permission from the family members to perform post mortem examinations on the body.

## Discussion

We report a case with metastatic cardiac squamous cell carcinoma with an unknown primary origin, present-



**Figure 3.** Histopathology of the surgical specimen revealed all three masses to be a cardiac metastasis from an unknown origin of a squamous cell carcinoma

ing with stroke, involving the right atrium and both left heart chambers simultaneously.

Cardiac metastases are far more common than are primary cardiac tumors. The reported prevalence (1.5–20%) varies widely. They have a broad clinical presentation including nonspecific symptoms, such as malaise, weight loss, chest pain, or congestive heart failure secondary to intracardiac obstructions and valvular involvements, or pericardial tamponade, arrhythmias or embolic events. Cardioembolic stroke accompanied with a metastatic cardiac tumor, as in our case, seems to be quite rare; only several cases have previously described [4].

Treatment options for patients with cardiac metastases are limited. They usually occur in the context of disseminated carcinomatosis, which usually limits treatment to measures aimed at relief of symptoms [5]. Due to the extent and location of the intracardiac tumors, most patients were not also candidates for surgical resection. However, palliative surgery may have a role in specific cases, such as obstruction of a cardiac chamber, cardiac tamponade, symptoms arising from local progression of the tumor or high risk of embolization. Prognosis is highly dependent on the stage and histological aggressiveness of the tumor.

Echocardiography is the first-line imaging method to diagnose cardiac tumors as it continues to be relatively inexpensive, readily available in most centers, repeatable, and portable. This case illustrates the usefulness of early cardiac evaluation with 2-dimensional echocardiography in patients with stroke.

Finding the primary origin of such metastases and screening the whole body to assess the extent of the disease have crucial importance for the management of patients. Further diagnostic tests can be performed with magnetic resonance imaging, computed tomography or transesophageal echocardiography for this purpose. In this particular case unfortunately it was impossible to discover the primary origin of the metastatic masses. We had some constraints limiting our further diagnostic work. Diagnostic tests prior to surgery were lacking, as the urgent decision to operate was taken after the consultation of the patient with neurologists and cardiovascular surgeons in order to prevent further severe stroke. Unfortunately, the patient's hemodynamic status did not let us perform any diagnostic tests in the post-operative period either. Moreover, a post mortem examination could not be done because the family members did not give the necessary legal permission.

### Conflict of interest

The authors declare no conflict of interest.

### References

1. Grigsby PW. The prognostic value of PET and PET/CT in cervical cancer. *Cancer Imaging* 2008; 11: 146-55.
2. Bussani R, De-Giorgio F, Abbate A, et al. Cardiac metastases. *J Clin Pathol* 2007; 60: 27-34.
3. Lam KY, Dickens P, Chan AC. Tumors of the heart. A 20-year experience with a review of 12,485 consecutive autopsies. *Arch Pathol Lab Med* 1993; 11: 1027-31.
4. Mitomi M, Kimura K, Iguchi Y, et al. A case of stroke due to tumor emboli associated with metastatic cardiac liposarcoma. *Intern Med* 2011; 50: 1489-91.
5. Butany J, Nair V, Naseemuddin A, et al. Cardiac tumours: diagnosis and management. *Lancet Oncol* 2005; 6: 219-28.