

NOTES cholecystectomy – the first experience in Poland

Maciej Michalik, Michał Orłowski, Agata Frask, Andrzej Małek, Krzysztof Maciejewski

Departments of General and Vascular Surgery, Anaesthesiology and Intensive Care, Gynaecology and Obstetrics,
F. Ceynowa Specialized Hospital, Wejherowo, Poland

Videosurgery and other miniinvasive techniques 2009; 4 (1): 42–45

Abstract

According to SAGES (the Society of American Gastrointestinal and Endoscopic Surgeons) the era of the laparoscopic revolution is over, and the era of natural orifice transluminal endoscopic surgery is coming. Natural orifice transluminal endoscopic surgery (NOTES) may provide the entry point for surgical interventions in the peritoneal cavity, thereby avoiding abdominal wall incisions. The aim of this paper was to present the very first NOTES cholecystectomy in Poland. A transvaginal access procedure was performed on 5th January 2009.

Key words: cholecystectomy, natural orifice transluminal endoscopic surgery, NOTES.

Introduction

In 2005 the Society of American Gastrointestinal and Endoscopic Surgeons (SAGES) published the following statement: “We believe it is fair to say that the laparoscopic revolution is over and that the next great changes for surgeons. There is little doubt that new technology will allow progressively more aggressive interventions *via* a natural body orifice” [1]. Theoretical considerations of the natural orifice transluminal endoscopic surgery (NOTES) procedure derived from an animal model were presented by Dr Anthony Kaloo from the US in 2003. A year later, G.V. Rao and N. Reddy in India performed the first transgastric appendicectomy in a human. In 2006 at the EAES congress in Berlin Dr Rao presented a series of 7 appendicectomies performed with NOTES technique in men. The basic idea of the new method is not to violate the integrity of the abdominal wall integument and not to leave a visible scar (no scar surgery). At present, four natural orifice surgical access points receive

surgeons’ attention: the oral cavity, rectum, urethra and vagina [2, 3].

The first experimental NOTES cholecystectomy through vaginal access was performed on a cadaver in April 2008 in Gdansk [4]. In the Department of General and Vascular Surgery of F. Ceynowa Specialized Hospital endoscopic procedures have been performed since 1987. Most of the practising surgeons do broad-spectrum endoscopic procedures, from diagnostic gastrofibroscopy to therapeutic endoscopy. Having been introduced on 1st April 1993, laparoscopic surgery is simultaneously performed by the same team. We began with cholecystectomies done as the only laparoscopic procedure up to 1995, and since 1996 gradually laparoscopic appendicectomy, TAPP hernioplasty, adrenalectomy and splenectomy have been introduced. Since 1st September 2000 we have broadened our spectrum of laparoscopic procedures with colorectal and bariatric procedures, oesophageal resection, hiatal hernia repair and gastro-oesophageal reflux correction. Finally, total gastrectomy and distal pancreatectomy were also done in laparoscopy.

Address for correspondence

Dr Maciej Michalik, Department of General and Vascular Surgery, F. Ceynowa Specialized Hospital, 10 Jagalskiego St, 84-200 Wejherowo, Poland, phone: +48 58 572 74 20, fax: +48 58 572 74 24, e-mail: michs1@wp.pl

Since 2005, when we first heard of the NOTES idea, preparations to perform such procedures have continued. We attended congresses and conferences on this issue (San Francisco, Yokohama, Stockholm, Chicago and New Orleans), and took part in NOTES workshops in Strasburg, Paris, Barcelona, Nevis and Brussels, where we had an opportunity to practise the new method on animals. We also took part in training on animals held last year at the University of Warmia and Mazury in Olsztyn and organized by Dr Wiesław Pesta in cooperation with the Olympus company. In March and April 2008 a few hybrid procedures were done: the crucial part of cholecystectomy was conducted with a fibreoptic Olympus GIF-Q 165 endoscope introduced into the peritoneal cavity *via* a laparoscopic trocar placed in the umbilicus. One additional 5 mm port was placed for traction of the gallbladder tool and for the clip applicator. Four such procedures were done till satisfactory team coordination and acceptable, short surgery duration was achieved (mean 45 min). A founding meeting of the Polish NOTES Group was held in May 2008 in Bydgoszcz [5]. A ‘road map’ in NOTES development in Poland was discussed. The group is going to function within the Videosurgery section of the Polish Surgical Society. Finally, on January 5th, 2009 the first transvaginal NOTES cholecystectomy was performed.

Case report

A 29-year-old female patient was admitted on 4th January 2009. She had no history of abdominal surgery, nor concomitant diseases. She had been pregnant twice, with one at-term vaginal delivery and

one pre-term birth of a deceased fetus at the 6th month. For approximately half a year she had been complaining of abdominal pain after fatty meals. Abdominal ultrasound confirmed simple cholecystolithiasis, with 5-10 mm gallstones and no evidence of post-inflammatory changes of the gallbladder wall. A NOTES procedure with transvaginal removal of the gall bladder was performed on 5th January 2009 in Wejherowo (Figure 1).

The patient was placed in a gynaecological position and put under combined general anaesthesia (Dr Andrzej Małek). After surgical field preparation, a pneumoperitoneum was created with a Veress needle to a maximum pressure of 12 mm Hg (Figure 2). Then, for increased safety and documentation of the procedure, a laparoscopic camera was introduced through the 5 mm umbilical port. A gynaecologist experienced in transvaginal surgery (Dr Krzysztof Maciejewski) opened the peritoneal cavity through the fornix, and a double-channel fibreoptic Olympus GIF 2T160 endoscope was introduced through an 8-mm incision. Once inspection of the whole peritoneal cavity was accomplished, the laparoscopic camera was removed (Figure 3). Grasping forceps (Olympus, FG-47L-L) were introduced through the left channel of the endoscope, the neck of the gallbladder was clutched and the cystic duct extended to visualize the Callot triangle (Figure 4). A hooked electric knife (Olympus, KD-620LR) was used to release the cystic duct from surrounding tissues. Two clips were placed with a single-shot clip applicator (Olympus, HX-201LR-135L). A single clip was put proximally on the cystic artery and both the artery and cystic duct were cut off. With traction of the gallbladder accomplished using endoscopic

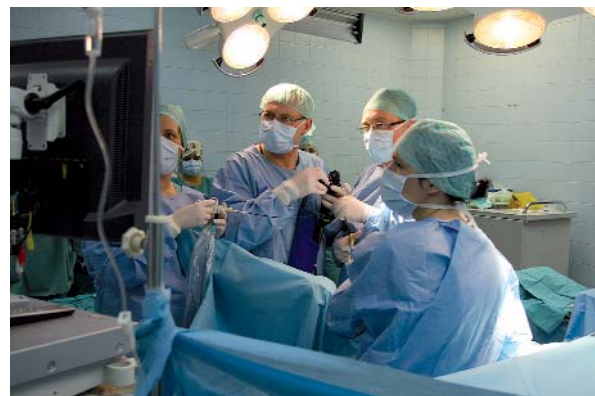
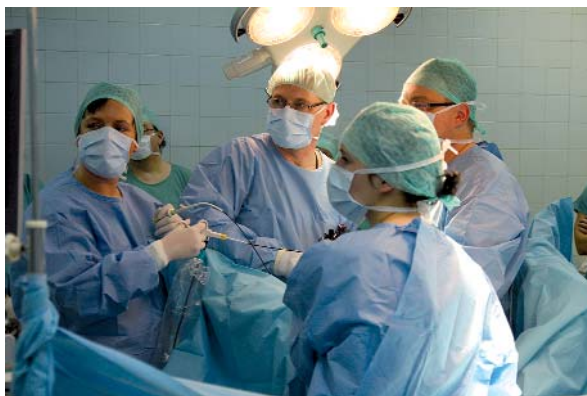
Figure 1. NOTES procedure. Dr Maciej Michalik assisted by Michał Orłowski and Agata Frask and endoscopy nurse Marzena Wykner

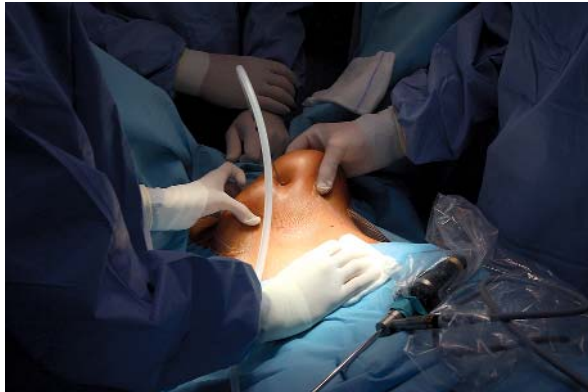

Figure 2. Pneumoperitoneum created with Veress needles

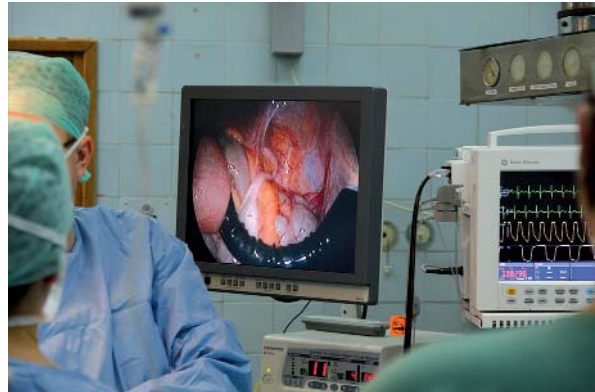

Figure 3. Inspection of the peritoneal cavity with fibroscope seen from laparoscopic camera

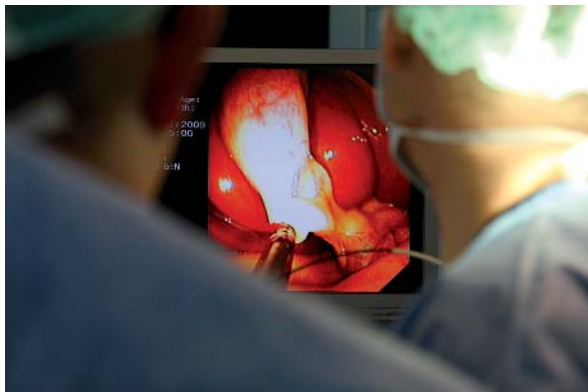


Figure 4. Traction of the gallbladder with endoscopic forceps

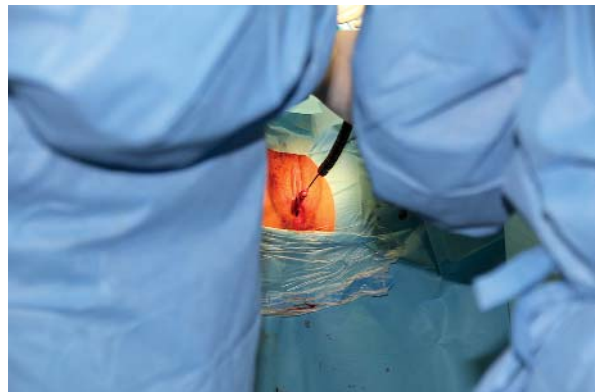

Figure 5. Removal of the gallbladder through the incision in the vagina

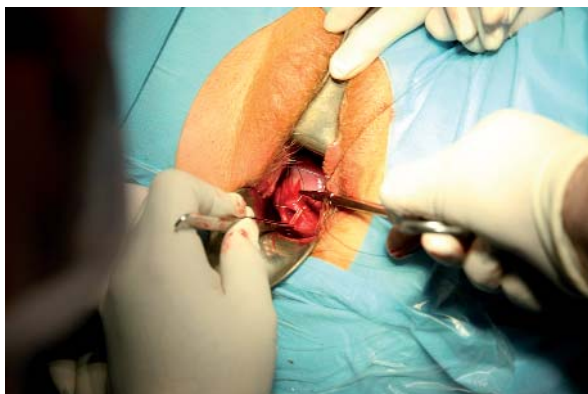

Figure 6. Closure of the fornix incision

forceps, the gallbladder was dissected from the liver surface with an electric knife. As soon as complete haemostasis of the liver was achieved, the resected gallbladder was grasped with an Olympus FQ-45U-1 grasper and removed from the peritoneum after

the endoscope via incision in the fornix of the vagina (Figure 5). Withdrawal of the endoscope with the gallbladder was again followed with the laparoscopic camera. After thorough desufflation of the peritoneum, an incision in the fornix was visualized with the colposcope and closed with a running suture, which ended the whole procedure (Figure 6). The surgery lasted 110 min from incision of the vagina to placement of stitches in the fornix. The patient was extubated on the operative table. For the duration of the procedure, in spite of direct placement of the fibroscope, without a laparoscopic port, the entry point was almost perfectly airtight. Postoperatively the patient required analgesia with intravenous Perfalgan for pain in the upper abdomen as well as a single dose of Zofran for nausea and vomiting. Several hours after surgery had finished, clinically irrelevant subcutaneous emphysema was observed. Oral feeding was introduced on the first

post-operative day and the patient was discharged home in good general condition.

Discussion

Natural orifice surgeries are innovative and so far definitely non-routine procedures for treatment of gallstones. The first such operation in Europe was performed in Strasburg by Marescaux *et al.* on 2nd April 2007 [6]. They also used a double-lumen Olympus endoscope. A few hundred transvaginal or transgastric cholecystectomies have been performed worldwide. During the aforementioned procedure we had some problems and technical difficulties: a crucial problem was to accomplish proper traction of the gallbladder and triangulation due to the extremely small distance of tools protruding from both channels of the endoscope (approximately 8 mm). Coordination of vision and tool placement is another issue, as any movement of the endoscope aimed at improved visualization results in rotation of the operating tools, which totally changes the topography of the surgical field. Additionally, available endoscopic clips cannot be applied on the dilated cystic duct. Considering all this and the present development of technology, we believe this procedure is doable only in highly selected cases with classic anatomy and no extra obstacles such as postoperative intraperitoneal adhesions, cholecystitis or atypical anatomical variations. Both medical and technological aspects affect NOTES development. The market does not offer an operative endoscope designed especially for NOTES. Octopus, and newer Endo-Samurai fibrosopes are a promising step forward, but they are not commercially available yet and they can only be used in experimenting centres. As has been said already, procedures through natural body orifices have not become routine procedures so far. This does not change the fact that the technique seems to be another interesting route in the development of surgery and the minimization of surgery-dependent injury.

References

1. Richards WO, Rattner DW. Endoluminal and transluminal surgery: no longer if, but when. *Surg Endosc* 2005; 19: 461-3.
2. Michalik M, Frask A. Technika podstawowych operacji N.O.T.E.S. (Natural Orifice Transluminal Endoscopic Surgery). *Pol Prz Chir* 2008; 80: 53-9.
3. Michalik M, Frask A, Orłowski M. NOTES (Natural Orifice Transluminal Endoscopic Surgery) – operacje przez naturalne otwory ciała. *Wideochirurgia* 2007; 2: 98-102.

4. Hać S, Kobiela J, Proczko-Markuszczyńska M. Cholecystektomia z dostępu przez pochwę – N.O.T.E.S. – pierwsze starcie. *Wideochirurgia* 2008; 3: 139-41.
5. Michalik M. Founding meeting of the N.O.T.E.S. Development Workgroup. *Videosurgery* 2009; 4: 46.
6. Marescaux J. Operation Anubis: A New Step in NOTES History! Epublication: *WebSurg.com*, Apr 2007; 7 (4).