

Comparative prospective randomized trial: laparoscopic versus open common bile duct exploration

Vladimir Grubnik, Aleksandr Tkachenko, Ksenia Vorotyntseva

Department of Surgery, State Medical University, Clinical Hospital, Odessa, Ukraine

Videosurgery and other miniinvasive techniques 2011; 6 (2): 84-91

DOI: 10.5114/wiitm.2011.23214

Abstract

Introduction: Single-stage laparoscopic procedures for common bile duct (CBD) stones are an alternative treatment option to two-stage endo-laparoscopic treatment and to open choledocholithotomy. Several reports have demonstrated the feasibility, safety, efficiency and cost-effectiveness of laparoscopic techniques.

Aim: To analyse the safety and benefits of laparoscopic compared to open common bile duct (CBD) exploration.

Material and methods: The prospective randomized trial included a total of 256 patients with CBD stones operated from 2005 to 2009 in a single centre. The male/female ratio was 82/174, with a median age 62.3 ± 5.8 years (range 27 to 87 years). There were two groups of patients. Group I: laparoscopic CBD exploration (138 patients). Group II: open CBD exploration (118 patients). Patient comorbidity was assessed by means of the American Society of Anesthesiologists (ASA) classification; ASA II – 109 patients, ASA III – 59 patients. Bile duct stones were visualized preoperatively by means of US examination in 129 patients, by means of ERCP in 26 patients, and by magnetic resonance cholangiopancreatography (MRCP) in 72 patients. Preoperative evaluation was done through medical history, biochemical tests and ultrasonography.

Results: The mean duration of laparoscopic procedures was 82 min (range 40-160 min). The mean duration of open procedures was 90 min (range 60-150 min). Mean blood loss was much lower in the laparoscopic group than in the open group (20 ± 2 v.s 285 ± 27), $p < 0.01$. Postoperative complications were observed in 7 patients of the laparoscopic group and in 15 patients in the open group ($p < 0.01$). Laparoscopic common bile duct exploration was performed through a trans-cystic approach in 76 patients and via choledochotomy in 62 patients. The transcystic approach was successful in 76 patients (74.5%). External drainage was used in 25 (32.8%) patients with the transcystic approach.

Conclusions: Laparoscopic CBD exploration can be performed with high efficiency, and minimal morbidity and mortality. Laparoscopic procedures have advantages over open ones in terms of postoperative morbidity and length of hospital stay.

Key words: common bile duct, common bile duct (CBD) exploration, choledochotomy, transcystic duct extraction (TCDE).

Introduction

Single-stage laparoscopic procedures for common bile duct (CBD) stones are an alternative treatment option to two-stage endo-laparoscopic treatment and to open choledocholithotomy. Several reports have demonstrated the feasibility, safety, efficiency and

cost-effectiveness of laparoscopic techniques [1-4]. Prospective studies of laparoscopic management of CBD stones (CBDS) that included more than 200 patients report success rates ranging from 88% to 97% (mean 92%) [5, 6].

The morbidity rate after laparoscopic CBD exploration ranges from 7% to 19% (mean 8%) [5, 6]. How-

Address for correspondence:

Surgical Department, Odessa Clinic Hospital, 26 Zabolotnogo, Odessa 65117, Ukraine, phone/fax: +38 (048) 750 04 06, e-mail: solnce-sun@ukr.net

ever, some trials demonstrate similar morbidity for open surgery, and shorter hospital stay as the only benefit of laparoscopic procedures. The most frequent complications after laparoscopic CBD clearance are bile leakage, biloma, cholangitis and intra-abdominal haematoma [6]. Several studies attribute this to the biliary drainage, e.g. the complication rate following T-tube is up to 16%, while it reaches only 5% for primary closure. However, other series did not show such results [3, 4]. The rate of residual stones after laparoscopic treatment ranges from 2.6% to 8% (mean 5%) and is equivalent to that of open surgery [3, 7, 8]. The transcystic approach, which is recently preferred in laparoscopic CBD exploration, is used in 26-93% (mean 71%) of cases, with a success rate ranging from 74% to 98% [7, 9, 10].

The main causes of failure of the transcystic approach are impacted stones, stones whose diameter is greater than 5-7 mm, multiple stones and unfavourable anatomy. The main cause of failure of choledochotomy is impacted stones as well [6, 7].

Thus, there are many controversies in choosing the appropriate single-stage procedure for CBD stones clearance (laparoscopic transcystic, laparoscopic choledochotomy, open choledochotomy) so far. Currently, most Eastern surgeons prefer open choledocholithotomy to the laparoscopic approach for the treatment of CBD stones.

Aim

The aim of the study was to analyse the safety and benefits of laparoscopic CBD exploration compared to open.

Material and methods

The prospective randomized trial included a total of 256 patients with CBD stones operated on from 2005 to 2009 in a single centre. The male/female ratio was 82/174, with a median age of 62.3 ±5.8 years (range 27 years to 87 years). For the randomization we used the method of Cuschieri [3, 7]. There were two groups of patients. Group I: laparoscopic CBD exploration (138 patients). Group II: open CBD exploration (118 patients).

Patient comorbidity was assessed by means of the American Society of Anesthesiology (ASA) scoring system; the score was ASA II – 109 patients, ASA III – 59 patients. Bile duct stones were visualized preoperatively by means of US examination in 129 patients, by means of endoscopic retrograde cholangiopancreatography (ERCP) in 26 patients, and by magnetic resonance cholangiopancreatography (MRCP) in 72 patients.

Preoperative evaluation was done through medical history, biochemical tests and ultrasonography. Patient demographics are shown in Table I. There was no statistically significant difference between the 2 groups of patients.

Surgical technique

The surgical technique described in detail previously is outlined briefly. The first step of the procedure is intraoperative cholangiography (IOC) which confirms or diagnoses CBDS and provides information about the number, size, and location of the stones and the anatomy of cystic and common bile ducts. The choice between transcystic duct extraction

Table I. Patient demographics

Parameters	Group I, Lap CBD (n = 138)	Group II, Open CBD (n = 118)	Value of p
Gender (M/F)	42/96	40/78	> 0.2
Age	61.9 ±5.2 (27-81)	63.1 ±6.4 (29-87)	> 0.2
ASA II/III	55/29	54/30	> 0.05
Acute cholecystitis	45 (32.6%)	41 (34.7%)	> 0.05
Jaundice	26 (18.8%)	32 (27.1%)	> 0.05
Biliary pancreatitis	29 (21.0%)	28 (23.7%)	> 0.05
US diameter of CBD	9.2 (6-13)	11.3 (8-15)	> 0.05

ASA – American Society of Anesthesiology, CBD – common bile duct

(TCDE) and choledochotomy depends on this information.

Transcystic duct extraction

Transcystic duct extraction was used for small stones (< 7 mm) located below the cystic duct, notably in the CBD. In the majority of TCDE the cystic duct needs to be dilated. Dilatation is performed with blunt, flexible dilators introduced by a 5-mm trocar inserted upright to the cystic duct opening. After dilatation a 3-mm flexible choledochoscope is introduced into the cystic duct. Small stones can be flushed or pushed through the papilla, but in the majority of cases the stones are extracted with a Dormia basket under choledochoscopic control. After extraction a completion cholangiography has to be performed because the upper bile ducts are accessible to choledochoscopy in only 10-15% of cases. Then the cystic duct is usually closed with an absorbable suture. Transcystic biliary drainage is used only in cases of cholangitis.

Choledochotomy

A choledochotomy is indicated for large stones (> 7 mm), numerous stones (> 5), or when the stones are located above the cystic duct implantation into the CBD and after failure of TCDE. The first step is to achieve good exposure of the porta hepatis. It is obtained by lifting the round ligament with a transparietal suture and by pulling the cystic duct up and laterally. The anterior aspect wall of the common bile duct is cleared on a length of 10 mm to 20 mm. The choledochotomy is performed vertically on the supraduodenal part of the anterior aspect of the CBD. The CBDS extraction is the most difficult step. All the stones visible through the choledochotomy can be extracted with atraumatic forceps. Stones located in the lower part of the CBD can be pushed through the choledochotomy by pressure on the CBD wall with blunt forceps or flushed through the choledochotomy with saline irrigation. The remaining stones are extracted with a Dormia basket under choledochoscopic control. The most difficult cases to manage are impacted stones because often they cannot be extracted with a Dormia basket so electrohydraulic lithotripsy needs to be used. Once the stones are fragmented they are retrieved with a Dormia basket or pushed through the papilla. We have never used papilla dilation because of the risk of

pancreatitis. Once the extraction of stones is over, the choledochotomy is closed with an absorbable running suture and a completion IOC is performed to check that there are no residual stones and to check the watertightness of the suture. Biliary drainage by T-tube rather than a transcystic drain is used in the case of cholangitis, porta hepatis inflammation, or when the number of stones is more than 5 or 6. In all cases subhepatic drainage is used. In the case of biliary drainage a cholangiography is performed on the third postoperative day. If there is no residual stone, the drain is closed and will be removed on an outpatient basis on the 21st postoperative day.

Open procedures were performed with bile duct stone exploration and T-tube in all patients.

Statistical analysis

Analysis of the statistical significance of differences between groups of data was performed with two-tailed Fisher's exact test, χ^2 , Wilcoxon, and one-way analysis of variance (ANOVA), as appropriate. A *p*-value of 0.05 or less was considered statistically significant. All analyses were performed with the statistical package JMP (version 6.0.2).

Results

No mortality occurred. The mean duration of laparoscopic procedures was 82 min (range 40-160 min). The mean duration of open surgery was 90 min (range 60-150 min). There were no differences between laparoscopic and open procedures (*p* > 0.1) (Table II). Mean blood loss was much less in the laparoscopic group than in the open group (20 ± 2 vs. 285 ± 27), *p* < 0.01 (Table II).

Postoperative complications were observed in 7 patients of the laparoscopic group and in 15 patients in the open group (*p* < 0.01).

Stone clearance

Laparoscopic common bile duct exploration was performed through a transcystic approach in 76 patients and via choledochotomy in 62 patients. The first attempt at CBDS extraction was a transcystic approach. The cystic duct was dissected close to the gallbladder and clipped after identification to prevent stone migration during surgery. Further dissection of the cystic duct was carried out towards the common bile duct in order to facilitate the introduction of the

Table II. Patient demographics and clinical outcome data

Parameters	Transcystic approach (n = 76)	Choledochotomy (n = 62)	Value of p
Age	56.5	66	< 0.01
ASA II/III	19/18	30/17	< 0.05
Acute cholecystitis	22 (28.9%)	23 (37%)	> 0.05
Jaundice	26 (18.8%)	32 (27.1%)	> 0.05
Biliary pancreatitis	29 (21.0%)	28 (23.7%)	> 0.05
Number of CBD stones	4 (1-8)	2.5 (1-40)	< 0.01
US diameter of CBD	4.5 (2-8)	10.5 (5-28)	< 0.01
Operative time [min]	62 (40-120)	90 (45-160)	< 0.01
Stone clearance	70 (92%)	60 (97%)	< 0.05
Conversion to open surgery	1	1	
LOS	2.5 (1.5-1.4)	6 (3-22)	< 0.01

LOS – length of hospital stay

flexible choledochoscopy (FCD) through a small incision in the cystic duct. If stones could not be extracted through the cystic duct (e.g., because of size incompatibility) a choledochotomy was performed.

There were 102 attempts to perform transcystic exploration of CBD. The transcystic approach was successful in 76 patients (74.5%). The transcystic approach was unsuccessful in 26 patients (25.5%). Reasons for failure were a narrow cystic duct in 4 patients, multiple stones in 12 patients, large stones in 6 patients and anatomical considerations in

5 patients. External drainage was used in 25 patients (32.8%) with the transcystic approach. Reasons for external drainage were cholangitis, biliary pancreatitis, transpapillary manoeuvres, and suspicion of retained stones.

Antegrade stenting was done in 19 patients from the transcystic approach group (Figure 1). Stone clearance in 62 patients after choledochotomy was successful in 54 patients (80%) (Figure 2).

Patients who underwent laparoscopic common bile duct exploration (LCBDE) via the transcystic

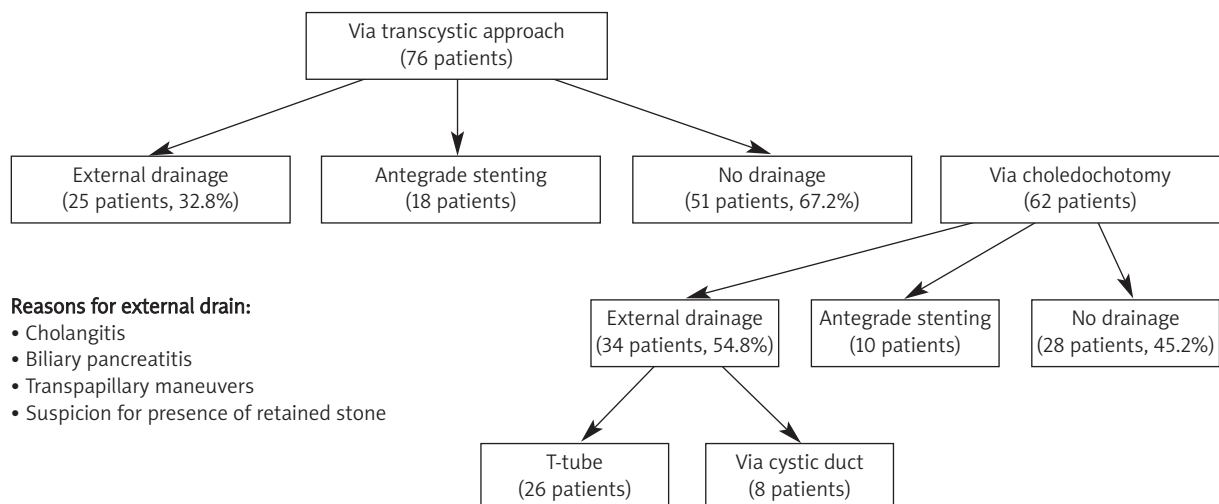


Figure 1. Drainage in common bile duct in laparoscopic group

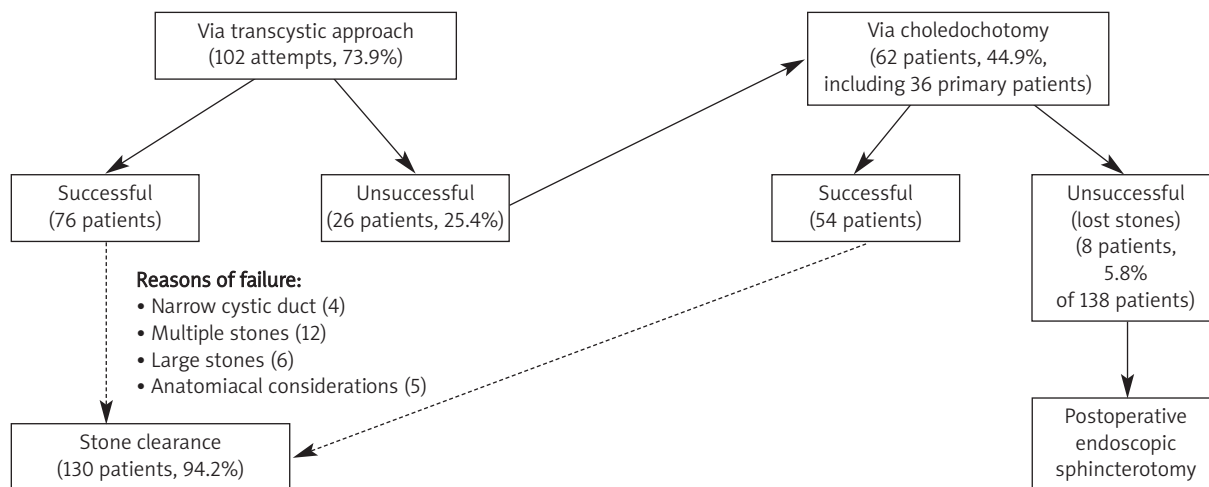


Figure 2. Success rate of stone extraction in laparoscopic group

Table III. Complication rate in laparoscopic versus open group

Complication	LAP (n = 138)	OPEN (n = 118)	Value of p
Severe acute cholecystitis	1	2	< 0.01
Dislocation of drain	1	2	< 0.01
Intra-abdominal bleeding	1	1	
Bile leak	2	1	< 0.01
Infrahepatic abscess	2	4	< 0.01
Wound infection	1	5	
Conversion to open procedure	2	1	< 0.01
Morbidity	9	15	< 0.01

LOS – length of hospital stay

approach were significantly younger, had less comorbidity and were treated for smaller stones. The duration of LCBDE with choledochotomy was significantly longer as well as the length of hospital stay (LOS). The morbidity in both groups was similar, but stone clearance was higher in the choledochotomy group.

Conversion to open procedure was performed in 2 patients. The reasons for conversion were severe inflammation and unheard anatomy in 1 case and Mirizzi type II syndrome in the other. Morbidity in the laparoscopic group was 6.5%. Complications after laparoscopy are shown in Table III.

Re-laparoscopy was done in 2 patients for dislocation of drainage in one and intra-abdominal bleeding in 1 patient. In 2 patients with bile leak RCP and

biliary standing were done with good results. Infrahepatic abscesses in 2 patients were punched and drained under US guidance.

Open choledochotomy with T-tube placed was performed in 118 patients. Stone clearance during open surgery was successful in 113 patients. One patient underwent an open stone extraction via duodenotomy because of an entrapped stone in the ampulla. Four patients with retained stones after an open procedure were treated by postoperative ERCP and stone extraction, which was successful in 3 patients and unsuccessful in 1 patient (Figure 3). This patient had a big duodenal diverticulum so it was too dangerous to perform endoscopic sphincterotomy; he had a second open procedure with successful stone clearance.

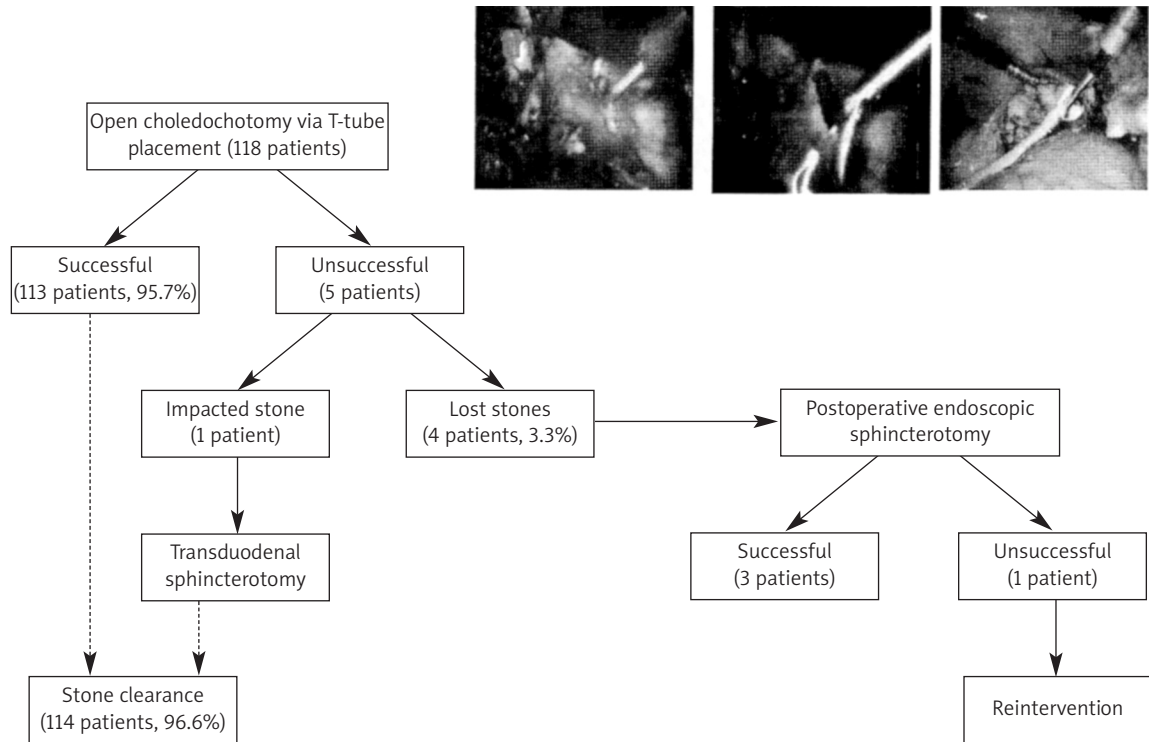


Figure 3. Success rate of stone extraction in open group

Morbidity in the open group was higher (12.7%) than in the laparoscopic group 65% (Figure 4).

Three patients were reoperated on: 2 for dislocation of drainage, 1 for progressive bile peritonitis. Four patients had intra-abdominal abscesses which were successfully drained under US guidance.

Discussion

Laparoscopic cholecystectomy is considered as a gold standard for the treatment of symptomatic cholecystolithiasis. Therefore, it seemed logical to extend the benefits of the laparoscopic approach to the treatment of CBDS, with the aim of having less morbidity and mortality that is associated with open surgery, to avoid specific complications and sequelae of endoscopic shincterotomy (ES), and to treat the patient with a single-stage procedure.

The randomized studies comparing ES combined with laparoscopic cholecystectomy (LC) to laparoscopic management report similar success rates. In these studies the success rate varies from 87% to 97%, the morbidity rate varies from 10% to 17%, and the mortality rate varies from 5% to 11%. Hospital stay was shorter after laparoscopy. Cuschieri *et al.*

Morbidity (15 patients, 12.7%)	
- Dislocation of drain (2)	→ Reintervention, correction
- Bile leak with progressive peritonitis (1)	→ Reintervention
- Intraabdominal abscess (4)	→ Percutaneous drainage under US guidance
- Wound infection (5)	
- Urinary tract infection (2)	
- Pneumonia (3)	
- Severe cholangitis (4)	

Figure 4. Morbidity in open group

conclude that laparoscopic treatment is preferable for ASA II and ASA III patients, while ES is indicated for high-risk patients.

Prospective studies of laparoscopic management of CBDS that included more than 200 patients report success rates ranging from 88% to 97% (mean 92%) [3, 4, 9], similar to ES success rates, which range from 81% to 100% (mean 91%), but the clearance of CBDS after ES is obtained in 17-35% of cases after two to five attempts [5-7, 11], while laparoscopic treatment of CBDS is a one-stage procedure.

High rates of pancreatitis (7.3%) and bile leakage (14.6%) following LCBDE with choledochotomy have

been reported, indicating that the passage of the ampulla of Vater should be avoided and choledochotomy should be reserved for large stones that cannot be extracted through the cystic duct. Indeed, these complications were observed in a case series of choledochotomy in 42% of patients [8-10]. In the present study no postoperative pancreatitis was observed, while bile leakage developed in one patient only. This may be explained by the large proportion of successful trans-cystic LCBDE and by the use of a flexible choledochoscope enabling direct visualization of the entire intrabiliary procedure, thus preventing any potential trauma or passage of the ampulla of Vater. Another potential advantage of the flexible choledochoscope is its therapeutic use in patients with intrahepatic lithiasis or as a diagnostic tool in patients with biliary lesions suspected to be neoplastic.

The morbidity rate after ES followed by LC ranges from 3% to 16% (mean 13%), while after laparoscopy it ranges from 7% to 19% (mean 8%) [1, 3, 7, 9]. The mortality rate after ES + LC ranges from 0% to 6% (mean 2%) and is twice the rate after laparoscopy, which is 1% [2-4, 7].

The rate of residual stones after laparoscopic treatment ranges from 2.6% to 8% (mean 5%) and is equivalent to that of open surgery [3, 5, 10]. However, if we consider that all stones remaining after the first attempt of stone extraction are residual stones, the rate of residual stones after ES ranges from 17% to 35% [2, 3, 5], far more frequent than for laparoscopic management. In our series we had a rate of 2.8% of residual stones. To minimize the risk of residual stones it is necessary to perform choledochoscopy and completion cholangiography after extraction of stones in all patients.

Only a few publications deal with late complications of laparoscopic management of CBDS [3].

The rate ranges from 0% to 3.2%, while after ES it ranges from 2% to 22% [4, 6, 8, 11]. The most frequent complications are recurrent stones. Tanaka *et al.* [7, 9] report a continuing accrual of recurrent stones up to 25 years after ES. In a series of 331 patients who were managed laparoscopically and followed for a median of 43 months, Ricciardi *et al.* [7, 11] observed no biliary complications.

The laparoscopic treatment of CBDS can be performed by a transcystic approach or by choledochotomy, with each technique having its own indications. The choice between these two techniques depends on information provided by IOC, i.e., the

size, number, and location of the stones and the anatomy and diameter of the cystic duct and CBD.

In the literature TCDE was used in 26-93% (mean 71%) [4, 8, 10, 11] of cases, with a success rate ranging from 74% to 98% [9, 10]. In our series TCDE was performed in 73.9% of cases and was successful in 76 patients. The 27 failures were managed by laparoscopic choledochotomy and by postoperative ES.

The majority of failures would probably now be treated by laparoscopy. The main causes of failure were impacted stones and stones whose size was greater than 5 mm.

In our practice the transcystic approach is used for small stones (< 7 mm) if the number of stones is fewer than 5 or 6 and if the stones are located below the cystic duct-CBD junction. Choledochotomy by first intention is indicated when the stones are larger than 7 mm, there are more than 5 or 6, or when the stones are located in the proximal biliary tree. The necessary conditions to perform a choledochotomy are a CBD diameter of 5 mm or more and a proficiency in laparoscopic sutures. The rate of complications and the postoperative hospital stay depend on the technique of stone extraction used.

Conclusions

Laparoscopic CBD exploration can be performed with high efficiency, and minimal morbidity and mortality. Laparoscopic procedures have advantages over open surgery in terms of postoperative morbidity and length of hospital stay. The transcystic approach is feasible in most patients, whereas choledochotomy should be restricted to large and multiple stones. No approaches guarantee complete stone clearance.

References

1. Topal B, Vromman K, Aerts R, et al. Hospital cost categories of one-stage versus two-stage management of common bile duct stones. *Surg Endosc* 2009; 24: 413-6.
2. Clayton ES, Connor S, Alexakis N, Leandros E. Metaanalysis of endoscopy and surgery versus surgery alone for common bile duct stones with the gallbladder in situ. *Br J Surg* 2006; 93: 1185-91.
3. Petelin JB. Laparoscopic common bile duct exploration. Lesson learnt from > 12 years experience. *Surg Endosc* 2003; 17: 1705-15.
4. Poulouse BK, Arbogast PG, Holzman MD. National analysis of in-hospital resource utilization in choledocholithiasis management using propensity scores. *Surg Endosc* 2006; 20: 186-90.
5. Berthou JC, Dron B, Charbonneau P, et al. Evaluation of laparoscopic treatment of common bile duct stones in a prospective

- series of 505 patients: indications and results. *Surg Endosc* 2007; 21: 1970-4.
6. MacFadyen B. Intraoperative cholangiography: past, present, and future. *Surg Endosc* 2006; 20: S436-40.
 7. Riciardi R, Islam S, Canete JJ, et al. Effectiveness long-term results of laparoscopic common bile duct exploration. *Surg Endosc* 2003; 17: 19-22.
 8. Tokamura H, Umezawa A, Cao H, et al. Laparoscopic management of common bile duct stones: transcystic approach and choledochotomy. *J Hepatobil Pancreat Surg* 2002; 9: 206-12.
 9. Topal B, Aerts R, Penninckx F. Laparoscopic common bile duct stone clearance with flexible choledochoscopy. *Surg Endosc* 2007; 21: 2317-21.
 10. Waage A, Stromberg C, Leijonmarck CE, Arvidsson D. Long-term results from laparoscopic common bile duct exploration. *Surg Endosc* 2003; 17: 1181-5.
 11. Tranter SE, Thompson MH. Comparison of endoscopic sphincterotomy and laparoscopic exploration of the common bile duct. *Br J Surg* 2002; 89: 1495-504.