

# Surgical management of gastrointestinal stromal tumors: a single center experience

Eligijus Poškus<sup>1</sup>, Pavel Petrik<sup>1</sup>, Eglė Petrik<sup>2</sup>, Vytautas Lipnickas<sup>1</sup>, Juozas Stanaitis<sup>1</sup>, Kęstutis Strupas<sup>1</sup>

<sup>1</sup>Clinic of Gastroenterology, Nephrourology and Surgery, Center of Abdominal Surgery, Vilnius University, Faculty of Medicine, Vilnius, Lithuania

<sup>2</sup>Department of Physiology, Biochemistry and Laboratory Medicine, Vilnius University, Faculty of Medicine, Vilnius, Lithuania

Videosurgery Miniinv (e-pub, ahead of print)

DOI: 10.5114/wiitm.2014.40987

## Abstract

**Introduction:** Gastrointestinal stromal tumors (GISTs) are the most common mesenchymal tumors of the gastrointestinal (GI) tract. Although the therapy targeted at inhibiting tyrosine kinases has shown dramatic results in metastatic and inoperable GISTs, the mainstay of treatment in primary localized forms remains surgical resection.

**Aim:** To provide an overview of our experience of GIST diagnosis and management, with emphasis on comparison of minimally invasive and open surgical resection for primary GISTs.

**Material and methods:** We retrospectively reviewed the medical records of all patients who underwent surgical removal of GISTs from 2008 to 2012. Patient demographics, clinical data, surgery, complications, histopathological data and clinical course were analyzed.

**Results:** Forty-four patients were identified. Average age at diagnosis was 63 years. Minimally invasive (MIS) and open surgery (OS) were each attempted in 22 (50.0%) patients. Laparoscopic removal was performed in 20, laparoscopic in 1, and laparoscopy-assisted endoscopic removal in 1. Conversion to an open procedure was performed in 4 (18.2%). We found significant differences in postoperative length of stay (8.5 days vs. 10.1 days,  $p < 0.001$ ) and tumor size (2.93 cm vs. 5.78 cm,  $p = 0.018$ ) between MIS and OS groups, respectively.

**Conclusions:** Laparoscopic removal is safe and effective for GISTs not exceeding 6 cm. Gastroesophageal junction and cardia GISTs require careful preoperative evaluation and planning to remove safely. We recommend avoiding laparoscopic removal of these tumors due to the high rate of conversion (100.0%) to an open procedure. Laparoscopic surgical approach is an appropriate technique for removal of small-sized intraluminal benign GISTs not involving the muscularis propria layer.

**Key words:** minimally invasive surgery, gastrointestinal stromal tumors, gastrointestinal stromal tumors.

## Introduction

Gastrointestinal stromal tumors (GISTs) are the most common mesenchymal neoplasms of the gastrointestinal (GI) tract [1]. The reported annual incidence is about 10–20 cases per 1 million individuals [2]. These tumors occur in patients of all ages, with a median age of 55–60 years [3], affecting males and females at the same rate.

Gastrointestinal stromal tumors most commonly occur in the stomach (50–70% of cases), followed by the small intestine (20–30% of cases) [4, 5]. However, these tumors are found throughout the GI tract. Gastrointestinal stromal tumors of the esophagus, colon and rectum account for less than 10% of all cases [4, 5]. Uncommonly, they can arise within the greater omentum, appendix and gallbladder.

### Address for correspondence:

Prof. Eligijus Poškus, Clinical of Gastroenterology, Nephrourology and Surgery, Center of Abdominal Surgery, Vilnius University Hospital, Santariskiu 2, LT 08661 Vilnius, Lithuania, phone: +37068635656, fax: +37052365101, e-mail: eligijus.poskus@santa.lt

The interstitial cells of Cajal, pleuropotential intestinal pacemaker cells, were identified as the origin of GISTs [6]. The key characteristic of GIST is gain-of-function sporadic mutation within the genes coding for the tyrosine kinase receptors, which is supposed to be the driving force of cell proliferation in the GIST [7]. Tyrosine kinase receptor (c-kit) is a transmembrane receptor that is activated by the binding of KIT protein, a c-kit proto-oncogene product. Up to 80% of GISTs have KIT protein mutations, while 8% have mutations in the platelet derived growth factor receptor  $\alpha$  (PDGFR $\alpha$ ),  $\alpha$ -polypeptide gene encoding a c-kit homologous type III receptor tyrosine kinase protein [8]. The essential ligand-independent activation of the mutated KIT protein results in imbalance between cell survival and proliferation, away from apoptosis [9]. The specific immunohistochemical markers of the tumors are CD117 – 95% positivity, CD34 – 70–80% positivity, SMA (smooth muscle actin) – 20–30% positivity, and desmin – < 5% positivity [10].

Most GISTs are diagnosed incidentally during preventive diagnostic studies or investigation for nonspecific GI symptoms. On abdominal computed tomography (CT) scan, a GIST typically appears as a hyperdense mass, closely associated with adjacent organs (stomach, small intestine). On upper GI endoscopy (UGIE), a GIST usually looks like a submucosal mass with usually central ulceration. Endoscopic ultrasound (EUS) can define the layer of the stomach wall that gives rise to the tumor. Upper GI endoscopy or EUS is an essential diagnostic modality to obtain tissue for histological diagnosis, usually by core-needle biopsy or fine-needle aspiration (FNA). Moreover, these diagnostic methods can also help decide whether endoscopic removal of the tumor is possible. Localization of the GIST, following UGIE with biopsy or EUS with FNA, within the smooth muscle layer and gain of neoplastic spindle cells with mutations in the c-KIT or PDGFR $\alpha$  genes are pathognomonic features. Often, however, UGIE is non-contributory. Moreover, acquiring tissue with endoscopic biopsy forceps frequently does not obtain enough tissue to perform histological diagnosis.

Better understanding of the nature of GISTs has enabled the development and application of targeted therapy. Such therapy, using tyrosine kinase inhibitors, has demonstrated efficiency in the treatment of metastatic and inoperable GISTs [11]. Nevertheless, at this time surgical resection presents the only possibility of cure for primary localized GISTs.

A complete surgical resection can be performed in up to 95% of these cases. The modern surgical treatment of GISTs combines the use of targeted therapy and aggressive minimally invasive surgery to provide effective treatment for this lethal GI malignancy [12]. Tumor-free microscopic surgical margins and tumor size were demonstrated to be the most important prognostic factors determining survival. It is therefore accepted that the surgical goal should be a complete segmental or wedge resection with tumor-free margins only without routine lymphadenectomy for tumors whose size and location technically allow for it [13]. However, the operative technique for complete surgical resection for primary solitary GISTs of various locations is at issue. Both open and minimally invasive operations have been shown to reduce recurrence rates and improve long-term survival. Retrospective series suggest that minimally invasive techniques may reduce perioperative stress and are associated with lower rates of postoperative complications, shorter hospital stays and equivalent recurrence rates. Maximum diameter of GIST for laparoscopic resection, however, is still not clearly defined. Moreover, GISTs located in proximity to the gastroesophageal junction (GEJ) or at the cardia can prove challenging to manage laparoscopically as the deformity after resection of such lesions can result in gastroesophageal reflux or late stenosis. Gastrointestinal stromal tumors involving the prepyloric part of the stomach have also been reported to be difficult to remove using minimally invasive technique [14].

Advances in endoscopic technology have allowed attempted excision of GISTs and other gastric submucosal masses to be performed endoscopically [15]. A combined laparoendoscopic approach has been reported in several series for resection of gastric GISTs, located in the gastroesophageal junction, cardia and posterior wall of the stomach [16–18]. However, most of these studies have a small number of cases; therefore safety and efficacy of this treatment are not yet established.

## Aim

The aim of the present study is to provide an overview of our experience of GIST diagnosis and management, with emphasis on comparison of minimally invasive and open surgical resection for primary localized gastrointestinal stromal tumors.

## Material and methods

The medical records of 47 consecutive patients were reviewed retrospectively from the database for all suspected GISTs to have undergone primary laparoscopic, laparoendoscopic or open resection from January 1, 2008 to December 31, 2012. All operations were performed in Vilnius University Hospital, at the Center of Abdominal Surgery, Vilnius, Lithuania. Histologic diagnosis of all tumors was confirmed post-operatively by pathologists of the National Centre of Pathology, Vilnius, Lithuania. Within this group, only patients presenting with a primary solitary GIST, surgically resectable, were selected. Three patients were excluded: one patient because of presenting with a recurrence of a GIST treated previously, and 2 patients because of presenting with gastric adenocar-

cinomas, confirmed by histology after the operation. Forty-four patients out of 47 observed were identified as having GISTs resected at our institution. Operative notes were reviewed for the technique employed.

Patients were staged preoperatively through UGIE, EUS, biopsy, abdominal ultrasound (US), CT or magnetic resonance tomography (MRT) scans (Table I). Our surgical approach was based on preoperative investigation, and was determined by tumor size, location and growth character (exophytic or endophytic).

Patients were applicable for laparoscopic surgery if preoperative investigation showed a localized, non-metastatic extramucosal tumor. Tumors were required to be of a diameter and in a position which suggested resectability through segmental or wedge resection.

**Table I.** Diagnostic characteristics of patients operated on for gastrointestinal stromal tumors

| Diagnostic workup |            |            |            |            |          |          | N (%)      |
|-------------------|------------|------------|------------|------------|----------|----------|------------|
| UGIE              | EUS        | B/FNA      | CT         | US         | MRT      | CTA      |            |
| +                 |            |            |            |            |          |          | 1 (2.27)   |
| +                 |            | +          |            |            |          |          | 1 (2.27)   |
| +                 | +          |            |            |            |          |          | 1 (2.27)   |
| +                 | +          | +          |            |            |          |          | 2 (4.55)   |
| +                 |            |            | +          |            |          |          | 3 (6.82)   |
| +                 |            | +          | +          |            |          |          | 6 (13.64)  |
| +                 |            | +          |            | +          |          |          | 1 (2.27)   |
| +                 |            |            |            |            |          | +        | 1 (2.27)   |
| +                 | +          |            | +          |            |          |          | 6 (13.64)  |
| +                 | +          | +          | +          |            |          |          | 7 (15.91)  |
| +                 | +          | +          |            | +          |          |          | 1 (2.27)   |
| +                 | +          |            | +          | +          |          |          | 1 (2.27)   |
| +                 |            |            | +          | +          |          |          | 2 (4.55)   |
| +                 |            | +          | +          | +          |          |          | 2 (4.55)   |
|                   | +          |            | +          | +          |          |          | 1 (2.27)   |
|                   |            |            | +          |            |          |          | 3 (6.82)   |
|                   |            |            | +          | +          |          |          | 3 (6.82)   |
|                   |            |            | +          | +          | +        |          | 1 (2.27)   |
|                   |            |            | +          |            | +        |          | 1 (2.27)   |
| 35 (79.5%)        | 19 (43.2%) | 19 (43.2%) | 36 (81.8%) | 12 (27.3%) | 2 (4.5%) | 1 (2.3%) | 44 (100.0) |

UGIE – upper gastrointestinal endoscopy, EUS – endoscopic ultrasound, B – biopsy, FNA – fine-needle aspiration, CT – computed tomography, US – ultrasound, MRT – magnetic resonance tomography, CTA – computed tomography angiography

An endoscopic approach was applied to patients who presented with a solitary intraluminal tumor of the gastric cardia, expected to be benign (very low or low risk of aggressive behavior). Tumors were required to be of a diameter which proposed complete removal through endoscopic enucleation and further extraction through the oral cavity.

When complete removal of the tumor by means of laparoscopy-assisted endoscopy was not possible, laparoendoscopic technique was applied. After pneumoperitoneum was established, an initial diagnostic laparoscopy was performed. Additionally, two 5-mm metal trocars were inserted into the peritoneal cavity. A gastroscope was introduced to inflate the stomach. Dilute epinephrine was injected submucosally beneath the tumor in order to reduce intraoperative bleeding and facilitate dissection. In that case,

**Table II.** Risk of aggressive behavior in GISTs (according to [6])

| Risk         | Size (largest dimension) [cm] | Mitotic count [HPF] |
|--------------|-------------------------------|---------------------|
| Very low     | < 2                           | < 5/50              |
| Low          | 2–5                           | < 5/50              |
| Intermediate | < 5                           | 6–10/50             |
|              | 5–10                          | < 5/50              |
| High         | > 5                           | > 5/50              |
|              | > 10                          | Any mitotic rate    |

one part of the tumor was resected endoscopically, and the remaining part of the tumor laparoscopically. The gastric defect was sutured laparoscopically with Vicryl 3-0.

Gastrointestinal stromal tumors not appropriate for purely laparoscopic or combined laparoendoscopic resection, or involving adjacent structures, were considered for open resection.

When necessary, intraoperative endoscopy was performed to specify the tumor location.

Data on patient demographics, symptoms on presentation, preoperative tumor localizing studies, tumor location, operation performed, operative time, histopathological features, overall and postoperative length of stay and clinical course were collected and analyzed. Histopathological features reviewed included margin status, tumor size, mitotic rate, immunohistochemical marker status (CD117, CD34, SMA, DES and S-100) and presence of ulceration and central necrosis of the tumor. Mitotic rate was defined as the number of mitoses per 50 high-power fields (HPF), and tumor size was defined as the maximal tumor diameter in the resected specimen. Mutational analysis was performed where required.

For estimating the risk of aggressive behavior and disease progression, patients were stratified into four categories (very low, low, intermediate and high) according to the Fletcher *et al.* classification, 2002 (Table II), based on tumor size and mitotic count, and into five categories (none, very low, low,

**Table III.** Rates of metastases or tumor-related death in GISTs (according to [10])

| Tumor parameters |                 | Risk of progressive disease |                         |                |              |
|------------------|-----------------|-----------------------------|-------------------------|----------------|--------------|
| Mitotic rate     | Tumor size [cm] | Gastric GISTs               | Jejunal and ileal GISTs | Duodenal GISTs | Rectal GISTs |
| ≤ 5/50 HPFs      | ≤ 2             | None                        | None                    | None           | None         |
|                  | > 2<br>≤ 5      | Very low (1.9%)             | Low (4.3%)              | Low (8.3%)     | Low (8.5%)   |
|                  | > 5<br>≤ 10     | Low (3.6%)                  | Moderate (24%)          | High (34%)     | High (57%)   |
|                  | > 10            | Moderate (12%)              | High (52%)              |                |              |
| > 5/50 HPFs      | ≤ 2             | None                        | High (50%)              | §              | High (54%)   |
|                  | > 2<br>≤ 5      | Moderate (16%)              | High (73%)              | High (50%)     | High (52%)   |
|                  | > 5<br>≤ 10     | High (55%)                  | High (85%)              | High (86%)     | High (71%)   |
|                  | > 10            | High (86%)                  | High (90%)              |                |              |

§No tumors of such category were included in the study.

**Table IV.** Clinical presentation regarding tumor location

| Symptoms                             | Stomach<br>(n = 35) | Duodenum<br>(n = 2) | Jejunum<br>(n = 3) | Ileum<br>(n = 2) | Mesentery<br>(n = 2) | Overall<br>(n = 44) |
|--------------------------------------|---------------------|---------------------|--------------------|------------------|----------------------|---------------------|
| Bleeding                             | 6                   | 1                   | 1                  | 1                |                      | 9 (20.5%)           |
| + AP                                 | 2                   |                     |                    |                  |                      |                     |
| + DS                                 | 1                   |                     |                    |                  |                      |                     |
| Abdominal pain                       | 16                  |                     | 1                  |                  | 1                    | 18 (40.9%)          |
| + DS                                 | 8                   |                     |                    |                  |                      |                     |
| + PAM                                |                     |                     |                    |                  |                      |                     |
| + DA + PAM                           | 2                   |                     |                    |                  |                      |                     |
| Dyspeptic symptoms                   | 3                   | 1                   |                    |                  |                      | 4 (9.1%)            |
| Asymptomatic<br>(incidental finding) | 10                  |                     | 1                  | 1                | 1                    | 13 (29.5%)          |

AP – abdominal pain, DS – dyspeptic symptoms, PAM – palpable abdominal mass

intermediate and high) according to the Miettinen and Lasota classification, 2006 (Table III), based on tumor size, location and mitotic rate. These classifications consider rather different parameters; therefore we used both of them in order to detect any differences within, regarding symptoms on presentation, tumor location, mean maximum tumor diameter and surgical procedures performed.

All patients with confirmed high risk of aggressive GIST without spreading features were followed up regularly including UGIE and abdominal CT scan every 6 to 12 months. Vital status and tumor recurrence were assessed.

### Statistical analysis

Data are expressed as mean  $\pm$  standard deviation, unless otherwise specified. Statistical analysis was performed using Mann-Whitney *U* test and ANOVA with Tukey's test (if needed) for analyzing differences between small groups. Value of  $p < 0.05$  was considered significant. Data analysis was performed using SPSS version 20.0.

## Results

### Patient characteristics

Between January 1, 2008 and December 31, 2012, 44 consecutive patients underwent surgical treatment for gastrointestinal stromal tumors. Laparoscopic removals as well as open resections were each attempted in 22 (50.0%) patients.

There were 18 (40.9%) males and 26 (59.1%) females. Female/male ratio = 1.44. The average age was  $63 \pm 14$  years (range: 30–84 years), male –  $67 \pm 14$  (range: 35–84 years), female  $60 \pm 13$  (range: 30–

80 years). There was no significant difference in age between the two sexes ( $p = 0.112$ ).

The most common symptom on presentation was abdominal pain – in 18 (40.9%) patients. Nine (20.5%) patients had GI bleeding, 3 (6.8%) of whom required endoscopic hemostasis and 6 (13.7%) blood transfusions. Four (9.1%) patients had only non-specific dyspeptic symptoms, and thirteen (29.5%) patients had lesions discovered during preventive diagnostic studies. The primary symptoms on presentation, depending on tumor location, are summarized in Table IV. There was a significant difference in average tumor size between asymptomatic and symptomatic patients (2.51 cm vs. 5.13 cm,  $p = 0.008$ ).

### Diagnostic workup

The most common diagnostic method used was abdominal CT scan, in 36 (81.8%) patients, followed by upper UGIE in 35 (79.5%) patients, EUS in 19 (43.2%) patients, and US in 12 (27.3%) patients. Uncommonly, MRT and CTA scans were used, in 2 (4.5%) and 1 (2.3%) patients, respectively. Biopsy, following UGIE, and FNA, following EUS, were applied to 13 (29.5%) and 6 (13.6%) patients, respectively. Histologic diagnosis of tumor was confirmed preoperatively in 14 (31.8%) patients: UGIE with biopsy in 8 (61.5%) patients, EUS with FNA in all 6 (100.0%) patients. Particular diagnostic workup is shown in Table I. Thirteen (29.5%) patients presented with asymptomatic GISTs, found incidentally during preventive diagnostic investigations, commonly the upper UGIE.

### Perioperative outcomes

Forty-three (97.7%) patients underwent elective resection, and 1 patient (2.3%) underwent emer-

gency open resection due to an episode of chills and partial mechanical small intestine obstruction. We achieved R0 resection in 97.7% ( $n = 43$ ) of the cases. Seven (15.9%) patients developed postoperative complications. Intraoperative blood loss was below 200 ml in all patients and no patient required blood transfusion. There were no mortalities either in the minimally invasive or in the open group. None of the 44 patients had received preoperative imatinib treatment for a GIST. Surgical procedures, according to the GIST location, are summarized in Table V.

The minimally invasive surgical techniques used were: purely laparoscopy ( $n = 20$ ), laparoendoscopy ( $n = 1$ ) and laparoscopy-assisted endoscopy ( $n = 1$ ). Intraoperative esophagogastroduodenoscopy was used in 4 (18.2%) cases: in 3 cases to specify the tumor location and in 1 case to dye the tumor excision borders. Characteristics of minimally invasive operations are summarized in Table VI. In 20 patients laparoscopic wedge resections were performed (gastric = 16, duodenal = 1, jejunal = 1, ileal = 2), in 1 patient with fundoplication. In 1 patient part of the tumor

**Table V.** Tumor location and operations performed

| Tumor location/operation  | L  | O | LE | LAE | Overall     |
|---|----|---|----|-----|-------------|
| <b>Stomach – 35 (79.55%) patients</b>   |    |   |    |     |             |
| <i>Gastroesophageal junction</i>  |    |   |    |     | 1 (2.27%)   |
| Wedge resection + m. Door fundoplication                                      | 1* |   |    |     |             |
| <i>Cardia</i>   |    |   |    |     | 6 (13.64%)  |
| Wedge resection   | 2* | 2 | 1  | 1   |             |
| <i>Fundus</i>   |    |   |    |     | 2 (4.55%)   |
| Wedge resection   | 1  | 1 |    |     |             |
| <i>Cardial notch</i>  |    |   |    |     | 4 (9.09%)   |
| Wedge resection   | 1  | 3 |    |     |             |
| <i>Body</i>   |    |   |    |     | 15 (34.09%) |
| <i>Lesser curvature</i>   |    |   |    |     | 7 (15.91%)  |
| Wedge resection   | 5  | 2 |    |     |             |
| <i>Greater curvature</i>  |    |   |    |     | 1 (2.27%)   |
| Wedge resection   | 1  |   |    |     |             |
| <i>Anterior wall</i>  |    |   |    |     | 3 (6.81%)   |
| Wedge resection   | 3  |   |    |     |             |
| <i>Posterior wall</i>   |    |   |    |     | 4 (9.09%)   |
| Wedge resection   | 2  | 2 |    |     |             |
| <i>Pyloric part</i>   |    |   |    |     | 7 (15.91%)  |
| <i>Antrum</i>   |    |   |    |     | 6 (13.64%)  |
| Distal gastrectomy  |    | 2 |    |     |             |
| Wedge resection   |    | 4 |    |     |             |
| <i>Canal</i>  |    |   |    |     | 1 (2.27%)   |
| Distal gastrectomy  |    | 1 |    |     |             |
| <b>Small intestine – 7 (15.89%) patients</b>                                  |    |   |    |     |             |
| <i>Duodenum</i>   |    |   |    |     | 2 (4.55%)   |
| Wedge resection   | 1* | 1 |    |     |             |
| <i>Jejunum</i>  |    |   |    |     | 3 (6.81%)   |
| Wedge resection   | 1  |   |    |     |             |
| Segmental resection of the jejunum  |    | 2 |    |     |             |
| <i>Ileum</i>  |    |   |    |     | 2 (4.55%)   |
| Wedge resection   | 2  |   |    |     |             |
| <b>Mesentery – 2 (4.55%) patients</b>   |    |   |    |     |             |
| Wedge resection + segmental resection of the jejunum                          |    | 1 |    |     |             |
| Segmental resection of the jejunum and duodenum inferior + duodenojejunostomy |    | 1 |    |     |             |

L – laparoscopic removal, O – open resection, LE – laparoendoscopic removal, LAE – laparoscopy-assisted endoscopic removal, \*conversion to an open procedure

**Table VI.** Characteristics of minimally invasive operations

| Characteristic                                   | Purely laparoscopy    | Laparoscopy with endoscopy | Laparoscopy-assisted endoscopy |
|--|-----------------------|----------------------------|--------------------------------|
| <i>N</i> (%)                                     | 20 (90.1)             | 1 (4.5)                    | 1 (4.5)                        |
| Tumor size, mean (range) [cm]                    | 2.9 (1.5–6.0)         | 3.5                        | 2.9                            |
| Location of tumor                                |                       |                            |                                |
| Stomach  | 16                    | 1                          | 1                              |
| Duodenum   | 1                     |                            |                                |
| Jejunum  | 1                     |                            |                                |
| Ileum  | 2                     |                            |                                |
| Mesentery  |                       |                            |                                |
| Mean operative time, mean $\pm$ SD (range) [min] | 131 $\pm$ 53 (45–275) | 195                        | 95                             |

was resected endoscopically, and another part laparoscopically, and in 1 patient the tumor was fully resected endoscopically under visual control with laparoscopy. In the minimally invasive group 3 (13.6%) patients underwent three concurrent operations: laparoscopic cholecystectomy in 1 and incisional umbilical hernia repair in 2. The average operative time (including concurrent operations and additional procedures) was 132  $\pm$ 53 min (range: 45–275 min).

There were no intraoperative complications. However, conversion to an open approach was performed in 4 (18.2%) patients, all in the purely laparoscopic operation group. Conversion to laparotomy was necessary due to inappropriate tumor location: in 1 case the tumor was located in the gastroesophageal junction (GEJ), in 2 cases in the cardia, near the GEJ, and in 1 case in the second portion (D2) of the duodenum. The mean tumor size in the conversion group was 2.55 cm (range: 1.5–3.8 cm), the average operative time was 159  $\pm$ 45 min (range: 110–210 min) and the mean postoperative stay was 9.75 days (range: 7–16 days).

Three (13.6%) patients developed postoperative complications: intraperitoneal bleeding due to rupture of the capsule of the spleen in 1 (tumor of the cardia), diffuse peritonitis due to postoperative lesser curvature suture leakage in 1 (tumor of the lesser curvature), which led to a prolonged hospital stay up to 68 days, and chronic esophagitis as a long-term complication in 1 (GEJ tumor). The average postoperative length of stay was 8.5  $\pm$ 12.0 (range: 8–35 days).

In the open group operative approaches applied were: wedge resection – 15 (gastric = 14, duodenal = 1), distal gastrectomy (antrectomy) – 3, resection

of the jejunum – 2, resection of the jejunum and duodenum = 1, resection of the jejunum with wedge resection of mesentery = 1. Five (22.7%) patients underwent 6 concurrent operations: laparoscopic cholecystectomy in 4 and incisional umbilical hernia repair in 2. The average operative time was 105  $\pm$ 51 min (range: 50–220 min). Two (9.1%) patients had intraoperative complications: tumor rupture with spillage in 1 (jejunal tumor, 19.0 cm in diameter), and superficial damage of the transverse colon in 1 (fundus tumor). Three (13.6%) patients had postoperative complications: fever in 1 (tumor of the posterior wall of the stomach), pleural and epigastric infiltrations with fever in 1 (tumor of the pyloric canal), and postoperative abdominal mass with gastric and duodenal erosions in 1 (tumor of the mesentery). The average postoperative length of stay was 10.1  $\pm$ 5.5 (range: 7–33 days).

There were no significant differences in average age ( $p = 0.799$ ), mean operative time ( $p = 0.06$ ) or postoperative complication rate ( $p = 1.00$ ) between minimally invasive and open surgery groups. However, we found significant differences in average length of stay ( $p = 0.003$ ), postoperative length of stay ( $p < 0.001$ ) and tumor size ( $p = 0.018$ ) between minimally invasive and open surgery groups (Table VII).

#### Tumor location and histopathological characteristics

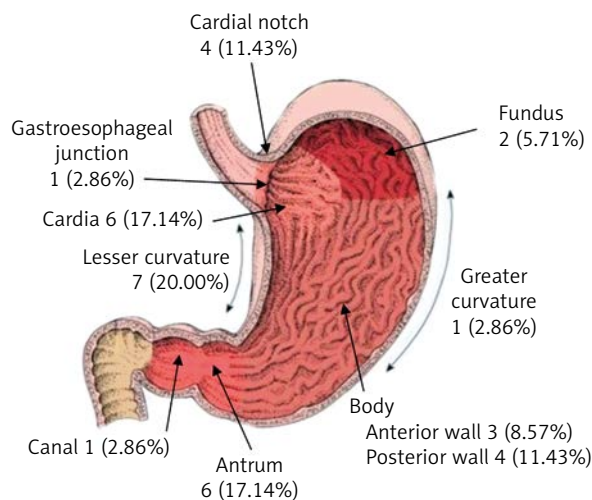
79.5% ( $n = 35$ ) of tumors were located in the stomach, followed by the small intestine – 15.9% ( $n = 7$ ) of tumors, and mesentery – 4.5% ( $n = 2$ ) of tumors. Tumors were located in all parts of the



**Table VII.** Comparative perioperative data between minimally invasive and open surgery for gastrointestinal stromal tumors

| Parameter                                 | Minimally invasive | Open | Value of <i>p</i> |
|---|--------------------|------|-------------------|
| Age, mean [years]                         | 62.1               | 63.2 | 0.799             |
| Tumor size, mean [cm]                     | 2.93               | 5.78 | 0.018             |
| Operative time, mean [min]                | 132                | 105  | 0.060             |
| Postoperative complications               | 3                  | 3    | 1.000             |
| Length of stay, mean [days]               | 11.8               | 13.3 | 0.003             |
| Postoperative length of stay, mean [days] | 8.5                | 10.1 | < 0.001           |

stomach with a predominance of the cardia, lesser curvature and antrum (Figure 1). Similarly, tumors were located in all parts of the small intestine with no predominance of any part: duodenum – 2 (4.5%), jejunum – 3 (6.8%), ileum – 2 (4.5%) tumors. The average tumor size was 4.4 ±3.8 cm (range: 0.7–19.0 cm). Mucosal ulceration was found in 15 (34.1%) and central necrosis in 10 (22.7%) of the tumors. Histology was consistent with spindle cells in 70.5% (*n* = 31), epithelioid in 13.6% (*n* = 6), mixed in 15.9% (*n* = 7) of the cases. CD117 was positive in 35 (79.5%), and CD34 in 33 (75.0%) lesions. Desmin, S-100 and SMA positivity occurred in 9 (20.5%), 10 (22.7%) and



**Figure 1.** Gastrointestinal stromal tumors of the stomach

10 (22.7%) lesions, respectively. The majority of the tumors had low (34.1%) [6] or very low (31.8%) [10] risk of aggressive behavior, and 15.9% of lesions had high risk of aggressive behavior (both Fletcher *et al.*, and Miettinen and Lasota). Distribution of presenting symptoms, tumor location, diameter and surgical procedure according to Fletcher’s and Miettinen and Lasota’s GIST aggressive behavior risk classifications are summarized in Table VIII. We found a higher rate of symptomatic patients in the high risk of aggressive behavior group of both Fletcher’s and Miettinen and Lasota’s classification (*p* < 0.05).

### Follow-up

Follow-up information was available for 6 (13.64%) high risk patients. The mean follow-up was 14.4 ±6.2 months (range: 8.4–24.5 months). One patient in the open surgery group with a 19.0 cm tumor and mitotic rate of < 5/50 HPF developed metastatic disease in the liver and mesentery, confirmed by abdominal CT scan. All 6 (100.0%) patients are alive and 5 (83.3%) of them are disease-free.

### Discussion

Gastrointestinal stromal tumors are rare submucosal tumors that are recently becoming increasingly diagnosed because of the rising incidence of upper GI endoscopy and abdominal CT scan, or perhaps because of the rising morbidity of GISTs. Gastrointestinal stromal tumors represent approximately 80% of mesenchymal GI tumors and less than 1% of all GI malignancies.

The clinical presentation of GISTs ranges from asymptomatic (15–30% of cases) to abdominal pain or gastrointestinal bleeding (17–42% of cases) from an ulcerated tumor [6, 19]. Other common symptoms on presentation are anemia secondary to GI bleeding (19% of cases), presence of a palpable abdominal mass (13% of cases), weight loss and GI obstruction [20]. The most common symptom in our experience was abdominal pain – 40.9% (*n* = 18) of cases, followed by bleeding in the digestive tract – 20.4% (*n* = 9) of cases, and non-specific dyspeptic symptoms – 9.1% (*n* = 4) of cases. 29.6% (*n* = 13) of all patients presented without any symptoms.

The development of symptoms is related to the size of the tumor. In our series, asymptomatic patients had GISTs of average diameter of 2.5 cm (range: 0.7–5.5 cm), patients with abdominal pain



**Table VIII.** Fletcher's and Miettinen's classifications of GIST: distribution of symptoms, tumor location, diameter and surgical procedures

| Variable                    | Fletcher's classification |                |                |                  |                | Miettinen's classification |                |                |                  |
|-----------------------------|---------------------------|----------------|----------------|------------------|----------------|----------------------------|----------------|----------------|------------------|
|                             | VL                        | L              | IM             | H                | N              | VL                         | L              | IM             | H                |
| Risk of aggressive behavior |                           |                |                |                  |                |                            |                |                |                  |
| N (%)                       | 8 (18.2)                  | 15 (34.1)      | 14 (31.8)      | 7 (15.9)         | 6 (13.6)       | 14 (31.8)                  | 9 (20.5)       | 8 (18.2)       | 7 (15.9)         |
| Symptoms                    |                           |                |                |                  |                |                            |                |                |                  |
| Asymptomatic                | 4                         | 5              | 4              | 0                | 2              | 5                          | 2              | 4              | 0                |
| Symptomatic                 | 4                         | 10             | 10             | 7                | 4              | 9                          | 7              | 4              | 7                |
| Localization                |                           |                |                |                  |                |                            |                |                |                  |
| Gastric                     | 5                         | 13             | 13             | 4                | 3              | 14                         | 7              | 7              | 4                |
| Duodenal                    | 1                         | 1              | 0              | 0                | 1              | 0                          | 1              | 0              | 0                |
| Jejunal                     | 0                         | 0              | 1              | 2                | 0              | 0                          | 0              | 1              | 2                |
| Ileal                       | 1                         | 1              | 0              | 0                | 2              | 0                          | 0              | 0              | 0                |
| Mesenteric                  | 1                         | 0              | 0              | 1                | 0              | 0                          | 1              | 0              | 1                |
| Diameter, mean (range) [cm] | 1.51 (0.7–1.9)            | 3.01 (2.0–4.2) | 4.52 (1.6–8.0) | 10.14 (5.7–19.0) | 1.67 (1.5–2.0) | 2.92 (1.7–4.2)             | 4.86 (0.7–8.0) | 3.25 (1.6–6.0) | 10.14 (5.7–19.0) |
| Surgical procedure          |                           |                |                |                  |                |                            |                |                |                  |
| Elective                    | 8                         | 15             | 14             | 6                | 6              | 14                         | 9              | 8              | 6                |
| Emergency                   | 0                         | 0              | 0              | 1                | 0              | 0                          | 0              | 0              | 1                |
| Laparoscopic                | 6                         | 11             | 5              | 0                | 5              | 11                         | 2              | 4              | 0                |
| Open                        | 2                         | 4              | 9              | 7                | 1              | 3                          | 7              | 4              | 7                |

N – none, VL – very low, L – low, IM – intermediate, H – high

– 4.2 cm (range: 1.5–6.0 cm), and patients who presented with GI bleeding – 6.0 cm (range: 1.7–19.0 cm). We found a significant difference in average tumor size between asymptomatic and symptomatic patients, 2.51 cm vs. 5.13 cm, respectively,  $p = 0.008$ . Also, higher prevalence of symptomatic patients was observed in the high risk of aggressive behavior group of both the Fletcher and Miettinen and Lasota classifications (Table VIII),  $p < 0.05$ .

Gastrointestinal stromal tumors are rarely suspected before the time of surgery due to the low incidence of the disease. Asymptomatic tumors are usually discovered incidentally during UGIE, abdominal CT scan or as a secondary finding during unrelated abdominal surgery. According to our results, all 13 (29.5%) asymptomatic GISTs were diagnosed during preventive UGIE. A high rate of suspicion is necessary to make the right diagnosis. DeMatteo reported a mean duration of symptoms of 6 months before establishing the diagnosis [21]. An abdominal CT scan, following UGIE or EUS, is the best choice to assess the exact tumor location and size, and evaluate direct or metastatic spread. We applied the ab-

dominal CT scan in combination with UGIE or EUS in 28 (63.6%) patients. In 1 (2.27%) patient with acute GI bleeding we diagnosed ileal GIST of a size 2.0 cm when CT angiography with 3D reconstruction was done to identify the source of GI bleeding.

Biopsy or fine-needle aspiration, followed by UGIE or EUS, respectively, can aid in making the differential diagnosis of the GI lesions. EUS with FNA frequently reveals spindle cells or may be positive for specific GIST markers [22]. The Sepe *et al.* series has shown that endoscopic fine-needle aspiration for the diagnosis of GIST has sensitivity as high as 80% [23]. In our series, preoperative biopsy, following UGIE, or FNA, following EUS, was applied to 13 (29.5%) and 6 (13.6%) patients, respectively. Preoperative histologic diagnosis of GIST was confirmed in 14 (31.8%) patients: UGIE with biopsy in 61.5% ( $n = 8$ ) of the cases, EUS with FNA in 100.0% ( $n = 6$ ) of the cases. Our data confirm that a clear preoperative histological diagnosis is still not possible in all cases of GISTs through endoscopic biopsy. Moreover, biopsy may be associated with a certain risk of tumor bleeding and dissemination. We observed 1 (2.27%)

patient, following UGIE with biopsy, who developed GI bleeding and further required endoscopic hemostasis. The latest 2010 European Society for Medical Oncology (ESMO) recommendations definitely consider surgical excision of tumors without preoperative histological diagnosis of GIST if they are of size > 2 cm or show an increase in size [24]. The 2007 National Comprehensive Cancer Network Clinical Practice Guidelines in Oncology (NCCN guidelines) state that preoperative biopsy is not appropriate in easily removable tumors and consider that it is important only if neoadjuvant targeted therapy is planned [25]. In our opinion, preoperative histological diagnosis is not necessary unless the diagnosis of GIST is in doubt. The main aim should be diagnosis of GISTs with high risk for aggressive behavior, first considering the tumor size and location.

Most patients present with a solitary primary tumor that is growing in an exophytic extraluminal way, which makes them easy to find. However, many of them are well confined by a thin surrounding pseudocapsule, which is very fragile [26]. Consequently, simple enucleation is not recommended. Spillage of tumor cells from rupture of a tumor into the abdominal cavity or port sites is a major intraoperative complication which may result in conversion to an open procedure during the minimally invasive surgical approach, disease progression and recurrence, and poor survival. Tumor rupture reduces average survival from 46 to 17 months [27]. Therefore, during laparoscopy and open surgery careful and minimal manipulation of the tumor by graspers or hands is necessary. If minimally invasive surgery is performed, it is advisable to place the tumor in a bag and to remove it through the skin incision. In our series, 1 (2.27%) patient in the open surgery group with a 19.0 cm jejunal GIST had intraoperative rupture of the tumor with spillage and subsequently developed metastatic disease in the liver and mesentery.

Minimally invasive surgical approaches (purely endoscopy, combined laparoendoscopy, purely laparoscopy) are being increasingly applied, especially for tumors located in the gastric region, which makes them technically very accessible [28, 29]. We have applied purely laparoscopy in 20 (45.5%) patients, laparoscopy-assisted endoscopy in 1 (2.27%) patient, and combined laparoendoscopy in 1 (2.27%) patient. Minimally invasive techniques can be performed intra-gastrically or extra-gastrically, intra-corporeally

or extra-corporeally. In the case when the tumor grows intra-gastrically and does not involve the muscularis propria layer, purely endoscopic removal is planned. When the tumor grows extra-gastrically and presents without mucosal ulceration, a purely laparoscopic operation is considered. However, special attention should be paid to GEJ, cardia and prepyloric tumors, which are perhaps the most difficult tumor locations to approach via laparoscopic techniques because of the risk of narrowing the GEJ, gastroesophageal reflux and stenosis, both GEJ and pyloric, after removal [14]. In that case, purely endoscopic enucleation or combined laparoendoscopic technique may be applied. Katoh *et al.* indicate endoscopic enucleation to be a safe and effective method of management of gastric GISTs < 3 cm in diameter, but only if the tumor tissue does not involve the muscularis propria layer [30]. Taniguchi *et al.* suggest that endoscopic enucleation is the best choice to treat cardia GISTs that seem to be benign and have low risk of aggressive behavior [31]. If the tumor's benignity is confirmed histologically after complete endoscopic enucleation, no further treatment is necessary. However, if malignancy is observed, or endoscopic resection is incomplete, further surgery with an appropriate extent of resection is essential. We have applied this technique in 2 (4.54%) patients: in 1 (2.27%) patient a cardia tumor of 3.5 cm in size was completely resected endoscopically under visual control with laparoscopy, and in 1 (2.27%) patient endoscopic removal of a 2.9 cm size cardia tumor was incomplete, so another part of the tumor was resected laparoscopically.

Controversy surrounds the maximum diameter of GIST for laparoscopic removal. The 2007 NCCN guidelines propose that GISTs of sizes < 5 cm should be removed with the use of laparoscopy. Meanwhile, for GISTs of sizes > 5 cm hand-assisted laparoscopy should be indicated, because these tumors are more vascularized, more fragile, have a larger pseudocapsule, frequently occur with a necrotic component and frequently are found to be attached to adjacent structures. For this reason, only centers with extensive experience in minimally invasive abdominal surgery should remove large GISTs. We removed GISTs purely laparoscopically in 45.5% ( $n = 20$ ) of all cases with an average tumor size of 2.9 cm, ranging from 1.5 cm to 6.0 cm.

In any other situation, open surgery is the first option. So the main factors associated with the

choice of an open operation are: tumor location, tumor size, local attachment to adjacent organs, preoperative tumor perforation and firm intraperitoneal adhesions [32, 33]. We applied open surgical resection in 22 (50.0%) patients, with a mean tumor size of 5.8 cm (range: 0.7–19.0 cm). The average tumor size was significantly lower in the minimally invasive group (2.9 cm vs. 5.8 cm,  $p = 0.008$ ). However, due to the tumor size more extensive resections may be required [34]. For these cases, the NCCN guidelines and the ESMO recommendations suggest neoadjuvant imatinib therapy to decrease tumor size, thereby allowing for organ-preserving surgery.

There has been no prospective randomized trial directly comparing laparoscopic and open surgical approaches for GISTs. Evidence on whether performing laparoscopic resection improves outcome is controversial. Several retrospective series have demonstrated that the laparoscopic approach is associated with low morbidity and mortality, and excellent oncologic outcomes. Our data show that the purely laparoscopic approach to local or segmental resections is amenable for GISTs located in the stomach or duodenum and results in effective control of the disease with minimal perioperative morbidity and no mortality. In our series, the mean tumor size was 2.9 cm and some were as large as 6 cm. We found minimally invasive surgery to be associated with a statistically significantly shorter average length of stay (11.8 vs. 13.3,  $p = 0.003$ ) and postoperative length of stay (8.5 vs. 10.1,  $p < 0.001$ ). However, Novitsky *et al.* in a series of 50 cases of laparoscopic resection with an average tumor size of 4.4 cm found no differences in terms of recurrence or effectiveness compared to an open series [22]. Nevertheless, laparoscopic removal is currently the surgical treatment of first choice in patients with primary localized GISTs, and open surgery is not even considered unless there are contraindications to the laparoscopic approach.

The rate of conversion to an open approach varies from 0.0% to 14.5% [33, 35], and it is more likely in patients with GISTs in proximity to the GEJ or cardia [36]. In our series, conversion to an open procedure was performed in 18.2% ( $n = 4$ ) of all cases: 1 (25.0%) in a GEJ tumor, 2 (50.0%) in cardia tumors, and 1 (25.0%) in a duodenal tumor.

Small intestine GISTs have been reported to have a higher rate of complications compared to tumors

of the stomach [10], although other studies have challenged this [37]. We found no worse outcome associated with small bowel tumors.

We consider laparoscopic resection to be safe and effective for GISTs not exceeding 6 cm (in centers experienced in advanced laparoscopic surgery). Gastroesophageal junction and cardia GISTs require careful preoperative evaluation and planning to resect safely. We recommend avoiding laparoscopic resection of these tumors, due to the high rate of conversion (100.0%) to an open procedure. The laparoendoscopic surgical approach is an appropriate technique for removal of small-sized intraluminal benign GISTs, not involving the muscularis propria layer. The decision to perform preoperative biopsy should be individualized and only performed when the results of the specimen definitely determine the choice of treatment.

## References

1. Corless CL, Fletcher JA, Heinrich MC. Biology of gastrointestinal stromal tumors. *J Clin Oncol* 2004; 22: 3813-25.
2. Nilsson B, Bumming P, Meis-Kindblom JM, et al. Gastrointestinal stromal tumors: the incidence, prevalence, clinical course, and prognostication in the preimatinib mesylate era – a population-based study in western Sweden. *Cancer* 2005; 103: 821-9.
3. Gold JS, Dematteo RP. Combined surgical and molecular therapy: the gastrointestinal stromal tumor model. *Ann Surg* 2006; 244: 176-84.
4. Miettinen M, Sobin LH, Lasota J. Gastrointestinal stromal tumors of the stomach: a clinicopathologic, immunohistochemical, and molecular genetic study of 1765 cases with long-term follow-up. *Am J Surg Pathol* 2005; 29: 52-68.
5. Tran T, Davila JA, El-Serag HB. The epidemiology of malignant gastrointestinal stromal tumors: an analysis of 1,458 cases from 1992 to 2000. *Am J Gastroenterol* 2005; 100: 162-8.
6. Fletcher CD, Berman JJ, Corless C, et al. Diagnosis of gastrointestinal stromal tumors: a consensus approach. *Hum Pathol* 2002; 33: 459-65.
7. Shinomura Y, Kinoshita K, Tsutsui S, et al. Pathophysiology, diagnosis, and treatment of gastrointestinal stromal tumors. *J Gastroenterol* 2005; 40: 775-80.
8. Sepe PS, Brugge WR. A guide for the diagnosis and management of gastrointestinal stromal cell tumors. *Nat Rev Gastroenterol Hepatol* 2009; 6: 363-71.
9. Rubin BP, Singer S, Tsao C, et al. KIT activation is a ubiquitous feature of gastrointestinal stromal tumors. *Cancer Res* 2001; 61: 8118-21.
10. Miettinen M, Lasota J. Gastrointestinal stromal tumors. Review on morphology, molecular pathology, prognosis, and differential Diagnosis. *Arch Pathol Lab Med* 2006; 130: 1466-78.
11. Joensuu H, Roberts PJ, Sarlomo-Rikala M, et al. Effect of the tyrosine kinase inhibitor STI571 in a patient with a metastatic gastrointestinal stromal tumor. *N Engl J Med* 2001; 344: 1052-6.

12. Roggin KK, Posner MC. Modern treatment of gastric gastrointestinal stromal tumors. *World J Gastroenterol* 2012; 18: 6720-8.
13. Heinrich MC, Corless CL. Gastric GI stromal tumors (GISTs): the role of surgery in the era of targeted therapy. *J Surg Oncol* 2005; 90: 195-207.
14. Pucci MJ, Berger AC, Lim PW, et al. Laparoscopic approaches to gastric gastrointestinal stromal tumors: an institutional review of 57 cases. *Surg Endosc* 2012; 26: 3509-14.
15. Makarewicz W, Bobowicz M, Dubowik M, et al. Endoscopic submucosal dissection of gastric ectopic pancreas. *Videosurgery Miniiniv* 2013; 8: 249-52.
16. Gayer CP, Edelman DA, Curtis B, et al. Combined endoscopic and laparoscopic approach to a gastroesophageal tumor. *JLS* 2011; 15: 228-31.
17. Hiki N, Yamamoto Y, Fukunaga T, et al. Laparoscopic and endoscopic cooperative surgery for gastrointestinal stromal tumor dissection. *Surg Endosc* 2008; 22: 1729-35.
18. Wilhelm D, von Delius S, Burian M, et al. Simultaneous use of laparoscopy and endoscopy for minimally invasive resection of gastric subepithelial masses – analysis of 93 interventions. *World J Surg* 2008; 32: 1021-8.
19. Scarpa M, Bertin M, Ruffolo C, et al. A systematic review on the clinical diagnosis of gastrointestinal stromal tumors. *J Surg Oncol* 2008; 98: 384-92.
20. Tryggvason G, Kristmundsson T, Orvar K, et al. Clinical study on gastrointestinal stromal tumors (GIST) in Iceland, 1990–2003. *Dig Dis Sci* 2007; 52: 2249-53.
21. DeMatteo RP. The GIST targeted cancer therapy: a tumor (gastrointestinal stromal tumor), a mutated gene (c-kit), and a molecular inhibitor (STI571). *Ann Surg Oncol* 2002; 9: 831-9.
22. Novitsky YW, Kercher KW, Sing RF, et al. Long-term outcomes of laparoscopic resection of gastric gastrointestinal stromal tumors. *Ann Surg* 2006; 243: 738-47.
23. Sepe PS, Moparty B, Pitman MB, et al. EUS-guided FNA for the diagnosis of GI stromal cell tumors: sensitivity and cytologic yield. *Gastrointest Endosc* 2009; 70: 254-61.
24. Casali PG, Jost L, Reichardt P, et al. Gastrointestinal stromal tumors: ESMO clinical recommendations for diagnosis, treatment and follow-up. *Ann Oncol* 2008; 19: 35-8.
25. Demetri GD, Benjamin RS, Blanke CD, et al. NCCN Task Force report: management of patients with gastrointestinal stromal tumor (GIST) – update of the NCCN clinical practice guidelines. *J Natl Compr Canc Netw* 2007; 5: S1-29.
26. Gervaz P, Huber O, Morel P. Surgical management of gastrointestinal stromal tumours. *Br J Surg* 2009; 96: 567-78.
27. Everett M, Gutman H. Surgical management of gastrointestinal stromal tumors: analysis of outcome with respect to surgical margins and technique. *J Surg Oncol* 2008; 98: 588-93.
28. Basu S, Balaji S, Bennett DH, et al. Gastrointestinal stromal tumors (GIST) and laparoscopic resection. *Surg Endosc* 2007; 21: 1685-9.
29. Sákra L, Šiller J, Vyhňálek P, et al. Surgical treatment of gastric and small bowel gastrointestinal stromal tumours. *Videosurgery Miniiniv* 2011; 6: 138-43.
30. Katoh T, Itoh Y, Mohri T, et al. Endoscopic enucleation of gastrointestinal stromal tumors of the stomach: report of five cases. *World J Gastroenterol* 2008; 14: 2609-11.
31. Taniguchi E, Kamiike W, Yamanishi H, et al. Laparoscopic intragastric surgery for gastric leiomyoma. *Surg Endosc* 1997; 11: 287-9.
32. Everett M, Gutman H. Surgical management of gastrointestinal stromal tumors: analysis of outcome with respect to surgical margins and technique. *J Surg Oncol* 2008; 98: 588-93.
33. Tabrizian P, Nguyen SQ, Divino CM. Laparoscopic management and longterm outcomes of gastrointestinal stromal tumors. *J Am Coll Surg* 2009; 208: 80-6.
34. Sokolich J, Galanopoulos C, Dunn E, et al. Expanding the indications for laparoscopic gastric resection for gastrointestinal stromal tumors. *JLS* 2009; 13: 165-9.
35. Sexton JA, Pierce RA, Halpin VJ, et al. Laparoscopic gastric resection for gastrointestinal stromal tumors. *Surg Endosc* 2008; 22: 2583-7.
36. Nguyen SQ, Divino CM, Wang JL, et al. Laparoscopic management of gastrointestinal stromal tumors. *Surg Endosc* 2006; 20: 713-6.
37. Keun PC, Lee EJ, Kim M, et al. Prognostic stratification of high-risk gastrointestinal stromal tumors in the era of targeted therapy. *Ann Surg* 2008; 247: 1011-8.

**Received:** 24.07.2013, **accepted:** 5.11.2013.