

All dangerous types of endoleaks after endovascular aneurysm repair in a single patient

Tomasz Synowiec¹, Marcin Warot¹, Paweł Burchardt², Paweł Chęciński¹

¹Department of General and Vascular Surgery and Angiology, Poznan University of Medical Sciences, Poznan, Poland

²Division of Cardiology-Intensive Therapy, Department of Internal Medicine, Poznan University of Medical Sciences, Poznan, Poland

Videosurgery Miniinv 2015; 10 (2): 290–294

DOI: 10.5114/wiitm.2015.52600

Abstract

Endovascular aneurysm repair (EVAR) has become tremendously popular in recent years. However, the long-term results of these stent grafts are uncertain and are still being evaluated. According to some data, the graft-related complication rate after EVAR could be as high as 43% in long-term observation. In this case report, we present a patient who had all dangerous types of endoleaks after EVAR and required sophisticated management including endovascular and open surgical repairs. After repeated invasive treatment, it was possible to exclude all endoleaks, and now the patient is free from graft-related complications. Although EVAR has become very popular, we should remember about possible complications, which could be very severe and life-threatening. For this reason, the choice between endovascular and open repair of abdominal aortic aneurysm should be well considered.

Key words: aneurysm, stent graft, abdominal aorta, endovascular aneurysm repair.

Introduction

Endovascular aneurysm repair (EVAR) created new possibilities for patients with abdominal aortic aneurysms (AAA), and in recent years it has become tremendously popular. Use of EVAR in selected groups of patients allows mortality and morbidity to be reduced in comparison to open repair. However, the long-term results of these stent grafts are uncertain and are still being evaluated [1, 2]. According to some data, the graft-related complication rate after EVAR could be as high as 43% in the long-term observation. The most common complications are endoleaks [3, 4].

In this case report, we present a patient who had all dangerous types of endoleaks after EVAR and required sophisticated management.

Case report

In 2006, a 78-year-old man was admitted to the Department of General and Vascular Surgery due to asymptomatic AAA. The maximal transverse diameter of the AAA was 60 mm. Concomitant diseases included arterial hypertension, coronary artery disease (status post-CABG in 1998), and heart failure (NYHA III). Because of the general condition of the patient, it was decided to perform an endovascular procedure. An aorto-bifemoral stent graft (Cook-Zenith) was implanted under local anesthesia. Control angiography revealed exclusion of the aneurysmal sac. Perioperative and postoperative periods were uneventful.

Two-year follow-up controls, performed with computed tomography (CT), did not reveal any graft-

Address for correspondence

Tomasz Synowiec MD, PhD, Department of General and Vascular Surgery and Angiology, Poznan University of Medical Sciences, 34 Dojazd St, 60-631 Poznan, Poland, phone: +48 61 846 45 30, e-mail: tomeksyn@wp.pl

related complications. The aneurysmal sac even shrank to a maximal transverse diameter of 56 mm. The next control imaging performed in 2009 showed an increase of the aneurysm to the diameter of 60 mm and endoleak type IIA. Laparoscopic ligation of the inferior mesenteric artery (IMA) was performed, and angio-CT after this procedure did not reveal type IIA endoleak (Photo 1). However, in the next control examination, in 2010, endoleak type IIIA was diagnosed. It was treated with angioplasty and covered stent implantation (Photo 2). In 2011, control angio-CT detected endoleak type IB in the right leg of the endograft, which was substantiated by angiography. Through paramedian incision, retro-

peritoneally, the right iliac arteries were approached. Banding of the right common iliac artery was performed with a strip of Dacron prosthesis. Intraoperative angiography confirmed successful exclusion of type IB endoleak (Photo 3). Perioperative and post-operative periods were uneventful. The control angio-CT performed at the end of 2011, 6 months after the last intervention, showed proper exclusion of the aneurysm. The maximal transverse diameter of the aneurysmal sac was 62 mm. However, the next control imaging performed at the beginning of 2012 revealed an increase of the aneurysmal sac to the diameter of 90 mm without visible endoleaks. Type V endoleak was suspected (Photo 4). The patient

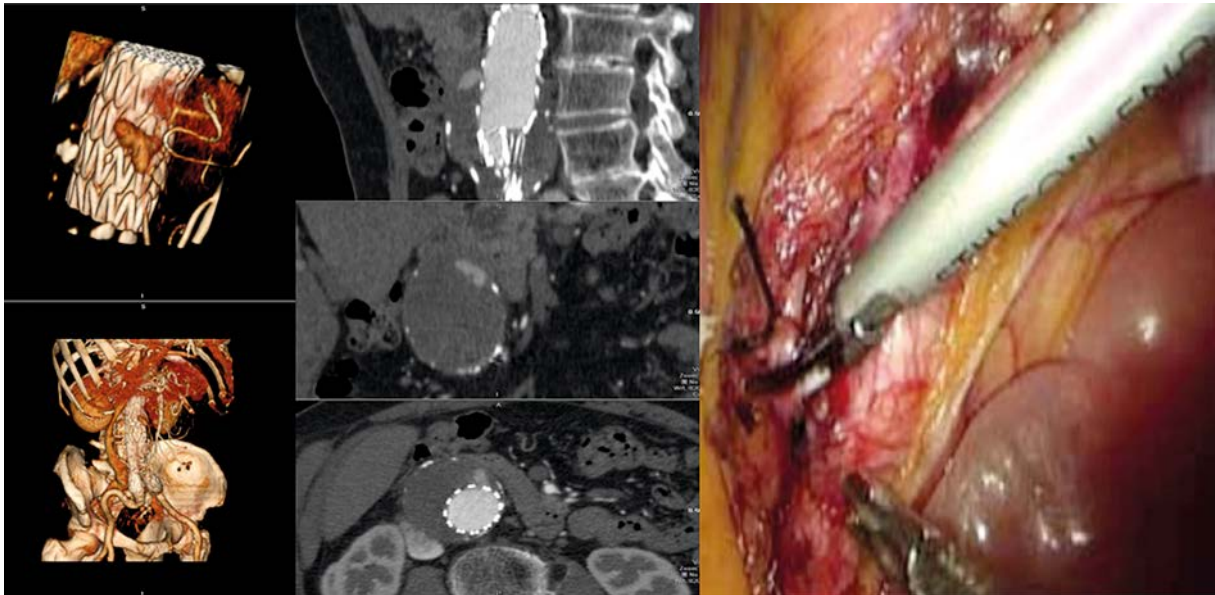


Photo 1. Endoleak type IIA treated with laparoscopic ligation

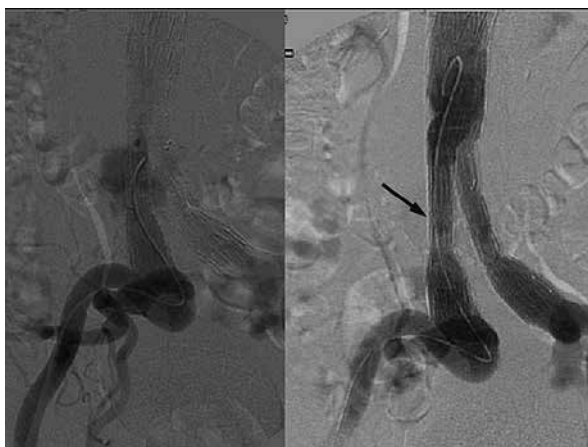


Photo 2. Endoleak type IIIA managed endovascularly by covered stent

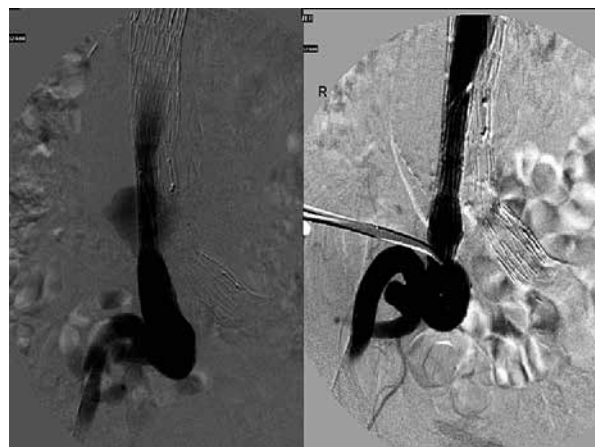


Photo 3. Surgical banding of right common iliac artery due to endoleak type IB

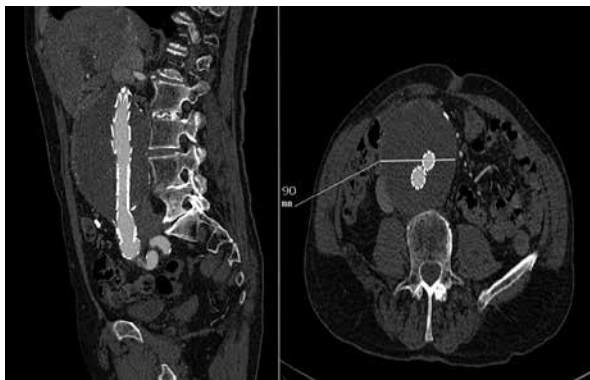


Photo 4. Suspicion of endoleak type V (endotension)

complained of abdominal pain and was qualified for surgical intervention. Under general anesthesia, laparotomy was performed, and the sac of the aneurysm was opened. Spot bleeding from the cover of the stent graft (endoleak type IIIB) and bleeding from 2 lumbar arteries (endoleak type IIB) was diagnosed. Next clamping of the body and legs of the stent graft was performed. To create a fast approach to the lumbar arteries, due to massive bleeding, the body of the stent graft was disconnected from its legs. The sites of bleeding were closed with polypropylene sutures. Next parts of the stent graft were connected together using short segments of a Dacron prosthesis (Photo 5). After the operation the patient spent 4 days in the Intensive Care Unit. The last CT scan, performed in November 2014, did not reveal graft-related complications. Maximal diameter of the aneurysmal sac was 50 mm.

Discussion

The main advantage of EVAR is low mortality during the procedure and the first 30-day period after the operation estimated at the level of 1.7% [1]. However, endograft complications include migration of the stent, obstruction, infections and endoleaks [5]. For this reason, patients after EVAR require follow-up surveillance with regular scans of the stent graft for the whole life after the procedure. The most common complications are endoleaks [4, 6].

Type I endoleak is one of the most life-threatening. There are two types of this endoleak: IA, which means a leak at the proximal part of the stent graft; and type IB, when the leakage is situated in the distal part of the stent graft. It leads to a large increase of pressure in the aneurysmal sac. It is one of the most frequent causes of aneurysm rupture in patients after EVAR [7]. In the present case, type I endoleak occurred in the distal part of the stent graft. The easiest way to manage that complication was to extend the stent graft. However, it required covering the internal iliac artery, which could result in buttock claudication or pelvic ischemia. A more advanced method would be to use a branched graft for the internal iliac artery, but tortuosity of the right iliac arteries was a contraindication for such a solution. Finally, surgical banding of common iliac artery (CIA) was performed. The risk of open repair was greater than for the endovascular one. However, this method of treatment seemed feasible for this patient and allowed blood flow through the right internal iliac artery to be preserved [8].

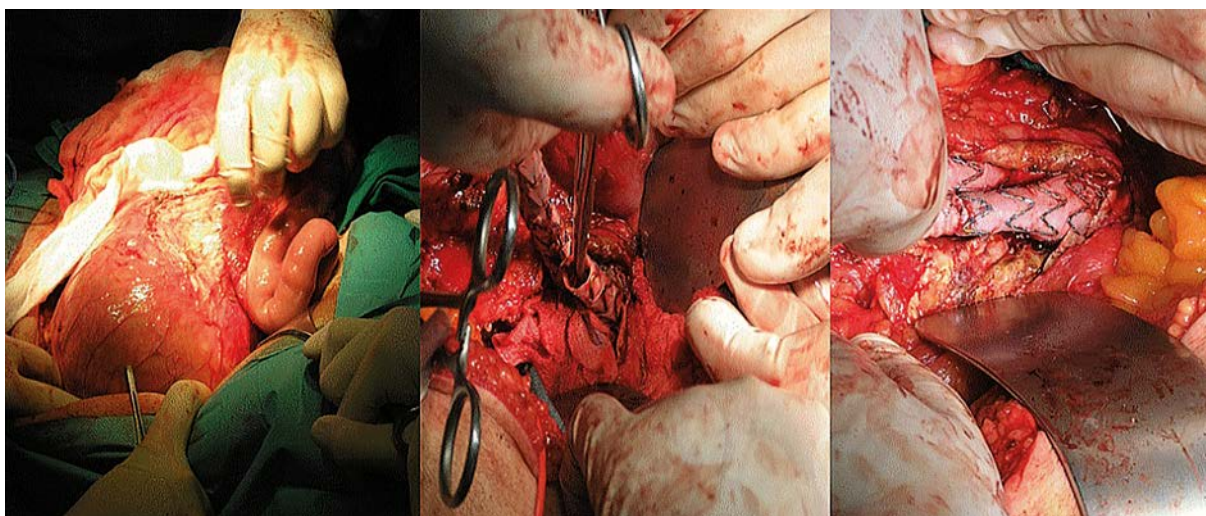


Photo 5. Open surgical repair of type IIB and type IIIB endoleak

Type II endoleak is the most common endoleak after EVAR. It means the sac is filling through the branches arising from the aneurysmal sac. When a leak is from the IMA, it is described as type IIA, and if from lumbar arteries as type IIB. It requires treatment when the aneurysmal sac is increasing in diameter, because enlargement of the aneurysmal sac could lead to rupture. There are a few options to treat such an endoleak, e.g. open or endoscopic ligation of branches of the AAA or an endovascular approach and its occlusion with thrombotic agents [9]. According to recent data from the literature, it seems that choosing the endovascular approach and embolisation of all preserved lumbar arteries, the IMA and canals with blood flow in the aneurysmal sac using Onyx embolic agent could give promising results. However, it requires a very experienced radiologist, proper equipment, and feasible anatomy. In addition, it is an expensive procedure [10]. In the present case, both types of this endoleak were observed. First in 2009 type IIA was diagnosed. Laparoscopic ligation of the IMA was performed because other endovascular methods were not available for us at that time, and the laparoscopic approach guaranteed a minimally invasive method with a good outcome [11]. It is important to remember that such ligation must be performed in the very proximal part of the IMA, to prevent refilling of the aneurysmal sac from the left colic artery – the first branch of the IMA. Type IIB endoleak was also diagnosed, but it was during the last open operation, and the lumbar arteries were ligated.

Type III endoleak is also one of the most life-threatening. It could be type IIIA that occurs when there is junctional separation of the stent graft or type IIIB, which means fractures or holes of the stent graft. Because of its origin, it could lead to high pressure in the aneurysmal sac, fast growth of the aneurysmal sac and rupture. In the case of type III endoleaks, many patients could be treated with endovascular techniques, mainly covered stent or another stent graft implantation. In the present case, first in 2010 type IIIB endoleak was diagnosed, which was easily treated with a cover stent. However, during the last operation in 2012 also the seldom type IIIA was observed and was treated but with application of vascular sutures on the holes in the stent graft [6, 12].

Type IV endoleak is connected with porosity of graft fabric and could be visible during control angi-

ography after stent graft placement. However, this endoleak is seldom visible and is not dangerous. It does not require treatment and resolves up to 30 days after graft implantation [6]. Type IV endoleak was the only one that was not seen in the present patient.

Enlargement of the aneurysm after EVAR without visible blood flow in the aneurysmal sac is named type V endoleak and means endotension. In this patient, enlargement of the aneurysmal sac, without visible blood flow in it, occurred in 2012. When the diameter of the aneurysmal sac exceeded 90 mm, the patient underwent open surgery. There is no consensus how to manage type V endoleak. In many cases, it is not true type V endoleak but, as in the present case, the symptom of other types of endoleaks that are not visible due to the limitation of imaging techniques [6].

Conclusions

Although EVAR has become very popular, we should remember about possible complications, which could be very severe and life-threatening. Treatment of these complications can be very complex and demanding. For this reason, the choice between endovascular and open repair of AAA should be well considered.

Conflict of interest

The authors declare no conflict of interest.

References

1. Greenhalgh RM, Brown LC, Kwong GP, et al. Comparison of endovascular aneurysm repair with open repair in patients with abdominal aortic aneurysm (EVAR trial 1), 30-day operative mortality results: randomised controlled trial. *Lancet* 2004; 364: 843-8.
2. Stather PW, Sidloff D, Dattani N, et al. Systematic review and meta-analysis of the early and late outcomes of open and endovascular repair of abdominal aortic aneurysm. *Br J Surg* 2013; 100: 863-72.
3. Synowiec T, Warot M, Burchard P, et al. Hemoptysis as a first symptom of endoleak after thoracic endovascular aortic repair, which caused aortic rupture and required complex management. *Videosurgery Miniiniv* 2013; 8: 178-81.
4. EVAR Trial Participants. Endovascular aneurysm repair and outcome in patients unfit for open repair of abdominal aortic aneurysm (EVAR trial 2): randomized controlled trial. *Lancet* 2005; 365: 2187-92.
5. Stather PW, Wild JB, Sayers RD, et al. Endovascular aortic aneurysm repair in patients with hostile neck anatomy. *J Endovasc Ther* 2013; 20: 623-37.

6. Cao P, De Rango P, Verzini F, et al. Endoleak after endovascular aortic repair: classification, diagnosis and management following endovascular thoracic and abdominal aortic repair. *J Cardiovasc Surg (Torino)* 2011; 51: 53-69.
7. van Marrewijk C, Buth J, Harris PL, et al. Significance of endoleaks after endovascular repair of abdominal aortic aneurysms: the EUROSTAR experience. *J Vasc Surg* 2002; 35: 461-73.
8. Paraskevas K, Möllendorf C, Fernandes E, et al. EVAR for aortoiliac aneurysms, including iliac branched grafts. *J Cardiovasc Surg (Torino)* 2012; 53 (1 Suppl. 1): 67-72.
9. Avgerinos ED, Chaer RA, Makaroun MS. Type II endoleaks. *J Vasc Surg* 2014; 60: 1386-91.
10. Bosiers MJ, Schwindt A, Donas KP, et al. Midterm results of the transarterial use of Onyx in the treatment of persisting type II endoleaks after EVAR. *J Cardiovasc Surg (Torino)* 2013; 54: 469-75.
11. Feezor RJ, Nelson PR, Lee WA, et al. Laparoscopic repair of a type II endoleak. *J Laparoendosc Adv Surg Tech A* 2006; 16: 267-70.
12. Wachal K, Szmyt K, Oszkinis G. Diagnosis and treatment of a patient with type IV endoleak as a late complication after endovascular aneurysm repair. *Videosurgery Miniinv* 2014; 9: 667-70.

Received: 27.01.2015, **accepted:** 12.05.2015.