

# Early complications of translumbar cannulation of the inferior vena cava as a quick, last-chance method of gaining access for hemodialysis. Ten years of experience in one clinical center

Jarosław Leś<sup>1</sup>, Sebastian Spaleniak<sup>2</sup>, Arkadiusz Lubas<sup>2</sup>, Stanisław Niemczyk<sup>2</sup>, Grzegorz Kade<sup>3</sup>

<sup>1</sup>Department of Anaesthesiology and Intensive Care, Military Institute of Medicine, Warsaw, Poland

<sup>2</sup>Department of Internal Medicine, Nephrology and Dialysis, Military Institute of Medicine, Warsaw, Poland

<sup>3</sup>Warmian-Masurian Cancer Center of the Ministry of the Interior and Administration's Hospital, Olsztyn, Poland

Videosurgery Miniinv

DOI: <https://doi.org/10.5114/wiitm.2020.99944>

## Abstract

**Introduction:** The gold standard of vascular access for chronic hemodialysis patients is the arteriovenous fistula (AVF). If an AVF cannot be created, the hemodialysis catheter can be inserted into the internal jugular, femoral or subclavian vein. After exhausting the abovementioned standard accesses, translumbar access to the inferior vena cava (IVC) is considered a quick, last-chance and rescue method.

**Aim:** Retrospective analysis of early complications (EC) of translumbar IVC catheterization using one type of catheter by one medical team.

**Material and methods:** From January 2010 to October 2019, a total of 34 translumbar IVC catheters were implanted in 27 patients.

**Results:** A major EC was found in 1 (2.9%) procedure. Minor EC occurred in 23.5 attempts. None of these complications required an intervention.

**Conclusions:** In patients with exhausted possibilities of obtaining standard vascular access for HD, translumbar IVC cannulation proved to be a safe and effective method.

**Key words:** hemodialysis, inferior vena cava, translumbar cannulation, hemodialysis catheter, urgent vascular access.

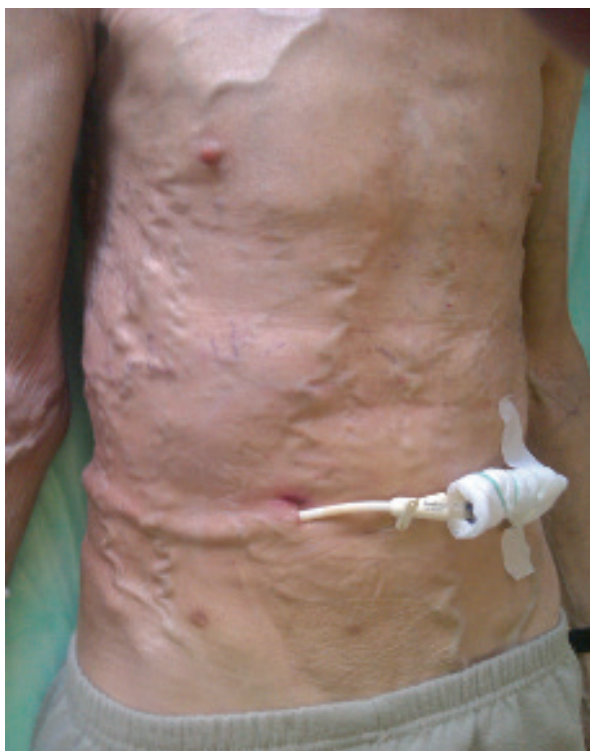## Introduction

In 1985, Kenney *et al.* first described successful translumbar inferior vena cava (IVC) catheterization [1]. Since then, this method has been used for parenteral nutrition, stem cell collection, chemotherapy, phototherapy and as vascular access for renal replacement therapy [1–3]. In 1995, Gupta *et al.* described the translumbar vascular catheter implantation for dialysis [3]. In Poland, the first catheter implantation to the IVC was performed in our center on February 9, 2007. The access obtained was

intended for hemodialysis (HD) purposes [4]. Since then, due to the inability to create an arteriovenous fistula and the loss of alternative vascular access (long-term or short-term vascular catheter) in one of the central veins, our center has dealt with the qualification and implantation of transcutaneous IVC catheters as a quick, last-chance and emergency access for hemodialysis. Due to the growing number of HD patients in Poland [5], it should be expected that the number of patients qualified for a rescue access using translumbar IVC catheter (Photo 1) and related complications may increase.

### Address for correspondence

Jarosław Leś PhD, Department of Anaesthesiology and Intensive Care, Military Institute of Medicine, 128 Szaserów St, 04-141 Warsaw, Poland, e-mail: jaroslaw\_les@hotmail.com



**Photo 1.** A patient with a visible translumbar catheter implanted due to obstruction of the brachiocephalic and iliac veins. The image also shows a developed collateral circulation



**Photo 2.** Complete implant kit (Split Cath III Translumbar Tray, MedComp, Harleysville, PA, USA)

## Aim

The aim of the study is to perform a retrospective analysis of early complications associated with translumbar cannulation of the IVC in order to obtain vascular access for HD using one type of catheter (Split Cath III Translumbar Tray, MedComp, Harleysville, PA, USA) (Photo 2). This special set consists of: 14 Fr 55 cm long catheter, trocar type 18 Ga × 20 cm introducer needle – for inferior vena cava puncture, two 6 Fr × 35 cm dilators for guidewire exchange, two Teflon-coated straight 0.038" × 120 cm guidewires, 16 Fr × 33 cm peelaway sheath-dilator for catheter introduction into the IVC.

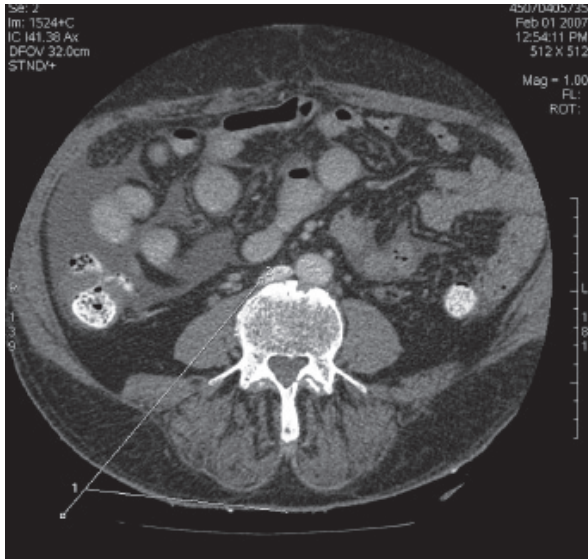
## Material and methods

Retrospective evaluation concerned patients with end-stage renal disease in a HD program whose vascular examinations (computed tomography angiography (CTA) or venography) excluded the possibility of a classical access to the superior and inferior vena cava in order to establish a catheter for HD.

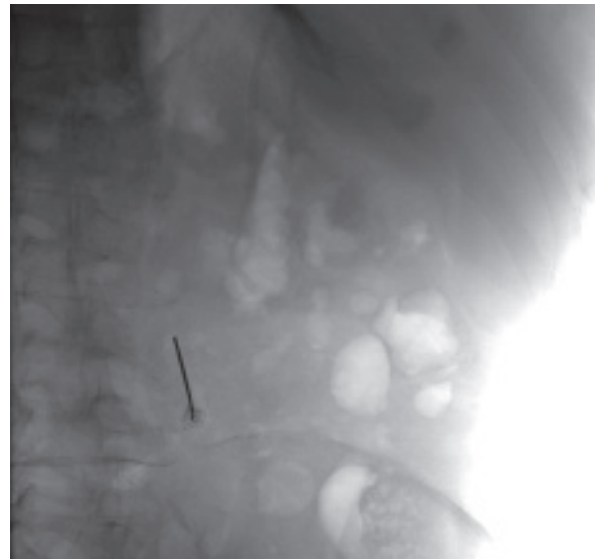In none of the patients qualified for implantation of the translumbar catheter was it possible to create typical arteriovenous or hybrid fistulas. It was not possible to insert the catheter from classical accesses either. All patients had an obstructed superior vena cava. The iliac and femoral veins were critically narrowed, to the extent that the catheter for dialysis could not be inserted. None of the patients had venous stenting or earlier exotic fistulas as the femoral veins were critically narrowed (patients disqualified from the procedure by a team of vascular surgeons)

The patients were informed about the procedure and gave informed consent. The parameters of the coagulation system, complete blood count and ionogram were monitored and corrected before each procedure. Antibiotic prophylaxis with cefazolin was administered (approximately 30–60 min before each procedure). Analgosedation (midazolam, metamizole) was administered during several procedures. During a procedure, the condition of a patient was monitored by electrocardiography, arterial oxygen saturation and arterial blood pressure measurement.

The patients had CTA of the abdomen prior to the procedure in order to mark the location of the IVC. In these individuals, the needle path was determined by analyzing the CTA image (Photo 3). IVC vein puncture was performed under fluoroscopy. The planned puncture point of the skin was approximately 10 cm to the right of the posterior median line and 1–1.5 cm above the iliac crest and the planned target point was approximately 3 cm in front of the L3 vertebral body. In most cases, 10 ml of contrast agent (iohexol



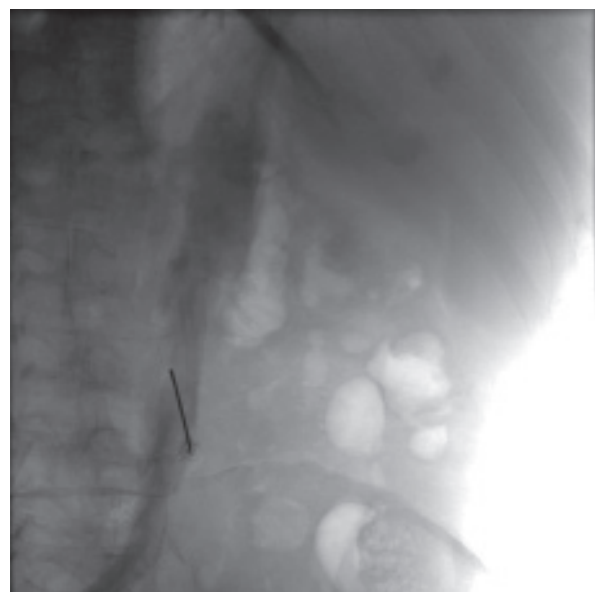**Photo 3.** Assessment of needle guidance on CT scan image



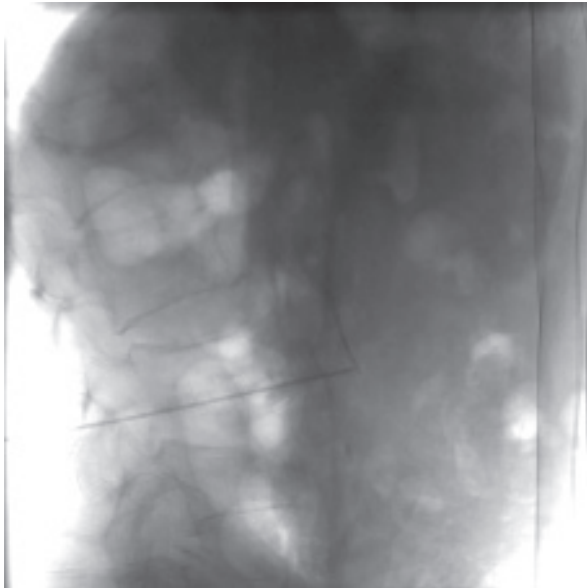
**Photo 4.** A fluoroscopic image in the oblique projection (before contrast administration)

– 350 mg I/ml) was administered intravenously to one of the peripheral veins on the lower limb to visualize the IVC (Photo 4). In 2 cases venography was not performed due to the inability to puncture the veins of the lower extremities. After visualizing the course of the IVC (Photos 4 and 5), the X-ray tube was set so that the skin puncture site was aligned with the target structure that was the center of the IVC width at the level of the third lumbar vertebra (tunnel vision technique). Then 5 ml of the contrast agent was administered intravenously to confirm that the skin entry point and target point (IVC) overlapped. A 20 cm long needle was inserted percutaneously through the planned entry point and guided centripetally and cephalically parallel to the X-rays in order to reach the IVC at the level of the L3 vertebral body. The assumed needle insertion depth was the sagittal plane running through the center of the L3 vertebra. The depth of the needle tip was assessed in anterior posterior (AP) projection. This plane was not crossed to avoid aortic puncture. Then the stylet was removed from the needle. The IVC was identified by blood aspiration during withdrawal of the needle, and in a few cases during earlier blood aspiration attempts during needle insertion. After insertion of the needle into the IVC, 2 ml of the contrast agent was administered under fluoroscopic control in order to confirm its correct position (Photo 6). In the next stage, a guidewire was placed in the IVC and an

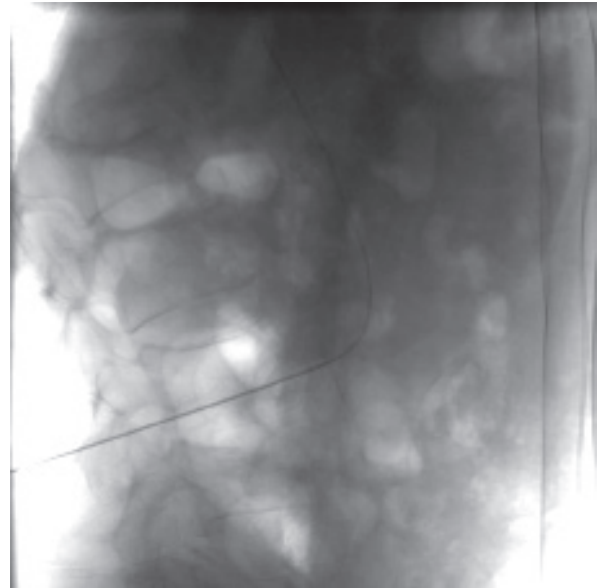
AP X-ray was taken to confirm the correct course of the guidewire towards the right atrium of the heart (Photo 7). After subcutaneous passage of the catheter from the right subcostal region to the needle insertion site (above the wing of the ilium), the catheter was inserted into the IVC using the modified Seldinger technique. The length of the interstitial course of the catheter was calculated based on the



**Photo 5.** A fluoroscopic image in the oblique projection visualizing the inferior vena cava after contrast administration



**Photo 6.** A fluoroscopic image in the lateral projection, confirming the inferior vena cava puncture by contrast administration

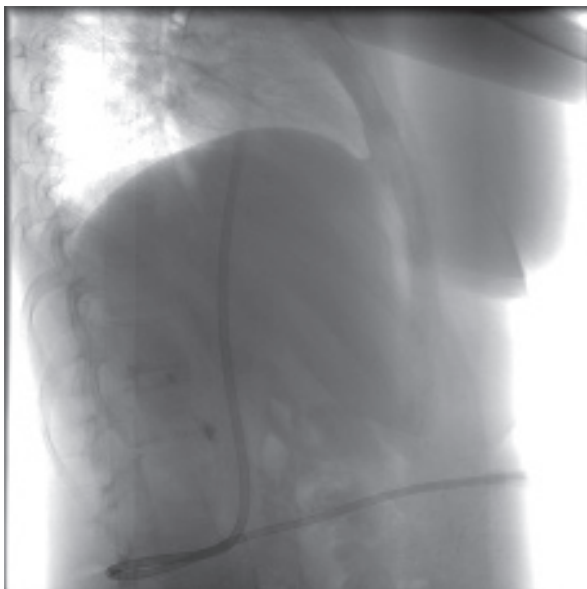


**Photo 7.** A fluoroscopic image in the lateral projection, confirming the correct placement of the guidewire in the IVC

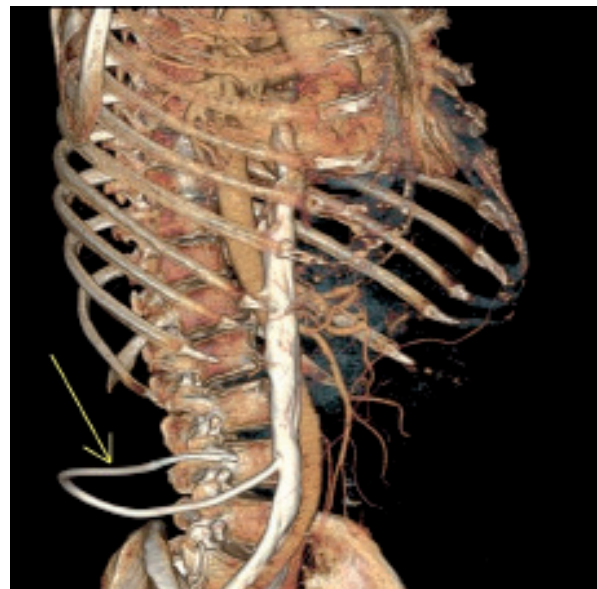
length of the guidewire inserted into the right atrium (Photo 8). For better visualization, the course of the catheter is shown in 3D reconstruction (Photo 9). The procedures for obtaining vascular access using the described method lasted 60–90 min on average. After the procedure, the catheter tunnels were filled with heparin (1000 IU/ml). The next day after the

procedure, the first hemodialysis treatment was performed using the inserted catheter.

Complications were divided into minor and major according to the CIRSE scale [6]. Minor complications do not require treatment or hospitalization. Complications requiring prolonged hospitalization, an unplanned increase in the level of patient care



**Photo 8.** A fluoroscopic image in the lateral projection, confirming the correct placement of the catheter



**Photo 9.** 3D reconstruction of the CT examination with the visible placement of the translumbar catheter implanted in the IVC (arrow)

and including complications with permanent adverse sequelae and death were considered major.

All study procedures were performed according to the Helsinki Declaration of Human Rights of 1975, modified in 1983 and 1989. The Bioethics Committee of the Military Chamber of Physicians in Warsaw (Poland) raised no objections to the design of our work.

## Results

From January 2010 to October 2019 a total of 34 translumbar catheters were implanted into the IVC in 27 patients (18 men and 9 women) for HD purposes. All IVC catheter implantation procedures were performed each time with a new puncture. The clinical characteristics of the study group, the causes of early complications, and the reasons for the catheter re-implantation are presented in Tables I and II.

The most serious complication was iatrogenic aortic puncture in 1 case (major), which accounted for 2.9% of all implantations. The ultrasound examination of the abdominal cavity after the procedure showed no signs of retroperitoneal or intra-abdominal bleeding. In the examined group, in 5 cases (which constituted 14.7% of all implantations) hematoma was found near the catheter tunnel (which did not require additional intervention). After 3 implantations (8.8%) bleeding from the catheter tunnel at the exit of the catheter to the skin was observed, and then was prevented by the application of Surgical and a pressure dressing. In 4 patients (3 men and 1 woman), reimplantation of the catheter into the IVC was performed 7 times (20.6% of all implantations).

## Discussion

Based on the performed analysis, it was found that the implantation of translumbar catheters into the IVC was a safe procedure characterized by a low risk of early (serious) complications. Since the first implantation of a translumbar vascular catheter in 1995, this procedure has become more widespread for dialysis purposes, and the number of catheters inserted into the IVC has been systematically increasing [3]. However, it is still only performed in individual clinical centers, which may be associated with the doctors' fears of the possibility of serious complications. This approach is supported by the work of Lorenz, who drew attention to the fact that

**Table I.** Clinical characteristics of the study group

Parameter	Results
Number of patients (n)	27
Sex (F/M)	9/18
Age [years]	68 (21–82)
Weight [kg]	69 (41.5–96.0)
Height [m]	1.68 (1.45–1.8)
BMI [kg/m <sup>2</sup> ]	24.3 (20.86–40.58)
Reason of kidney failure:	
GN	7
DN	3
Hypertensive nephropathy	4
Polycystic kidney disease	1
Nephrolithiasis	2
Urinary tract defects	2
Undetermined reason	8

GN – glomerulonephritis, DN – diabetic nephropathy, BMI – body mass index. The results for some parameters are given as the median and the smallest and largest values.

**Table II.** Characteristics of implantation, reimplantation and early complications of IVC catheterization

Parameter	Results
Number of all catheter implantations to the IVC	34
Number of catheter reimplantations to the IVC	7
Reason for catheter reimplantations to the IVC:	
Self-removal	2
Bacteremia	2
Extrusion of the outer cuff	2
Thrombosis	1
Early complications of catheter implantation to the IVC:	
Hematoma in the region of the catheter	5
Bleeding from the catheter tunnel	3
iatrogenic aortic puncture	1

the procedure associated with direct IVC puncture in order to obtain permanent access to the central vein is technically more difficult and time-consuming compared to other techniques [7]. At the same

time, he stated that the risk of perioperative complications associated with it is low. On the other hand, long-term observation revealed a higher incidence of translumbar catheter malfunctions and a comparable incidence of infections compared to permanent catheters placed in the thoracic veins [7]. Herscu *et al.* analyzed a group of 7 patients who underwent HD catheter implantation using the hepatic veins (4 cases) and the IVC (3 cases). A mean of 14 (range: 11–18) dialysis access procedures were performed before catheter placement by transhepatic interventions. In this study, no perioperative complications were observed, and all implantations were successful [8]. Biswal *et al.* analyzed a series of 10 patients who underwent long-standing HD using a translumbar catheter implanted in the IVC. All attempts to establish vascular access were successful. In only 1 case was there an early complication in the form of retroperitoneal bleeding, which required transfusion of 3 blood units [9].

Due to the increased risk of serious complications of IVC catheterization under fluoroscopic control, some operators began to implant catheters into the IVC under computed tomography (CT) control to minimize this risk [10]. Kariya *et al.* described two cases of percutaneous IVC catheterization under CT control for the purposes of chemotherapy in patients with breast cancer. Both implantation procedures proved to be effective and no perioperative complications were observed. The authors of the study stated that CT allowed for better visualization of the urinary tract, aorta, IVC and other organs than fluoroscopy, which reduced the risk of perioperative complications [10]. The use of CT to implant a catheter into the IVC has also been described by Grözinger *et al.* [11]. In this study, the authors analyzed a group of twelve patients, who were subjected to a total of 17 procedures to establish translumbar vascular access to the IVC (in 10 cases it was related to nutrition, in 2 cases to drug supply). All implantation procedures were technically successful. However, the 30-day percentage of early complications was 11.8% ( $n = 2$ ) and was associated with one subcutaneous bleeding event and 1 case of catheter bending. In the summary of the work, the authors consider the implantation of catheters into the IVC using CT as a safe procedure [11]. In the largest retrospective analysis conducted by Liu *et al.*, 84 procedures of translumbar implantations of HD catheters into the IVC were evaluated in 28 patients.

In the study group, 28 implantations were primary and 56 were catheter replacements. All catheter implantations into the IVC proved to be technically successful. No early complications were observed in any of the procedures [12]. In a retrospectively study, Moura *et al.* evaluated a group of 11 dialysis patients who underwent implantation into the IVC with 12 catheters using angiography. All implantation procedures were successful. In the early period after surgery (< 30 days), one complication in the form of severe bleeding and one extubation failure were observed [13]. Nadolski *et al.* analyzed the impact of body mass index (BMI), among other factors, on the risk of complications occurring during the insertion of a translumbar catheter into the IVC. The study analyzed a group of 33 patients, in whom 93 implantation procedures were performed (33 procedures were primary implantations, while the remaining 59 procedures were catheter replacements) [14]. In all cases, the implantations were successful. In the group of patients with normal BMI, two over-sedation complications (suppression of breathing) and symptomatic second-degree heart block were reported. In the group of patients with BMI > 25 kg/m<sup>2</sup>, the following complications were found: retroperitoneal hematoma, sudden cardiac arrest and temporary loss of vascular access. In the study it was found that BMI > 25 kg/m<sup>2</sup> did not significantly affect the incidence of complications. In the evaluated group, the frequency of complications during catheterization was 12.5% [14]. Rajan *et al.* described 3 cases of retroperitoneal hematoma in a group of 37 patients (2 hematomas in a patient with a correctly positioned catheter in the IVC, in 3 cases catheter displacement into soft tissues was observed). Due to the possibility of retroperitoneal bleeding, even in patients with a correctly positioned catheter, the authors recommend that the first dialysis after the catheter implantation should exclude the use of heparin [15]. In all the discussed works, the effectiveness of catheter implantation in the IVC was 100%, which is consistent with our observations. However, the occurrence and nature of the described complications in individual articles is significantly different. While the occurrence of retroperitoneal hematomas, retroperitoneal bleeding and aortic punctures was reported in individual studies, for example the presence of hematomas in the region of the catheter tunnel is described only in our study. Similarly, complications in the form of heart block are described only in a few

studies [14]. Probably such frequencies of reported complications and their nature may result from the analysis of small series of cases and the retrospective nature of the analysis. This undoubtedly constitutes a limitation of the study and means that our study can be considered at most a level 3b test.

In the group of patients with inability to insert a catheter with a classical access, an alternative to a translumbar catheter for HD is a transhepatic access. However, this access is characterized by a short functioning period. Stavropoulos *et al.* found that in a group of 12 patients with 36 catheters with transhepatic access, the average duration of access was 24.3 days [16]. In the study by Smith *et al.*, access to HD through hepatic veins was employed in 16 patients. Ten patients required multiple catheter replacements (3 times on average), and the mean catheter patency was 64 days [17]. Potential benefits of transhepatic access to the IVC compared to the translumbar access include easier hepatic vein puncture and placement of the catheter in obese patients, and a smaller distance between the skin and the hepatic vein compared to the distance between the skin and the IVC in the lumbar region. In addition, transhepatic access can be successfully performed even if the lower part of the IVC is completely obstructed. However, transhepatic access is burdened with numerous complications (collapse of the catheter, displacement of the end of the vascular catheter requiring catheter replacement, and liver dysfunction) [16, 17].

Undoubtedly, the analysis of early complications when implanting a catheter to the IVC, as well as an analysis of the literature in this area, allowed for the most complete presentation of the range of complications, which a translumbar catheter implanter must take into account.

## Conclusions

Percutaneous catheterization to the inferior vena cava in order to gain vascular access for hemodialysis has proved to be a safe method for patients in whom the possibilities of obtaining standard vascular access have been exhausted. An important element of a safe procedure is the earlier assessment of the inferior vena cava in the computed tomography angiography.

## Conflict of interest

The authors declare no conflict of interest.

## References

1. Kenney PR, Dorfman GS, Denny DF. Percutaneous inferior vena cava cannulation for long-term parenteral nutrition. *Surgery* 1985; 97: 602-5.
2. Butros SR, Walker TG, Salazar GM, et al. Direct translumbar inferior vena cava ports for long-term central venous access in patients with cancer. *J Vasc Interv Radiol* 2014; 25: 556-60.
3. Gupta A, Karak PK, Saddekni S. Translumbar inferior vena cava catheter for long-term hemodialysis. *J Am Soc Nephrol* 1995; 5: 2094-7.
4. Leś J, Grzesiak J, Łabuś M, et al. Translumbar cannulation of vena cava inferior as an alternative method of vascular access for hemodialysis. *Pol Merk Lek* 2008; 24: 331-4.
5. Dębska-Ślizień A, Rutkowski B, Rutkowski P, et al. Aktualny stan leczenia nerkozastępczego w Polsce – 2017. *Nefrol Dializoter Pol* 2018; 22: 133-40.
6. Filippiadis DK, Binkert C, Pellerin O, et al. Cirse Quality Assurance Document and Standards for Classification of Complications: The Cirse Classification System. *Cardiovasc Intervent Radiol* 2017; 40: 1141-6.
7. Lorenz JM. Unconventional venous access techniques. *Semin Intervent Radiol* 2006; 23: 279-86.
8. Herscu G, Woo K, Weaver FA, et al. Use of unconventional dialysis access in patients with no viable alternative. *Ann Vasc Surg* 2013; 27: 332-6.
9. Biswal R, Noshier JL, Siegel RL, et al. Translumbar placement of paired hemodialysis catheters (Tesio catheters) and follow-up in 10 patients. *Cardiovasc Intervent Radiol* 2000; 23: 75-8.
10. Kariya S, Tanigawa N, Kojima H, et al. Percutaneous translumbar inferior vena cava cannulation under computed tomography guidance. *Jpn J Radiol* 2009; 27: 176-9.
11. Grözinger G, Grosse U, Syha R, et al. CT-guided translumbar placement of permanent catheters in the inferior vena cava: description of the technique with technical success and complications data. *Cardiovasc Intervent Radiol* 2018; 41: 1356-62.
12. Liu F, Bennett S, RN, Arrigain S, et al. Navaneethan: patency and complications of translumbar dialysis catheters. *Semin Dial* 2015; 28: E41-7.
13. Moura F, Guedes FL, Dantas Y, et al. Translumbar hemodialysis long-term catheters: an alternative for vascular access failure. *J Bras Nefrol* 2019; 41: 89-94.
14. Nadolski GJ, Trerotola SQ, Stavropoulos SW, et al. Translumbar hemodialysis catheters in patients with limited central venous access: does patient size matter? *J Vasc Interv Radiol* 2013; 24: 997-1002.
15. Rajan DK, Croteau DL, Sturza SG, et al. Translumbar placement of inferior vena caval catheters: a solution for challenging hemodialysis access. *Radiographics* 1998; 18: 1155-67.
16. Stavropoulos SW, Pan JJ, Clark TW, et al. Percutaneous transhepatic venous access for hemodialysis. *J Vasc Interv Radiol* 2003; 14: 1187-90.
17. Smith TP, Ryan JM, Reddan DN. Transhepatic catheter access for hemodialysis. *Radiology* 2004; 232: 246-51.

Received: 10.03.2020, accepted: 7.06.2020.