

Prevention of catheter tip malposition with an ultrasound-guided finger-pressure method to block the internal jugular vein during PICC placement: a meta-analysis

Yan Zheng¹, Hua-Jing Zhou², Nian Tao³, Yun Tian⁴, Shu-Wen Qin⁵, Bi-Yong Qin⁶, Yu Xia⁷

¹Nursing Department, The Sixth Hospital of Wuhan, Affiliated Hospital of Jiangnan University, Hubei, Wuhan, China

²Department of Neurology, The First People's Hospital of Jiangxia District, Hubei, Wuhan, China

³Nursing Department, The First People's Hospital of Jiangxia District, Hubei, Wuhan, China

⁴Department of Nursing, Xiangyang No.1 People's Hospital, Hubei, Xiangyang, China

⁵Nursing School of Soochow University, Jiangsu, Suzhou, China

⁶Neurology Department, The Sixth Hospital of Wuhan, Affiliated Hospital of Jiangnan University, Hubei, Wuhan, China

⁷Department of Infection Management, The First People's Hospital of Jiangxia District, Hubei, Wuhan, China

Videosurgery Miniinv 2022; 17 (2): 289–298
DOI: <https://doi.org/10.5114/wiitm.2022.115198>

Abstract

Introduction: Peripherally inserted central catheters (PICC) are a type of deep venipuncture, for which the catheter tip malposition rate is high.

Aim: To examine the feasibility of preventing catheter tip malposition during PICC placement using an ultrasound-guided finger-pressure method to block the internal jugular vein.

Material and methods: We conducted a double-blinded randomized controlled trial (RCT) at a tertiary public hospital in Hubei province, China. A total of 600 patients were recruited and randomly allocated to the ultrasound-guided finger compression method (UGFCM) and traditional partial head method (TPHM) group ($n = 300/\text{group}$). Incidence of catheter tip malposition was assessed as the primary outcome of the study. A systematic literature review and meta-analysis was performed. We searched MEDLINE, EMBASE, Cochrane Library, China-National Knowledge Infrastructure, and Chinese Biomedicine Database and performed publication bias and sensitivity analyses on 10 extracted studies.

Results: There were no significant differences in baseline demographic and clinical characteristics between the two groups ($p > 0.05$). Overall incidence of catheter tip malposition was significantly lower in the UGFCM and TPHM group (1.67% vs. 10.3%) and particularly the incidence of malposition in the internal jugular vein (1% vs. 9%). In the meta-analysis of 10 eligible studies, with 1263 cases using the UGFCM method while 1261 adopted the TPHM method, the results showed that the incidence of catheter tip malposition was significantly lower in the group using the UGFCM method (OR = 0.17, 95% CI: 0.11–0.27, $p < 0.01$), which is in line with the results of our RCT study.

Conclusions: This study may add valuable evidence on adopting the finger-pressure method for blocking neck veins to reduce the incidence of catheter tip malposition, particularly in the internal jugular vein.

Key words: peripherally inserted central catheters, internal jugular vein, intraoperative malposition, catheter tip, tumor chemotherapy.

Address for correspondence

Dr. Yu Xia, Department of Infection Management, The First People's Hospital of Jiangxia District, No. 1 Cultural Avenue, Jiangxia District, Hubei, Wuhan City 430000, China, phone: +86-027-87959136, e-mail: yu56070990@163.com; Dr. Nian Tao, Department of Infection Management, The first People's Hospital of Jiangxia District, Hubei, Wuhan City 430000, China, phone: +86-027-87959136, e-mail: 508203608@qq.com

Introduction

Peripherally inserted central catheters (PICCs) are venous access devices, which are commonly used in clinical practice for infusions in both hospitalized patients and outpatients [1, 2]. Venous access devices can effectively reduce repeated venipuncture and the stimulation of blood vessels when using chemotherapy drugs or high permeability liquid. It is believed to be one of the most reliable tools for central venous infusion [3–6]. PICCs are performed as a type of deep venipuncture, for which the catheter tip malposition rate is as high as 34.2% [7]. Because of operative reasons and the patient's physical condition, illness, and condition of their blood vessels, during catheterization, the catheter tip can be malpositioned into veins, including the internal jugular, axillary, thoracic, azygos, and subclavian. Catheter tip malposition into the internal jugular vein occurs most frequently [8]. Without timely correction, catheter tip malposition into the internal jugular vein can cause severe complications, such as cranial nerve damage, phlebitis, catheter blockage, and vein thrombosis [9–13]. This may also result in a secondary catheterization [8], catheter instability, reduced indwelling time, or local infection [14].

There are no effective methods to prevent catheter tip malposition during PICC placement. Most clinicians use the method of puncturing under guidance by means of an instrument, such as digital gastrointestinal X-ray, radiotherapy simulation location, or two-dimensional and color Doppler ultrasound [15–19]. These methods not only increase the costs of treatment, but also increase radiation exposure for both operators and patients. The traditional clinical practice has adopted a technique involving partial head-turn to prevent catheter tip malposition. When the catheter tip reaches the position of the shoulder joint during PICC placement, patients are instructed to turn their head to the operator with their lower jaw near the sternum handle tube to block the internal jugular vein. However, this traditional method has some limitations; in particular, the catheter tip can easily enter the internal jugular vein if patients are uncooperative. A previous study reported that the incidence of catheter tip malposition into the internal jugular vein during PICC insertion using this 'traditional method' is as high as nearly 20% [20].

In recent years, some studies have reported the effects of using an ultrasound-guided finger-pres-

sure method to block the internal jugular vein during PICC placement to prevent malposition of the catheter tip, but the quality and effect of these studies lack a unified system of evaluation and meta-analysis. Approximately 1000 patients undergo PICC placement annually, within the university affiliated hospital. In the process of PICC placement, team members of the intravenous treatment center have attempted to use an ultrasound-guided finger-pressure method to block the internal jugular vein in order to prevent catheter tip malposition into the internal jugular vein.

Aim

We therefore performed a randomized controlled study to compare the incidence of catheter tip malposition between cases in which the ultrasound-guided finger-pressure method was used and those in which the traditional method was adopted to block the internal jugular vein during PICC placement. We also performed a meta-analysis of the published literature to evaluate the effect of an ultrasound-guided finger-pressure method to block the internal jugular vein on the prevention of catheter tip malposition into the internal jugular vein during PICC placement.

Material and methods

RCT study

We designed the study as a randomized, controlled comparison between two methods for blocking the internal jugular vein during PICC, including the ultrasound-guided finger compression method (UGFCM) and the traditional partial head method (TPHM). The study was designed in collaboration with the Vascular Access Team, the Oncology Unit, and our hospital management.

The study recruited oncology patients who underwent insertion of a PICC at the cancer center of our hospital between June 6, 2013 and December 2014. Inclusion criteria included patients who were: 1) receiving chemotherapy or long-term transfusion in need of PICC placement; 2) age \geq 18 years old; 3) without history of neck trauma; 4) without superior vena cava compression syndrome; 5) without swelling lymph oppression under the alar. Some local contraindications for PICC insertion or refusal to participate in the study were exclusion criteria. A to-

tal of 600 patients who met the study criteria were recruited in this study.

Using simple randomized grouping, the 600 patients were assigned numbers 1 to 600 sequentially on admission, and then subsequently assigned numbers from a random number table. Random odd numbers were assigned to the UGFCM group and even numbers to the TPHM group, with 300 patients per group. The 2 groups were similar with regard to socio-demographic and clinical characteristics, such as age, gender, site of catheter insertion, catheterized vein, clinical diagnoses, etc. with $p > 0.05$ based on the independent t -test and χ^2 test (Table I).

There were designated teams to place the PICC. For practical purposes, operators in the center used the type of catheters with which they were familiar. Either 4-Fr or 5-Fr catheters were used depending on their intended purpose. All PICC were placed using a sterile technique, with similar standards in each intravenous treatment center.

Catheterization procedure

First, in preparation for the PICC placement the patients' peripheral vasculature was evaluated. Patients and their families were informed of the necessity of the procedure, its key points, and possible complications, and written informed consent was obtained. Operators used ultrasound to guide their marking of the internal jugular vein of the puncture side, which is located in the cross section of the supraclavicular fossa, near the sternoclavicular joints (the internal jugular vein and carotid artery are parallel, and the internal jugular vein is blocked under the probe pressure, while the carotid artery shows obvious pulsing). Second, in the process of catheter insertion, the basilic vein was the optimal vessel for catheter insertion, followed by the elbow and cephalic veins. Routine disinfection and application of sterile towels were required before puncture. The catheter was delivered at a slow, constant speed to the superior vena cava, once the puncture was successful. When the catheter

Table I. Patients' characteristics

Parameter	UGFCM (n = 300)	TPHM (n = 300)	t/ χ^2	P-value
Age [years] mean \pm SD	52.93 \pm 16.43	52.97 \pm 13.29	0.026	0.980
Sex, n (%):				
Male	142 (47.3)	134 (44.7)	0.075	0.784
Female	158 (52.7)	156 (55.3)		
Height [cm] mean \pm SD	166.04 \pm 7.72	165.42 \pm 7.36	0.277	0.758
Weight [kg] mean \pm SD	64.97 \pm 9.71	64.64 \pm 10.52	0.046	0.955
Site of catheter insertion, n (%):				
Left arm	154 (51.3)	156 (52.0)	0.027	0.870
Right arm	146 (48.7)	144 (48.0)		
Vein of catheter insertion, n (%):				
Basilic vein	249 (83.0)	251 (83.7)	0.049	0.976
Cephalic vein	29 (9.7)	28 (9.3)		
Median cubital vein	22 (7.3)	21 (7.0)		
Cancer types, n (%):				
Lymphatic tumor	61 (20.3)	62 (20.7)	0.014	0.905
Breast cancer	56 (18.7)	57 (19.0)		
Stomach cancer	30 (10.0)	28 (9.3)		
Rectal cancer	49 (16.3)	49 (16.3)		
Pancreatic cancer	33 (11.0)	34 (11.3)		
Cervical cancer	32 (10.7)	33 (11.0)		
Other cancer	39 (13.0)	37 (12.4)		

UGFCM – ultrasound guided finger compression method, TPHM – traditional partial head method.

ter reached the shoulder joint position, the assistant stood on the puncture side, and used four fingers of their hand to press the site of the internal jugular vein cross section, as the operator(s) continued to gently, consistently insert the catheter to the predicted length. Next, the intubation sheath and supporting godet were withdrawn, ensuring that the catheter was adequately fixed with a transparent sticker and a Stat Lock, and well connected with a heparin cap. X-ray fluoroscopy was performed to confirm that the position was appropriate and corrected, if necessary. Other operating procedures and considerations were consistent with conventional PICC insertion.

The control group was treated using the conventional PICC insertion method. After evaluation by the intravenous treatment team, an assistant instructed the patients to practice the chin-to-side-clavicle position exercise as much as they were able to move their chin to the side of the clavicle, especially towards the puncture side, to facilitate coordination during the procedure. In the process of catheter insertion, the basilic vein was the optimal vessel for catheter insertion, followed by the elbow and cephalic veins. Before puncture, routine disinfection and application of sterile towels was required. When the catheter tip reached the shoulder joint position, patients made a lateral head movement with an assistant's help, which required patients to turn their head towards the puncture side in order to block the internal jugular vein. Then, the head was lowered to bring the lower jaw close to the shoulder, and the catheter was advanced to the predicted length. Other related procedural steps and considerations were similar to those in the observation group.

Measurement of incidence of catheter tip malposition

The main objective of this study was to evaluate the incidence of catheter tip malposition. The diagnosis of malposition was based on chest X-rays showing the catheter tip localized not to the superior vena cava, but rather in other veins, such as the internal jugular, axillary, thoracic, azygos, or subclavian. This diagnosis excluded malpositioning caused by deviation of the predicted length, including variations in the atrium and ventricle.

Meta-analysis

Literature retrieval: We systematically searched MEDLINE, EMBASE, the Cochrane Library, China-Na-

tional Knowledge Infrastructure, and the Chinese Biomedicine Database, from the time of their establishment until May 2015 using the following limits: article in English or Chinese. We searched for articles related to the finger-pressure method for blocking the internal jugular vein and the traditional head method during PICC placement to prevent catheter tip malpositioning. We developed a search strategy using the following query: ["PICC" OR "peripherally inserted central catheters" OR "ultrasound-guided finger compression method" OR "chin-to-side-clavicle position" OR "catheter tip malpositioning" OR "block the internal jugular vein"]. The reference lists of major textbooks, review articles, and dissertations were also manually searched for potential qualified research.

Studies had to satisfy the following criteria: 1) randomized controlled trials (RCT) and controlled clinical trials (CCT) of the compression method and the traditional method for blocking the internal jugular vein during PICC placement to prevent intraoperative catheter tip malposition; 2) adult patients (> 18 years old) undergoing PICC placement; 3) the experimental group using the finger-pressing method alone or in combination with another method to block the internal jugular vein, and the control group using the traditional method to block the internal jugular vein during PICC placement; 4) catheter tip positions all determined by X-ray after PICC placement; 5) outcome indicators including incidence of catheter malposition into the internal jugular vein during PICC placement; and 6) literature data completed or analysis data required can be calculated according to the results of the report. Studies were excluded from the analysis for the following reasons: 1) reports that were repeated, of poor quality, or with little information; 2) non-Chinese or -English articles; 3) review articles; 4) RCTs where investigators used their own study for contrast; and 5) studies that did not provide basic information or related interventions.

Two independent researchers read the title and abstract of each article and extracted the following information from each study with a standard form: first author, year of publication, country, research object (including exclusion criteria, method of grouping, category, and sample size), intervention (including research setting, intervention and follow-up times, case rate and cause of the loss, detailed interventions), outcome indicators (name, data type, evaluation index of time and corresponding values),

statistical methods, authors' conclusions, and the evaluation of the extractor.

Ethics approval and consent to participate

Prior to the study, the ethical approval was obtained from the Ethics Committee of The First People's Hospital of Jiangxia District. Written informed consent was obtained from each patient.

Statistical analysis

Statistical analysis was performed using SPSS software version 16.0, and the data were summarized in standard descriptive statistics. Percentages were compared by χ^2 test, and $p < 0.05$ was considered to be statistically significant. Review Manager Version 5.2 software (Cochrane Collaboration, Oxford, England; <http://www.cochrane.org/software/revman.htm>) was used to perform the meta-analysis [21, 22]. Individual and pooled OR and 95% CI were calculated for the strength of the association between the compression method of blocking the internal jugular vein compared to the traditional method. Between-study heterogeneity was evaluated by the Q test. The fixed-effects model was selected if the between-study test indicated no heterogeneity ($p > 0.1$). Otherwise, the random-effects model was used ($p < 0.1$). In the meta-analysis, study heterogeneity was qualified by I^2 , and a funnel plot was used to assess the possible presence of publication bias, with an asymmetric funnel chart indicating publication bias.

Results

Experimental results

From June 2013 to December 2014, 600 outpatient adult cancer patients (120 cases of lympho-

ma, 113 breast cancer, 58 stomach cancer, 98 rectal cancer, 67 pancreatic cancer, 65 uterine neck cancer, and 79 other tumors) were consecutively enrolled in this study (Table I).

The incidence of catheter tip malposition is shown in Table II. The group treated by UGFCM to block the internal jugular vein had a 1.7% rate of malposition overall (5 cases) and 1% rate of internal jugular vein malposition (3 cases). The TPHM had an overall malposition rate of 10.3% (31 cases) and internal jugular vein malposition rate of 9% (27 cases). The overall and internal jugular vein-specific catheter malposition rates were significantly lower in the UGFCM group than the TPHM group ($p < 0.05$).

Two groups of 36 patients with catheter tip malpositioning were subjected to the ultrasound-guided pressure method to block the internal jugular vein under digital subtraction angiography (DSA) in order to correct the catheter placement. For 5 cases in the UGFCM group and 29 in the TPHM group the superior vena cava was reached after a single adjustment. The success rate of correction after a single attempt was 94.4%. Two cases in the control group required a second correction, both successful, in which we simultaneously applied pressure to the internal jugular vein under ultrasound guidance and injected saline.

Meta-analysis results

A total of 84 potentially relevant publications were retrieved on the basis of the search strategy, which focused on comparing the effects of the UGFCM method and the TPHM method for blocking the internal jugular vein to prevent PICC tip malposition. Using the defined criteria, we reviewed the titles, abstracts, and full texts of all retrieved articles. Ultimately, 9 articles were included in this study [23–28]. One study [11] compared two types of pressure method with the traditional method. To reduce

Table II. Patients with peripherally inserted central catheter malposition

Malposition site	UGFCM (n = 300)	TPHM (n = 300)	χ^2	P-value
Total malposition	5 (1.7)	31 (10.3)	19.976	< 0.001
Malposition site:				
Jugular vein	3 (1.0)	27 (9.0)	20.211	0.000
Axillary vein	0 (0)	1 (0.3)	1.002	0.317
Within thoracic vein	1 (0.3)	1 (0.3)		
Umbilical vein	0 (0)	1 (0.3)	1.002	0.317
Subclavian vein	1 (0.3)	1 (0.3)		

Table III. Essential features and intervening measures of studies included in the meta-analysis

First author, year [ref.]	Country	Study types	Sample number (test group/control group)	Dates of collection	Intervening measure	
					Experimental group	Control group
Hu, 2013 [11]	China	RCT	320 (160/160)	2011.01–2012.03	Finger-pressure method	Traditional partial head method
					Press the device-pressure method	Traditional partial head method
Lei <i>et al.</i> , 2013 [13]	China	RCT	326 (163/163)	2011.06–2011.12	Ultrasound guided finger compression method	Traditional partial head method
Zhang, 2012 [24]	China	RCT	200 (100/100)	2009.08–2011.05	Finger-compression method	Traditional partial head method
Din, 2013 [20]	China	RCT	111(61/50)	2011–2013	Finger-pressure method	Traditional partial head method
Cheng <i>et al.</i> , 2014 [23]	China	RCT	112 (57/55)	2011.08–2012.09	Palm of hand side-pressure method	Traditional partial head method
Lu, 2015 [25]	China	RCT	596 (296/300)	2010.10–2014.10	Finger-pressure method	Traditional partial head method
Jiang <i>et al.</i> , 2014 [26]	China	CCT	90 (45/45)	2012.06–2012.12	Finger-pressure method	Traditional partial head method
Ma <i>et al.</i> , 2013 [27]	China	CCT	216 (108/108)	2011.01–2012.12	Finger-pressure method	Traditional partial head method
Xu <i>et al.</i> , 2014 [28]	China	CCT	233 (133/120)	2013.01–2013.12	Finger-pressure method	Traditional partial head method

the possibility of publication bias, we included both comparisons and considered this report to represent 2 studies. Therefore, 10 well-designed trials were ultimately included: 7 RCTs from 6 articles and 3 CCTs from 3 articles. The final pooled analyses included 1263 cases in the treatment group and 1261 cases in the control group. Basic characteristics of the various

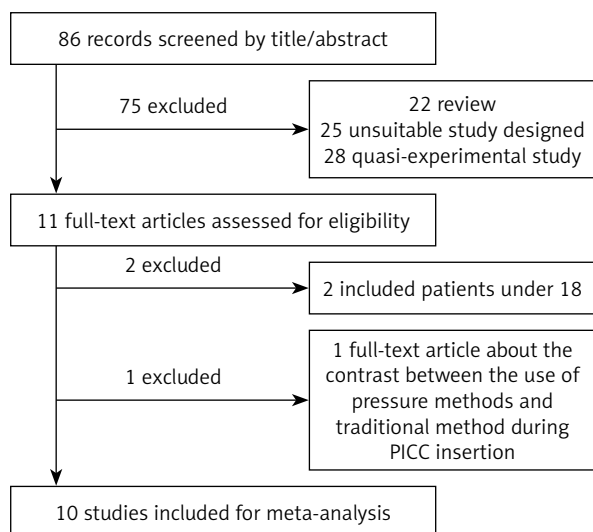


Figure 1. Study selection flow diagram

studies included in the analysis are shown in Table III. The screening process is illustrated in Figure 1.

According to the Cochrane Collaboration medical bias risk assessment methods, the 10 research studies had different levels of bias (Figures 2 and 3). All 7 RCTs were referred to “random” in the text, but only 4 studies [11, 13, 20] reported using a random number table. The others provided no details. No studies reported blinding and allocation of hidden situation (although it is impossible for the performer to be blind to the pressure method and partial head method, single blinding of patients and evaluators can be performed). All 10 studies reported results without selectivity, but the possibility of other bias could not be determined on the basis of the information provided.

All 10 studies adopted a pressure method (upper four fingers, ultrasonic probe, or device pressure) for blocking the internal jugular vein to prevent malposition during PICC placement in the UGFCM group and used a traditional method (neck or turn method) in the TPHM group.

Results of meta-analysis

As shown in Figure 4, all 10 studies reported the incidence rate of PICC internal jugular vein malpo-

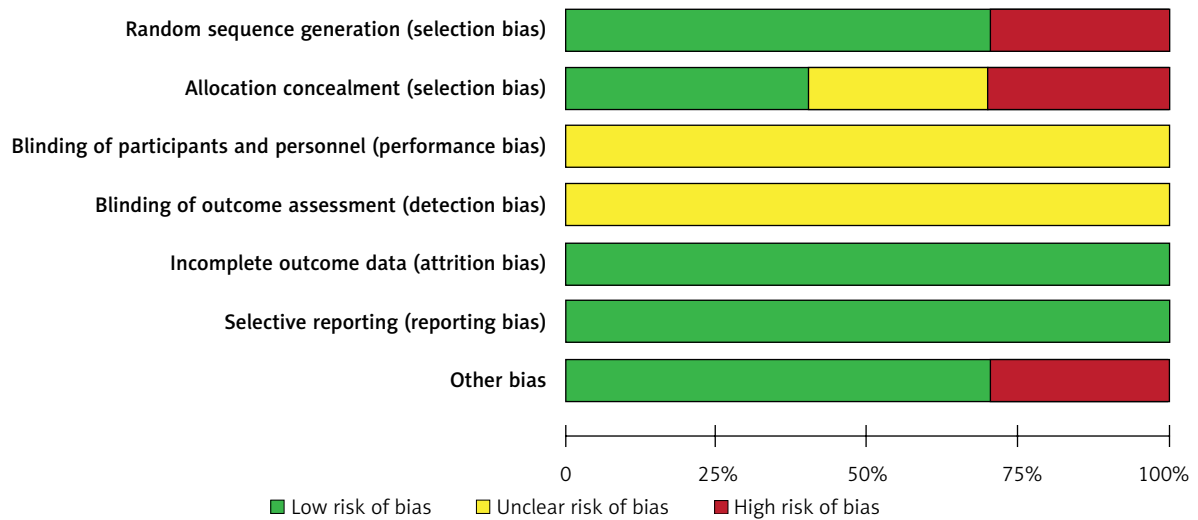


Figure 2. Bias risk

sition, and we used this incidence as the main index of the effect of the pressure method to block the internal jugular vein on the prevention of PICC malposition. The heterogeneity test indicated no significant heterogeneity between studies ($X^2 = 8.14$, $p = 0.52$, $I^2 = 0\%$). Therefore, the fixed effect model

was adopted for analysis. Meta-analysis results indicated a significantly lower incidence rate of catheter tip malposition with the use of the pressure method (UGFCM) compared to the traditional method (TPHM) for blocking the internal jugular vein during PICC placement (OR = 0.17, 95% CI: 0.11–0.27, $p < 0.01$),




Figure 3. Bias risk figure: evaluating the risk of bias for each of the included studies

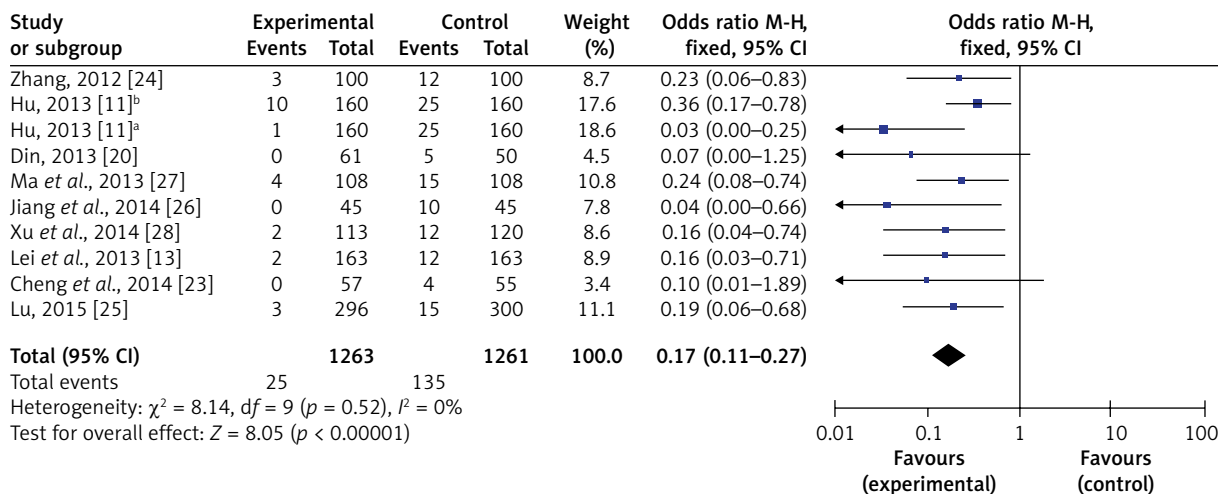


Figure 4. Forest plots of pressure and traditional methods to block the internal jugular vein during peripherally inserted central catheter placement for prevention of malposition of the catheter tip

as shown in Figure 4. Publication bias of the literature on the association between UGFCM and TPHM method to block the internal jugular vein during PICC insertion was assessed by Begg’s funnel plot and Egger’s linear regression test. The graphical funnel plot shown in Figure 5 seemed symmetrical, suggesting no evident publication bias. This was also according to a subsequent Egger’s test ($p = 0.247$). These results suggested no evident publication bias in the 10 articles. The method of one-by-one elimination was adopted for sensitivity analysis, and the total ef-

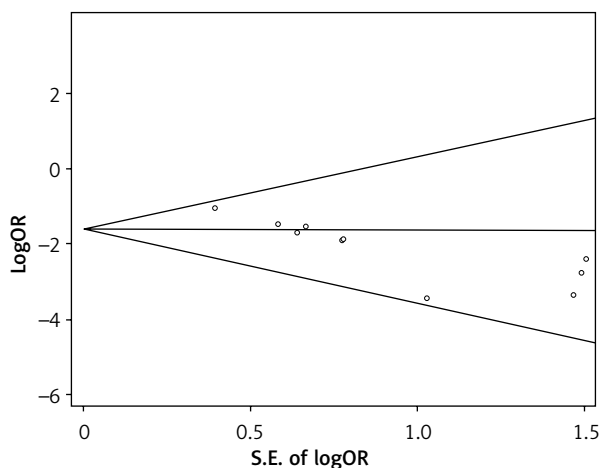


Figure 5. Begg’s funnel plot of the overall analysis of catheter tip malposition revealed no evident publication bias under ultrasound-guided finger compression versus traditional partial head methods to block the internal jugular vein during PICC insertion

fect detected in the meta-analysis did not markedly change before and after exclusion of any one study, indicating the basic reliability of its results.

Discussion

In the experimental results, the intra-procedural catheter tip malposition rate was 1.67% overall and 1% in the internal jugular vein with the UGFCM method to block the internal jugular vein with PICC, while these rates were 10.3% and 9%, respectively, using the TPHM method. Meta-analysis results indicated that compared to the TPHM method, the UGFCM method to block the internal jugular vein was associated with a significantly lower rate of intra-operative catheter tip malposition during PICC insertion. Therefore, the pressure method (UGFCM) to block the internal jugular vein during PICC placement for the prevention of catheter tip malposition demonstrated a significant effect on improving the success rate of PICC placement, thereby avoiding repeated catheterization leading to the occurrence of phlebitis, easing the burden and pain for the patient, and improving efficiency by saving the time needed for a nurse to adjust the catheter.

The internal jugular vein is the largest vein of the neck, with the lower parts and the lumen often in the open state [28], and provides a convenient conduit for the catheter into these anatomical parts. Yuan [9] used a method of PICC placement whereby the assistant guided patients to perform deep breathing movements when the catheter had nearly arrived at

the shoulder joint. While the rising and falling of the chest was observed in patients, the operators lifted the catheter at a constant speed and immediately stopped progressing the catheter when the chest fell. A respiratory cycle corresponded to the cycle of a catheter. The incidence of catheter tip malposition was 1.57% with this technique, but patients undergoing the procedure must be skilled with breathing. Advancing the catheter must immediately stop if patients experience coughing or sneezing, and several cycles are needed to send the catheter in to the predicted length according to the patient's respiratory rhythm. This method is not suitable for patients who are critically ill or have a breathing disorder and is inappropriate for deep-breathing patients. Zhang [10] stated that when the catheter is about to reach the shoulder joint position, the same side of the patient's upper limb needs to move nearer to the head, making an angle of 20–30°. The incidence of catheter tip malposition was 2.32%. One of the other disadvantages of this method is changing the sterile area intraoperatively, which increases the risk of contaminating the aseptic area. Hu [11] used finger compression or press machine methods during PICC placement and still observed high incidence of catheter tip malposition: 11.25% with simple finger pressure and 6.88% with the press machine method. The finger compression method requires familiarity with the internal jugular vein anatomical position; otherwise, the inappropriate position of applied pressure will not effectively block the internal jugular vein. The press machine method requires additional equipment, and the location pressed is close to the carotid sinus, creating some risk to the patient. The continuous pressure also reduces patient comfort; Lv *et al.* [12] suggested that a semi-Fowler position be used for PICC placement, and their reported incidence of malposition was 4.4%. This method relies on the effect of gravity to reduce catheter tip malposition, because it can increase the probability of the catheter tip progressing downward. However, it can only prevent malposition of the catheter into the vein going upward. Lei and Cheng [13] suggested that assistants use ultrasonic probe pressure to block the internal jugular vein when the catheter reaches the shoulder position in PICC placement and reported a 1.25% incidence of malposition. Because this method relies on the magnitude of the ultrasonic probe pressure, it is not effective for patients with a thicker internal jugular vein, which is difficult

to close with the pressure of the probe. In addition, it is challenging for assistants to master the pressure application. Pressure that is too great can easily cause patient discomfort; if too light, the effect is insufficient.

In the present study, compared with the TPHM method for PICC placement, an UGFCM method to block the internal jugular vein during PICC placement significantly reduced the incidence of catheter malposition in the internal jugular vein. A major reason for this difference may be that operators can directly evaluate blood vessel position, direction, and degree of filling by ultrasonic observation before PICC placement; this technique avoids the failure of pressure to reach the designated position when the assistant is unfamiliar with the internal jugular vein dissection position. In addition, this method requires only an assistant and the patient in a state of relaxation, not patient cooperation, which is more conducive to delivery of the catheter.

The meta-analysis performed in this study involved a systematically and scientifically designed search plan, but there were still some limitations. First, although we retrieved the English-language literature, ultimately 10 Chinese articles and zero English article were included in the meta-analysis, probably because this pressure method has still been gaining popularity domestically in recent years, and there have been no related case reports originating abroad. Second, the statistical analysis of funnel distribution was slightly asymmetric, indicating the possibility of publication bias in some of the literature. This bias may influence the extrapolation of the results. In addition, due to limited sample sizes and the limitations of the research design, the reliability of these results still must be confirmed by large-sample and high-quality research.

Conclusions

This study shows that an ultrasound-guided pressure method (UGFCM) for blocking the internal jugular vein during PICC placement can reduce the incidence of catheter tip malposition overall and in the internal jugular vein compared with the traditional method (TPHM). However, because of the limitations of this study, we still suggest that clinical adoption of the method should be cautious, and suggest that future high-quality studies include large samples and should be designed in strict ac-

cordance with CONSORT guidelines [29] to further demonstrate the effectiveness of the pressure method to block the internal jugular vein during PICC insertion for the prevention of catheter malposition.

Acknowledgments

Hubei Provincial Health Research Foundation (Grant No. WJ2021F065) and Scientific Research Fund of Wuhan Health Commission, Hubei Province (Grant No. WX20D78).

Yan Zheng, Hua-Jing Zhou, Nian Tao contributed equally to this study.

Conflict of interest

The authors declare no conflict of interest.

References

1. Gabriel J. PICC in an acute oncology setting. *Br J Nurs* 2015; 24: S12.
2. Pittiruti M, Emoli A, Porta P, et al. A prospective, randomized comparison of three different types of valved and non-valved peripherally inserted central catheters. *J Vasc Access* 2014; 15: 519-23.
3. Bobkiewicz A, Krokowicz L, Banasiewicz T, et al. Endoscopic vacuum therapy with instillation (iEVT)-a novel endoscopic concept for colorectal anastomotic leak and perianal complications. *Videosurgery Miniinv* 2020; 15: 560-6.
4. Paauw JD, Borders H, Ingalls N, et al. The incidence of PICC line-associated thrombosis with and without the use of prophylactic anticoagulants. *JPEN J Parenter Enteral Nutr* 2008; 32: 443-7.
5. Wang D, Amesur N, Shukla G, et al. Peripherally inserted central catheter placement with the sonic flashlight: initial clinical trial by nurses. *J Ultrasound Med* 2009; 28: 651-6.
6. Chapman R, Watkins R, Zappia T, et al. Nursing and medical students' attitude, knowledge and beliefs regarding lesbian, gay, bisexual and transgender parents seeking health care for their children. *J Clin Nurs* 2012; 21: 938-45.
7. DeChicco R, Seidner DL, Brun C, et al. Tip position of long-term central venous access devices used for parenteral nutrition. *JPEN J Parenter Enteral Nutr* 2007; 31: 382-7.
8. Trerotola SQ, Thompson S, Chittams J, et al. Analysis of tip malposition and correction in peripherally inserted central catheters placed at bedside by a dedicated nursing team. *J Vasc Interv Radiol* 2007; 18: 513-8.
9. Yuan L. Application of breathing coordination in reducing catheter tip malposition during PICC inserting. *Chin J Nurs* 2014; 49: 498-502.
10. Zhang QY. Prevention of catheter heterotopias in the process of PICC. *J Chin Peopl Liber Army* 2009; 26: 55-6.
11. Hu Q. Comparison on the effect of three different methods on preventing PICC ectopic in jugular veins. *Chin J Nurs* 2013; 48: 160-2.
12. Lv YF, Zhou XX, Wang XZ. Semi-fowler's role in the prevention of PICC catheter heterotopias. *J Nurs Training* 2009; 24: 1870-2.
13. Lei WL, Cheng HY. Results observation about internal jugular vein blocking method under ultrasound guided preventing catheter tip malposition of via peripheral vein in central venous catheter. *West China Med J* 2013; 28: 447-8.
14. Song LP, Liu ZY, Hao QL. Application of three-way valve type central venous catheter in cancer patients's chemotherapy. *J Chin Peopl Liber Army*. 2003; 20: 50-1.
15. Li Y, Hu JE, Liu JZ. Application research on digital gastrointestinal X-ray machine in correcting ectopic and positioning of PICC. *J Nurs* 2010; 17: 59-61.
16. Wan YH, Peng GG, Cheng SM. Application of radiotherapy simulation localization machine in PICC catheter heterotopias. *Med Equipment* 2010; 31: 81-2.
17. Hu JE. Application research on two-dimensional and color doppler ultrasound in the correct PICC catheter heterotopia. *J Nurs* 2008; 15: 68-70.
18. Park JY, Kim HL. A comprehensive review of clinical nurse specialist-led peripherally inserted central catheter placement in Korea: 4101 cases in a tertiary hospital. *J Infus Nurs* 2015; 38: 122-8.
19. Rangel UV, Gomes Junior SC, Costa AM, et al. Variables associated with peripherally inserted central catheter related infection in high risk newborn infants. *Rev Lat Am Enfermagem* 2014; 22: 842-7.
20. Din C. When critically ill elderly patients with PICC catheter individual position strategy. *J Nurs Training* 2013; 28: 1891-2.
21. Wan GX, Cao YW, Li WQ, et al. The catechol-O-methyltransferase Val158Met polymorphism contributes to the risk of breast cancer in the Chinese population: an updated meta-analysis. *J Breast Cancer* 2014; 17: 149-56.
22. Wan GX, Cao YW, Li WQ, et al. Associations between TLR9 polymorphisms and cancer risk: evidence from an updated meta-analysis of 25,685 subjects. *Asian Pac J Cancer Prev* 2014; 15: 8279-85.
23. Cheng H, Cheng W, Yang XH. Nursing of oppressed together with partial pressure head shoulder preventing internal jugular vein catheter heterotopias. *Med Today* 2014; 20: 108-9.
24. Zhang JR. Application on improvement of PICC tube insertion in breast cancer patients. *Chin Med Pharm* 2012; 2: 160-2.
25. Lu H. Research on ultrasound guided by the traditional method of turning neck and finger-pressing preventing PICC ectopic effect. *J Xinjiang Med* 2015; 45: 344-6.
26. Jiang XL, Zhu MZ. Application research on cross sectional press combined with vascular ultrasound instrument for prevention of PICC catheter heterotopia to jugular vein. *Nur Res* 2014; 28: 1734-5.
27. Ma JX, Tao LY. Application of pressing method on preventing PICC from straying into jugular vein. *J Nurs Admin* 2013; 13: 603-4.
28. Xu HP. Finger pressing method with turned lower jaw reduce cervical ectopic PICC catheter. *J Jiangsu Med* 2014; 40: 2089-90.
29. Schulz KF, Moher D, Altman DG. CONSORT 2010 comments. *Lancet* 2010; 376: 1222-3.

Received: 12.10.2021, accepted: 25.11.2021.