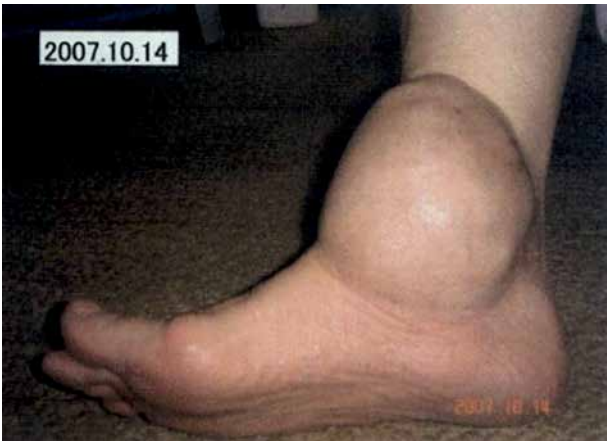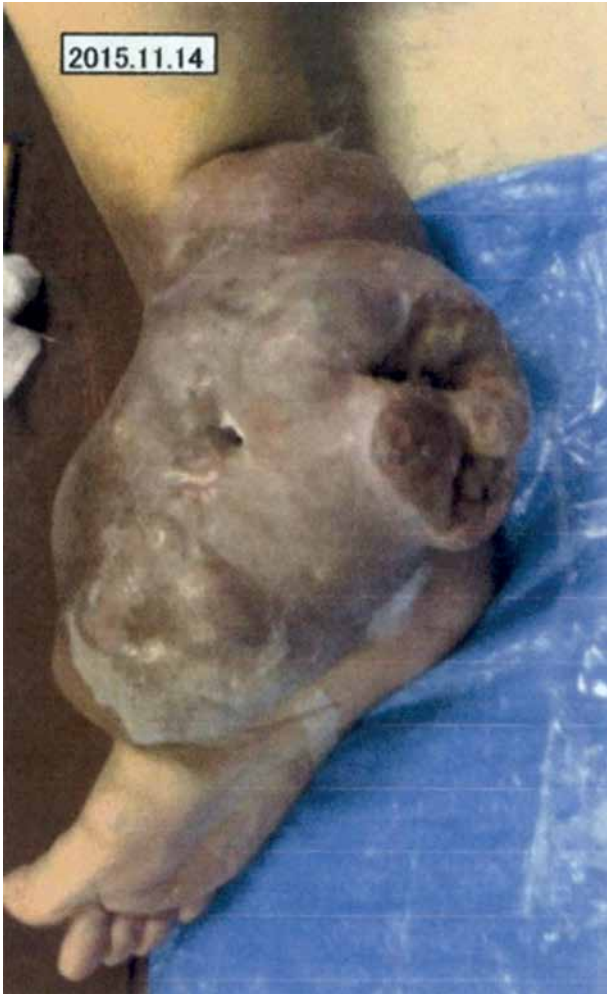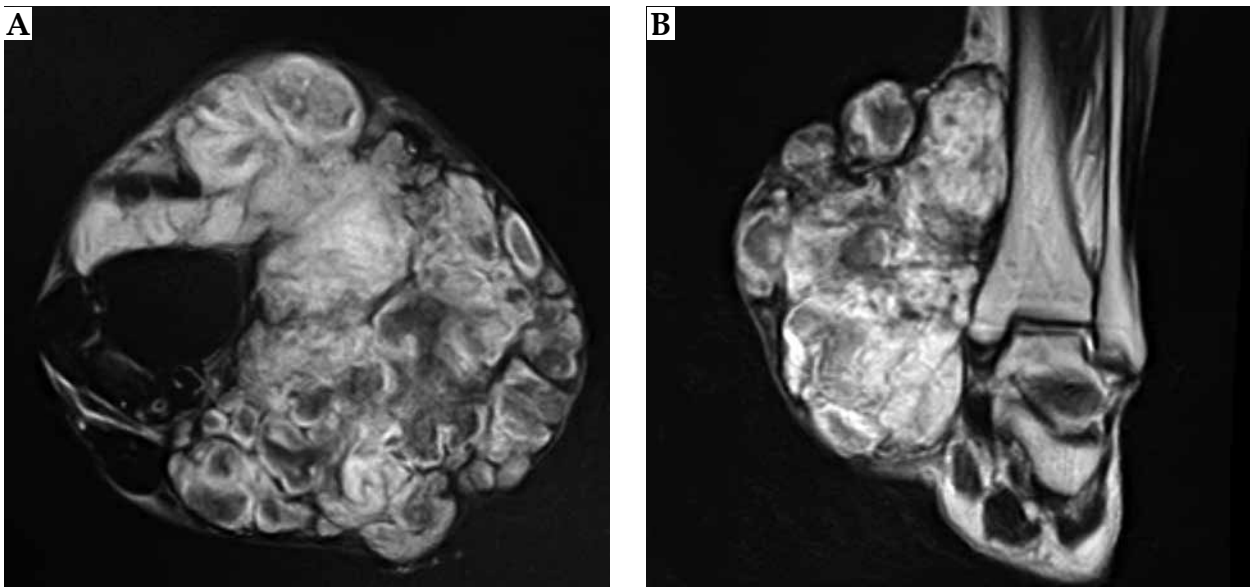




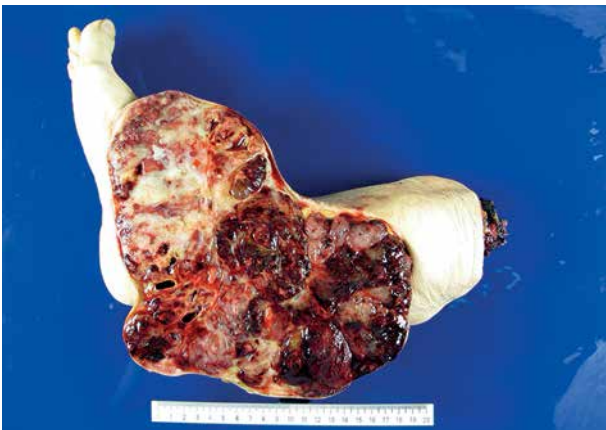Supplementary Fig. 1. Photograph of the right ankle joint tumor from 2007



Supplementary Fig. 2. Photograph of the right ankle joint tumor from 2015 showing the tumor accompanied with necrosis and infection



Supplementary Fig. 3. Pre-treatment MRI images of the right ankle joint tumor. **A)** Axial view, **B)** coronal view



Supplementary Fig. 4. Gross finding of surgical specimen for the right ankle joint tumor