

# EXPRESSION OF PROTEINS ASSOCIATED WITH THERAPY RESISTANCE IN RHABDOMYOSARCOMA AND NEUROBLASTOMA TUMOUR CELLS

ANNA PITUCH-NOWOROLSKA<sup>1</sup>, MARCIN ZAREMBA<sup>2</sup>, AGNIESZKA WIECZOREK<sup>3</sup>

<sup>1</sup>Department of Clinical Immunology, Jagiellonian University Medical College, Kraków

<sup>2</sup>Department of Pathology, Polish-American Institute of Paediatrics, Jagiellonian University Medical College, Kraków

<sup>3</sup>Students' Scientific Association, Jagiellonian University Medical College, Kraków

The activity of multidrug resistance (MDR) proteins in tumour cells is associated with an increased resistance to therapy and in consequence with a decreased effectiveness of chemotherapy. The majority of MDR molecules belong to a family of ABC (ATP binding cassette) transporters. Neuroblastoma (NBL) and rhabdomyosarcoma (RMS) are common solid tumours of childhood. The response to therapy is better in NBL, worse in RMS, but still unsatisfactory despite surgery and aggressive chemotherapy. The immunohistochemical staining for p-gp (p-glycoprotein), MRP1 (multidrug resistance associated protein 1), BCRP (breast cancer resistance protein) and LRP (lung resistance protein) expression was performed in primary tumour sections of NBL (10 cases) and RMS (10 cases).

A different pattern of MDR expression in NBL and RMS were noted. In NBL, MRP1 was expressed in all studied tumours, p-gp, BCRP only in 3 out of 10 tumours, LRP, in 4 cases. The combination of more than one protein was noted in the majority of NBL tumours. In RMS, the expression of 3 or 4 MDR proteins was noted in 9 cases. The high expression of an MDR protein profile in RMS suggests various mechanisms acting simultaneously, which might explain chemotherapy resistance and a low percentage of long-time survival in this tumour.

**Key words:** rhabdomyosarcoma, neuroblastoma, multidrug resistance proteins, children.

## Introduction

Rhabdomyosarcoma (RMS) and neuroblastoma (NBL) are common soft tissue tumours of childhood. The results of therapy including surgery and aggressive chemotherapy are still unsatisfactory. In RMS, the prognosis is associated with a histological type (embryonal including botryoides and alveolar), age of patients and clinical stage at diagnosis. In clinical stage I and II, the survival (3-year failure free) is 60-80% of patients while in stage IV this number decreases to 20-30% [1, 2]. The relapses are generally associated with a therapy failure and further decrease in patients' survival [1, 2]. In recent years, the intensified chemotherapy has improved results of

therapy but they are still below those expected. Moreover, the expression of multidrug resistance (MDR) proteins (glycoprotein p – p-gp, multidrug resistance related protein 1 – MRP1, breast cancer resistance protein – BCRP and lung resistance protein – LRP) is recognized as an additional unfavourable marker for therapy and prognosis [3-5].

The long-time survival in NBL depends on the clinical stage, age of patients, n-Myc amplification and presence of tumour markers [6]. In an advanced stage and high-risk disease, the survival remains low despite the most aggressive therapy, including an intensified chemotherapy protocol, surgery of the primary tumour and ablative therapy before bone marrow transplantation [6]. A list of known unfavourable

factors in NBL includes the age (more than 1 year of age), advanced clinical stage, high level of tumour markers (ferritin, lactodehydrogenase – LDH, neuron specific enolase – NSE), high number of n-Myc copies and expression of MDR proteins (mainly MRP and LRP) [6-8].

The study of MDR proteins concentrates on common proteins, i.e. p-gp (MDR1), MRP1, BCRP and LRP. The p-gp and MRP1 belong to ATP cassette binding transporters with the activity of a drug efflux pump which exports selected substrates (including chemotherapeutics) from the cells. BCRP protein is a half-transporter with mitoxanthrone as the main substrate. LRP belongs to vault proteins with an activity resulting in reduction in the intracellular level of drugs. In the physiology, LRP is expressed in many tissues including suprarenal gland and muscles – tissues of NBL and RMS origin. The precise mechanism of LRP activity is not known [9-13].

A list of p-gp substrates includes alkaloid of Vinca rosacea, daunorubicin and derivatives, mitoxanthrone and etoposide [11, 12]. The physiological expression of p-gp was noted in many tissues including liver, kidney, hematopoietic cells, jejunum and placenta. The MRP1 molecules were found in the cell membrane, in Golgi structures and plasmatic reticulum. The first known substrate of MRP1 is mitoxanthrone but all drugs conjugated to acidic ligands during the intracellular transport and metabolism may be a target for this molecule [12-14].

The occurrence of p-gp in RMS is within the wide range of patients' number. The intensity of expression is different in reported groups of patients. The methods used in these studies may be responsible for these different results. However, the high expression is strongly associated with shorter survival of patients [3, 10]. The expression of MRP1 was associated with an alveolar type of RMS, which might be an additional factor explaining poorer results in this histological type of the tumour [3]. In NBL cells, the p-gp was noted

in about 80% of patients and was considered as most common MDR proteins in this tumour. The role of p-gp in therapy resistance of tumour cells was indicated following the observation of an increased p-gp expression after chemotherapy in metastases or relapsing tumour cells [10, 15]. The high expression of MRP1 was associated with a high number of n-MYC copies and poor prognosis in NBL [7] but this study included analysis of MRP1 gene expression only. The high level of n-MYC seems to promote the expression and activity of MRP1, which suggests the synergistic mechanism of an increased resistance to therapy [8, 16].

The purpose of this study was to determine the expression of different MDR proteins (p-gp, MRP1, BCRP, LRP) and to analyse the association between their expression in NBL and RMS primary tumour cells in children.

## Material and methods

Groups of patients included 10 cases of RMS and 10 cases of NBL. The diagnosis of RMS and NBL was based on histology of the tumour and expression of desmin, MyoD protein (for RMS), NSE (for NBL) in malignant cells. The clinical characteristics of patients are shown in Table I.

The paraffin-embedded sections from primary tumour biopsies were used. After de-paraffinisation the sections were stained with monoclonal antibodies for the following MDR proteins:

- p-gp (Multidrug Resistance protein 1) with monoclonal antibody (mAb) clone JSB-1 (Monosan, Uden, Netherlands) in 1 : 100 working dilution, overnight incubation,
- BCRP (Breast Cancer Resistance Protein) with mAb clone BXP-21 (Monosan) in 1 : 150 working dilution, 2 hrs of incubation,
- mRP1 (Multidrug Resistance Related Protein) with mAb clone MRPr1 (Monosan) in 1 : 100 working dilution, 2 hrs of incubation,

**Table I.** The characteristics of patients with RMS and NBL included into the study

TUMOUR	GENDER BOYS/GIRLS	AGE YEARS (MEAN)	HISTOLOGICAL TYPE	LOCALIZATION OF THE PRIMARY TUMOUR
RMS	6/4	< 1-3 years – 3 4-10 years – 6 teenagers – 1 (6.4 years)	embryonal – 8 alveolar – 2	nose and pharynx – 2 pelvis (bladder, anal region) – 5 abdomen – 1 testes and epididymides – 2
NBL	6/4	< 1-3 years – 6 4-10 years – 2 teenagers – 2 (4.7 years)	neuroblastoma – 10	mediastinal mass – 3 abdomen (retroperitoneal) – 4 suprarenal gland – 2 femur – 1

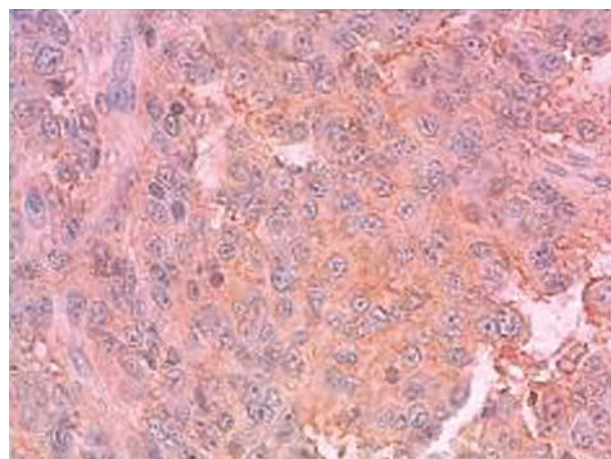
- LRP (Lung Resistance Protein) with mAb clone LRP-56 (Monosan) in 1 : 50 working dilution, 2 hrs of incubation.

The visualization of reaction was performed with DakoCytomation EnVision+ system HRP (DAB) (DAKO, Glostrup, Denmark) according to the manufacturer's instruction. The microscopic analysis included at least 300 cells and was performed by 2 independent investigators. The expression of a given protein was considered when no less than 10% of malignant cells showed positive reaction. The results are expressed as a percentage of positive cells and intensity of expression is described as: weakly positive (+), positive (++), strongly positive (+++).

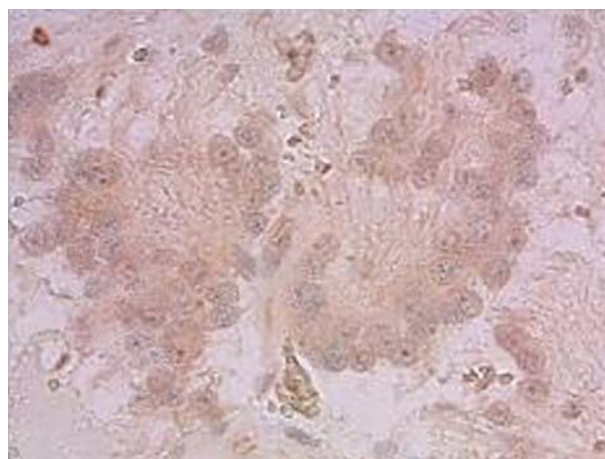
## Results

The expression of p-gp in tumour cells was noted in 7 cases: 3 cases of NBL and 4 cases of RMS. The

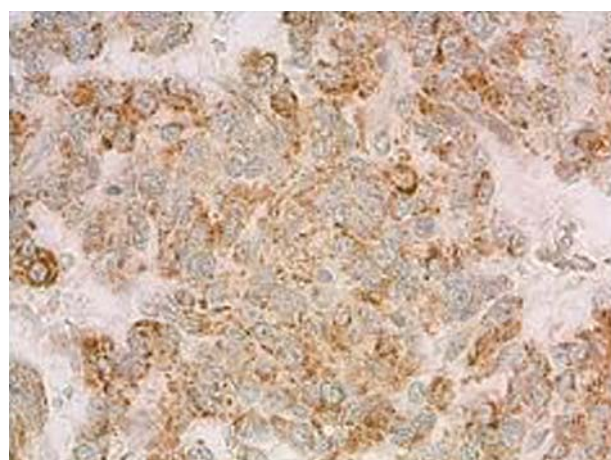
intensity was low with the exception of 1 case of RMS (strong reaction). The expression of BCRP was noted only in 3 cases of NBL and all cases of RMS. The intensity of expression in NBL cells was low in contrast to RMS tumour cells, which showed high intensity in the majority of cases – 8 out of 10 (Fig. 1). MRP1 expression was seen as granular type reaction from single granule (weak reaction) to cytoplasm filled by granules (high expression). In both studied tumours (NBL and RMS), the expression of MRP1 was noted in all cases but the reaction in NBL cells was rather weak (5 cases), positive (4 cases) and strong only in 1 case. The reaction in RMS was much higher and the expression regarded as positive was noted in 4 cases, strongly and very strongly positive – in 4 cases. The weak reaction was noted only in the remaining 2 cases (Fig. 2). The expression of LRP protein was observed in 6 cases of NBL and 9 cases of RMS. The reaction in both groups varied and ranged from weak to strong.



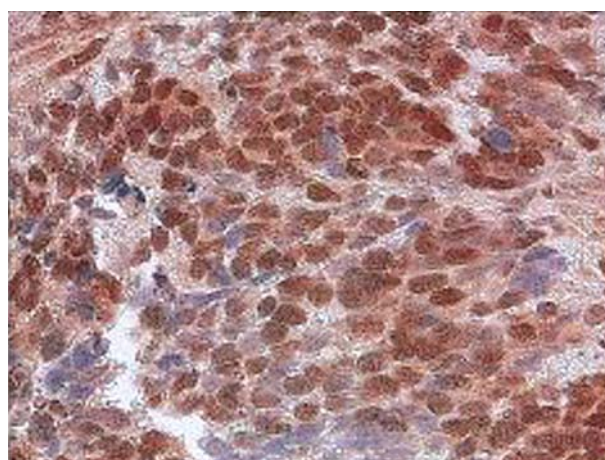
P-gp expression on NBL cells. The immunohistochemical staining showed high intensity – (++)



BCRP expression on NBL cells. The intensity was weak – (+)

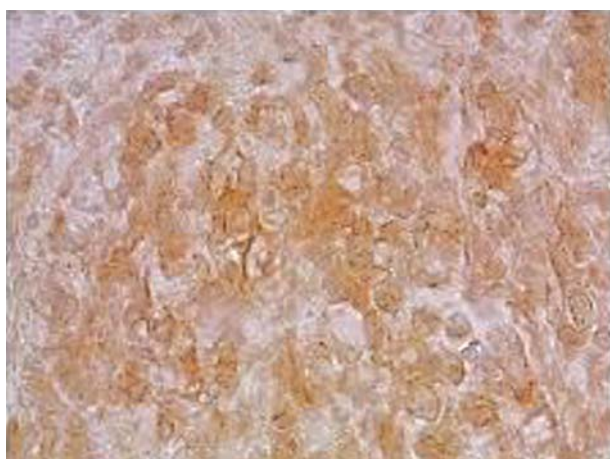


MRP1 expression on NBL cells. The intensity was strong – (++)

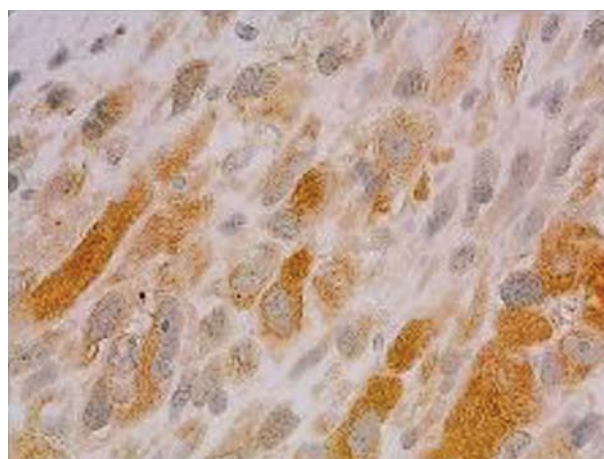


LRP expression on NBL cells. The intensity was very strong (+++)

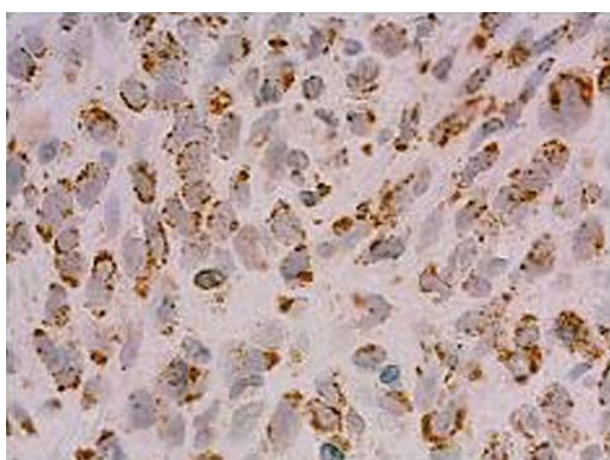
**Fig. 1.** Expression of multidrug resistance (MDR) proteins in neuroblastoma (NBL) primary tumour cells. The immunohistochemical staining with monoclonal antibodies against given proteins was performed in standard conditions



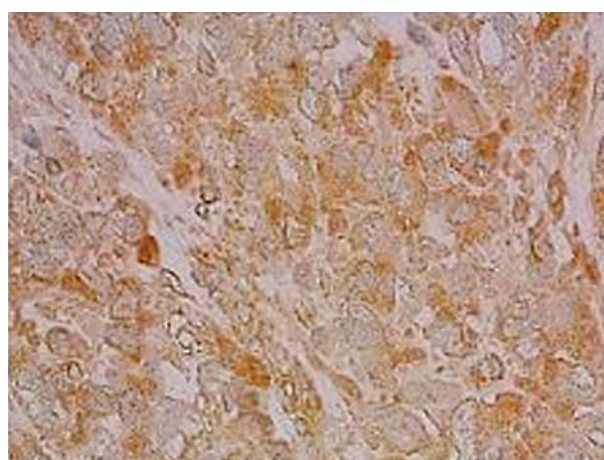
P-gp expression on RMS cells. The intensity was strong – (++)



BCRP expression on RMS cells. The intensity was very strong (+++)



MRP1 expression on RMS cells The intensity was strong – (++)



LRP expression on RMS cells. The intensity was very strong (+++)

**Fig. 2.** Expression of multidrug resistance (MDR) proteins in rhabdomyosarcoma (RMS) primary tumour cells. The immunohistochemical staining with monoclonal antibodies against given proteins was performed in standard conditions

Rhabdomyosarcoma tumour cells showed the presence of more than one MDR protein in the majority of cases. The expression of 3 or 4 different proteins present simultaneously was noted. Neuroblastoma cells showed expression of a single resistance protein (MRP1) or a combination but only in 4 cases such combination (3 or 4 proteins) was present (Table II).

## Discussion

The determination of MDR proteins in NBL and RMS primary tumour tissue showed a different pattern of their expression. In NBL, the expression of MRP1 was common while p-gp, BCRP and LRP was observed in the minority of studied cases. The combination of more than one protein was noted in the majority of NBL tumour cases. In RMS almost in all cases the expression of at least 3 MDR proteins was

**Table II.** Expression and co-expression of MDR proteins in NBL and RMS primary tumour cells

MULTIDRUG RESISTANCE PROTEIN PROFILE	NBL	RMS
p-gp + MRP1 + LRP	2	0
p-gp + BCRP + MRP1 + LRP	1	4
BCRP + MRP1	1	1
BCRP + MRP1 + LRP	1	5
MRP1	3	0
MRP1 + LRP	2	0

noted. The complex expression of MDR proteins in RMS may be associated with a higher chemotherapy resistance and lower percentage of long-time survival in this type of tumour as an additional mechanism.

The expression of gene and/or protein of p-gp in NBL was noted in a wide range of patients depending on the groups studied [17, 18]. Moreover, in the majority of these studies no obvious association with prognosis, metastases formation, and overall, disease-free survival was noted [15, 17, 18]. The increase of p-gp expression along the clinical stages of NBL was suggested in one study [10]. The analysis of NBL patients with a better and worse prognosis showed the association of p-gp expression with a better prognosis but the majority of these patients were younger than one year. This prognosis might depend on the age of patients, which seemed to be a better predictive factor for a good prognosis than expression of p-gp [18]. In our study of NBL tumour cells, low expression of p-gp was observed in both aspects – the number of cases expressing p-gp and low intensity of staining resembling the amount of p-gp molecules in a single cell. The study of RMS tumour cells showed expression of p-gp in a wide range depending on methods of assay and no association with survival of patients [3-5]. In two studies concerning 45 patients (children and adults) and 13 children, the p-gp expression was high in both aspects – intensity of staining and a number of cases expressing this MDR molecule (80%) [4-5]. In our study, the expression of p-gp was noted only in 4 patients and the intensity of staining was low.

MRP1 proteins are now considered as important for drug resistance in solid tumours. In NBL, the correlation between expression of MRP1 and overexpression of the n-MYC gene increased the risk of therapy failure. Moreover, there were some data suggesting the regulation of MRP1 expression by the n-MYC oncogene [8, 16], which might explain the correlation between expression of MRP and n-MYC. It suggested the synergistic effect on therapy leading to shorter survival of patients. In cases with a low number of n-MYC copies, MRP1 protein remained a significant independent prognostic factor for poor survival of NBL patients [8, 19]. The predictive role of MRP1 expression was showed in large groups of 209, 206 and 90 NBL patients [7, 8, 19]. However, in the last study, the level of MRP1 expression (low or high) was without any clinical significance [19]. In our study, expression of MRP1 was noted in all cases of NBL but the intensity of staining was rather low. MRP1 expression was independent of other MDR proteins and was noted as a single MDR protein in NBL cells. It stressed the importance of MRP1 expression in resistance to therapy in this tumour.

In RMS, the expression of MRP1 was noted in more than half of studied tumours and was present in both (embryonal and alveolar) histological types. However, MRP negative cases were of an embryonal type of RMS only [4-5]. The clinical significance of MRP1 expression on RMS tumour cells differs

depending on the group of patients. The association with shorter survival was noted in a study of 23 RMS patients [3] while no association was observed in other groups of 13 and 45 RMS patients [4-5]. In our cases of RMS, expression of MRP1 was showed in all cases and all of them were in combination with other MDR proteins.

The clinical significance of LRP expression in RMS was shown in refractory tumours after chemotherapy [4-5]. It suggested that primary tumours were resistant because of p-gp, MRP1 dependent mechanisms in contrast to chemotherapy-induced resistance that is based on LRP activity. The lack of correlation between LRP and p-gp or MRP1 expression indicated different regulation of LRP expression than other ABC transporters [4-5]. In our study, expression of LRP was noted in 6 cases of NBL and almost all cases (9 out of 10) of RMS in primary tumours before therapy. Moreover, LRP expression was noted only in combination with other MDR proteins. These data made it difficult to interpret clinical significance of a particular MDR protein (MRP1 or LRP) in studied tumours. There are no data about expression of BCRP in NBL and RMS primary tumours in children. In our study, expression of BCRP was found in 3 cases of NBL and all cases of RMS but in combination with other MDR proteins.

The studies of the profile of MDR proteins expression in primary tumour are scarce [3-5]. However, the same relations between these proteins were found e.g. p-gp correlated with MRP expression in RMS tumours [5]. The expression of combination (profile) of MDR proteins indicates a different defensive mechanism activity in the same single tumour cell, which significantly increases possibility of a tumour cell to survive. In RMS, expression of MDR proteins was only in combination mainly with MRP1, BCRP and LRP. The activity of a wide range of MDR proteins might be associated with resistance of primary tumour cells and cells after induction therapy (chemotherapy-induced resistance) to the majority of cytostatics used in RMS and NBL treatment.

## References

1. Arndt C, Tefft M, Gehan E. A feasibility, toxicity and early response study of etoposide, ifosfamide and vincristine for the treatment of children with rhabdomyosarcoma. *J Pediatr Hematol/Oncol* 1997; 19: 124-129.
2. Stuart A, Radhakrishnan J. Rhabdomyosarcoma. *Indian J Ped* 2004; 71: 331-337.
3. Gallego S, Llorca A, Paradea A, et al. Expression of multidrug resistance -1 and multidrug resistance associated proteins genes in pediatric rhabdomyosarcoma. *Oncol Reports* 2004; 11: 179-183.
4. Klunder JW, Komdeur R, van der Graaf WTA, et al. Expression of multidrug resistance associated proteins in rhabdomyosarcomas before and after chemotherapy. *Human Pathol* 2003; 34: 150-155.

5. Komdeur R, Klunder JW, van der Graaf WTA, et al. Multidrug resistance proteins in rhabdomyosarcomas. *Cancer* 2003; 97: 1999-2005.
6. Weinstein JL, Katzenstein HM, Cohn SL. Advances in the diagnosis and treatment of neuroblastoma. *Oncologist* 2003; 8: 278-292.
7. Haber M, Smith J, Bordow SB, et al. Association of high-level MRP1 expression with poor clinical outcome in a large prospective study of primary neuroblastoma. *J Clin Oncol* 2006; 24: 1546-1553.
8. Pajic M, Norris MD, Cohn SL, et al. The role of multidrug resistance-associated protein 1 gene in neuroblastoma biology and clinical outcome. *Cancer Letters* 2005; 228: 241-246.
9. Schmitt L, Tampe R. Structure and mechanism of ABC transporters. *Curr Opin Structural Biol* 2002; 12: 754-760.
10. Zaremba M. Lekooporność w nowotworach wieku dziecięcego. Część I – białka związane z lekoopornością. *Onkol Pol* 2005; 8: 57-61.
11. Leonard GD, Fojo T, Bates SE. The role of ABC transporters in clinical practice. *Oncologist* 2003; 8: 411-424.
12. Gottesman MM, Fojo T, Bates SE. Multidrug resistance in cancer: role of ATP-dependent transporters. *Nature Reviews Cancer* 2002; 2: 48-56.
13. Ejendal KFK, Hrycyna ChA. Multidrug resistance and cancer: the role in the human ABC transporter ABCG2. *Curr Protein Peptide Science* 2002; 3: 503-511.
14. Borst P, Evers R, Koel M, et al. A family of drug transporters: the multidrug resistance-associated proteins. *J Natl Cancer Inst* 2000; 92: 1295-1302.
15. Kutluk MT, Ayhan A, Gogus S, et al. Glutathione-S-transferase and p-glycoprotein expression in neuroblastoma. *Ped Hematol Oncol* 2002; 19: 337-345.
16. Norris MD, Smith J, Tanabe K, et al. Expression of multidrug transporter MRP4/ABCC4 is a marker of poor prognosis in neuroblastoma and confers resistance to irinotecan in vitro. *Mol Cancer Ther* 2005; 4: 547-553.
17. Cremoux P, Jourdan-Da-Silva N, Couturier J, et al. Role of chemotherapy resistance genes in outcome of neuroblastoma. *Ped Blood Cancer* 2007; 48: 311-317.
18. Obana K, Hashizume K. Expression of multidrug resistance-related P-glycoprotein shows good prognosis in neuroblastoma. *J Ped Surgery* 1997; 32: 420-422.
19. Goto H, Keshelava N, Matthyay KK, et al. Multidrug resistance-associated protein 1 (MRP1) expression in neuroblastoma cell lines and primary tumours. *Med Ped Oncol* 2000; 35: 619-622.

#### Address for correspondence

Anna Pituch-Noworolska MD, PhD  
Department of Clinical Immunology  
Polish-American Institute of Paediatrics  
Jagiellonian University Medical College  
ul. Wielicka 265  
30-663 Kraków  
phone/fax +48 12 658 17 56  
e-mail: mipituch@cyf-kr.edu.pl