

# ADENOMATOID TUMOUR OF THE ADRENAL GLAND: A CASE REPORT AND LITERATURE REVIEW

MAGDALENA BIALAS<sup>1</sup>, WOJCIECH SZCZEPAŃSKI<sup>1</sup>, JOANNA SZPOR<sup>1</sup>, KRZYSZTOF OKOŃ<sup>1</sup>,  
MARTA KOSTECKA-MATYJA<sup>2</sup>, ALICJA HUBALEWSKA-DYDEJCZYK<sup>2</sup>, ROMANA TOMASZEWSKA<sup>1</sup>

<sup>1</sup>Chair and Department of Pathomorphology, Jagiellonian University Medical College, Kraków

<sup>2</sup>Chair and Department of Endocrinology, Jagiellonian University Medical College, Kraków

Adenomatoid tumour (AT) is a rare, benign neoplasm of mesothelial origin, which usually occurs in the genital tract of both sexes. Occasionally these tumours are found in extra genital locations such as heart, pancreas, skin, pleura, omentum, lymph nodes, retroperitoneum, intestinal mesentery and adrenal gland. Histologically ATs show a mixture of solid and cystic patterns usually with focal presence of signet-ring like cells and scattered lymphoid infiltration. The most important thing about these tumours is not to misdiagnose them as primary malignant or metastatic neoplasms. We present a case of an adrenal AT in a 29-year-old asymptomatic male. The tumour was an incidental finding during abdominal CT-scan for an unrelated condition. We also present a review of the literature concerning adrenal gland AT and give possible differential diagnosis.

**Key words:** adenomatoid tumour, adrenal gland, immunophenotype.

## Introduction

Adenomatoid tumour (AT) is a benign neoplasm of mesothelial origin [1-3]. The usual place of its appearance is the male and female genital tract, most often epididymis in men and fallopian tube in women [4, 5]. Extragenital ATs have occasionally been described in heart [6], pancreas [7], skin [8], pleura [9], omentum [10], lymph nodes [11], retroperitoneum [12], intestinal mesentery [13], periadrenal soft tissue [14] and adrenal gland [15-31].

We report the clinicopathological and immunohistochemical findings of an incidentally discovered AT of the right adrenal gland in a 29-year-old man.

## Material and methods

The resected adrenal gland with tumour was fixed in a 10% buffered formaldehyde solution. Representative sections of the tumour were embedded in paraffin. Tissue samples were cut into approximately 4 µm thick sections by microtome, placed on glass slides and stained with haematoxylin end eosin for

histopathological examination. Additional sections were made for immunohistochemical analysis (for details see Table I).

Proliferative activity of the tumour was determined using immunohistochemical staining for nuclear protein MIB-1 (Ki-67). The proliferative activity rate (MIB-index) was calculated as a percentage of nuclei positive for MIB-1 in five areas of 100 cells each.

Clinical data were obtained from the patient's files in the Endocrinology and Surgery Departments.

## Results

### Clinical and macroscopic findings

A 29-year-old male was admitted to the hospital with the diagnosis of inguinal hernia. The pre-operative imaging procedures revealed a well circumscribed, mostly solid, 4 µm tumour of the right adrenal gland. The right adrenal gland with the tumour was removed.

The material sent for the histological examination weighted 34 g and consisted of fatty tissue and

**Table I.** Primary antibodies used for immunohistochemical staining

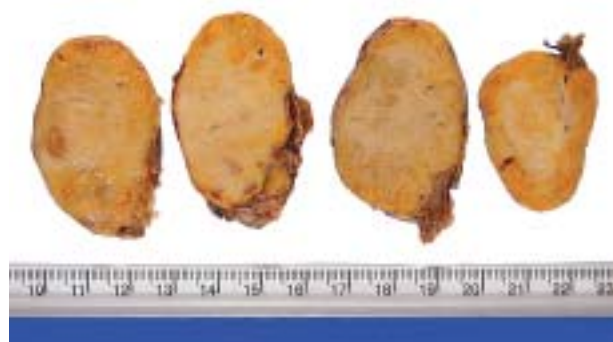
| ANTIBODY    | PRETREATMENT   | DILUTION/<br>INCUBATION TIME | DETECTION<br>METHOD | MANUFACTURER |
|-------------|----------------|------------------------------|---------------------|--------------|
| AE1/AE3     | citrate buffer | 1/50 (30')                   | LAB VISION          | Dako         |
| CK5/6       | EDTA           | 1/50 (30')                   | EN VISION           | Dako         |
| CK7         | citrate buffer | 1/50 (30')                   | EN VISION           | Dako         |
| CK20        | citrate buffer | 1/50 (30')                   | EN VISION           | Dako         |
| calretinin  | citrate buffer | 1/100 (60')                  | EN VISION           | Novocastra   |
| D2-40       | citrate buffer | ready to use (30')           | EN VISION           | Polgen       |
| CD31        | EDTA           | 1/20 (60')                   | EN VISION           | Dako         |
| CD34        | citrate buffer | 1/50 (30')                   | LAB VISION          | Dako         |
| factor VIII | citrate buffer | 1/50 (60')                   | EN VISION           | Dako         |
| Ki-67       | citrate buffer | 1/50 (night)                 | LAB VISION          | Dako         |

enlarged adrenal gland. On cross-sections a mass 4 cm in the biggest dimension arising from not-widened 3.5 cm long adrenal gland was seen (Fig. 1). The tumour was solid and well circumscribed. Its cut surface was smooth, greyish-white and partly yellow without haemorrhage or necrosis.

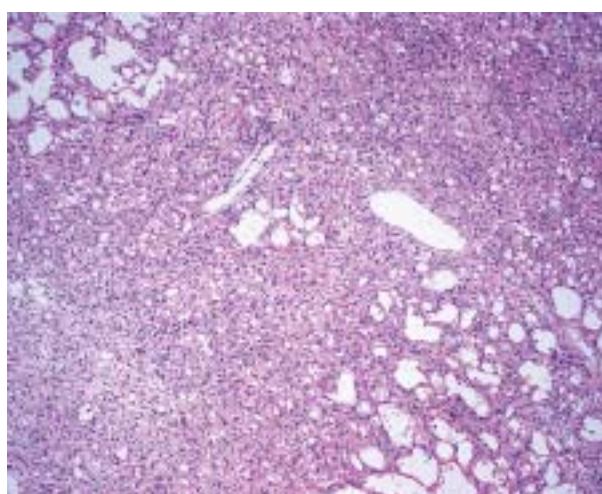
### Histological findings

The histological examination revealed an unencapsulated tumour consisting of a mixture of different patterns: gland-like spaces of various size, irregular outline and focal cystic dilation and solid nests of cells set in a fibrous stroma (Fig. 2). The tumour structures were seen between nests of residual adrenocortical cells (Fig. 3). A discontinuous rim of compressed adrenal cortex was focally present around the tumour. Cells lining these irregular chan-

nels and tubular structures were mostly flattened resembling endothelial cells (Fig. 2). Some of them were plump with epithelioid features and abundant cytoplasm. Small groups of cells with the appearance of so-called signet-ring cells with round, intracytoplasmic vacuoles were also seen (Fig. 3). Nuclei were vesicular, occasionally with small nucleolus. None of the cells exhibited atypia or pleomorphism. Mitotic figures and necrosis were absent. Small lymphoid aggregates and foci of lipomatous metaplasia were focally present within the tumour (Fig. 4). The adrenal medulla had typical histological structure without evidence of the tumour cells. Mucicarmin stain did not reveal any presence of mucin within signet-ring like cells or in tumour channels. An immunohistochemical examination showed that the tumour cells exhibited strong expression of cytokeratin



**Fig. 1.** Cut surface of the adrenal gland showing a solid, well circumscribed tumour with smooth, greyish-white surface



**Fig. 2.** Adrenal AT composed of mixture of patterns: fenestrated channels of varied size and irregular outlines, and solid nests of cells (HE, 10×)



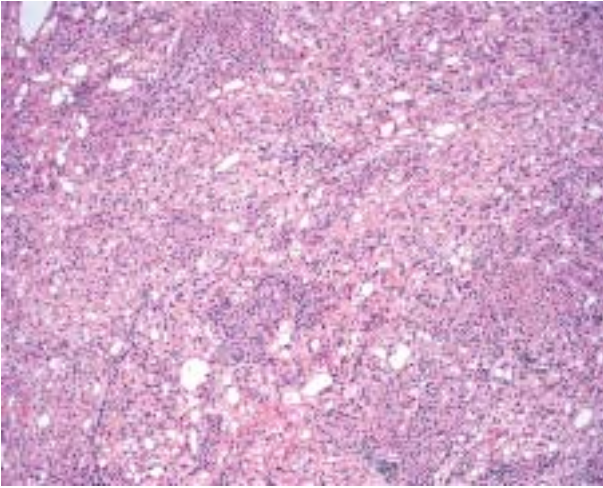


Fig. 3. Tumour structures intermingled with residual adrenal cortical tissue (HE, 10×)

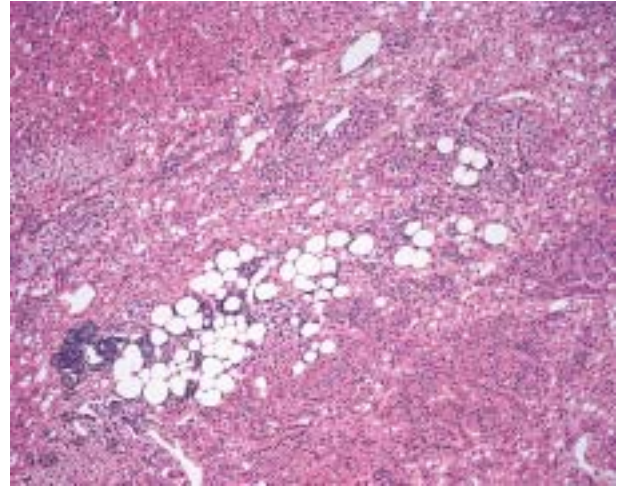


Fig. 4. Focal lymphoid aggregates and foci of lipomatous metaplasia within AT (HE, 10×)

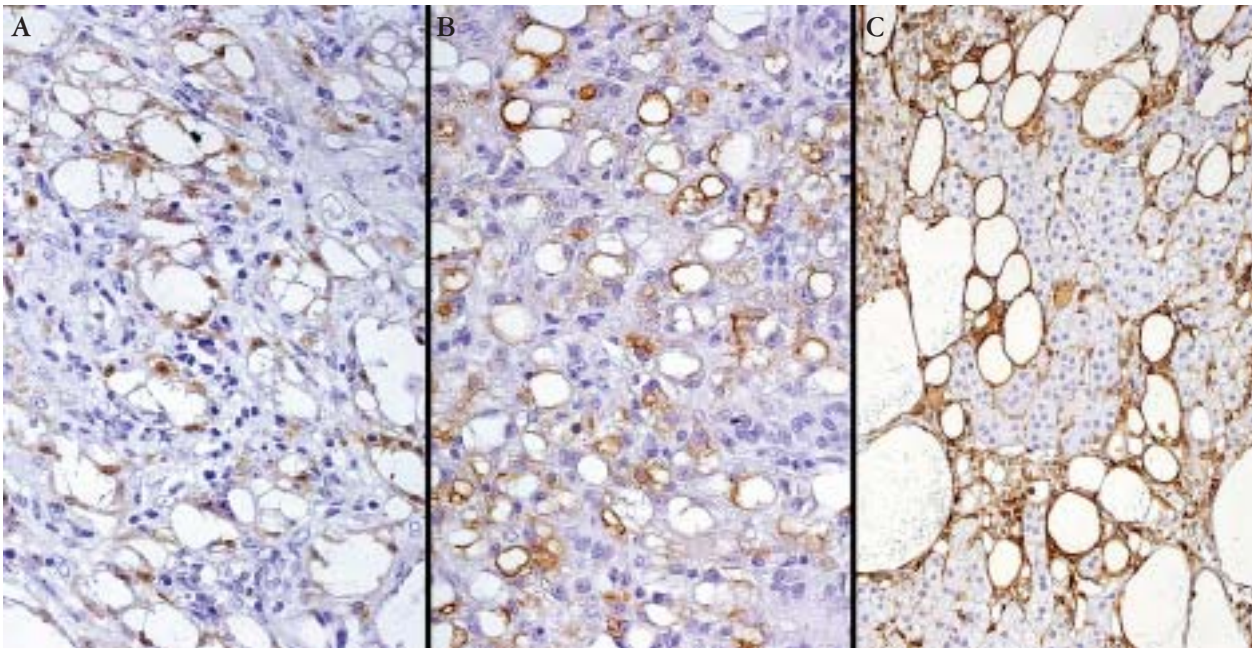


Fig. 5. Adrenal AT immunohistochemistry: A) calretinin, B) D2-40, C) Vimentin

AE1/AE3, CK7, calretinin (Fig. 5), D2-40 (Fig. 5) and vimentin (Fig. 5). Focal expression of cytokeratin CK5/CK6 was observed. Tumour cells did not express any vascular markers like: CD31, CD34 and Factor VIII or epithelial marker CK20. Proliferating activity measured by expression of proliferative marker Ki-67 (MIB-index) did not exceed 1% of cells.

## Discussion

AT is a rare finding usually present in the genital tract. Adrenal gland AT is extremely rare: we could only find 27 cases reported previously in the litera-

ture [15-31]. Only four authors reported more than one case of AT [16-18, 28] with the biggest series consisting of 5 cases [18]. Characteristics of the 28 adenomatoid tumours reported previously together with our case are summarized in Table II.

ATs occurred in young adults mostly in the 3<sup>rd</sup>-4<sup>th</sup> decades of life. The average age of patients in all reported cases was 40, ranging from 24 to 64 years. Only 6 patients were older than 50.

Most of the patients with the adrenal gland AT were men. Only one tumour was reported in a woman [16]. A possible explanation for this disproportion can be connected with the differences in embryological development of the gonads in both

**Table II.** Clinicopathological features of adenomatoid tumours of the adrenal gland

| PATIENT No. | AGE | SEX | LATE-RALITY | DIAM-ETER | CLINICAL FINDINGS AND SYMPTOMS                            | CITA-TION |
|-------------|-----|-----|-------------|-----------|---|-----------|
| 1.          | 26  | M   | R           | 15        | IRF (suspicion of a giant echinococcus cyst of the liver) | [15]      |
| 2.          | 49  | M   | R           | 1.3       | IFA   | [16]      |
| 3.          | 57  | M   | L           | 3.8       | IFA   | [16]      |
| 4.          | 50  | F   | R           | 0.5       | IFA   | [16]      |
| 5.          | 40  | M   | L           | 6.0       | IRF (found on CT scan during sarcoma staging)             | [16]      |
| 6.          | 46  | M   | R           | 1.2       | CT (symptoms: central and right flank abdominal pain)     | [17]      |
| 7.          | 33  | M   | L           | 1.7       | IRF (CT during workup for hypertension)                   | [17]      |
| 8.          | 33  | M   | R           | 4.2       | IRF (CT)  | [17]      |
| 9.          | 37  | M   | L           | 3.1       | IFS   | [18]      |
| 10.         | 31  | M   | R           | 3.2       | IRF   | [18]      |
| 11.         | 31  | M   | –           | 3.5       | IRF (investigation in the course of hypertension)         | [18]      |
| 12.         | 64  | M   | L           | 1.2       | IFA   | [18]      |
| 13.         | 44  | M   | L           | 3.2       | IRF (investigation in the course of hypertension)         | [18]      |
| 14.         | 24  | M   | L           | 1.1       | IRF (during investigation for Cushing syndrome)           | [19]      |
| 15.         | 30  | M   | L           | 3.0       | IFA   | [20]      |
| 16.         | 54  | M   | L           | 6.5       | IRF (investigation in the course of pneumonia)            | [21]      |
| 17.         | 31  | M   | R           | 4.0       | IRF   | [22]      |
| 18.         | 42  | M   | L           | 2.5       | IRF   | [23]      |
| 19.         | 54  | M   | R           | 3.6       | IRF   | [24]      |
| 20.         | 51  | M   | R           | 3.0       | IRF (investigation in the course of hypertension)         | [25]      |
| 21.         | 28  | M   | R           | 9.0       | IRF (investigation in the course of acute cholecystitis)  | [26]      |
| 22.         | 42  | M   | L           | 14.5      | IRF (during evaluation of renal colic)                    | [27]      |
| 23.         | 47  | M   | R           | 7.0       | IRF (CT performed for diverticulitis)                     | [28]      |
| 24.         | 52  | M   | R           | 5.5       | IRF (investigation in the course of hypertension)         | [28]      |
| 25.         | 44  | M   | L           | 3.5       | IRF (investigation in the course of hypertension)         | [29]      |
| 26.         | 34  | M   | R           | 3.0       | IFA   | [30]      |
| 27.         | 33  | M   | L           | 1.7       | IRF (investigation in the course of hypertension)         | [31]      |
| 28.         | 29  | M   | R           | 4.0       | IRF   | our case  |

*M – male, F – female, R – right adrenal gland, L – left adrenal gland, IRF – incidental radiographic finding, IFA – incidental finding during autopsy, IFS – incidental finding during surgery for unrelated reasons*

sexes, especially different role of mesonephric ducts in males and females [20] together with the hypothesis that ATs arise from inclusions of pluripotential mesenchyme cells associated with the Mullerian tract [1, 17-19]. The mesonephric duct in men slowly transforms into a duct of epididymis and remains in that form. The mesonephric duct in women regresses early during the embryogenesis [20]. The possibility of penetration of pluripotential mesenchyme cells from the developing mesonephric duct to different locations (e.g. adrenal glands) in women is much less probable than in men.

Adrenal ATs were almost equally distributed between the right and left adrenal glands (14 : 13), in one case, data were not available. Almost all cases were discovered incidentally during radiographic

examination [15-19, 21-29, 31], surgery for an unrelated reason [18] or during autopsy [16, 18, 20, 30].

ATs demonstrated a great degree of size variation: the smallest described examples were about 1 cm in diameter [16-19], the biggest one had about 15 cm [15]. 21 reported ATs were smaller than 5 cm and all were asymptomatic [16-20, 22-25, 28-31] as well as two the biggest tumours [15, 27]. Only one patient had symptoms which could be connected to adrenal mass [17]. The patient with central and right flank abdominal pain had a coexisting big adrenal cyst (11 cm in diameter) with only small AT 1.2 cm in diameter in the cyst wall. The symptoms were more probably connected with the big cystic mass in the abdomen than with the small solid area of AT in the cyst wall [17].



ATs were round, usually well circumscribed, gray or greyish-white with light-yellow areas. In some of them irregular cystic spaces had been macroscopically visible [16, 21, 23, 27].

The immunohistochemical profile was consistent with the one described in ATs in usual locations (genital tract) and was typical for the tumour of mesothelial origin: calretinin +, CK5/6+, CK7+, vimentin+, D2-40+, CD31-, CD34-.

Diagnosing difficulties of AT may arise when this tumour occurs in sites different from its usual location which is the urogenital tract. The adrenal AT tumour can mimic all other entities occurring in this place like: adenomas, carcinomas, pheochromocytomas, myelolipomas, benign cystic lesions and metastases from distant locations. It may also be easily misdiagnosed as vascular neoplasm: lymphangioma or angiosarcoma. Differential diagnosis includes all these entities.

Numerous irregular cystic spaces lined with flattened cells may suggest a vascular neoplasm, especially lymphangioma. However, the cells are positive for CK and they lack reactivity for the usual vascular markers (CD31, CD34, factor VIII), which excludes vascular tumours. It is important that ATs may show reactivity for D2-40, a marker which is known to be positive in endothelia of lymphatic vessels. At least in two cases reported in the literature ATs were primarily diagnosed as lymphangiomas [18].

Histologically all ATs presented a local pseudoglandular pattern often with an infiltrative appearance at the periphery which could lead to it being confused with adenocarcinoma. In case number 1 described by Isotalo [18] AT was incorrectly diagnosed as adenocarcinoma (the diagnosis from a frozen section). The final diagnosis from permanent sections was correct. Adenocarcinomas of the adrenal gland show striking nuclear pleomorphism, the mitotic figures are easily found and the cells are cytokeratin positive but they do not show co-expression of cytokeratin and calretinin (nuclear staining). The MIB-index in any reported AT was not higher than 3% (the highest one reported by Isotalo [18]). MIB-index in malignant primary and metastatic adrenal tumours is usually much higher.

Mucin stain may be helpful in excluding the neoplastic nature of signet-like looking cells. Such cells in AT are mucin negative. Signet-ring cell carcinoma (usually metastatic from a stomach) shows nuclear pleomorphism and cells contain a lot of acid mucin: dark blue droplets in Alcian-PAS. Cystic adenomas which are considered in differential diagnosis do not express CK and D2-40. Excluding cases of ATs found incidentally during autopsy, the local resection of the tumour was curative for all patients. No local recurrences or metastatic spread of AT have ever been reported.

In summary, ATs in extra genital sites like adrenal gland are very uncommon. Nonetheless, such diagnostic possibility should always be considered in order to avoid misdiagnosing them as primary or metastatic malignant tumours.

## References

- Cheng L, Ulbright TM. Adenomatoid tumor. In: World Health Organization Classification of Tumours. Pathology and Genetics of Tumours of Endocrine Organs. DeLellis RA, Lloyd V, Heitz PU (eds.). IARC Press, Lyon 2004; 167-168.
- Lack EE. Tumors of the Adrenal Gland and Extraadrenal Paraganglia – AFIP Atlas of Tumor Pathology. Silverberg SG, Sobin LH (eds.). American Registry of Pathology, Armed Forces Institute of Pathology, Washington 2007; 205-209.
- Wojewoda CM, Wasman JK, MacLennan GT. Adenomatoid tumor of the adrenal gland. *J Urol* 2008; 180: 1123-1124.
- Lack EE. Tumors of the adrenal gland. In: Diagnostic Histopathology of Tumors. Fletcher C (ed.). 3rd ed. Churchill Livingstone Elsevier 2007; 1099-1122.
- DeLellis RA, Mangray S. The Adrenal Glands. In: Sternberg's Diagnostic Surgical Pathology. Mills SE, Carter D, Greenson J (eds.). 5th ed. Lippincott Williams and Wilkins, 2009; 545-567.
- Natarajan S, Luthringer DJ, Fishbein MC. Adenomatoid tumor of the heart: report of a case. *Am J Surg Pathol* 1997; 21: 1178-1180.
- Overstreet K, Wixom C, Shabaik A, et al. Adenomatoid tumor of the pancreas: a case report with comparison of histology and aspiration cytology. *Mod Pathol* 2003; 16: 613-617.
- Adem C, Schneider M, Hoang C. Pathologic quiz case: An unusual umbilical mass. *Arch Pathol Lab Med* 2003; 127: 303-304.
- Kaplan MA, Tazelaar HD, Hayashi T, et al. Adenomatoid tumor of the pleura. *Am J Surg Pathol* 1996; 20: 1219-1223.
- Hanrahan JB. A combined papillary mesothelioma and adenomatoid tumor of the omentum: Report of the case. *Cancer* 1971; 27: 109-114.
- Isotalo PA, Nascimento AG, Trastek VF, et al. Extragenital adenomatoid tumor of a mediastinal lymph node. *Mayo Clin Proc* 2003; 78: 350-354.
- Benisch BM. A retroperitoneal mesonephric cystadenoma with features of the adenomatoid tumor of the genital tract. *J Urol* 1973; 44: 110-113.
- Craig JR, Hart WR. Extragenital adenomatoid tumor: Evidence for mesothelial theory of origin. *Cancer* 1979; 43: 1678-1682.
- Evans CP, Vaccaro JA, Storrs BG. Suprarenal occurrence of an adenomatoid tumor. *J Urol* 1988; 139: 348-349.
- Hoffmann M, Yedibela S, Hohenberger W, et al. Adenomatoid tumor of the adrenal gland. *Int J Surg* 2008; 6: 485-487.
- Raaf HN, Grant LD, Santoscoy C, et al. Adenomatoid tumor of the adrenal gland: a report of four new cases and a review of the literature. *Mod Pathol* 1996; 9: 1046-1051.
- Garg K, Lee P, Ro JY, et al. Adenomatoid tumor of the adrenal gland: a clinicopathologic study of 3 cases. *Ann Diag Pathol* 2005; 9: 11-15.
- Isotalo PA, Keeney GL, Sebo TJ, et al. Adenomatoid tumor of the adrenal gland. A clinicopathologic study of five cases and review of the literature. *Am J Surg Pathol* 2003; 27: 969-977.
- Travis WD, Lack EE, Azumi N, et al. Adenomatoid tumor of the adrenal gland with ultrastructural and immunohistochemical demonstration of mesothelial origin. *Arch Pathol Lab Med* 1990; 114: 722-724.
- Hamamatsu A, Arai T, Iwamoto K, et al. Adenomatoid tumor of the adrenal gland: case report with immunohistochemical study. *Patol Int* 2005; 55: 665-669.

21. Glatz K, Wegmann W. Correspondence: papillary adenomatoid tumour of the adrenal gland. *Histopathology* 2000; 37: 376-382.
22. Schadde E, Meissner M, Kroetz M, et al. Adenomatoider tumor der Nebenniere – eine seltene differenzialdiagnose des Nebennierentumors. *Chirurg* 2003; 3: 248-252.
23. Song-Qing F, Yi J, Duo L, et al. Adenomatoid tumor of the left adrenal gland with concurrent left nephrolithiasis and left kidney cyst. *Pathology* 2005; 37: 398-400.
24. Varkarakis IM, Mufarrij P, Studeman KD, et al. Adenomatoid tumor of the adrenal gland. *Urology* 2005; 65: 175.
25. Chung-Park M, Yang JT, McHenry C, et al. Adenomatoid tumor of the adrenal gland with micronodular adrenal cortical hyperplasia. *Hum Pathol* 2003; 34: 818-821.
26. Gasque CR, Marti-Bonmati L, Dosda R, et al. MR imaging of a case of adenomatoid tumor of the adrenal gland – case report. *Eur Radiol* 1999; 9: 552-554.
27. Denicol NT, Lemos FR, Koff WJ. Adenomatoid tumor of supra-renal gland – case report. *Internat Braz J Urol* 2004; 30: 313-315.
28. Timonera ER, Paiva ME, Lopes JM, et al. Composite adenomatoid tumor and myelolipoma of adrenal gland: report of 2 cases. *Arch Pathol Lab Med* 2008; 132: 265-268.
29. Simpson PR. Adenomatoid tumor of the adrenal gland. *Arch Pathol Lab Med* 1990; 114: 725-727.
30. Angeles-Angeles A, Reyes E, Munoz-Fernandez L, et al. Adenomatoid tumor of the right adrenal gland in patient with AIDS. *Endocr Pathol* 1997; 8: 59-64.
31. Mi-Jung K, Jae YR. A 33-year-old man with an incidentally found left adrenal mass during workup for hypertension – pathologic quiz case. *Arch Pathol Lab Med* 2003; 127: 1633-1634.

### Address for correspondence

**Magdalena Białas**  
Chair and Department of Pathomorphology  
Jagiellonian University Medical College  
ul. Grzegórzecka 16  
31-531 Kraków  
e-mail: mbialas7@gmail.com  
fax +48 12 411 97 25