

THE USE OF COMPUTER IMAGE ANALYSES IN THE ASSESSMENT OF CHOSEN HISTOCLINICAL FEATURES OF NEPHROBLASTOMA CELLS IN CHILDREN

JÓZEF KOBOS¹, PIOTR DEMBSKI¹, KATARZYNA TARAN²

¹Department of Pathology of the Age of Development, Konopnicka Memorial Hospital, Medical University of Łódź

²Department of Pathology, Medical University of Łódź

The goal of the research was to assess the nuclear morphometric discriminant function (MV_f) in the analyzed group of nephroblastomas and to evaluate its potential prognostic value. We found a statistically important correlation between the favourable histology of Wilms' tumours (according to SIOP 93-01 and SIOP 2001 classifications of kidney tumours of childhood) and low values of MV_f discriminant function, which was also associated with the best prognosis for the patients. We believe that MV_f assessment may be a helpful tool in making prognosis in doubtful cases of nephroblastomas in children.

Key words: morphometry, nephroblastoma, childhood, SIOP classifications.

Introduction

Wilms' tumour is one of the most common kidney tumours that affect children. It is usually diagnosed in patients up to 6 years old. It can grow to a large volume, sometimes it appears bilateral and it may be also partially cystic. Microscopically, Wilms' tumour contains different proportions of epithelial, blastemal and stromal components [1, 2].

The main histological classifications take into account morphology of the cells and their pattern of growth and divide Wilms' tumours into subgroups with different microscopic appearance and different prognosis.

SIOP 93-01 classification used in Poland until 2003 and introduced by SIOP (Societe Internationale D'Oncologie Pediatrique) divides kidney tumours into five groups: Wilms' tumours with a low grade of malignancy, Wilms' tumours with a medium grade of malignancy, Wilms' tumours with a high grade of malignancy, Wilms' tumours which cannot be classified and other tumours. The newest formula currently used in Poland, i.e. "The revised SIOP working classification of renal tumour of childhood" published in 2001, apart from morphology, takes also into consideration the fact of routine preoperative (so called

"inductive") chemotherapy used in the treatment of this tumour and divides kidney tumours according to their histology and prognosis for the patients [1-3].

A feature of Wilms' tumour morphology of extreme interest today that is widely discussed is the anaplasia of cell nuclei found in microscopic picture in 5% of examined cases. Microscopically, anaplasia is characterized by the presence of large differently shaped and hyperchromatic nuclei of tumour cells as well as by enormous mitotic figures. Two different types of anaplasia were described in the literature: focal and diffuse. The presence of the diffuse type indicates poor prognosis [4-6]. However, not only routine histological assessment of prognostic factors is currently done. At present, advanced technologies based on computer image analysis are used in microscopic examination of malignancies. Owing to them the results are more precise and allow to pose a definite diagnosis and prognosis for the patients.

In order to analyze the morphometry of the tumour cells, a method must be determined and all kinds of microscopic data must be collected with the inclusion of the so-called picture environment, which consists of reference structure, structures (objects), the selection method and the size of observation fields and other features that describe the analyzed

elements. It is also necessary to define the type of measurements. According to the literature, the value of MV_f function is a widely accepted morphometric parameter assessed in malignancies due to its correlation with the prognosis and the course of neoplastic disease [7].

Material and methods

51 formalin-fixed and paraffin-embedded nephroblastoma tissue sections from the files of the Department of Pathology of the Age of Development and Department of Pathology of Konopnicka Memorial Hospital Medical University of Łódź were selected for our study. From these tissue samples, paraffin blocks with a thickness of 3-4 μm were prepared and stained with haematoxylin and eosin (HE). For the purpose of our study, all of previously diagnosed tumours (SIOP 93-01) were reclassified according to current criteria for this group (SIOP Classification of Renal Tumours of Childhood 2001).

The surface area, perimeter, length, width, Feret H diameter (maximum Feret diameter), Feret V diameter (minimum Feret diameter) and the centre of gravity of the examined cells were measured and the nuclear morphometric discriminant function for each cell was calculated using the following formula:

$$MV_f = (0.02 \times AGE) + (1.17 \times SNRF) + (90.6 \times LEFD) - 94$$

AGE – age in months, SNRF – skewness counted using the standard shape coefficient: $SF = L^2 / (2 \times \pi \times S)$; where L represents the perimeter, S – the surface area, LEFD – quotient of Feret V diameter to Feret H diameter of the examined cells.

The findings were compared with the following histoclinical features: age, sex, the presence of tumour relapse or metastases and histological type of the tumour as specified by the SIOP 93-01 and SIOP 2001 classifications.

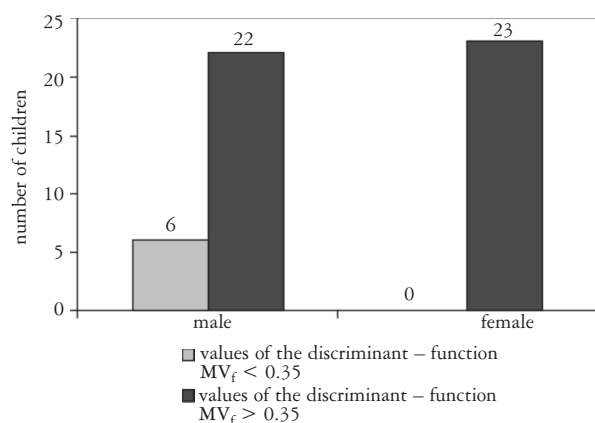


Fig. 1. Values of the average MV_f discriminant function in the examined group

Results

The youngest child was 7 days old, the oldest was 14 years old (the average: 45, standard deviation 32.62, median 48 months). The highest number of tumours were diagnosed among children aged up to 4 years of life.

The minimal value of MV_f discriminant function was -10.31 , the maximal 373.86 (the average: 46.38 , median 22.76 , standard deviation 74.57). In the examined group, the value of MV_f discriminant function lower than -0.35 was found in 6 cases (11.76%), exclusively among boys (Fig. 1). In the remaining 45 cases (88.24%), the MV_f discriminant function was higher than -0.35 .

The results of statistical analysis

There was a strong statistically significant correlation between the tumour type according to SIOP 93-01 classification and the value of MV_f discriminant function below -0.35 ($p = 0.000$). Table I presents average values of MV_f discriminant functions in relation to the tumour type according to SIOP 93-01 classification.

There were no statistically significant relationships between the tumour type according to SIOP 93-01 classification and age ($p = 0.090$), sex ($p = 0.435$) or the presence of relapse or metastases ($p = 0.062$).

The analysis of Wilms' tumours main groups (low grade, intermediate grade and high grade) according to SIOP 93-01 showed that a statistically significant correlation with MV_f value was absent but occurred as a result of the division into low grade Wilms' tumours and, jointly considered, intermediate and high grade Wilms' tumours ($p = 0.047$).

Statistically significant correlations were also observed between low grade and combined intermediate and high grade group and the MV_f value lower than -0.35 ($p = 0.000$) and age ($p = 0.039$). There was no correlation of such groups with sex ($p = 0.331$).

In the analysis of Wilms' tumour main types (low risk, intermediate risk and high risk) according to SIOP 2001 classification, a statistically significant correlation was found between the tumour type according to SIOP 2001 classification and age ($p = 0.017$), the presence of relapse or metastases ($p = 0.006$) and the value of MV_f discriminant lower than -0.35 ($p = 0.001$). Table II presents average values of discriminant functions in relation to the tumour type according to SIOP 2001 classification.

There were no statistically significant relations between main tumour types and MV_f value or sex. Similarly as in the case of SIOP 93-01 classification, a statistically significant correlation with MV_f value occurred as an effect of the differentiation of low risk tumours from jointly analyzed intermediate and

Table I. Values of average MV_f discriminant function in relation to SIOP 93-01 classification

HISTOLOGICAL TUMOUR TYPE ACCORDING TO SIOP 93-01 CLASSIFICATION	VALUES OF AVERAGE MV_f DISCRIMINANT FUNCTION
low grade	-4.344
intermediate grade	47.212
high grade	57.318

Table II. Values of average MV_f discriminant function in relation to SIOP 2001 classification

HISTOLOGICAL TUMOUR TYPE ACCORDING TO SIOP 2001	VALUES OF MV_f DISCRIMINANT FUNCTION
low risk	-1.481
intermediate risk	46.353
high risk	82.568

Table III. Results of MV_f discriminant function statistical analysis

FEATURE I	FEATURE II	P
MV_f discriminant function	histological tumour type according to SIOP 93-01	>0.5
	histological tumour type according to SIOP 93-01 after division into low grade and intermediate taken together with high grade tumours	0.047
	histological tumour type according to SIOP 2001	>0.5
	after division into low risk and intermediate taken together with high risk tumours	0.034

high risk entities ($p = 0.034$). Nephroblastomas classified as either low risk or a combined group of intermediate and high risk showed statistically significant differences with respect to the value of MV_f discriminant function lower than -0.35 ($p = 0.000$) as was the case with the SIOP 93-01 classification. Table III presents statistical correlations of MV_f discriminant function.

Discussion

Tumours affecting children after the first year of life are the main cause of death after intoxication and accidents. In some cases, it is possible to start treatment basing on clinical, radiological and biochemical examinations with the assessment of appropriate blood and urine markers. However, for the final diagnosis and best results for the patients, the histological examination of a tumour tissue sample must be carried out. During the microscopic analysis of children malignancies, immunohistochemical exami-

nations with the use of monoclonal antibodies and molecular techniques are used [1, 2, 8].

In Poland, nephroblastoma is the most frequently diagnosed solid tumour that affects children. In accordance with the decisions of SIOP group, this kind of tumour is diagnosed on the basis of the clinical picture, radiological examinations and lab tests without the need of histological analysis before preoperative chemotherapy. When the chemotherapy is finished, the kidney with the tumour is surgically removed and at the time of microscopic examination of the postsurgical specimen, prognostic factors are sought. Currently, the most important markers of prognosis for the patients with nephroblastoma are the stage of disease and histological type. Histology indicates also the best treatment. Children with intermediate- or high-risk tumours need further chemotherapy and/or radiotherapy [1, 2, 8]. However, sometimes the biology of malignancies found in children appears to be unpredictable and there is still the need for new prognostic markers for this group [9-11].

One of the assessed factors with a potential prognostic value described in literature is the MV_f discriminant function. It was proved that the values of $MV_f \geq -0.35$ were associated with unfavourable prognosis and high values of MV_f discriminant function were connected with relapse or metastases. The assessment of MV_f discriminant function does not allow for the exact prognostics of the time free from the disease or survival among patients with nephroblastoma. However, what is very important, the study results showed that the morphometry of Wilms' tumour may be significant as far as the decisions about further treatment are concerned. That diagnostic tool makes it possible to select a group of children affected by nephroblastoma with a low value of MV_f discriminant function and with a low degree of clinical advancement and therefore with favourable prognosis [11-14]. In our research we did not find statistically significant correlations between the value of MV_f discriminant function and the histological main Wilms' tumour types assessed in accordance with SIOP 93-01 and SIOP 2001 classifications. Statistically significant correlations between the value of MV_f discriminant function and histological type occurred only after the division of examined nephroblastomas into low grade (or risk) tumours and, jointly considered, intermediate and high grade (or risk) Wilms' tumours.

Our research allowed us to presume that the use of morphometry is an effective way of selecting nephroblastomas with the lowest values of MV_f discriminant function that is associated with a low histological risk and the best prognosis for the patients. In such cases, postoperative chemotherapy is not required and only a long observation period is in place. Apart from the analysis of widely used prognostic factors for Wilms' tumours, the assessment of MV_f discriminant function may be an additional tool useful in doubtful cases.

References

1. Taran K, Kobos J, Sporny S. Examination of expression of WT1 Gene Product and CD44 Adhesive Molecule in Nephroblastoma Histologic Types. *Pol J Pathol* 2008; 59: 177-182.
2. Beckwith JB. Wilms' tumors and other renal tumors of childhood. In: Finegold, M, ed. *Major Problems in Pathology: vol. 18. Pathology of Neoplasia I Children and Adolescents*. WB Saunders, Philadelphia 1986; 313-332
3. Beckwith JB. Renal neoplasms of childhood. In: Sternberg, SS (ed.). *Diagnostic Surgical Pathology*. Raven Press, New York 1989; 1331-1353.
4. Faria P, Beckwith JB, Mishra K, et al. Focal versus diffuse anaplasia in Wilms tumor – new definitions with prognostic significance. A report from the National Wilms Tumor Study Group. *Am Surg Pathol* 1996; 20: 909-920.
5. Alvarez-Silvan AM, Bavian Carrasco F, Pineda Cuevas G: Preservation of anaplastic features in Wilms tumors after preoperative chemotherapy. *Med Pediatr Oncol* 1989; 17: 131-133.
6. Beckwith JB, Palmer NF. Histopathology and prognosis of Wilms tumor. Results from the first National Wilms Tumor Study. *Cancer* 1978; 41: 1937-1948.
7. Breslaw N, Partin AW, Lee BR, Guthrie KA, Beckwith JB, Green DM: Nuclear Morphometry and Prognosis in Favorable Histology Wilms' Tumor: A Prospective Reevaluation. *J Clin Oncol* 1999; 17: 2123-2126.
8. O'Leary M, Krailo M, Anderson J, Reaman GH. *Progress in Childhood Cancer: 50 Years of Research Collaboration, A Report from the Children's Oncology Group*. *Semin Oncol* 2008; 35: 484-493.
9. Taran K, Kobos J, Sporny S. Number of mitotic figures in microscopic picture of nephroblastoma histologic types – estimation of the value of the oldest known prognostic factor. *Pol J Pathol* 2008; 59: 43-47.
10. Niedzielski J, Becht R, Taran K. Should a poorly differentiated epithelial feature of Wilms' tumor be considered an unfavourable prognostic factor? *Pol J Urol* 2006; 60: 74-78.
11. Taran K, Kobos J, Sitkiewicz A, Sporny S. Estimation of prognostic value of CD44 expression in neuroblastic tumors in children. *Folia Neuropathologica* 2007; 45: 126-132.
12. Partin AW, Yoo JK, Crooks D. Prediction of disease – free survival after therapy in Wilms' tumor using nuclear morphometric techniques. *J Pediatr Surg* 1994; 29: 456-460.
13. Mohler JL, Partin AW, Lohr WD. Nuclear roundness factor measurement for assessment of prognosis of patients with prostatic carcinoma. I. Testing of a digitization system. *J Urol* 1988; 139: 1080-1084.
14. Gearhart JP, Partin AW, Leventhal BG. The use of nuclear morphometry to predict response to therapy in Wilms' tumor. *Cancer* 1992; 69: 806-808.

Address for correspondence

Katarzyna Taran MD, PhD
 Department of Pathology Medical University of Łódź
 ul. Pomorska 251
 92-213 Łódź
 e-mail: dr.taran.patho@gmail.com