

MAST CELLS IN MELANOCYTIC SKIN LESIONS. AN IMMUNOHISTOCHEMICAL AND QUANTITATIVE STUDY

GRZEGORZ DYDUCH¹, KRZYSZTOF OKOŃ¹, ELENA PESCARINI^{1,2}

¹Department of Pathomorphology, Jagiellonian University Medical College, Krakow, Poland

²Universita degli Studi di Padova, Dipartimento di Specialità Medico-Chirurgiche, Sezione di Chirurgia Plastica, Padua, Italy

The mast cells participate in inflammation and possibly in carcinogenesis. The aim of the study was to study mast cells in melanocytic lesions. The material consisted of 24 pigmented nevi, 18 dysplastic nevi and 19 melanomas. The sections were stained immunohistochemically for tryptase and chymase. Positive cells were counted inside the lesions and at the interface between the lesion and dermis.

The mean intralesional tryptase+ count was 15.75 for nevi, 21.78 for dysplastic nevi, and 8.07 for melanomas. The chymase+ intralesional count was 14.89 for nevi, 21.88 for dysplastic nevi, and 11.34 for melanomas. The tryptase+ perilesional count was 16.89 for nevi, 15.93 for dysplastic nevi, and 15.71 for melanomas. The chymase+ perilesional count was 16.52 for nevi, 16.16 for dysplastic nevi, and 14.77 for melanomas. The tryptase/chymase intralesional ratio was 0.93 for nevi, 1.05 for dysplastic nevi, and 1.67 for melanomas. The tryptase/chymase perilesional ratio was 1.02 for nevi, 1.09 for dysplastic nevi, and 1.00 for melanomas. The differences between intralesional mast cells, both tryptase+ and chymase+, were statistically significant. The intralesional tryptase+ count showed an inverse correlation to age ($R = -0.42$); this correlation was the strongest in melanomas.

The results obtained in our study suggest a possible correlation between mast cells and the pathogenesis of cutaneous melanoma.

Key words: chymase, mast cells, melanoma, pigmented nevus, tryptase.

Introduction

Melanocytic nevi of the skin are fairly common. The details of the transition from a common nevus to a dysplastic nevus and ultimately to a melanoma are intensively studied, but remain incompletely understood. In cancer pathology and therapy there is an increasing interest in the interactions between the cancer cells themselves and their environment, including the connective tissue stroma, the newly forming vessels and inflammatory elements. In particular, the relationship between inflammatory process and cancer is complex and only partially understood. It has been theorized that inflammation may be the source of growth factors for the cancer, and that cancer growth itself is controlled

by immunologic and inflammatory mechanisms. Chronic inflammatory mechanisms are also responsible for neoangiogenesis required for the continuous growth of cancer. One of the cells known to actively participate in the chronic inflammatory process, yet not extensively studied, is the mast cell. The paucity of information may be due to the difficulty of visualizing mast cells in the tissue sections by routine stain or due to the ability of the mast cells to imitate other connective tissue or inflammatory cells. Generally, at least two different populations of mast cells were described; one expressing both chymase and tryptase, and the other with sole tryptase expression. In different body sites, mast cell populations are differently represented, and they may differ in their functions [1-5].

The aim of the study was to compare the representation of chymase- and tryptase-positive mast cells in melanocytic lesions of the skin and in their immediate proximity.

Material and methods

All the cases were obtained from the files of the Department of Pathomorphology. The material was fixed in buffered formalin, processed by the routine method and embedded in paraffin. Four μm sections were cut from the paraffin blocks. Primary anti-tryptase antibody (clone AA1, Novocastra, UK) at 1 : 100 dilution and anti-chymase antibody (clone CC1, Abcam, UK) at 1 : 100 dilution were used. Antigen retrieval was carried out by microwaving in citrate buffer (pH 6.0) for 5 min at 700 W, then for 5 minutes at 600 W for chymase stain and by trypsin digestion (30 min at 37°C) for tryptase stain. The EN-VISION + System kit (DAKO, Denmark) detection system was used. 3-amino-9-ethylcarbazole (DAKO, Denmark) was used as chromogen. The immunostained slides were examined under Optech microscope (Optech Microscope Services Limited, UK) equipped with a 40 \times lens (field of vision diameter: 0.45 mm). For each stain, two separate counts were performed. For the intralesional count, the entire area of the melanocytic lesion was scanned, and the immunopositive cells as well as the number of fields were recorded. For the perilesional count, only the fields of view along the interface between the lesion and its neighbourhood were chosen, and then the number of positive cells and fields were recorded. The results were expressed as the average number of positive cells per high power field. The statistical analysis was performed using Statistica 9.0 (StatSoft Inc, USA). The Kruskal-Wallis ANOVA with multiple post-hoc comparison tests, the Mann-Whitney U test, and the Spearman correlation coefficient were used. The significance level was set as $p = 0.05$.

Results

The material included 61 skin biopsies from 54 patients, and consisted of 24 common pigmented nevi, 18 dysplastic nevi and 19 melanomas. The female/male ratio was 25 to 29, and the mean age was 41.1 (range 11 to 86, SD 20.25).

In the common pigmented nevus group, the female/male ratio was 11 to 10, and the mean age was 26.62 (range 11 to 65, SD 13.89); in the dysplastic nevus group the female/male ratio was 6 to 8, and the mean age was 36.29 (range 20 to 63, SD 13.84); in the melanoma group the female/male ratio was 19 to 11, and the mean age was 60.68 (range 41 to 86, SD 13.66).

Most of the melanomas were of the nodular melanoma type (15, i.e. 78.9%), two cases were superficial spreading melanomas and single cases included spitzoid melanoma and a melanoma originating from the melanocytic nevus. The average infiltrate thickness according to Breslow was 2.78 mm (range 0.60 to 7 mm, SD 1.97). The average number of mitotic figures was 15.68 per mm^2 (range 1.00 to 50, SD 15.47).

The counts of mast cells are shown in Table I and Fig. 2. According to Kruskal-Wallis ANOVA test, there were significant differences between groups in the intralesional mast cell counts. For tryptase-positive cells (Kruskal-Wallis $H = 20.86$, $p < 0.01$), the post-hoc multiple comparison test showed variations that were due to the difference between the melanomas and both the common pigmented and dysplastic nevi. For chymase-positive cells (Kruskal-Wallis $H = 8.90$, $p < 0.012$), the post-hoc multiple comparison test showed variation due entirely to the difference between melanomas and dysplastic nevi. Slight differences were also seen in the intralesional chymase / tryptase ratio, but these did not reach statistical significance (Kruskal-Wallis $H = 4.83$, $p > 0.09$). Differences in perilesional mast cell counts were not statistically significant (tryptase-positive cells Kruskal-Wallis $H = 0.84$, $p > 0.65$, chymase-positive cells Kruskal-

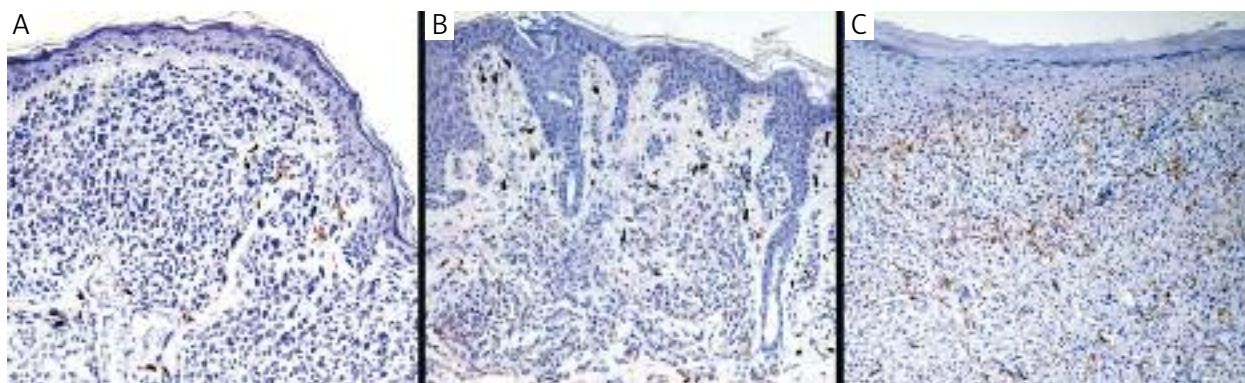


Fig. 1. Mast cells in melanocytic nevi and melanomas. A – common pigmented nevus, B – dysplastic nevus, C – melanoma. Immunohistochemistry for tryptase, original magnification 400 \times

Table I. Values of the mast cell counts

	TRYPTASE INTRALESIONAL		CHYMASE INTRALESIONAL		TRYPTASE PERILESIONAL		CHYMASE PERILESIONAL		TRYPTASE/ CHYMASE INTRALESIONAL		TRYPTASE/ CHYMASE PERILESIONAL	
	MEAN	(SD)	MEAN	(SD)	MEAN	(SD)	MEAN	(SD)	MEAN	(SD)	MEAN	(SD)
Pigmented nevi	15.75	(9.01)	14.89	(9.37)	16.89	(7.59)	16.52	(7.33)	0.93	(0.26)	1.02	(0.21)
Dysplastic nevi	21.78	(10.80)	21.88	(14.44)	15.93	(8.30)	16.16	(5.59)	1.05	(0.43)	1.09	(0.31)
Melanomas	8.07	(5.53)	11.34	(8.25)	15.71	(7.35)	14.77	(6.64)	1.67	(1.51)	1.00	(0.31)
All cases	14.90	(10.04)	15.66	(11.29)	16.24	(7.62)	15.87	(6.58)	1.21	(0.95)	1.03	(0.27)

SD – standard deviation of mean

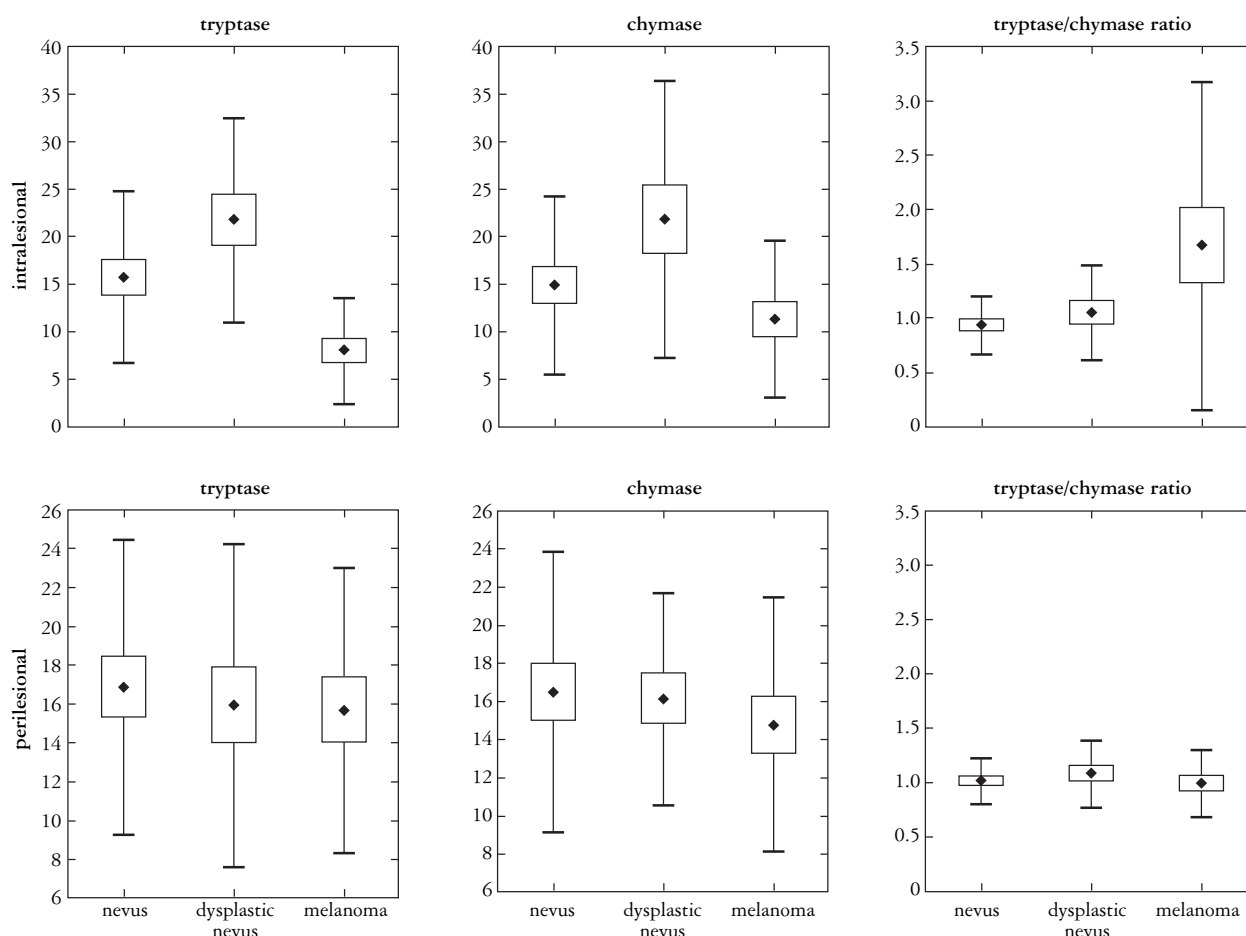


Fig. 2. The number of immunopositive cells in the melanocytic lesions under study. Tryptase-positive cells on the left, chymase-positive in the centre, and tryptase-chymase count ratio on the right. Upper row – intralésional mast cells; lower row – perilesional mast cells. Central point is the arithmetic mean, box is the arithmetic mean ± standard error of mean, whisker is the arithmetic mean ± standard deviation of mean

Wallis $H = 1.75$, $p > 0.40$), and the chymase / tryptase ratio ($H = 0.86$, $p > 0.64$). The intralésional tryptase-positive cell counts showed a significant, inverse correlation to patients' age ($R = -0.42$, $p < 0.002$); this correlation was the strongest in the melanoma group ($R = -0.47$, $p < 0.05$), but was weaker and not sig-

nificant in both common and dysplastic nevi. It is worth noting that the age-mast cell count correlation was positive in common nevi ($R = 0.17$), but negative in dysplastic nevi ($R = -0.30$), like in melanomas. There were no differences in mast cell counts related to the sex of the patients.

Discussion

Mast cells are difficult to visualize on routine stains, and they may be easily mistaken for other inflammatory cells. As a consequence, a variety of special stains is used; the classical one is the toluidine blue stain; however, histochemical stains may be technically tricky and difficult to interpret. Immunohistochemistry for CD117 or tryptase is thought to mark all the mast cells both specifically and sensitively, and may be used for assessing their total number. However, chymase, another mast-cell specific proteinase, is detected in a subset of mast cells only. Therefore, two separate populations of mast cells may be recognized, tryptase positive and tryptase-chymase positive. The function of chymase is particularly important in circulatory and renal disease. It is also important in arterial hypertension as it is able to function as an alternative convertase in the renin-angiotensin axis [1, 3, 4]. The mast cells are well known to participate in the inflammatory process, especially if an allergic component is present. The proinflammatory function of the mast cell may depend on different mediators, including tryptase itself, as well as chymase, histamine and several cytokines [6]. The relationship between inflammation, mast cells and cancer might be quite complicated, featuring both promotion and inhibition of the tumour growth. Pro-neoplastic stimuli include the following: the promotion of neoangiogenesis, the promotion of tumour growth by the factors released by the mast cell, the production of the proteases facilitating migration of tumour cells and immunosuppression. The anti-neoplastic actions might include direct inhibition of cell growth, increased inflammatory anti-tumour reaction, induction of apoptosis and decreased cell mobility. The opposite effects of the same mast cell might depend on its ability to degranulate or secrete specific mediators in response to a variance of stimuli. Mast cells might also be able to recruit both M1 and M2 macrophages, which are well known to have opposite effects on tumour growth. Another important factor is the heterogeneity of the mast cells, especially the presence of both chymase-positive and chymase-negative cells; these may differ in their products and also in response to stimuli [7]. The participation of the mast cells in both the progression of cancer and in neoangiogenesis has been shown in several cancer types; specifically pulmonary carcinoma [8], colorectal carcinoma [9, 10], neurofibromas [11] and various skin tumours including melanocytic nevi and melanomas [11-16]. Proangiogenic action of mast cells might be mediated by secretion of VEGF, angiopoietin, bFGF, TGF- β , TNF- α and IL-8 [17-19]. Tryptase also has proangiogenic action with its ability to degrade connective tissue matrix and ability to activate PAR-2 receptors expressed on endothelial cells [10, 20]. Chymase was also shown to be pro-angiogenic [21]. The mast cells were implicated in increased vascular per-

meability and connective matrix remodelling; these functions may influence cancer progression and metastatic spread. Of particular interest is that mastocytes may directly influence growth of the cancer cells [6, 9, 13, 14, 20]. Yoshii *et al.* showed that tryptase may be responsible for stimulation of cancer growth, specifically through the protease activated receptor (PAR-2), MAP kinase activation and prostaglandin E2 release [10]. Since the PAR-2 receptor is expressed by nevi and melanomas [22], an analogous mechanism could be operating in melanocytic lesions; however, the subject requires further studies. With the pleiotropic effects the clinical significance of tumour-related mast cells remains only partially understood. The issue is further complicated by the existence of both intratumoral and peritumoral mast cells with possibly divergent significance. Most studies suggest that peritumoral mast cells are more numerous than intratumoral; it was also observed that intratumoral mastocytes contain less granules; this might indicate a more extensive secretion [8-10]. Carlini *et al.* showed that patients with the non small cell pulmonary carcinoma and a high chymase-positive mast cell count inside the tumours had higher vascular density. It was also shown that the patients with a higher peritumoral mast cell count had a higher chance of survival [8]. Mauro *et al.* performed a similar analysis of colorectal carcinoma. They reported a correlation between the mast cell count and vascular density, and a higher survival rate for patients with a lower mast cell count at the tumoral/stromal interface [9]. Ribatti *et al.* [23] found the density of mast cells to parallel microvessel density in progression of gastric carcinoma. This relationship was seen for both chymase and tryptase. In addition to the clinical significance of mast cells, their participation in the process of carcinogenesis is of particular interest; however, this topic is not well explored. Mast cells may promote the growth of cancer cells directly (*vide supra*). Mast cells have also been shown to regulate proliferation of blood vessels and to participate in induction of angiogenic switch, necessary for a fully malignant phenotype. Wilk *et al.* [24] have seen a stepwise increase of tryptase-positive and chymase-positive mast cells from normal mucosa, to cervical intraepithelial neoplasia, and ultimately to invasive cervical carcinoma. A similar progression of mast cell numbers was described for oral dysplasia and cancer [25]. In addition, the mast cells were also shown to participate in the progression of cutaneous tumours.

In normal skin, there are always a certain number of mast cells present; these are predominantly of the tryptase/chymase type. Mast cells can contribute to the tumorigenesis of cutaneous malignancies through different mechanisms. These mechanisms include participation in immunosuppression, the release of proangiogenic and mitogenic factors and involvement in the degradation of the extracellular matrix [12]. Both

tryptase and chymase can be involved in the growth of some skin tumours, however, in the skin, chymase is partially inactivated, due to effective inhibitors such as α 1-antichymotrypsin or α 1-protease inhibitor [13]. Mast cells accumulate at the periphery of or within cutaneous neoplasms. Mast cells are recruited and activated by microenvironmental factors, tumour cells or UVB radiation. It is hypothesized that a higher, genetically predetermined density of dermal mast cell predisposes to UVB induced immunosuppression. Patients with basal cell carcinomas and melanomas share an increased dermal mast cell prevalence in non-sun exposed buttock skin [15, 16]. Increased mast cell counts were reported in more aggressive variants of both basal cell carcinoma and squamous cell carcinoma. This effect seemed to be independent of the presence of an inflammatory infiltrate [12].

Evidence supports the mainly tumorigenic action of mast cells in the development of cutaneous cancers; however, their anticancer effects have also been documented. Some mediators released by mast cells show an inhibitory effect on tumour growth and angiogenesis, specifically TNF- α , IL-1 and IL-6 have been reported to suppress melanoma growth. Additionally, phenotype and secretory patterns of mast cells can be altered by microenvironmental factors, which results in the release of specific mediators. For example, low pH promotes IL-4 and IL-6 production without concomitant histamine release. Some mediators that have well-established proangiogenic functions may paradoxically inhibit progression of the tumour. It is postulated that histamine can increase prostacyclin synthesis by endothelial cells and prostacyclin is a potent antimetastatic factor [12]. Some studies have shown the direct tumour cytotoxicity of mast cells. Activation of TLR2 on mast cells and subsequent release of IL-6 results in the inhibition of tumour growth both *in vitro* and *in vivo*. Recruitment of NK cells and CD3+ T cells by mast cells has also been observed [26].

The presence of mast cells within melanocytic lesions is a well-documented phenomenon. Although the hypothesis that mast cells would represent a transitional phase in the differentiation of melanocytes has not been widely accepted, both types of cells share some developmental features. C-kit (CD117) and its ligand SCF seem to be crucial for the maturation, survival and migration of both melanocytes and mast cells [14]. At least two cases of combined mastocytoma-pigmented nevus have been reported. The mast cells are observed in typical melanocytic nevi, dysplastic nevi, in situ melanomas and in invasive melanomas. Nevertheless, the clinical significance of the mast cells and their role in the development and progression of melanocytic tumours remains controversial [27].

Statistically significant differences in the number of perilesional mast cells were found between nevi and melanomas. In several studies the increase in mast cell

counts reflected the postulated steps in the progression of melanocytic tumours. This progression involves the transformation of a common nevus to a dysplastic nevus, then further progression into an in situ melanoma and finally into an invasive melanoma. The lowest mast cell count was found in the common nevi, an intermediate value was seen in the dysplastic nevi and highest numbers of mast cells were seen in melanomas [14, 28, 29]. It was postulated that the mast cells accumulate around melanomas and promote their growth, specifically by the release of proangiogenic factors. In fact, peritumoral mast cell counts correlate strongly with microvessel density, presence of the metastases and prognosis [14, 17, 28, 30]. Melanoma cells may attract mast cells by producing mast cell chemotactic/mitogenic factors such as IL-3 or FGF-2. The recruitment of mast cells, and subsequent release of heparin, bFGF, histamine, or TNF- α favours tumour progression, featuring a self-perpetuating regulatory loop [28, 31].

In our study the perilesional mast cell density was the lowest in the melanoma group, but the differences between groups were not significant. This discrepancy between our results and other studies can be partly explained by the different methodologies applied or different number of cases examined. Some authors visualize mast cells by toluidine blue stain, some counted them over a limited area [17, 28-30], while other studies counted the volume of the tissue occupied by mast cells, and not the specific number of these cells [14]. Our study counted the chymase- and tryptase-positive cells in all available fields of view and then calculated the numbers per unit area, which, in our opinion, gives more reliable data. Conversely, our findings may constitute a real phenomenon. The melanomas in our series were relatively large tumours, with the average infiltrate thickness of 2.78 mm. It is conceivable that at some point of tumour development its cells become self-sufficient regarding angiogenesis, without the necessity for further contribution of mast cells. Further studies are required to clarify this issue.

Our results also reflected significant differences between groups in the intralesional mast cell counts. To our knowledge, there are no reports analyzing the role of intratumoral mast cells in melanocytic tumours. The lowest mast cell count was observed in the melanoma group, both for chymase- and tryptase-positive cells. We believe that there are two possible explanations for these results. Assuming that mast cells favour tumour growth, the increasing density of intratumoral mast cells along the postulated nevus-dysplastic nevus axis would suggest their role at the early stages of melanocytic carcinogenesis. This increasing density of mast cells is then followed by a subsequent decrease after emergence of a fully malignant phenotype. Since angiogenesis is most pronounced at the interface between the tumour and the stroma, intratumoral mast

cells are likely to act by another, non-angiogenic mechanism. An alternative explanation might be that the increasing mast cell counts from common nevi to dysplastic nevi could be a sign of the host response against tumour transformation into malignancy. Lower mast cell counts in cancer might reflect the overcoming of host defences, therefore allowing cancer growth. Alternatively, lesions with low immune reaction (featuring low mast cell counts) will be able to evolve into a fully malignant phenotype, whereas the ones promoting strong reaction (with a high mast cells count) may remain stable.

Our results also showed an inverse correlation between intratumoral mast cells and age; this relationship was particularly strong in the melanoma group. This finding along with the fact that the advanced age is associated with defects in all cells of the innate immune system, including the decrease in number of mast cells in the skin, may further support the idea of mast cells as an element of immune surveillance [32].

We believe that further studies are needed to elucidate the role of mast cells in melanocytic lesions.

References

1. Beil WJ, Pammer J. In situ detection of the mast cell proteases chymase and tryptase in human lung tissue using light and electron microscopy. *Histochem Cell Biol* 2001; 116: 483-493.
2. Buckley MG, Gallagher PJ, Walls AF. Mast cell subpopulations in the synovial tissue of patients with osteoarthritis: selective increase in numbers of tryptase-positive, chymase-negative mast cells. *J Pathol* 1998; 186: 67-74.
3. Buckley MG, McEuen AR, Walls AF. The detection of mast cell subpopulations in formalin-fixed human tissues using a new monoclonal antibody specific for chymase. *J Pathol* 1999; 189: 138-143.
4. Okon K, Stachura J. Increased mast cell density in renal interstitium is correlated with relative interstitial volume, serum creatinine and urea especially in diabetic nephropathy but also in primary glomerulonephritis. *Pol J Pathol* 2007; 58: 193-197.
5. Schwartz LB. Analysis of MC(T) and MC(TC) mast cells in tissue. *Methods Mol Biol* 2006; 315: 53-62.
6. He S, Peng Q, Walls AF. Potent induction of a neutrophil and eosinophil-rich infiltrate in vivo by human mast cell tryptase: selective enhancement of eosinophil recruitment by histamine. *J Immunol* 1997; 159: 6216-6225.
7. Theoharides TC, Conti P. Mast cells: the Jekyll and Hyde of tumor growth. *Trends Immunol* 2004; 25: 235-241.
8. Carlini MJ, Dalurzo MC, Lastiri JM, et al. Mast cell phenotypes and microvessels in non-small cell lung cancer and its prognostic significance. *Hum Pathol* 2010; 41: 697-705.
9. Mauro LV, Bellido M, Morandi A, et al. Association between mast cells of different phenotypes and angiogenesis in colorectal cancer. *Mol Med Report* 2008; 1: 895-902.
10. Yoshii M, Jikuhara A, Mori S, et al. Mast cell tryptase stimulates DLD-1 carcinoma through prostaglandin- and MAP kinase-dependent manners. *J Pharmacol Sci* 2005; 98: 450-458.
11. Carr NJ, Warren AY. Mast cell numbers in melanocytic naevi and cutaneous neurofibromas. *J Clin Pathol* 1993; 46: 86-87.
12. Ch'ng S, Wallis RA, Yuan L, et al. Mast cells and cutaneous malignancies. *Mod Pathol* 2006; 19: 149-159.
13. Diaconu N-C, Kaminska R, Naukkarinen A, et al. The increase in tryptase- and chymase-positive mast cells is associated with partial inactivation of chymase and increase in protease inhibitors in basal cell carcinoma. *J Eur Acad Dermatol Venereol* 2007; 21: 908-915.
14. Duncan LM, Richards LA, Mihm MC Jr. Increased mast cell density in invasive melanoma. *J Cutan Pathol* 1998; 25: 11-15.
15. Grimbaldston MA, Pearce AL, Robertson BO, et al. Association between melanoma and dermal mast cell prevalence in sun-unexposed skin. *Br J Dermatol* 2004; 150: 895-903.
16. Hart PH, Grimbaldston MA, Finlay-Jones JJ. Sunlight, immunosuppression and skin cancer: role of histamine and mast cells. *Clin Exp Pharmacol Physiol* 2001; 28: 1-8.
17. Tóth-Jakatics R, Jimi S, Takebayashi S, Kawamoto N. Cutaneous malignant melanoma: correlation between neovascularization and peritumor accumulation of mast cells overexpressing vascular endothelial growth factor. *Hum Pathol* 2000; 31: 955-960.
18. Feoktistov I, Ryzhov S, Goldstein AE, Biaggioni. Mast cell-mediated stimulation of angiogenesis: cooperative interaction between A2B and A3 adenosine receptors. *Circ Res* 2003; 92: 485-492.
19. Norrby K. Mast cells and angiogenesis. *APMIS* 2002; 110: 355-371.
20. Blair RJ, Meng H, Marchese MJ, et al. Human mast cells stimulate vascular tube formation. Tryptase is a novel, potent angiogenic factor. *J Clin Invest* 1997; 99: 2691-2700.
21. Muramatsu M, Katada J, Hattori M, et al. Chymase mediates mast cell-induced angiogenesis in hamster sponge granulomas. *Eur J Pharmacol* 2000; 402: 181-191.
22. Massi D, Naldini A, Ardinghi C, et al. Expression of protease-activated receptors 1 and 2 in melanocytic nevi and malignant melanoma. *Hum Pathol* 2005; 36: 676-685.
23. Ribatti D, Guidolin D, Marzullo A, et al. Mast cells and angiogenesis in gastric carcinoma. *Int J Exp Pathol* 2010; 91: 350-356.
24. Wilk M, Liszka L, Palen P, et al. Intensity of angiogenesis and mast cell infiltration in cervical intraepithelial and invasive lesions – are they correlated? *Pathol Res Pract* 2010; 206: 217-222.
25. Mohtasham N, Babakoochi S, Salehinejad J, et al. Mast cell density and angiogenesis in oral dysplastic epithelium and low- and high-grade oral squamous cell carcinoma. *Acta Odontol Scand* 2010; 68: 300-304.
26. Oldford SA, Haidl ID, Mackenzie HA, et al. A critical role for mast cells and mast cell-derived IL-6 in TLR2-mediated inhibition of tumor growth. *J Immunol* 2010; 185: 7067-7076.
27. Northcutt AD, Tschen JA. Combined mastocytoma-junctional nevus. *Am J Dermatopathol* 2004; 26: 478-481.
28. Ribatti D, Vacca A, Ria R, et al. Neovascularisation, expression of fibroblast growth factor-2, and mast cells with tryptase activity increase simultaneously with pathological progression in human malignant melanoma. *Eur J Cancer* 2003; 39: 666-674.
29. Schadendorf D, Kohlms C, Gawlik C, et al. Mast cells in melanocytic tumours. *Arch Dermatol Res* 1995; 287: 452-456.
30. Ribatti D, Ennas MG, Vacca A, et al. Tumor vascularity and tryptase-positive mast cells correlate with a poor prognosis in melanoma. *Eur J Clin Invest* 2003; 33: 420-425.
31. Reed JA, McNutt NS, Bogdany JK, Albino AP. Expression of the mast cell growth factor interleukin-3 in melanocytic lesions correlates with an increased number of mast cells in the perilesional stroma: implications for melanoma progression. *J Cutan Pathol* 1996; 23: 495-505.
32. Montagna W, Carlisle K. Structural changes in ageing skin. *Br J Dermatol* 1990; 122 Suppl 35: 61-70.

Address for correspondence

Grzegorz Dyduch
Department of Pathomorphology
Jagiellonian University Medical College
ul. Grzegórzecka 16
31-531 Kraków
Poland
e-mail: grzegorzdyduch@gmail.com