

ADRENAL MYELOLIPOMAS COMPOSED WITH ADRENAL NODULAR HYPERPLASIA IN THE SAME GLAND

ANNA BABINSKA¹, ADAM NALECZ², RENATA SWIATKOWSKA-STODULSKA¹, KRZYSZTOF SWORCZAK¹

¹Department of Endocrinology and Internal Medicine, Medical University of Gdansk, Poland

²Department of Pathology, Medical University of Gdansk, Poland

Adrenal myelolipoma is a benign neoplasm composed of an admixture of hemopoietic elements and mature adipose tissue. The incidence of adrenal myelolipoma is reported as between 4% and 5% of adrenal incidentaloma. The association of an adrenal myelolipoma and adrenal nodular hyperplasia or adrenal adenoma is rare. Four cases of adrenal myelolipomas in the material of 702 incidentally discovered adrenal lesions treated in our center are presented in this paper (in a group of 294 operated patients). Two myelolipomas have been reported as isolated adrenal masses and two – in association with adrenocortical nodular hyperplasia.

Key words: adrenal myelolipomas, adrenal nodular hyperplasia, adrenalectomy.

Introduction

Adrenal myelolipoma is a benign tumor, like a lesion composed of an admixture of hemopoietic elements and mature adipose tissue, similar to those seen in the bone marrow. Fewer than 200 cases of adrenal myelolipomas have been reported in the world literature [1].

Adrenal myelolipomas account for about 4% of adrenal incidentalomas [2-5]. Male to female ratio is 1 : 1 [4, 5]. They are usually unilateral but may be bilateral and may also develop in extraadrenal sites like retroperitoneum, thorax and pelvis [5].

To the best of our knowledge, only few cases of myelolipomas mixed with other adrenal or medullary lesions have been reported [6-9]. Myelolipomas have been reported, with or without hormonal activity, as isolated adrenal masses or in association with other adrenal disorders [8, 9]. Adrenal myelolipomas are mainly asymptomatic, only large lesions manifest as abdominal discomfort, bleeding or symptoms of pressing adjacent organs [4, 5, 10, 11].

We present four incidentally found adrenal myelolipomas. Two of them are isolated, asymptomatic, hormonally inactive adrenal myelolipomas, larger than 4 cm, and two cases are combined adrenal myelolipomas and adrenocortical nodular hyperplasia

in the same adrenal gland. One of the mixed adrenocortical hyperplasias containing myelolipoma presented hormonal activity. The diagnosis was established by microscopic examination of the specimen.

Case reports

Case 1

A 40-year-old previously healthy woman was admitted to our hospital because of an incidentally found right adrenal mass. She presented abdominal pain of few months' duration. The computed tomography (CT) scan revealed a right adrenal mass measuring 41 mm × 39 mm × 18 mm. It was described as a large, heterogeneous mass. There were also focal areas with calcification.

The clinical history and laboratory results demonstrated no evidence suggesting that the patient had a metabolic disorder commonly associated with adrenal tumor like hypercortisolism or catecholamine hypersecretion (Table I).

Keeping in view the large size of the adrenal mass lesion, she underwent right laparoscopic adrenalectomy. The postoperative course was uneventful. Histopathological examination revealed adrenal myelolipoma.

Table I. Endocrine tests

	CASE 1	CASE 2	CASE 3	CASE 4	NORMAL VALUE
Plasma					
Cortisol 8.00	526 nmol/l	307 nmol/l	564 nmol/l	487 nmol/l	171-536 nmol/l
Cortisol 20.00	102.2 nmol/l	232 nmol/l	147 nmol/l	220 nmol/l	64-340 nmol/l
ACTH 8.00	17.3 pg/ml	12.4 pg/ml	10.2 pg/ml	14.2 pg/ml	9-46 pg/ml
ACTH 20.00	10 pg/ml	< 10 pg/ml	< 10 pg/ml	10.5 pg/ml	9-46 pg/ml
DHEAS	4.3 μ mol/l	5.2 μ mol/l	12.4 μ mol/l	1.9 μ mol/l	1.08-10.7 μ mol/l
Androstenedione	2.39 ng/ml	1.74 ng/ml	5.6 ng/ml	3.0 ng/ml	0.2-3.1 ng/ml
Testosterone			106 ng/l		20-96 ng/l
17OH progesterone			1.2 ng/ml		0.2-1.3 ng/ml
1 mg DEX "overnight" test	42.7 nmol/l	< 27 nmol/l	89 nmol/l	35.6 nmol/l	< 50 nmol/l
Urine					
Cortisol	127 nmol/day	177 nmol/day	67 nmol/day	102 nmol/day	50-200 nmol/day
17-ketosteroids	11.5 mg/day	9 mg/day	9.9 mg/day	10.7 mg/day	7-12 mg/day
Metanephrines	413 μ g/day	607 μ g/day	513 μ g/day	578 μ g/day	< 1000 μ g/day

Case 2

A 79-year-old female, known to have hypertension, was hospitalized for examinations of a right adrenal mass that was incidentally discovered by abdominal CT during examinations of weakness and liver region pain (suspicion of cholelithiasis).

Blood and urine tests showed that the adrenal mass was non-functional (Table I). The CT revealed a 40 mm \times 36 mm \times 25 mm mass arising from the lateral limb of the left adrenal gland consisting of fat. The patient had left laparoscopic adrenalectomy performed. Histopathological examination revealed adrenal myelolipoma.

Case 3

A 56-year-old female with hypertension and diabetes mellitus was found to have an incidental left-side adrenal mass. An ultrasound test was made for urinary frequency. Physical examination revealed hirsutism, pronounced virilization and obesity. She reported irregular menstrual cycles and sterility.

The CT scans revealed solid well-defined adrenal tumor. It measured 2.0 cm \times 1.8 cm and caused distortion of the lateral limb of the left adrenal gland.

Laboratory tests showed overproduction of dehydroepiandrosterone sulfate (DHEAS), androstenedione and testosterone (Table I). A 5 days' 2 mg dexamethasone suppression test was also performed. The plasma testosterone level was not suppressed (it was even increased), thus confirming the diagnosis of hormonal activity of the adrenal tumor. We exclude Cushing's syndrome using 2 mg and 8 mg dexamethasone suppression test (Table II). Subsequently, the patient had a total adrenalectomy performed. A histological association of adrenal nodular hyperplasia with the focus of myelolipomas was found (Fig. 1, Fig. 2). The androgens' level was normal after the adrenal mass was removed without any complications.

Case 4

A 66-year-old man was found to have an incidental well-defined echogenic right adrenal mass. The ultrasound test was done because of the right abdominal pain.

The CT scan of the abdomen showed an isolated 70 mm \times 5.5 mm \times 4.5 mm heterogeneous right suprarenal mass.

The clinical history, physical examination and laboratory tests showed that there was no evidence suggesting

Table II. Endocrine tests: suppression tests – case 3

TESTS	PLASMA CORTISOL	PLASMA ACTH	URINARY CORTISOL	URINARY 17-KETOSTEROIDS	DHEAS	TESTOSTERONE	ANDROSTENEDIONE
2 mg DEX suppression	27 nmol/l	< 10 pg/ml	45 nmol/day				
8 mg DEX suppression	35 nmol/l	< 10 pg/ml	22 nmol/day	10.6 mg/day		97 ng/l	
5 days' 2 mg DEX suppression					5.2 μ mol/l	104 ng/l	1.1 ng/dl

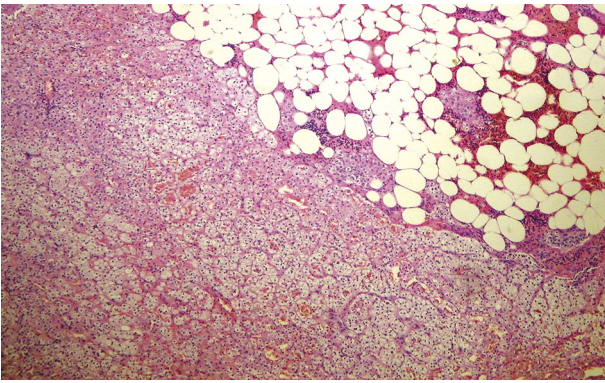


Fig. 1. The border between myelolipoma and cortical nodular hyperplasia. Note clearly visible foci of myeloid differentiation (HE, magnification 40×). Case 3

that the patient had metabolic disorders commonly associated with adrenal tumor. The patient was subsequently admitted to the hospital for preoperative work-up of the adrenal mass. The endocrine tests did not suggest that the lesion was hypersecretory (Table I).

Because of the adrenal mass size of over 4 cm, the patient underwent laparoscopic adrenalectomy. The postoperative course was uneventful. Histopathological examination revealed myelolipoma mixed with adrenal hyperplasia.

Discussion

Myelolipomas are usually small non-functional tumors. Histologically, the tumor is primarily composed of fatty tissue with scattered hematopoietic elements [1, 5, 10]. Although those tumors are predominantly associated with adrenal glands, the extraadrenal locations are also reported [10]. Moreover, myelolipomas have been reported not only as an isolated adrenal mass, but also in the association with other adrenal pathological conditions, at a frequency of 5-15%, adrenocortical nodular hyperplasia, adrenocortical adenomas or carcinomas, and endocrinological dysfunctions including Addison's disease, Conn's syndrome, Cushing's syndrome, 21-hydroxylase deficiency, 17-hydroxylase deficiency and very rarely, medullary hyperplasia [2, 9, 12-14]. In a group of 294 patients who underwent adrenalectomy, adrenal myelolipomas were found in 4 cases (1.36%). Two cases of myelolipomas coexisted with adrenal nodular hyperplasia.

A group of 408 patients have been followed up in an outpatient clinic for 2-15 years. Radiological and hormonal tests have not revealed the progression of the disease.

Adrenal myelolipomas are usually diagnosed during imaging procedures performed for other purposes and, in the majority of cases, they are incidentalomas. The large lesions have been reported to present with symptoms such as flank pain resulting from tu-

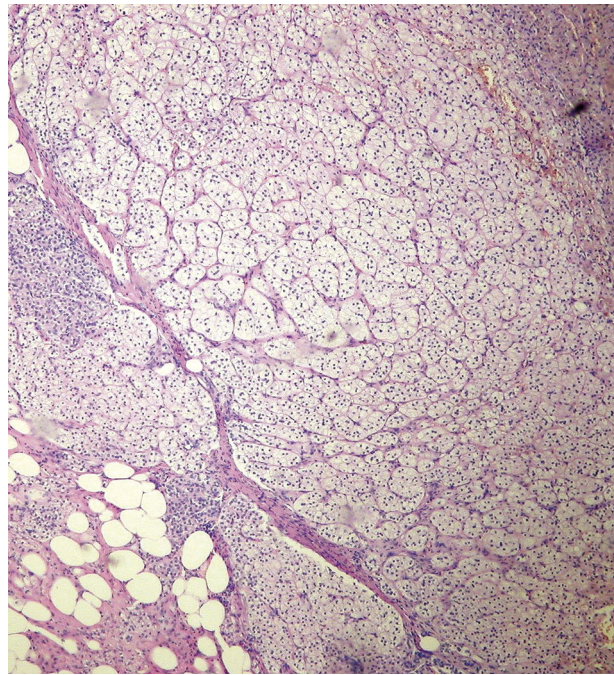


Fig. 2. The other area of the suprarenal gland showing well-formed cortical, hyperplastic nodule (HE, magnification 40×). Case 3

mor bulk, necrosis or spontaneous rupture with retroperitoneal hemorrhage [10, 11]. In our group, the patients were referred because of an adrenal tumor discovered during an ultrasound examination of the abdomen, performed for reasons other than the suspected adrenal lesion. The ultrasound findings were verified by CT in all cases. The first step in diagnosis work-up of adrenal incidentalomas is assessment of their hormonal activity. In a group of four myelolipomas, only one patient with mixed adrenocortical hyperplasia containing myelolipoma, was diagnosed with androgen overproduction.

Most authors recommended surgery for hormonal active adrenal tumors or/and tumors larger than 4 cm resulting from the strong correlation of adrenal tumor size with a risk of malignancy [4, 10, 15]. There are different indications for surgery in myelolipomas. These tumors are benign even when lesions are more than 6 cm; therefore, the tumor size guideline does not apply to myelolipomas [4, 10, 15]. On the CT scans, they are typically seen as a well-circumscribed, heterogeneous suprarenal masses of low density (usually less than -30 HU equivalent to mature fat). Magnetic resonance imaging (MRI) typically shows high signal intensity on T1-weighted images and attenuates with fat suppression [16]. If there are radiological elements of myelolipoma, some authors advocate surgery for tumor size of even more than 10 cm resulting for a risk of developing abdominal pain or life-threatening hemorrhage that may be associated with large tumors [10].

Myelolipomas are usually diagnosed on CT by the pathognomonic presence of fat in the lesion. In our

group of four presenting tumors, the CT scans were not suggestive of myelolipomas. We recommend surgery for adrenal incidentalomas larger than 4 cm resulting from a strong correlation of the adrenal tumor size with the risk of malignancy. The subclinical androgen excess may accompany adrenocortical carcinomas [15]. Because of that, in one case we advocated surgery for hormonally active tumor of 2 cm.

The laparoscopic adrenalectomy became the standard of care for the treatment of functioning and non-functioning adrenal tumors. In our own material, two patients underwent laparoscopic adrenalectomy. In case 3, because of suggestion of adrenocortical carcinoma and in case 4, because of the adrenal tumor size of over 7 cm, patients underwent open adrenalectomy.

Mixed changes in adrenocortical tumors are extremely rare. There are only a few cases reported in the English literature [8, 13, 14]. Etiology of mixed adrenal tumors is unclear, although it has been associated with other medical conditions like hypertension, atherosclerosis, diabetes mellitus and other chronic conditions. Various theories of the etiology of associated adrenal nodular hyperplasia or adenoma and myelolipoma had been presented. Myelolipomas are derived from bone marrow embolization or embryonic primitive mesenchymal cells, or arise from metaplastic transformation of adrenal stromal cell [1, 2, 12]. The adrenal gland could be transformed into myelolipomatous elements due to necrotic tissue products, in patients with cancer or other chronic diseases [7]. A case of myelolipoma associated with hyperthyroidism was also reported. The thyroid hormones have important effects on the development, growth, metabolism and tumorigenesis of myelolipoma in the adrenal gland [7]. In our own material, there were no patients with known neoplastic disease and hyperthyroidism.

The hormonal microenvironment might have played an important role in the development of the associated adrenal hyperplasia or adenoma and myelolipomatous foci. Stimulation with adrenocorticotropic hormone (ACTH), cortisol, dehydroepiandrosterone (DHEA) or testosterone might have changed adrenocortical hyperplasia into myelolipomas foci [12, 17]. Similarly, the myelolipomas seen in patients with chronic illnesses, including cancer, may be due in part to prolonged stimulation with ACTH hormone from marked stress [9, 17].

The adrenocortical adenoma or adrenal hyperplasia may have subclinical secretion. The persistent stimulation by hormones might have played a role as a mediator in transforming the adrenal tissue into myeloid cells and fatty replacement [13]. In our own material, the testosterone overproduction could transform adrenal nodular hyperplasia to myelolipomas foci.

In conclusion, adrenal nodular hyperplasia associated with myelolipoma is rare. The mechanism of concurrence remains unclear and multiple factors are probably involved.

References

- Osborn M, Smith M, Senbanjo T, et al. Adrenal myelolipomas – clinical, radiological and cytological findings: a case report. *Cytopathology* 2002; 13: 242-246.
- Manassero F, Pomara G, Rappa F, et al. Adrenal myelolipomas associated with adenoma. *Int J Urol* 2004; 11: 326-328.
- Yildiz I, Akpolat I, Erzurumlu K, et al. Giant adrenal myelolipomas: case report and review of the literature. *Pathol Int* 2000; 50: 502-504.
- Al Harthi B, Riaz MM, Al Khalaf AH, et al. Adrenal myelolipoma a rare benign tumour managed laparoscopically: report of two cases. *J Minim Access Surg* 2009; 5: 118-120.
- Bialas M, Okoń K, Stachura J. Primary adrenal tumors – a 16-year experience in single institution. *Pol J Pathol* 2008; 59: 101-106.
- Tamidari H, Mishara AK, Gupta S, Aguarwal A. Catecholamine secreting adrenal myelolipomas. *Indian J Med Sci* 2006; 60: 331-333.
- Lu HS, Gan MF, Chen HS, Huang SQ. Adrenal myelolipomas with myxoid cortical adenoma associated with Conn's syndrome. *J Zhejiang Univ Sci B* 2008; 9: 500-505.
- Vrezas I, Wentworth P, Bornstein SR. Myelolipomatous foci in an adrenal adenoma causing Cushing's syndrome? *Endocr Res* 2003; 29: 67-71.
- Ishay A, Dharan M, Luboshitzky R. Combined adrenal myelolipomas and medullary hyperplasia. *Horm Res* 2004; 62: 23-26.
- Patel VG, Babalola OA, Fortson JK, Weaver WL. Adrenal myelolipoma: report of cases and review of the literature. *Am Surg* 2006; 72: 649-654.
- Ioannidis O, Papaemmanouil S, Chatzopoulos S, et al. Giant bilateral symptomatic adrenal myelolipomas associated with congenital adrenal hyperplasia. *Pathol Oncol Res* 2011; 17: 775-778.
- Yamada S, Tanimoto A, Wang KY, et al. Non-functional adrenocortical adenoma: a unique case of combination with myelolipomas and endothelial cysts. *Pathol Res Pract* 2011; 207: 192-196.
- Matsuda T, Abe H, Takase M, et al. Case of combined adrenal cortical adenoma and myelolipomas. *Pathol Int* 2004; 54: 725-729.
- Honda K, Kashima K, Daa T, et al. Myxoid adrenal cortical adenoma. *Pathol Int* 2001; 51: 887-891.
- Babinska A, Sworczak K, Wiśniewski P, et al. The role of immunohistochemistry in histopathological diagnostics of clinically "silent" incidentally detected adrenal masses. *Exp Clin Endocrinol Diabetes* 2008; 116: 246-251.
- Kenny PJ, Wagner BJ, Rao P, Heffess CS. Myelolipoma: CT and pathologic features. *Radiology* 1998; 208: 87-95.
- Selye H, Stone H. Hormonally induced transformation of adrenal into myeloid tissue. *Am J Pathol* 1950; 26: 211-233.

Address for correspondence

Anna Babinska MD
Department of Endocrinology and Internal Medicine
Medical University of Gdansk
ul. Dębinki 7
80-288 Gdańsk, Poland
phone: +48 58 349 28 40, +48 58 349 28 41
e-mail: a.mail@wp.pl