

SPECIFICITY AND SENSITIVITY OF INI-1 LABELING IN EPITHELIOID SARCOMA

LOSS OF INI1 EXPRESSION AS A FREQUENT IMMUNOHISTOCHEMICAL EVENT IN SYNOVIAL SARCOMA

KATARZYNA MULARZ, AGNIESZKA HARAZIN-LECHOWSKA, ALEKSANDRA AMBICKA, ANNA KRUCZAK,
MAGDALENA ROZMUS-PIĘTOŃ, URSZULA MARCHIŃSKA-OSIKA, IWONA ŚWIĄTKIEWICZ, MARTA KRÓL,
DARIUSZ PABIS, GRZEGORZ JANUŚ, JANUSZ RYŚ

Department of Tumour Pathology, Centre of Oncology – Maria Skłodowska-Curie Memorial Institute,
Cracow Branch, Poland

INI1 antigen is a product of the *INI-1/SMARCB1* gene localized on chromosome 22q. It is well known that *INI1* gene inactivation or loss of INI1 antigen expression is observed in epithelioid sarcomas; however, there are only few reports concerning specificity and sensitivity of immunohistochemical INI1 labeling as a marker of this neoplasm. That is why we decided to test 99 soft tissue sarcomas for the presence of the *INI1* gene product. More specifically, the analyzed group consisted of 33 synovial sarcomas, 14 fibrosarcomas, 8 desmoid tumors, 8 DFSPs, 5 MPNSTs, 9 epithelioid sarcomas, 11 Ewing sarcomas/PNETs, 9 rhabdomyosarcomas and 2 clear cell sarcomas. Additionally, 7 malignant melanomas and 9 adenocarcinomas were included into the study.

Positive staining with an antibody against the *INI-1* gene product was observed in all studied cases of MPNST, Ewing sarcoma/PNET, rhabdomyosarcoma, malignant melanoma, clear cell sarcoma, and adenocarcinoma. On the contrary, none of 9 epithelioid sarcomas was labeled. The loss of INI1 expression was also detected in 7 (21.2%) synovial sarcomas, confirmed cytogenetically or by FISH. Considering the lack of reaction with INI-1 antibody as a diagnostic test for epithelioid sarcoma we estimated that its sensitivity reached 100% and specificity – 83.5% ($p < 0.0001$).

Key words: INI-1 antigen, immunohistochemistry, epithelioid sarcoma, synovial sarcoma.

Introduction

INI-1 antigen, also known as RDT, SNF5, Snr1, BAF47, RTPS, Sfh1p, hSNFS or SNF5L1 is a product of the *INI-1/SMARCB1* (*SWI/SNF-related matrix-associated actin-dependent regulator of chromatin subfamily B member 1*) gene localized on chromosome 22q [1]. It is a member of an evolutionarily conserved SW1/SNF complex that activates transcription of selected genes by chromatin remodeling in an ATP-dependent manner [2, 3]. For example, the SWI/SNF complex is nec-

essary for *c-MYC*-mediated transactivation. What is more, the nuclear protein INI1 binds to HIV-1 integrase facilitating the insertion of viral DNA (e.g. HPV virus) into the human genome [2].

INI1-related growth arrest results from its binding to GADD34 and HFR fusion proteins (that leads to formation of a trimolecular complex *in vivo*). In this complex, the product of the *GADD34* gene mediates growth arrest and apoptosis in response to negative growth signals, DNA damage, and protein misfolding. Wu *et al.* showed that the fusion of INI1 protein and

Epstein-Barr nuclear protein 2 disrupts INI1 binding to GADD34 and partially reverses the GADD34-mediated growth suppression in Ha-ras expressing HIH-3T3 cells [4].

Loss of INI1 expression or *INI1* gene inactivation was observed in epithelioid sarcomas, renal and/or extrarenal rhabdoid tumors, extraskeletal myxoid chondrosarcomas, epithelioid MPNSTs as well as medullary renal carcinomas and myoepithelial cell tumors [5].

Aim of the study

There are only few reports concerning specificity and sensitivity of an anti-*INI1* antibody as an immunohistochemical marker of epithelioid sarcoma. That is why we decided to investigate a new commercially available antibody against the *INI-1* gene product.

Material and methods

Tissue material from 99 soft tissue sarcomas representing three main categories of malignant mesenchymal tumors were selected for the study. Among them there were 54 spindle cell sarcomas, 21 sarcomas built of epithelioid cells, and 24 malignant small round blue cell tumors. More specifically, the analyzed group consisted of 33 synovial sarcomas, 14 fibrosarcomas, 8 desmoid tumors, 8 DFSPs, 5 MPNSTs, 9 epithelioid sarcomas, 11 Ewing sarcomas/PNETs, 9 rhabdomyosarcomas and 2 clear cell sarcomas. Additionally, 7 malignant melanomas and 9 adenocarcinomas were included into the study (Table I).

Immunohistochemical studies were performed on formalin-fixed, paraffin-embedded sections, up to 4 μ m thick, mounted onto Super-Frost(+) slides and dried at 56°C for 24 hours, then deparaffinized in xylene (2 \times 30 minutes), rehydrated in absolute alcohol followed by 96% alcohol (for 5 minutes in each concentration) and, finally, rinsed in distilled water. In the rehydrated sections, endogenous peroxidase was blocked with 3% hydrogen peroxide for 15 minutes. Afterwards, the sections were immersed in sodium citrate buffer (pH 6.0), and underwent the unmasking procedure according to the original manufacturer's indications. After washing in TBS, the sections were successively incubated with blocking serum, primary antibody (anti-*INI* monoclonal antibody, clone Y-7; Santa Cruz Biotechnology Inc., California, USA, 1 : 500 dilution, incubation for 24 h at 4°C) and detection system components. Finally, the slides were incubated in DAB solution (DAKO-S3000) with 3% hydrogen peroxide, counterstained in Harris hematoxylin, dehydrated and coverslipped in Canada Balsam.

Statistical analysis

Sensitivity, specificity, PPV (*positive predictive value*) and NPV (*negative predictive value*) were estimated according to the definitions depicted in Table II. The differences between values of the tested variables were assessed using χ^2 test with Yates' correction and p-value < 0.05 was considered statistically significant.

Table I. Histological characteristics of the tumors studied

HISTOLOGY	TOTAL NUMBER OF TUMORS	SPINDLE-CELL SARCOMAS	SARCOMAS WITH EPITHELIOID COMPONENT	SMALL ROUND-CELL TUMORS
synovial sarcoma ^a	33	20	9 ^b	4
fibrosarcoma ^c	14	13	1	
fibromatosis (desmoid tumor)	8	8		
dermatofibrosarcoma protuberans	8	8		
malignant peripheral nerve sheath tumor	5	5		
epithelioid sarcoma	9		9	
Ewing sarcoma/PNET	11			11
rhabdomyosarcoma ^d	9	2		7
melanoma of soft part	2		2	
malignant melanoma	7		7	
adenocarcinoma	9		9	
total number of tumors studied	115	54	37	24
total number of sarcomas studied	99	54	21	24

^aAll synovial sarcomas were confirmed cytogenetically and/or by FISH using *SYT* break apart probes.

^bBiphasic synovial sarcomas.

^cIncluding 1 case of epithelioid fibrosarcoma and 1 infantile fibrosarcoma.

^dThe rhabdomyosarcoma group consisted of 4 alveolar, 3 embryonal, 1 sclerosing and 1 pleomorphic subtypes.

Results

Positive immunohistochemical staining with an antibody against the *INI-1* gene product was characterized by intensive nuclear reaction in both neoplastic and normal cells. It was observed in all studied cases of malignant peripheral nerve sheath tumor (MPNST), Ewing sarcoma/PNET, rhabdomyosarcoma, malignant melanoma, clear cell sarcoma (melanoma of soft parts), and adenocarcinomas. The reaction was found in 100% of cells of all above-mentioned tumors.

Among the remaining neoplasms, the percentage of cases labeled by the antibody to INI-1 protein varied from 78.8% (synovial sarcomas) to 92.9% (fibrosarcomas) (Table II) (Fig. 1A-E). Epithelioid sarcoma was the only exception among studied tumors; the reaction to the INI-1 antibody was observed in none of 9 epithelioid sarcomas tested. Non-neoplastic stromal cells of entrapped normal tissues, inflammatory cells as well as endothelial cells were used as positive controls in all these cases (Fig. 1F). Noteworthy, the lack of the INI1 expression was also detected in 7 (21.2%) synovial sarcomas, confirmed cytogenetically or by FISH.

Considering the lack of reaction with the INI-1 antibody as a diagnostic test for epithelioid sarcoma we estimated that its sensitivity reached 100%, and specificity – 83.5%. PPV and NPV values were 47.4% and 100%, respectively ($\chi^2 = 45.91$, $p < 0.0001$).

With regard to malignant neoplasms built exclusively of epithelial and/or epithelioid cells (biphasic synovial sarcomas, epithelioid fibrosarcoma, epithelioid sarcoma, melanoma and carcinomas), the specificity of the immunohistochemical test for the absence of the INI-1 antigen appeared to be much higher; its value was estimated as 96.4% (Table IV). PPV and NPV rates, defining the significance of INI-1 labeling in differential diagnosis of epithelioid sarcomas and other epithelial/epithelioid malignant tumors were calculated as 90% and 100%, respectively ($p < 0.0001$).

Table II. Definitions of the estimated value

Sensitivity = true positives/(true positives + false negatives)
Specificity = true negatives/(true negatives + false positives)
Positive predictive value = true positives/(true positives + false positives)
Negative predictive value = true negatives/(true negatives + false negatives)

lioid sarcomas and other epithelial/epithelioid malignant tumors were calculated as 90% and 100%, respectively ($p < 0.0001$).

Discussion

Loss of reaction with the antibody against the suppressor *INI1* gene product is considered a sensitive and specific marker of epithelioid sarcoma. A review of available literature has shown that lack of INI1 expression was characteristic of the vast majority (80-90%) of epithelioid sarcoma cases, both for the classic and so-called proximal type of the tumor [6, 7]. In the studied group, all of nine cases of epithelioid sarcoma also showed negative immunohistochemical staining against the INI1 antigen.

The present study has revealed that loss of the INI1 antigen expression in tumor cell nuclei can be a useful marker in differential diagnosis between epithelioid sarcoma (negative immunohistochemical reaction) and a group of soft tissue sarcomas which express this protein (desmoid tumour, epithelioid fibrosarcoma, rhabdomyosarcoma, and Ewing sarcoma/PNET). Finally, this marker can be also helpful in differential diagnosis between epithelioid sarcoma and metastatic adenocarcinoma or malignant melanoma. Similar results

Table III. Results of immunohistochemical studies with the antibody against INI-1 protein

HISTOLOGICAL TYPE OF THE TUMOR	TOTAL NUMBER OF TUMORS	NUMBER (%) OF TUMORS WITH POSITIVE REACTION	NUMBER (%) OF TUMORS WITH NEGATIVE REACTION
epithelioid sarcoma	9	0	9 (100.0)
synovial sarcoma	33	26 (78.8)	7 (21.2)
dermatofibrosarcoma	8	6 (87.5)	1 (12.5)
fibrosarcoma	14	13 (92.9)	1 (7.1)
fibromatosis/desmoid	8	8 (100)	0
MPNST	5	5 (100)	0
Ewing sarcoma/PNET	11	11 (100)	0
rhabdomyosarcoma	9	9 (100)	0
melanoma of soft part	2	2 (100)	0
malignant melanoma	7	7 (100)	0
adenocarcinoma	9	9 (100)	0
total number of tumors studied	115	96 (83.5)	19 (16.5)

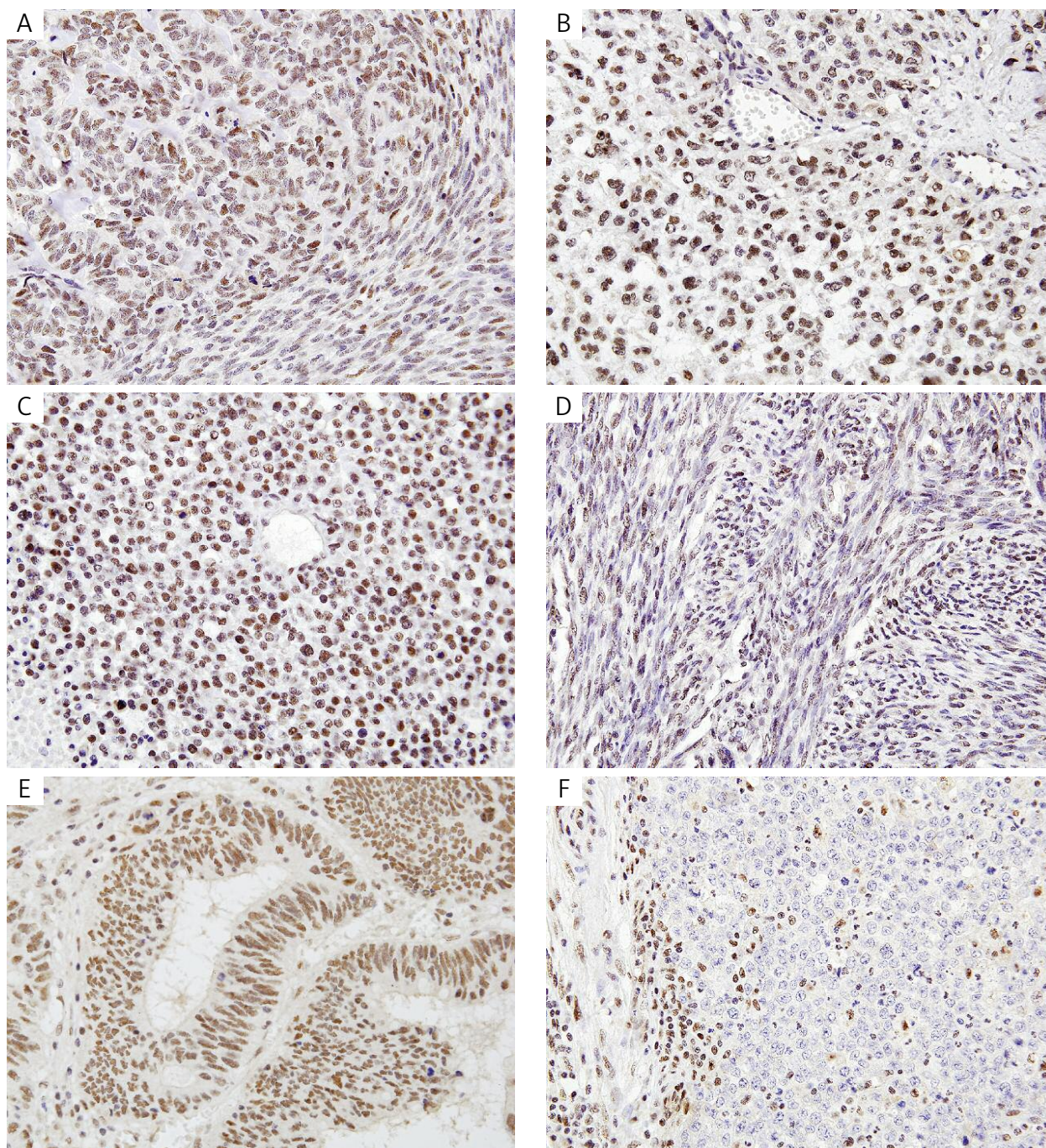


Fig. 1. Results of immunohistochemical studies with the antibody against INI-1 protein. Positive nuclear reaction in the neoplastic cells of synovial sarcoma (A), Ewing sarcoma/PNET (B, C), fibrosarcoma (D), and adenocarcinoma (E). The lack of reaction in the nuclei of epithelioid sarcoma (F) with simultaneous nuclear labeling of non-neoplastic stromal cells as well as inflammatory cells in the vicinity of tumor tissue (internal control of the immunohistochemical reaction)

were noticed by Hornick *et al.* [7], who found intact reaction to INI1 protein in all 54 adenocarcinomas, 12 embryonal carcinomas, 20 metastatic melanomas, 20 malignant mesotheliomas, 30 malignant vascular proliferations (20 epithelioid angiosarcomas and 10 hemangioendotheliomas), as well as in 7 anaplastic large cell lymphomas and 5 histiocytic sarcomas. On the contrary, 12 (50%) of 24 tested epithelioid Ma-

lignant Peripheral Nerve Sheath Tumors (MPNSTs) presented the loss of the INI1 antigen expression [7].

Moreover, the lack of INI1 antigen is typical of extrarenal rhabdoid tumor. That is why this neoplasm is thought, at least by some authors, as an entity related to the proximal type of epithelioid sarcoma [1, 8].

Loss of INI1 protein expression was also noticed in some synovial sarcomas [1, 8]. In our study, this phe-

Table IV. Results of immunohistochemical studies with the antibody against INI-1 protein in a subgroup of malignant neoplasms built of epithelioid and/or epithelial cells

HISTOLOGICAL TYPE OF THE TUMOR	TOTAL NUMBER OF TUMORS	NUMBER (%) OF TUMORS WITH POSITIVE REACTION	NUMBER (%) OF TUMORS WITH NEGATIVE REACTION
epithelioid sarcoma	9	0	9 (100.0)
synovial sarcoma (biphasic type)	9	8 (88.9)	1 (11.1)
epithelioid fibrosarcoma	1	1 (100)	0
malignant melanoma	7	7 (100)	0
adenocarcinoma	9	9 (100)	0
melanoma of soft part	2	2 (100)	0
total number of tumors studied	37	27 (72.9)	10 (27.1)

nomenon was revealed in 7 (21.2%) of 33 cases of synovial sarcomas. However, Kohashi *et al.* observed the lack of reaction with the anti-*INI1* antibody in 66 (69%) of 95 synovial sarcomas [9], and Argyrakos *et al.* [10] found reduced reaction to *INI1* in 4 of 5 cases of synovial sarcomas and no reaction in one case.

The results obtained by Japanese authors [9] are similar to ours; they observed nuclear reaction with the anti-*INI1* antibody in all of 10 MPNSTs. However, they also found the intact *INI1* expression in 3 adult fibrosarcomas as well as 7 fibrosarcomas arising in DFSP [9]. What is more, they described four cases of extraskeletal myxoid chondrosarcoma with no *INI1* antigen expression. Additionally, 2 of these 4 cases presented homozygous deletion and frameshift mutation of the *SMARCB1/INI1* gene [11].

References

1. Modena P, Lualdi E, Facchinetti F, et al. *SMARCB1/INI1* tumor suppressor gene is frequently inactivated in epithelioid sarcomas. *Cancer Res* 2005; 65: 4012-4019.
2. Cheng SW, Davies KP, Yung E, et al. *c-MYC* interacts with *INI1/hSNF5* and requires the *SWI/SNF* complex for transactivation function. *Nat Genet* 1999; 22: 102-105.
3. Kalpana GV, Marmon S, Wang W, et al. Binding and stimulation of HIV-1 integrase by a human homolog of yeast transcription factor *SNF5*. *Science* 1994; 266: 2002-2006.
4. Wu DY, Tkachuck DC, Roberson RS, et al. The human *SNF5/INI1* protein facilitates the function of the growth arrest and DNA damage-inducible protein (*GADD34*) and modulates *GADD34*-bound protein phosphatase-1 activity. *J Biol Chem* 2002; 277: 27706-27715.
5. Hollmann TJ, Hornick JL. *INI1*-deficient tumors: diagnostic features and molecular genetics. *Am J Surg Pathol* 2011; 35: e47-63.
6. Chbani L, Guillou L, Terrier P, et al. Epithelioid sarcoma: a clinicopathologic and immunohistochemical analysis of 106 cases from the French sarcoma group. *Am J Clin Pathol* 2009; 131: 222-227.
7. Hornick JL, Dal Cin P, Fletcher CD. Loss of *INI1* expression is characteristic of both conventional and proximal-type epithelioid sarcoma. *Am J Surg Pathol* 2009; 33: 542-550.
8. Guillou L, Waden C, Coindre JM, et al. Proximal type epithelioid sarcoma, a distinctive aggressive neoplasm showing rhabdoid features. *Clinicopathologic, immunohistochemical, and ultrastructural study of a series.* *Am J Surg Pathol* 1997; 21: 130-146.
9. Kohashi K, Oda Y, Yamamoto H, et al. Reduced expression of *SMARCB1/INI1* protein in synovial sarcoma. *Mod Pathol* 2010; 23: 981-990.
10. Argyrakos T, Kopaka M, Karagkounis G, et al. *INI-1* and *TLE1* expression in five synovial sarcomas diagnosed by fluorescent in situ hybridization. *Virchows Arch* 2012; 461 (Suppl 1): S224.
11. Kohashi K, Oda Y, Yamamoto H, et al. *SMARCB1/INI1* protein expression in round cell soft tissue sarcomas associated with chromosomal translocations involving *EWS*: a special reference to *SMARCB1/INI1* negative variant extraskeletal myxoid chondrosarcoma. *Am J Surg Pathol* 2008; 32: 1168-1174.

Address for correspondence

Janusz Ryś MD, PhD
 Department of Tumour Pathology,
 Centre of Oncology, Maria Skłodowska-Curie Memorial Institute
 Cracow Branch, Poland
 ul. Garncarska 11
 31-115 Kraków, Poland
 phone and fax: +48 12 421 20 98
 e-mail: z5rys@cyf-kr.edu.pl