

Quiz

WHAT IS YOUR DIAGNOSIS?

A 23 year-old female with anemia presented with several episodes of fresh blood in the stools. During elective colonoscopy, a 5 cm sessile polyp located 15 cm from the anal verge was discovered and partially excised. Histopathological examination showed an adenomatous polyp with high-grade dysplasia and small foci of adenocarcinoma, consequently the patient was qualified for laparoscopic anterior resection of the rectum. During the laparoscopic procedure,

diffuse black discoloration of the parietal peritoneum, greater omentum (Fig. 1), mesenteric lymph nodes and ovaries was discovered. Because of the suspicion of advanced metastatic intraperitoneal melanoma, biopsies of the lesions were taken and the laparoscopic anterior rectal resection was postponed.

Microscopic images of routine HE staining of the lesion (Figs. 2-3) as well as the melan A staining (Fig. 4) are shown.

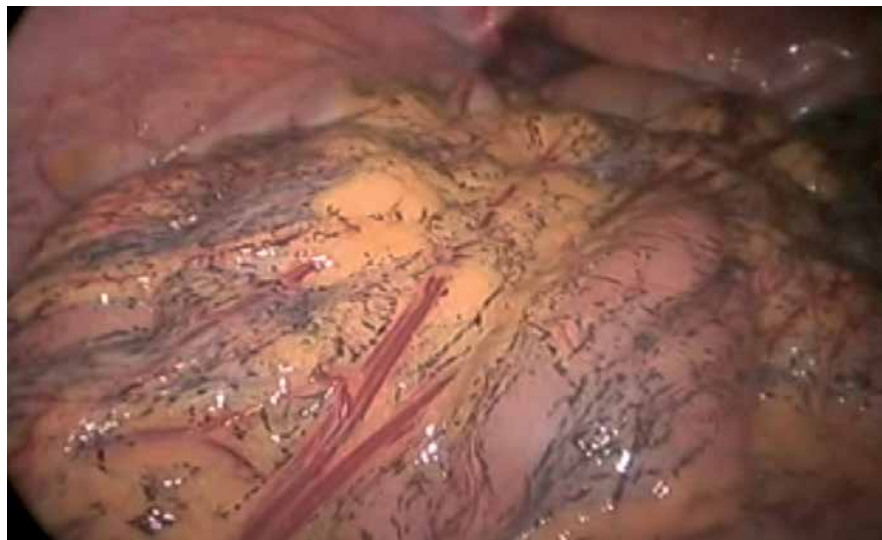

Fig. 1.

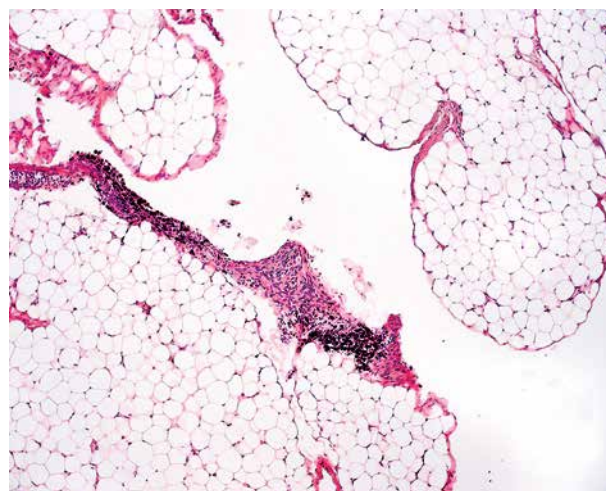


Fig. 2.

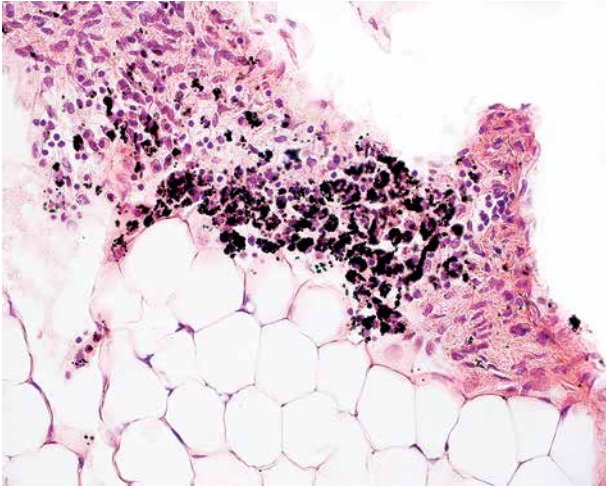


Fig. 3.

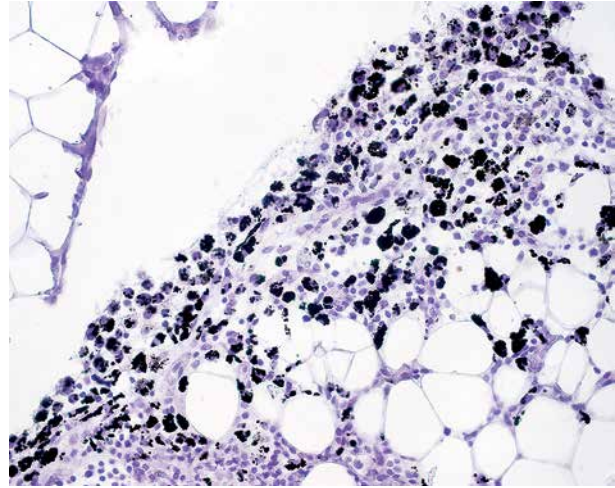


Fig. 4.

Ea-sle Chang¹, Piotr Bachul^{1,2}, Mirosław Szura¹, Joanna Szpor³, Krzysztof Okoń³, Jerzy A. Walocha²

¹First Department of General, Oncological and Gastroenterological Surgery,
Jagiellonian University Medical College, Krakow, Poland

²Department of Anatomy, Jagiellonian University Medical College, Krakow, Poland

³Department of Pathomorphology, Jagiellonian University Medical College, Krakow, Poland

Answers should be sent to the Editorial Office by 15.08.2015. The correct answer will be announced in the next issue of the *Polish Journal of Pathology*. All participants with the highest number of correct answers to the quizzes published in vol. 66 (4 issues) will be entered into the prize draw for a book.