

PAROTID GLAND TUMORS IN CHILDREN – PRE- AND POSTOPERATIVE DIAGNOSTIC DIFFICULTIES

RAFAŁ ZIELIŃSKI¹, JÓZEF KOBOS², ANNA ZAKRZEWSKA¹

¹Department of Paediatric Otolaryngology, Phoniatriy and Audiology, Medical University of Lodz, Poland

²Department of Pathology, University Clinical Hospital No.4, Medical University of Lodz, Poland

Major salivary gland tumors are very rare in the developmental period. Confirming tumor changes in the salivary gland requires precise diagnostic imaging involving an ultrasonography scan, computed tomography and magnetic resonance. Needle aspiration biopsy (NAB) of the tumor is of high importance. Excision is the basic treatment method in cases of parotid gland tumor. The statistical data concerning tumors favor less invasive methods, which seems logical in the population of children. The surgical methods used in tumor treatment feature extracapsular excision of tumor, partial parotidectomy and total parotidectomy, sometimes followed by lymphatic node surgery. The clinical cases presented in the paper show difficulties with pre- and postoperative histopathological diagnosis in major salivary gland tumors in children. A core biopsy of the tumor may improve the accuracy of preoperative diagnosis but it does not exclude the possibility of misdiagnosis.

Key words: tumor, salivary gland, children.

Introduction

Salivary gland tumor lesions in children are rare: they constitute about 10% of all childhood tumors in the head and neck area [1]. In the youngest children, the most common are hemangiomas, while the most commonly seen in pre-school and school children are inflammatory tumors [2, 3]. The most common benign epithelial tumor of the major salivary glands is the pleomorphic adenoma: in both adults and children, its most common location is the parotid gland [4]. The incidence of these neoplasms is higher in children over ten years old, with approximately 70% occurring between 16 and 20 years of age [5]. However, the most common malignant salivary gland tumor in children is mucoepidermoid carcinoma, which occurs mainly in older children and young people, but is also a problem in children under 10 [6]. Other malignant salivary gland tumors are adenoid cystic carcinoma, non-differentiated carcinoma, cancer originating from alveolar cells and sarcoma [7]. The paper presents two examples of the difficulties en-

countered in the diagnosis of parotid salivary gland tumors in children.

Case reports

A boy aged 15 was admitted to the clinic suffering from a tumor of the left preauricular area. The lesion had drawn attention for about 10 months. Previously, the boy had been examined by both a surgeon and a laryngologist, who recommended needle aspiration biopsy (NAB) of the lesion. The results of a second histopathological examination showed that it had the texture of pleomorphic adenoma.

On the day of admission, the physical examination confirmed a tuberous lesion located in the left parotid gland projection, mobile, about 2 cm × 2 cm in size, with no skin coloration or morphology change above the lesion. The examination did not show any features of peripheral paresis or paralysis of the facial nerve. The patient's general condition was good and laboratory tests did not show any significant anomalies. Based on the size of the lesion

and preoperative histopathology test results, it was decided to excise the tumor by means of the extracapsular method. During the surgery, a left parotid gland tumor measuring 1.7 cm × 1.5 cm was enucleated. However, in one pole of the lesion, an infiltration with signs of inflammation was noticeable. The entire lesion, with the enlarged lymph node, was located between the parotid glands. Following the procedure, the topical condition was good and the wound healed well.

The histopathological examination of the tuberos lesion showed a diametrically textured low-grade mucoepidermoid carcinoma, which demonstrated high histopathological differentiation. The lymph node also demonstrated features of inflammation.

A quick decision to perform re-surgery, with total parotidectomy on the left side on the seventh day after surgery, was prompted by the result of the histopathological examination. The trunk and branches of the facial nerve were preserved. The patient's general and topical condition after the operation was good. Histopathological examination showed the radicality of surgery. The boy had been under outpatient clinic care for 12 months. Clinical trials and control ultrasonography did not show any alarming abnormalities. But in the fourth month during follow-up examinations, the patient was diagnosed with diabetes, and appropriate diabetes treatment was established (Figs. 1-3).

A girl aged 15 was admitted to the clinic with a left preauricular area tumor, which was visible and had been growing for about 3 months. On the day of admission to the clinic, a tumor 2 cm in diameter, painless and mobile, was confirmed to be present in the right preauricular area. The morphology and color of the skin above the lesion were not different to those of the surrounding area. The examination did not show any features of peripheral paresis or paralysis of the facial nerve. The patient's general condition was good and laboratory tests did not show any significant anomalies. An ambulatory neck ultrasonography showed a solid 14 mm × 16 mm × 23 mm change in the right parotid gland in the area of the palpable lesion.

Computed neck tomography showed a T1- and T2-dependent low-contrast lesion of 14 mm × 15 mm × 20 mm in the superficial lobe of the right parotid gland, reacting to contrast to a higher degree than the gland parenchyma. An intrahospital oligobiopsy (core biopsy) of the lesion with ultrasonographic monitoring, under general anesthesia, was conducted. The results of the histopathological examination of the oligobiopsy were that on the basis of immunohistochemical tests (MC, EMA, CEA, c-kit, S-100, SMA, Bcl-2, vimentin, CD10 and Ki-67), the cytological picture suggested a parotid gland epithelial tumor. The differential diagnosis should confirm

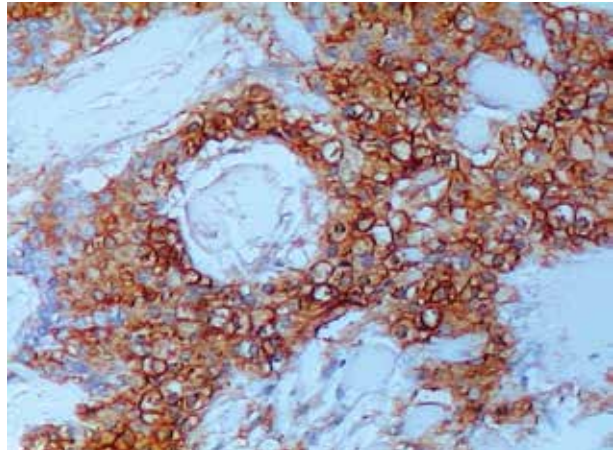


Fig. 1. Mucoepidermoid carcinoma of the parotid gland. Visible epithelial tumor cells. EMA staining. Original magnification 200×

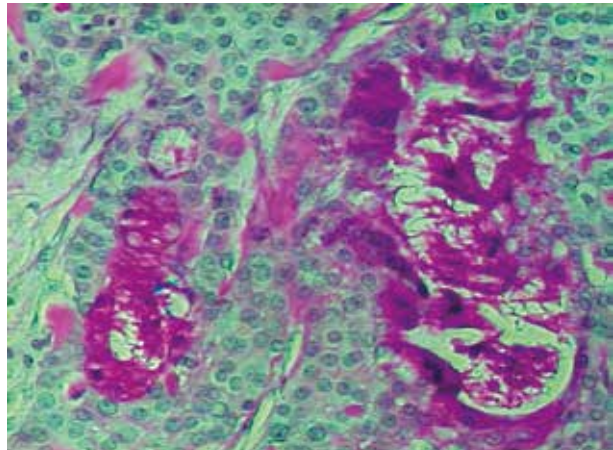


Fig. 2. Mucoepidermoid carcinoma of the parotid gland. Visible PAS positive staining in mucous (tumor) cells. PAS staining. Original magnification 200×

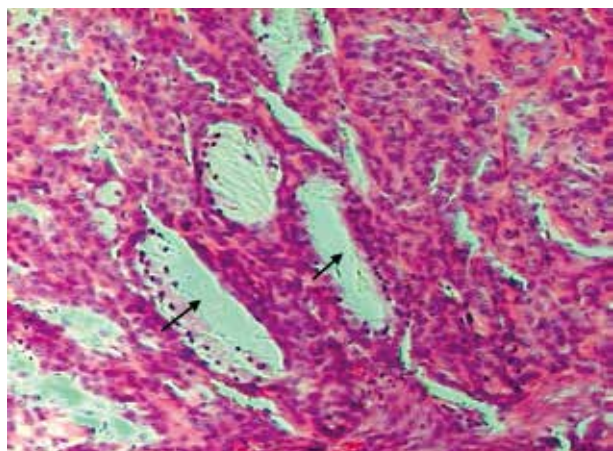


Fig. 3. Mucoepidermoid carcinoma of the parotid gland. Visible sheaths of tumor cells with clear (mucous) cytoplasm. Original magnification 100×

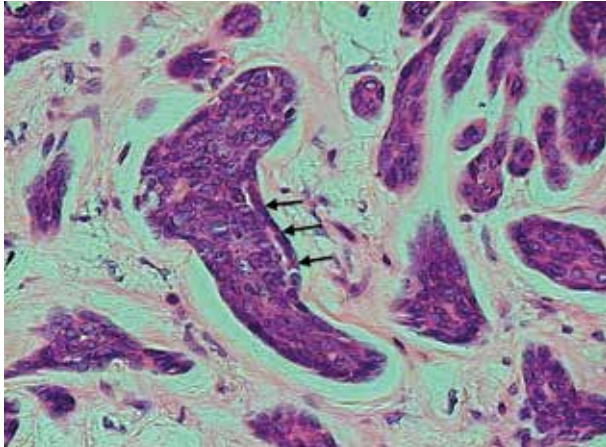


Fig. 4. Basal cell adenoma of the parotid gland. Visible basal tumor cells at the border of the tumor focus. Original magnification 200×

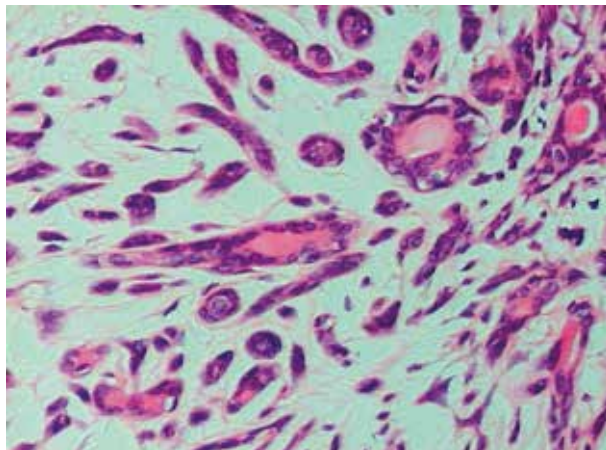


Fig. 5. Basal cell adenoma of the parotid gland. Visible small group of tumor cells. Original magnification 200×

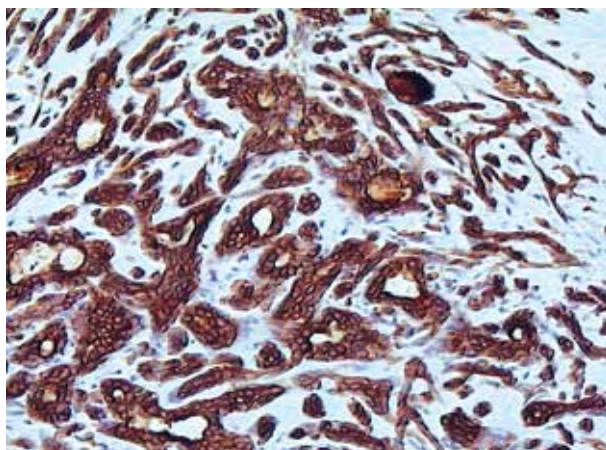


Fig. 6. Basal cell adenoma of the parotid gland. AE1/AE3 staining. Original magnification 100×

adenoid cystic carcinoma, polymorphous low-grade adenocarcinoma or cellular pleomorphic adenoma. However, a second stage histopathological examination showed no such diagnosis at this stage.

On the basis of the clinical examination and supplementary tests, the girl was qualified for a right side superficial parotidectomy. During the surgical procedure, a tumor of 2 cm, together with the superficial lobe of the right parotid gland, was removed. During macroscopic postoperative examination, the tumor did not show any macroscopic signs of malignancy. The results of the histopathological examination revealed that the microscopic picture was not typical, while the immunohistochemical tests [MC, vimentin, Bcl-2, CEA, C-kit, S-100, SMA, CD-12, low index of Ki-67 (2%)] indicated a diagnosis of myoepithelial predominant pleomorphic adenoma. The tumor was covered with a thin capsule made of connective tissue. Differential diagnosis should confirm polymorphous low-grade adenocarcinoma or adenoid cystic carcinoma.

The results of second stage histopathological examination indicated the presence of a basal cell adenoma of the parotid gland. A tumor of the coil-duct was built with small areas of membranous growth. The encapsulated lesion was completely excised. Tests revealed the immunophenotype to be CKAE1/AE3+, p63, S-100 in myoepithelial cells were present, CD117 and GFAP were negative, PAS focally was positive, and Ki-67 was present in about 2% of cells. The girl has been under observation by the outpatient clinic for 6 months and no signs of recurrence have been found (Figs. 4-7).

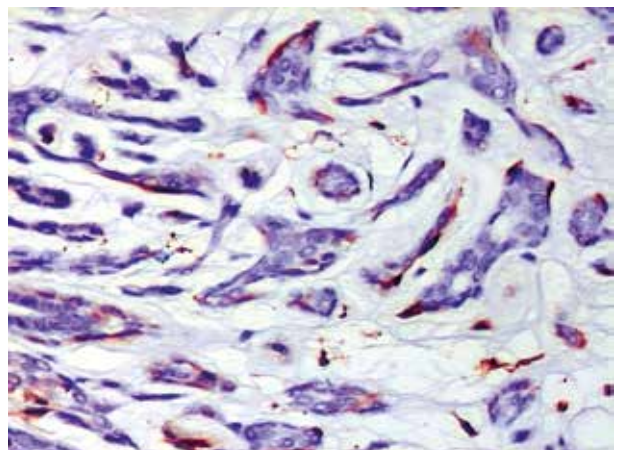


Fig. 7. Basal cell adenoma of parotid gland. Visible singular "positive" cells at the periphery of tumor foci. S100 protein staining. Original magnification 200×

Discussion

Parotid gland tumors in children often show problems connected with the preoperative diagnostics. The tumors are rare, and in the case of a suspicious mass being found in the glands, special care should be provided by general practitioners so as to shorten the time between first sight of the disease and the operational treatment. Confirming tumor changes of the salivary gland requires precise diagnostic imaging involving an ultrasonography scan and, sometimes, computed tomography and magnetic resonance imaging.

In computed tomograph scans, these tumors are defined as clearly separated and moderately saturated formations. However, in magnetic resonance imaging, the presence of a tumor is suggested by a mass whose saturation is greater than that of salivary gland tissues, but lower than those found in the lymph node area, and which is usually well separated from the area [8].

In histopathological preoperative diagnostics, NAB of a tumor and, if possible, ultrasonographic observation are of high importance. The specificity of fine-needle aspiration cytology for diagnosing malignant salivary gland tumors is 96% [9]. Many authors stress the necessity of careful histopathological evaluation of the preoperative NAB, as well as the importance of taking repeated samples to confirm the preoperative diagnosis [10].

However, despite the use of established diagnostic principles and clinical evaluation, the results of imaging studies and a pathomorphological NAB do not always eliminate malignant processes [11, 12]. The first case given in this study is an example of such a preoperative misdiagnosis. A specific diagnosis with NAB can only be made in approximately 60-75% of cases but a core biopsy may improve the accuracy of the preoperative diagnosis, confirming postoperative diagnosis in 97% of cases [13]. However, the main complications of the procedure are facial nerve paralysis/paresis and bleeding with hematoma formation. To avoid facial nerve paralysis/paresis, ultrasonographic monitoring is advised, though the facial nerve cannot be identified [14]. An alternative method of avoiding this complication is to use the parotid duct as a landmark for localizing a superficial mass or mass located deep under the facial nerve. In most cases, the hemorrhage is related to the cystic components of the tumor. It occurs in 67-93% of cases [15].

The principles of operational treatment of epithelial tumors of the major salivary gland in children do not differ from those in adults. Benign tumors of the parotid gland in most cases require the excision of the superficial lobe. However, when preoperative histopathological diagnosis confirms the presence of a ma-

lignant tumor, the operation includes a total parotidectomy. In cases of a confirmed malignant lesion, a radical excision of the parotid gland is performed. The essential problems concerning total excision are the high probability of breaking the facial nerve, and the necessity of nerve fragment excision in the case of infiltration [16]. Many authors believe that in the case of the most common benign tumor, a superficial pleomorphic adenoma, partial parotidectomy should be performed. In their view, it greatly reduces the recurrence rate of the tumor, but at the same time it may damage the facial nerve.

Another approach, extracapsular excision of the tumor, is more effective at separating and sparing the facial nerve. This method, used in the first case described in this report, reduces the number of complications, among which Frey syndrome is the most common [17]. It was shown not to complicate a complete parotidectomy procedure performed after detection of a malignant tumor in samples removed during the first surgery.

In cases of malignant tumors, when there is a suspicion that there are metastases to the lymph nodes, their excision is necessary. Sometimes surgical excision is followed by radiotherapy, yet most authors consider surgical treatment to be the only necessary therapeutic management, especially in children, because of the negative consequences of the radiation therapy on their development. Chemotherapy is not used in cases of malignant major salivary gland tumors in children [18]. Total parotidectomy proved to be successful treatment in the case of the boy with mucoepidermoid carcinoma of the parotid gland, and augmentation therapy was not necessary.

The authors declare no conflict of interest.

References

1. Callender DL, Frankenthaler RA, Luna MA, et al. Salivary gland neoplasms in children. *Arch Otolaryngol Head Neck Surg* 1992; 118: 472-476.
2. Ellies M, Laskawi R. Diseases of the salivary glands in infants and adolescents. *Head Face Med* 2010; 6: 1.
3. Ridder GJ, Richter B, Laszig R, Sander A. Parotid involvement in cat scratch disease: a differential diagnosis with increased significance. *Laryngorhinootologie* 2000; 79: 471-477.
4. Shapiro NL, Bhattacharyya N. Clinical characteristics and survival for major salivary gland malignancies in children. *Otolaryngol Head Neck Surg* 2006; 134: 631-634.
5. Ribeiro Kde C, Kowalski LP, Saba LM, de Camargo B. Epithelial salivary glands neoplasms in children and adolescents: a forty-four-year experience. *Med Pediatr Oncol* 2002; 39: 594-600.
6. da Cruz Perez DE, Pires FR, Alves FA, et al. Salivary gland tumors in children and adolescents: a clinicopathologic and immunohistochemical study of fifty-three cases. *Int J Pediatr Otorhinolaryngol* 2004; 68: 895-902.

7. Shikhani AH, Johns ME. Tumors of the major salivary glands in children. *Head Neck Surg* 1988; 10: 257-263.
8. Rahbar R, Grimmer JF, Vargas SO, et al. Mucoepidermoid carcinoma of the parotid gland in children: A 10-year experience. *Arch Otolaryngol Head Neck Surg* 2006; 132: 375-380.
9. Daneshbod Y, Daneshbod K, Khademi B. Diagnostic difficulties in the interpretation of fine needle aspirate samples in salivary lesions: diagnostic pitfalls revisited. *Acta Cytol* 2009; 53: 53-70.
10. Brennan PA, Davies B, Poller D, et al. Fine needle aspiration cytology (FNAC) of salivary gland tumours: repeat aspiration provides further information in cases with an unclear initial cytological diagnosis. *Br J Oral Maxillofac Surg* 2010; 48: 26-29.
11. Cordoba F, Pinera JG, De La Torre JP, et al. Parotid gland's tumors in children. *Cir Pediatr* 2008; 21: 27-31.
12. Behzatoglu K, Bahadir B, Kaplan HH, et al. Fine needle aspiration biopsy of the parotid gland. Diagnostic problems and 2 uncommon cases. *Acta Cytol* 2004; 48: 149-154.
13. Ellis GL, Auclair PL. Tumours of the salivary glands. 3rd ed. Washington 1996.
14. Wan YL, Chan SC, Chen YL, et al. Ultrasonography-guided core-needle biopsy of parotid gland masses. *AJNR Am J Neuroradiol* 2004; 25: 1608-1612.
15. Wan YL, Cheung YC, Lui KW, et al. Sonographic analysis of salivary gland masses. *J Med Ultrasound* 2003; 11: 1-6.
16. Terhaard C, Lubsen H, Tan B, et al. Facial nerve function in carcinoma of the parotid gland. *Eur J Cancer* 2006; 42: 2744-2750.
17. McGurk M, Thomas BL, Renehan AG. Extracapsular dissection for clinically benign parotid lumps: reduced morbidity without oncological compromise. *Br J Cancer* 2003; 89: 1610-1613.
18. Shashinder S, Tang IP, Velayutham P, et al. A review of parotid tumours and their management: a ten-year-experience. *Med J Malaysia* 2009; 64: 31-33.

Address for correspondence

Rafał Zieliński
 Department of Paediatric Otolaryngology,
 Phoniatria and Audiology
 Medical University of Lodz
 Sporna 36/50
 91-738 Łódź, Poland
 e-mail: rafal.zielinski@umed.lodz.pl