

## ORIGINAL PAPER

**THE VALUE OF TUMOR MARKERS IN THE DIAGNOSIS OF PAPILLARY THYROID CARCINOMA ALONE AND IN COMBINATION**HENG MA<sup>1</sup>, SANPENG XU<sup>1</sup>, JIN YAN<sup>2</sup>, CHAO ZHANG<sup>1</sup>, SHENGHUI QIN<sup>1</sup>, XI WANG<sup>1</sup>, NAPING LI<sup>1</sup><sup>1</sup>The Institute of Pathology, Tongji Hospital, Tongji Medical College, Huazhong University of Science and Technology, Wuhan, PR China<sup>2</sup>Tongji Hospital, Tongji Medical College, Huazhong University of Science and Technology, Wuhan, PR China

Aim of the study is to evaluate the expression of CK19, galectin-3, HBME-1, CD56, claudin-1 and neutrophil gelatinase-associated lipocalin (NGAL) in papillary thyroid carcinoma (PTC), including classic, follicular variant and micro-carcinoma. Peritumoral benign thyroid tissues were used as a control (C).

Immunohistochemical staining with the EnVision detection system was performed on 59 formalin-fixed, paraffin-embedded thyroid tissues, including 43 PTC and 16 C.

CK19, galectin-3, HBME-1, claudin-1 and NGAL were positive in most PTC, but were negative or showed focal weak staining in C. CD56 was positive in C, but absent in PTC. For a single analyzed tumor marker, the sensitivity of the above six thyroid tumor markers was 100%, 95.3%, 86%, 79.1%, 90.7%, 93%, respectively. The specificity was 56.25%, 100%, 100%, 100%, 100%, 100%, respectively. For the combination of the six tumor markers, the sensitivity, specificity, positive predictive value, negative predictive value and the diagnostic accuracy were all 100%, with co-expression of at least four indices.

In the diagnosis of PTC, combined application of the above tumor markers is recommended. It can be diagnosed as PTC clearly when thyroid lesions are positive for at least four of the above tumor markers [CD56(-)], and can be excluded as PTC definitely when at least four tumor markers are negative [CD56(+)].

**Key words:** papillary thyroid carcinoma, CK19, galectin-3, HBME-1, CD56, claudin-1, NGAL.

**Introduction**

Papillary thyroid carcinoma (PTC) is the most prevalent form of thyroid cancer comprising approximately 80% of thyroid epithelial malignancies [1]. The diagnostic criteria for PTC have been established for more than 50 years [2], pathologic examination through routine hematoxylin and eosin (HE) staining was the 'gold standard' diagnosis of PTC [3]. The diagnosis of typical PTC is easy to achieve through conventional histological evaluation, but for follicular variant or papillary thyroid microcar-

cinoma, especially in cases without obvious invasion, metastasis or stromal desmoplasia, or unsatisfactory sections, it is usually a great challenge. Taking into account that over- or under-diagnosis may have a great impact on patient management and prognosis, it is necessary to use immunohistochemical staining with effective tumor markers as an auxiliary diagnostic tool to discriminate these morphologically overlapping diseases.

With high sensitivity and specificity, positive staining panel of galectin-3, mesothelial antigen HBME-1 and cytokeratin-19 (CK19) have been proved to be

the most promising and most frequently used molecular markers in identifying papillary thyroid cancer, including follicular variant [4, 5]. They were first preferred in many hospitals for their ease of use [4]. CD56, as a neural cell adhesion molecular [6], was also proved to be frequently expressed in normal thyroid tissues but absent in malignant thyroid tumors, especially in PTC [3, 7].

Claudin-1, a novel marker for PTC, is identified as a tight junction component. It belongs to the claudin family [8]. Several lines of evidence at the gene [9, 10] and protein [7, 11] level showed that the expression of claudin-1 was elevated in PTC, whereas, it was absent or weak staining on the membrane of normal and benign thyroid lesions. Another new detector for PTC is neutrophil gelatinase-associated lipocalin (NGAL), also known as neu-related lipocalin (NRL), oncogene 24p3, uterocalin and lipocalin 2 (LCN2) [12]. It is involved in cancerogenesis and cancer progression by increasing iron uptake from the extracellular space to inner cells which is essential for neoplastic cell multiplication [13]. Barresi *et al.* [13, 14] reported that NGAL expression appeared to be significantly more frequent in the malignant thyroid tumors than in benign ones, the later including follicular adenomas, Hürthle cell adenomas and atypical adenomas. What is more, no NGAL staining was found in the normal thyroid gland, nodular colloid goiters or in Hashimoto's thyroiditis. Hence, NGAL and claudin-1 might constitute an effective auxiliary diagnosis index in the discrimination of thyroid carcinoma.

Hence, immunohistochemical staining with the above six thyroid tumor markers was designed to compare their expression in PTC (including classic, follicular, and micro variant) with peritumoral benign thyroid tissues (C), and to evaluate their value in the diagnosis of PTC alone and in combination.

## Material and methods

### Materials

All materials for this experiment were collected from the Pathology Department of Tongji Hospital

affiliated to Tongji Medical College of Huazhong University of Science and Technology. According to diagnostic criteria based on the World Health Organization Histological Classification (2003), 59 specimens of surgically removed, formalin-fixed and paraffin-embedded thyroid lesions during the period of January 2011 to March 2013 were selected, including 43 cases of PTC and 16 peritumoral benign thyroid tissues (C). Regarding to the histological subtype of PTC, 15 cases were classic variant (PTC-C), 21 follicular variants (PTC-FV) and 7 papillary thyroid microcarcinoma (PTMC). Three males and 40 females were included, ranging from 16 to 63 years old (mean:  $39.58 \pm 11.052$  years).

### Immunohistochemistry

Immunohistochemical staining with the EnVision detection system was performed on consecutive sections ( $4 \mu\text{m}$  thick) from each archival tissue block. Primary antibodies, sources, and dilutions are listed in Table I. According to the manufacturer's instructions, all sections were deparaffinized with xylene, and rehydrated through a series of descending graded alcohols. Antigen retrieval was performed in 1 mM EDTA pH 8.0 (CK19, galectin-3, CD56, claudin-1) or in citrate buffer pH 6.0 (NGAL) in a pressure cooker for 1.5 minutes at  $120^\circ\text{C}$ . Sections did not undergo the antigen retrieval program with HBME-1. Endogenous peroxidase activity was blocked by using 3%  $\text{H}_2\text{O}_2$  for 20 min. They were then incubated with primary antibody for 1 hour at room temperature, followed by a peroxidase-conjugated polymer (Dako REAL EnVision/HRP, Rabbit/Mouse (ENV) reagent of the kit k5007, Denmark) for 30 min. To reveal the immune staining, the sections were incubated with Dako REAL DAB+ Chromogen for 5 min (Dako k5007, Denmark), followed by counterstaining with hematoxylin, then dehydration and mounting. Slides were examined using a BX50 optical microscope (Olympus, Japan) with a SPOT-II digital imaging software (DIAGNOSTIC Instruments, inc. USA). Normal human skin was used as a positive control for claudin-1, human colon tissue for lipocalin 2 (NGAL), gastroin-

Table I. Properties of primary antibodies used in the study

ANTIGEN	CLONE	SOURCE	DILUTION	SUPPLIER
Cytokeratin 19	MAB-0056	Mouse mAb	Ready-to-use	Maixin-BIO China
Galectin-3	MAB-0572	Mouse mAb	Ready-to-use	Maixin-BIO China
CD56	MAB-0256	Mouse mAb	Ready-to-use	Maixin-BIO China
HBME-1	GM350504	Mouse mAb	Ready-to-use	Gene Tech, China
Claudin-1	ZA-0365	Rabbit pAb	Ready-to-use	ZSGB-BIO, China
Lipocalin 2 (NGAL)	ab41105	Rabbit pAb	1 : 200	Abcam, UK

*mAb* – monoclonal antibody, *pAb* – polyclonal antibody

testinal stromal tumor for HBME-1, and neuroblastoma tissue for CD56. A classic PTC known to react diffusely and strongly with CK19 and galectin-3 was used as the positive control. PBS was used as a negative control instead of the primary antibody.

### Evaluation of immunohistochemical staining

The results of immunohistochemical staining were assessed by two pathological professors and a consensus regarding controversial cases was reached at a multiheaded microscope. The cells were regarded as positive for these proteins when immunoreactivity was clearly observed in their nuclei, membrane and/or cytoplasm. Staining of the follicular colloid in the absence of staining of the follicular epithelium was considered nonspecific and negative. We used a semi-quantitative scoring method for each immunohistochemical marker with the cut-off values based on data published previously [4, 11, 14-17] and the clinical experience of the pathologists involved (Naping Li and Xi Wang). The percentage of positive cells for each section was counted under 5 high power fields, and the mean value of each case was scored as follows: 0, staining in < 10% of the cells; 1, staining in 10-25% of the cells; 2, staining in 26-50% of the cells; 3, staining in > 50% of the cells. A score of 0 was considered as negative, and scores of 1 to 3 were considered as positive.

All statistics were analyzed using SPSS version 18.0. Fisher's exact probability test was used for significance analysis ( $p < 0.05$ ). In addition, the sensitivity, specificity, positive predictive value, negative predictive value and the diagnostic accuracy for each index were assessed as follows:

sensitivity = true positive / (true positive + false negative); specificity = true negative / (true negative + false positive); positive predictive value = true positive / (true positive + false positive); negative predictive value = true negative / (true negative + false negative); the diagnostic accuracy = (true positive + true negative) / (true positive + true negative + false negative + false positive).

## Results

### Immunolocalization of the above six thyroid tumor markers in follicular epithelium

As shown in Fig. 1, CK19, galectin-3 and NGAL mainly expressed in the cytoplasm; at the same time, Galectin-3 and NGAL also showed occasional nuclear expression (Fig. 1B-D top). Claudin-1 expressed mainly on the membrane surface, accompanied by weak cytoplasm positive expression (Fig. 1E). CD56 often showed strong and complete membrane expression in benign thyroid follicular cells, especially the benign cells adjacent to tumor regions (Fig. 1F

lower left side). The expression of HBME-1 is mainly on the membrane, which is at the luminal side, papillary or the lateral membranous surface, with or without the cytoplasm and the content of glandular cavity staining positive (Fig. 1G upper right side).

### The expression of the above six tumor markers in PTC and benign thyroid tissues alone and in combination

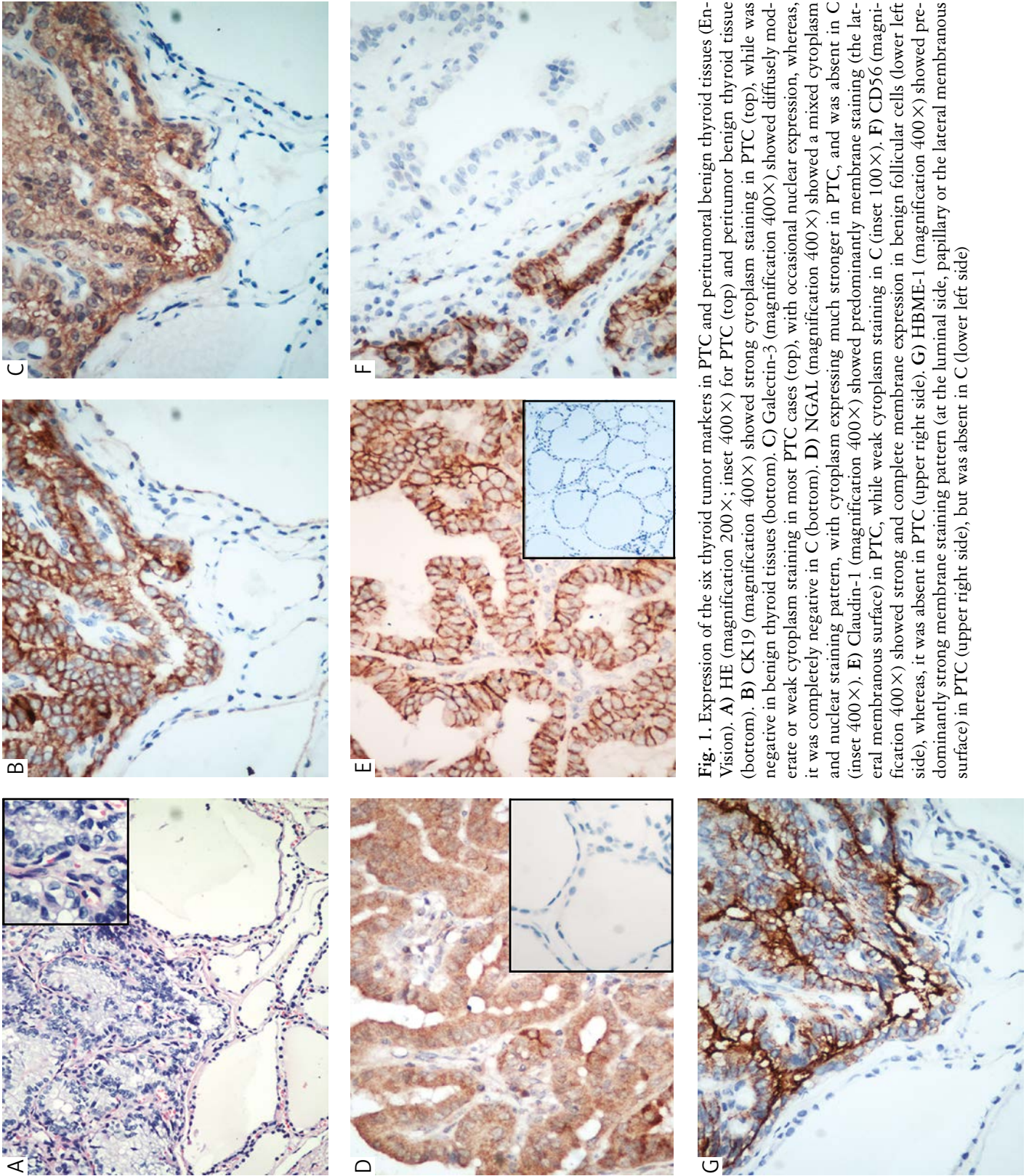
CK19 was positive in all cases of PTC, among which 39 cases (88.37%) showed moderate or strong and diffuse expression (Fig. 1B top), while in 16 C tissues only 7 cases were moderate to weakly positive. Galectin-3 was positive in 41/43 cases of PTC (95.3%), among which 24 cases showed a weak but diffuse staining pattern (Fig. 1C top), whereas in 16 C, galectin-3 was completely negative (Fig. 1C bottom). With high sensitivity (95.3%) and specificity (100%), galectin-3 was an appropriate indicator to differentiate PTC from benign thyroid lesions.

Besides CK19 and galectin-3, NGAL also frequently (33/43) showed moderate or strong expression in PTC tissues (Fig. 1D), only 3 PTC being negative for NGAL, while all 16 C cases were negative for NGAL (Fig. 1D inset). In addition, the content of follicular cavities in C also showed occasional NGAL protein expression, while in tumors with follicular structure (such as PTC-FV), it was absent. In a word, all these features of NGAL may contribute to differentiating malignant thyroid tumors from benign lesions. Furthermore, 90.7% of PTC was positive for claudin-1, among which 74.42% (32/43) was moderate to strongly positive (Fig. 1E). In 16 C, claudin-1 was absent or showed a weak cytoplasm staining pattern which was also considered as negative (Fig. 1E inset). Hence, claudin-1 was also proved to be a novel effective auxiliary diagnostic indicator for the evaluation of PTC.

In our research, CD56 often showed moderate to strong expression in all C tissues (Fig. 1F lower left side) (specificity 100%), whereas in PTC, 79.1% (34/43) of cases were completely negative or showed focal weak staining pattern (Fig. 1F upper right side). In short, CD56 was a good negative indicator for the diagnosis of PTC. HBME-1 was diffusely positive in 86% (37/43) of cases of PTC (Fig. 1G upper right side). In contrast, 16 C tissues were completely negative for HBME-1 (Fig. 1G lower left side). Hence, one can see, with high sensitivity and specificity, HBME-1 is also a good marker to differentiate PTC from C.

The expression of CK19, galectin-3, HBME-1, CD56, claudin-1 and NGAL in PTC and C is shown in Table II. Fisher's exact probability test showed that the differences for the expression of the above six thyroid tumor markers between PTC and C were all statistically significant (all  $p < 0.001$ ). In addition, no statistically significant difference for the expression





**Fig. 1.** Expression of the six thyroid tumor markers in PTC and peritumoral benign thyroid tissues (En-Vision). **A)** HE (magnification 200×; inset 400×) for PTC (top) and peritumoral benign thyroid tissue (bottom). **B)** CK19 (magnification 400×) showed strong cytoplasm staining in PTC (top), while was negative in benign thyroid tissues (bottom). **C)** Galectin-3 (magnification 400×) showed diffusely moderate or weak cytoplasm staining in most PTC cases (top), with occasional nuclear expression, whereas, it was completely negative in C (bottom). **D)** NGAL (magnification 400×) showed a mixed cytoplasm and nuclear staining pattern, with cytoplasm expressing much stronger in PTC, and was absent in C (inset 400×). **E)** Claudin-1 (magnification 400×) showed predominantly membrane staining (the lateral membranous surface) in PTC, while weak cytoplasm staining in C (inset 100×). **F)** CD56 (magnification 400×) showed strong and complete membrane expression in benign follicular cells (lower left side), whereas, it was absent in PTC (upper right side). **G)** HBME-1 (magnification 400×) showed predominantly strong membrane staining pattern (at the luminal side, papillary or the lateral membranous surface) in PTC (upper right side), but was absent in C (lower left side)

of CK19, galectin-3, HBME-1, CD56, claudin-1 and NGAL were detected among three different subtypes of PTC (classic, follicular variant and micro-carcinoma), which means that the three different subtypes of PTC basically shared the same immune phenotype with each other (Table III).

As shown in Table IV, for the combination of the above 6 tumor markers, the sensitivity, specificity,

positive predictive value, negative predictive value and diagnostic accuracy were 53.49%, 56.3%, 76.7%, 31% and 54.2%, separately, with six indicators' co-expression; with at least five indicators' co-expression, the sensitivity, specificity, positive predictive value, negative predictive value and the diagnostic accuracy were 93.02%, 100%, 100%, 84.2% and 94.9%, respectively; with at least four indicators'

**Table II.** The expression of the six thyroid tumor markers in PTC and peritumoral benign thyroid tissues

SPECIES	PTC N = 43 (%)	BENIGN THYROID TISSUES N = 16 (%)	FISHER EXACT PROBABILITY TEST
CK19(+)	43 (100)	7 (43.75)	All values of p < 0.01
Galectin-3(+)	41 (95.3)	0 (0)	
HBME-1(+)	37 (86)	0 (0)	
CD56(+)	9 (20.9)	16 (100)	
Claudin-1(+)	39 (90.7)	0 (0)	
NGAL(+)	40 (93)	0 (0)	

*n* – the number of cases, PTC – papillary thyroid carcinoma

**Table III.** The expression of six thyroid tumor markers among three different subtypes of PTC

SPECIES	PTC			FISHER EXACT PROBABILITY TEST
	PTC-C N = 15 (%)	PTC-FV N = 21 (%)	MPTC N = 7 (%)	
CK19(+)	15 (100)	21 (100)	7 (100)	All values of p > 0.05
Galectin-3(+)	13 (86.7)	21 (100)	7 (100)	
HBME-1(+)	11 (73.3)	20 (95.2)	6 (85.7)	
CD56(+)	2 (13.3)	4 (19)	3 (42.9)	
Claudin-1(+)	14 (93.3)	18 (85.7)	7 (100)	
NGAL(+)	15 (100)	19 (90.5)	6 (85.7)	

*n* – the number of cases, PTC – papillary thyroid carcinoma, PTC-C – papillary thyroid carcinoma-classic, PTC-FV – papillary thyroid carcinoma-follicular variant, MPTC – papillary thyroid micro-carcinoma

**Table IV.** The significance of the six thyroid tumor markers in the diagnosis of PTC

SPECIES	SENSITIVITY %	SPECIFICITY %	PP %	NP %	ACCURACY %
CK19	100	56.25	86	100	88.1
Galectin-3	95.3	100	100	88.9	96.6
HBME-1	86	100	100	72.7	89.8
CD56	79.1	100	64	100	84.7
Claudin-1	90.7	100	100	80	93.2
NGAL	93	100	100	84.2	94.9
Co-expression of at least four species	100	100	100	100	100
Co-expression of at least five species	93.02	100	100	84.2	94.9
Co-expression of six tumor markers	53.49	56.3	76.7	31	54.2

PP – positive predictive value, NP – negative predictive value, Accuracy – the diagnostic accuracy

co-expression, the sensitivity, specificity, positive predictive value, negative predictive value and the diagnosis accuracy were all 100%. In the light of the results above, we can see that all PTC cases had at least four of the above tumor markers' co-expression, whereas all C tissues were negative for at least four of the above tumor markers (CD56 was negative in PTC and positive in C).

## Discussion

Although CK19, galectin-3, HBME-1, CD56, claudin-1 and NGAL have all been shown to have high sensitivity and specificity in discrimination of PTC from benign thyroid lesions, the results varied among studies. In addition, in clinical work-up, how to best use these tumor markers has not been addressed fully.

In our research, CK19, the most sensitive marker for PTC, is consistently over-expressed in all PTC (100%). Focal or scattered CK19 staining may be found in benign lesions (including follicular adenoma and nodular goiter), but only diffusely and strongly CK19 positive staining has diagnostic value for PTC [5, 18]. In accordance with previous reports [5, 18], the specificity of CK19 is 56.25% (9/16), which is the lowest in this experiment. The majority of the immunoreactivity occurred in areas of degeneration, indicating the reactive nature of CK19 positivity [19]. At the same time, with high negative predictive value (100%), we can explicitly exclude the diagnosis of PTC in thyroid lesions without CK19 expression.

Galectin-3 is a  $\beta$ -galactoside-binding animal lectin which participates in cell-cell and cell-matrix adhesion, cell growth and cell cycle regulation, neoplastic transformation, metastasis, cellular damage repair and apoptosis [17]. It has been noted to be expressed in PTC and transformed thyroid cell lines but not in normal thyroid cells [20, 21]. HBME-1 is a monoclonal antibody developed against the micro-villous surface of mesothelial cells and subsequently applied in the diagnosis of malignant thyroid tumors [22]. Galectin-3 and HBME1 have been demonstrated in follicular carcinomas and less frequently in adenomas. In our research, they had the highest specificity and positive predictive value (all were 100%), but several studies have shown galectin-3 expression in benign conditions and FAs, as well as staining inflammatory cells and reactive normal epithelium [5], limiting the usefulness of galectin-3 in discriminating benign disease from PTC. Although HBME-1 was not sensitive enough (86%), it was specific for PTC. Thyroid lesions with HBME-1 strong diffuse positivity can be defined as PTC clearly. In addition, for galectin-3 and HBME-1 expression atypical cases, combined application with other effective tumor markers was necessary.

It is reported that the expression of CD56 is closely related to the differentiation of thyroid epithelium [23]. Consistent with others' research [3, 24], we detected moderate or strong expression of CD56 in all C, while it was negative in 79.1% (34/43) of PTC cases. Lack of CD56 expression in follicular cell-derived papillary carcinomas was extremely helpful in differentiating PTC [3], particularly the follicular variant and microcarcinoma from other follicular-derived neoplasms/lesions. Although it was not sensitive enough (only 79.1%), the negative predictive value was 100%. It can be diagnosed as PTC definitely in thyroid lesions without CD56 expression. It is speculated that CD56 expression was involved in the activation of epithelial mesenchymal transition (EMT) (which contributed to the development of more migratory and invasive cancers), and modulation of genes regulating metastasis as the vascular endothelial growth factor (VEGF) [25, 26]. This could explain the maintained elevated CD56 expression in some PTC cases which may acquire later a more aggressive and metastatic phenotype [7]. However, this also increased the false positive rate, thereby limiting the usefulness of CD56 in the diagnosis of PTC alone.

Claudin-1 was the first member of the claudin family to be identified as a tight junction component [8]. In the research of Németh *et al.* [11] they demonstrated a strong expression of claudin-1 protein in PTC and their regional lymph node metastases contrasted with weak or no expression in follicular thyroid cancers, follicular adenomas, and in the peritumoral non-malignant thyroid tissue. It confirmed that high claudin-1 expression was related to papillary morphology, including the follicular variant [11]. One possible mechanism of claudin-1 over-expression in the development of PTC is that up-regulation or abnormal expression of some claudins may facilitate tumor formation by directly altering the function of TJ through the MEK-2 activation [27] or affect cell signalling pathways by binding domains to ZO-1 [28, 29], which interacts with several signalling proteins related to the neoplastic process, such as Ras substrate AF-6, G-protein and connexin. In contrast with previous reports [7, 11], we occasionally found claudin-1 expression on the cytoplasm of atypical follicular cells in C. This may be explained by claudin-1 being a four-time trans-membrane protein [30], so there should be claudin-1 staining on the cytoplasm near the membrane. But if sections were made unsatisfactorily or claudin-1 is located on both the membrane and cytoplasm, it may interfere with our clear analysis of claudin-1 immune location, thereby affecting the usefulness of claudin-1 in the diagnosis of PTC.

Neutrophil gelatinase-associated lipocalin, a protein secreted by human thyroid carcinomas, is induced by the same factors that promote the development of cancer [31]. Nuclear factor- $\kappa$ B contributes to thy-



roid tumor cell survival by controlling iron uptake via NGAL [32]. In addition, NGAL may induce cancer progression through the positive modulation of matrix metallo-proteinase-9 (MMP-9) [33], and increase the invasiveness of cancer cells by decreasing E-cadherin-mediated cell-cell adhesion through an iron-dependent mechanism [34]. In line with research by Barresi *et al.* [13, 14], NGAL expression appeared to be specific (100%) for thyroid carcinoma and represented a sensitive method (93%) in PTC in comparison to C. In addition, the content of follicular cavities in C also showed occasional NGAL expression, while in tumors with follicular structure (such as PTC-FV), it was negative. In conclusion, all these features of NGAL can contribute to differentiating malignant tumors from benign lesions. It was noteworthy that all immunohistochemical procedures were repeated several times with an endogenous biotin-free system, but the contents of benign thyroid follicular cavities still occasionally showed NGAL protein expression, which was likely to cause NGAL false positivity in C. Hence, for NGAL staining in atypical cases, the diagnosis of PTC should be cautious, and combined application with other specific tumor markers is essential.

Although the above six indicators are useful, they should be used cautiously as none of them were 100% reliable. In the research of Abd El Atti *et al.* [7], thyroid lesions showed that the claudin-1(+)/CD56(-) panel can be diagnosed as PTC definitely, whereas cases with the claudin-1(+)/CD56(+) panel still cannot be identified as benign or malignant clearly. Combined application of the above six indicators can solve this problem. In our research, all PTC had at least four of the above tumor markers' co-expression, whereas benign thyroid tissues were negative for at least four tumor markers. For the combination of the six above tumor markers, the sensitivity, specificity, positive predictive value, negative predictive value and the diagnostic accuracy were all 100% with at least four tumor markers' co-expression.

*The authors declare no conflict of interest.*

*We give our thanks to all the people who had participated in this study, especially Mrs. Juan Ni and Mr. Cheng Yang for their assistance with this project.*

## References

- Lee JH, Kim Y, Choi JW, Kim YS. The association between papillary thyroid carcinoma and histologically proven Hashimoto's thyroiditis: a meta-analysis. *Eur J Endocrinol* 2013; 168: 343-349.
- Crile GJ, Hazard JB. Relationship of the age of the patient to the natural history and prognosis of carcinoma of the thyroid. *Ann Surg* 1953; 138: 33-38.
- El Demellawy D, Nasr AL, Babay S, Alowami S. Diagnostic utility of CD56 immunohistochemistry in papillary carcinoma of the thyroid. *Pathol Res Pract* 2009; 205: 303-9.
- Paunovic I, Isic T, Havelka M, et al. Combined immunohistochemistry for thyroid peroxidase, galectin-3, CK19 and HBME-1 in differential diagnosis of thyroid tumors. *APMIS* 2012; 120: 368-379.
- de Matos PS, Ferreira AP, de Oliveira Facuri F, et al. Usefulness of HBME-1, cytokeratin 19 and galectin-3 immunostaining in the diagnosis of thyroid malignancy. *Histopathology* 2005; 47: 391-401.
- Lanier LL, Testi R, Bindl J, Phillips JH. Identity of Leu-19 (CD56) leukocyte differentiation antigen and neural cell adhesion molecule. *J Exp Med* 1989; 169: 2233-2238.
- Abd El Atti RM, Shash LS. Potential diagnostic utility of CD56 and claudin-1 in papillary thyroid carcinoma and solitary follicular thyroid nodules. *J Egypt Natl Canc Inst* 2012; 24: 175-184.
- Furuse M, Fujita K, Hiragi T, et al. Claudin-1 and -2: novel integral membrane proteins localizing at tight junctions with no sequence similarity to occludin. *J Cell Biol* 1998; 141: 1539-1550.
- Fluge Ø, Bruland O, Akslen LA, et al. Gene expression in poorly differentiated papillary thyroid carcinomas. *Thyroid* 2006; 16: 161-175.
- Hucz J, Kowalska M, Jarzab M, Wiench M. Gene expression of metalloproteinase 11, claudin 1 and selected adhesion related genes in papillary thyroid cancer. *Endokrynol Pol* 2006; 57 Suppl. A: A18-A25.
- Németh J, Németh Z, Tátrai P, et al. High expression of claudin-1 protein in papillary thyroid tumor and its regional lymph node metastasis. *Pathol Oncol Res* 2010; 16: 19-27.
- Yang J, Goetz D, Li JY, et al. An iron delivery pathway mediated by a lipocalin. *Mol Cell* 2002; 10: 1045-1056.
- Barresi V, Leni A, Tuccari G, Barresi G. Neutrophil gelatinase-associated lipocalin (NGAL) immunohistochemical expression in follicular cell-derived thyroid tumors: a novel diagnostic tool? *Histol Histopathol* 2012; 27: 329-336.
- Barresi V, Vitarelli E, Reggiani Bonetti L, et al. Diagnostic value of neutrophil gelatinase-associated lipocalin (NGAL) immunorexpression in follicular-patterned lesions of the thyroid gland. *Virchows Arch* 2012; 460: 319-325.
- Park WY, Jeong SM, Lee JH, et al. Diagnostic value of decreased expression of CD56 protein in papillary carcinoma of the thyroid gland. *Basic and Applied Pathology* 2009; 2: 63-68.
- Mataraci EA, Özgüven BY, Kabukçuoğlu F. Expression of cytokeratin 19, HBME-1 and galectin-3 in neoplastic and non-neoplastic thyroid lesions. *Pol J Pathol* 2012; 63: 58-64.
- Prasad ML, Huang Y, Pellegata NS, et al. Hashimoto's thyroiditis with papillary thyroid carcinoma (PTC)-like nuclear alterations express molecular markers of PTC. *Histopathology* 2004; 45: 39-46.
- Scognamiglio T, Hyjek E, Kao J, Chen YT. Diagnostic usefulness of HBME1, galectin-3, CK19, and CITED1 and evaluation of their expression in encapsulated lesions with questionable features of papillary thyroid carcinoma. *Am J Clin Pathol* 2006; 126: 700-708.
- Cheung CC, Ezzat S, Freeman JL, et al. Immunohistochemical diagnosis of papillary thyroid carcinoma. *Mod Pathol* 2001; 14: 338-342.
- Fernández PL, Merino MJ, Gómez M, et al. Galectin-3 and laminin expression in neoplastic and non-neoplastic thyroid tissue. *J Pathol* 1997; 181: 80-86.
- Yoshii T, Inohara H, Takenaka Y, et al. Galectin-3 maintains the transformed phenotype of thyroid papillary carcinoma cells. *Int J Oncol* 2001; 18: 787-792.
- Raphael SJ. The meanings of markers: ancillary techniques in diagnosis of thyroid neoplasia. *Endocr Pathol* 2002; 13: 301-311.
- Migita K, Eguchi K, Kawakami A, et al. Detection of Leu-19 (CD56) antigen on human thyroid epithelial cells by an immunohistochemical method. *Immunology* 1991; 72: 246-249.
- El Demellawy D, Nasr A, Alowami S. Application of CD56, P63 and CK19 immunohistochemistry in the diagnosis of

- papillary carcinoma of the thyroid. *Diagn Pathol* 2008; 3: 1-12.
25. Vasko VV, Saji M. Molecular mechanisms involved in differentiated thyroid cancer invasion and metastasis. *Curr Opin Oncol* 2007; 19: 11-17.
  26. Ringel MD. Molecular markers of aggressiveness of thyroid cancer. *Curr Opin Endocrinol Diabetes Obes* 2009; 16: 361-366.
  27. Tan X, Egami H, Ishikawa S, et al. Arrangement of expression and distribution of tight junction protein claudin-1 in cell dissociation of pancreatic cancer cells. *Int J Oncol* 2004; 25: 1567-1574.
  28. Furuse M, Furuse K, Sasaki H, Tsukita S. Conversion of zonulae occludentes from tight to leaky strand type by introducing claudin-2 into Madin-Darby canine kidney I cells. *J Cell Biol* 2001; 153: 263-272.
  29. Resnick MB, Konkin T, Routhier J, et al. Claudin-1 is a strong prognostic indicator in stage II colonic cancer: a tissue microarray study. *Mod Pathol* 2005; 18: 511-518.
  30. Morita K, Furuse M, Fujimoto K, Tsukita S. Claudin multigene family encoding four-transmembrane domain protein components of tight junction strands. *Proc Natl Acad Sci U S A* 1999; 96: 511-516.
  31. Bratt T. Lipocalins and cancer. *Biochim Biophys Acta* 2000; 1482: 318-326.
  32. Iannetti A, Pacifico F, Acquaviva R, et al. The neutrophil gelatinase-associated lipocalin (NGAL), a NF- $\kappa$ B-regulated gene, is a survival factor for thyroid neoplastic cells. *Proc Natl Acad Sci U S A* 2008; 105: 14058-14063.
  33. Yan L, Borregaard N, Kjeldsen L, Moses MA. The high molecular weight urinary matrix metalloproteinase (MMP) activity is a complex of gelatinase B/MMP-9 and neutrophil gelatinase-associated lipocalin (NGAL). Modulation of MMP-9 activity by NGAL. *J Biol Chem* 2001; 276: 37258-37265.
  34. Hu L, Hittelman W, Lu T, et al. NGAL decreases E-cadherin-mediated cell-cell adhesion and increases cell motility and invasion through Rac1 in colon carcinoma cells. *Lab Invest* 2009; 89: 531-548.

### Address for correspondence

Prof. Naping Li  
Tongji Hospital  
Tongji Medical College  
Huazhong University of Science and Technology  
tel. +008613618642687  
fax +008602763892396  
e-mail: 2281640313@qq.com, naping-li@foxmail.com