

ORIGINAL PAPER

SPECTRUM OF BIOPSY-PROVEN RENAL DISEASES IN PATIENTS WITH TYPE 2 DIABETES MELLITUS. A SINGLE CENTER STUDYMALGORZATA WĄGROWSKA-DANILEWICZ¹, MARIAN DANILEWICZ²¹Department of Nephropathology, Medical University of Lodz, Lodz, Poland²Department of Pathomorphology, Medical University of Lodz, Lodz, Poland

This is the first report from Poland documenting biopsy-proven renal diseases in type 2 diabetes mellitus. We analyzed the data of 76 patients with type 2 diabetes who underwent renal biopsy and were diagnosed in the Department of Nephropathology, Medical University of Lodz. The patients were divided into the following three groups according to the histological diagnosis: group I – isolated non-diabetic renal disease (NDRD); group II – NDRD superimposed on underlying diabetic nephropathy (NDRD + DN); and group III – isolated diabetic nephropathy (DN). Non-diabetic renal disease was found in 38 patients (50%), non-diabetic renal disease superimposed on underlying diabetic nephropathy was diagnosed in 11 patients (14.5%), and isolated diabetic nephropathy was seen in 27 patients (35.5%). The most common glomerular lesion found in groups I and II was focal segmental glomerulosclerosis (FSGS). On the basis of clinical and laboratory parameters, differentiating NDRD from DN in diabetic patients is not always obvious. However, our study revealed that hematuria, short duration of diabetes and the absence of diabetic retinopathy in type 2 diabetic patients manifesting renal involvement may suggest NDRD. The only way to distinguish NDRD from DN is histological evaluation of renal tissue.

Key words: diabetic nephropathy, non-diabetic renal disease, renal biopsy.

Introduction

The prevalence of diabetes mellitus (DM) has been increasing worldwide, and diabetic nephropathy (DN) has become the leading cause of end stage renal disease (ESRD) [1]. According to the World Health Organization, the number of diabetics in Poland will increase to 2.2-2.5 million by 2030 [2]. Type 2 diabetes constitutes the majority of cases of diabetes, and accounts for 85% to 90% of all carbohydrate metabolism disorders. The pathogenetic mechanisms involved in the initiation and progression of renal injury in diabetic nephropathy are multifactorial. They include renal hemodynamic abnormalities, particularly elevated glomerular filtration rate (GFR), cap-

illary hydraulic pressure, and persistent hyperglycemia, which induces biochemical abnormalities in the polyol pathway and participates in the formation of advanced products of nonenzymatic glycosylation. Diabetic nephropathy causes injury to each of the cell types in the glomerular tuft [1]. However, injury to the podocytes is crucial for the progression to glomerulosclerosis [3]. The characteristic clinical lesions of diabetic nephropathy encompass heavy proteinuria, hypertension, and renal failure. The most characteristic lesions seen in DN are nodular or diffuse glomerulosclerosis, expansion of mesangium, capillary wall thickening and arteriolar hyalinosis; however, it must be taken into consideration that renal diseases other than diabetic glomerulosclerosis can

occur in diabetic patients. On the other hand, diabetic nephropathy is the most common glomerular lesion that may be complicated by another form of glomerulonephritis. Among patients with type 2 diabetes who had renal biopsy, the prevalence of NDRD varied in the published literature, from 12% to 79% [4, 5, 6, 7, 8, 9, 10]. It is thought that approximately 33% of biopsies with diabetic nephropathy have superimposed glomerular diseases. Mazzucco *et al.* [10] found that at a centre where biopsies were performed in patients with proteinuria > 0.5 g/day regardless of renal dysfunction or hematuria, 64 of 193 type 2 diabetics had nondiabetic glomerular disease, 43 of which were superimposed on diabetic glomerulosclerosis. Concurrent diabetic glomerulosclerosis and membranous glomerulonephritis are the most commonly reported dual glomerular diagnoses [11]. Pathologic evaluation of renal tissue can discriminate diabetic nephropathy from nondiabetic renal disease (NDRD), but nephrologists are often reluctant to perform renal biopsy in patients with diabetes mellitus owing to the potential risk of the procedure. A renal biopsy is generally reserved for diabetic patients who show recent worsening of proteinuria, hematuria or acute renal failure. It should be stressed that discernment of NDRD from diabetic nephropathy is of considerable importance, because the early treatment of renal diseases other than DN in diabetics may reduce progression of chronic kidney disease to ESRD. The aim of the study was to evaluate the incidence of non-diabetic renal disease, non-diabetic renal disease superimposed on underlying diabetic nephropathy and isolated diabetic glomerulosclerosis in patients with type 2 diabetes mellitus. Another purpose was to analyze clinical and laboratory data in relation to histopathology findings. It should be highlighted that this is the first report documenting biopsy-proven renal disease in patients with type 2 diabetes mellitus in Poland.

Material and methods

The material consisted of kidney biopsies obtained for diagnostic purposes from 76 adult patients (52 males and 24 females, mean age \pm SD: 57 \pm 9.4 years) with type 2 diabetes mellitus who had undergone renal biopsy between January 2006 and February 2013, and were diagnosed in the Department of Nephropathology, Medical University of Lodz. Patient age, gender, duration of diabetes, presence of diabetic retinopathy, hypertension, nephrotic syndrome, urinary protein excretion, hematuria, glomerular filtration rate (GFR), and the value of body mass index (BMI) were noted at the time of renal biopsy. The duration of diabetes was defined as the period between the age at onset and age at performing renal biopsy. Hypertension was defined as blood pressure

more than 140/90 mmHg. Indications for renal biopsy were the presence of acute renal insufficiency, hematuria or massive proteinuria.

In all cases renal biopsy specimens were routinely processed by light microscopy, immunofluorescence and electron microscopy. The samples were embedded in paraffin and sectioned at 2 μ m, followed by HE, Masson, periodic acid-Schiff, periodic acid-silver methenamine, and Congo red staining. For immunofluorescence study the samples were sectioned in frozen conditions, followed by staining for IgG, IgA, IgM, C3, C1q, kappa and lambda light chain. The electron microscopy observations were done with JEM 1011 electron microscopy after routine staining. Diabetic nephropathy was diagnosed by experienced renal pathologists by the presence of expansion and intercapillary glomerulosclerosis, with or without the nodular Kimmelstiel-Wilson formation, basement membrane thickening, fibrin caps or capsular drops and arteriolar hyalinosis, supported by immunofluorescence study and electron microscope findings. Pathologic lesions in DN were classified according to the pathologic classification of diabetic nephropathy [12]. Non-diabetic renal disease was categorized following orthodox criteria [13]. On the basis of histology findings the patients were grouped into one of the three categories: group I – isolated non-diabetic renal disease (NDRD); group II – NDRD superimposed on underlying diabetic nephropathy (NDRD + DN); and group III – isolated diabetic nephropathy (DN).

Statistics

All values are expressed as mean \pm standard deviation (SD) or percentages. The differences between groups were assessed using the Mann-Whitney U test. The univariate χ^2 test was used where appropriate (Statistica 8 software, license for Medical University of Lodz, Poland). Results were considered statistically significant if $p < 0.05$.

Results

Renal biopsy showed that among studied cases 38 biopsies (50%) met histological criteria of non-diabetic renal disease (group I), 11 biopsies (14.5%) were found to have non-diabetic renal disease superimposed on underlying diabetic nephropathy (group II), and 27 biopsies (35.5%) showed isolated diabetic nephropathy (group III) (Fig. 1). Clinical and laboratory data in the three studied groups are shown in Table I. Males outnumbered females in all groups. Patients in group I had an average age of 58.2 \pm 9.8 years, whereas patients in group II had an average age of 59.4 \pm 10.3 years, and those in group III had an average age of 60.6 \pm 8.1 years. No statistically significant differences were detected between the three

groups in the age at the time of biopsy, the incidence of hypertension, nephrotic syndrome and BMI value. The duration of diabetes was significantly shorter in group I than in groups II and III (NDRD vs. NDRD + DN $p < 0.001$; NDRD vs. DN $p < 0.001$, respectively). The prevalence of diabetic retinopathy prior to renal biopsy was significantly lower in NDRD patients than in patients with evidence of DN ($p < 0.03$). Urinary protein excretion was significantly lower in patients with NDRD than in patients with NDRD + DN, as well as in patients with DN ($p < 0.04$, and $p < 0.001$, respectively). Microhematuria occurred in 57.9% of patients with NDRD and in 33.3% of patients with DN ($p < 0.04$). Mean GFR was significantly lower in patients with evidence of DN than in NDRD and NDRD + DN groups ($p < 0.006$, and $p < 0.03$, respectively). Histopathological findings in NDRD patients are shown in Table II. Focal segmental glomerulosclerosis (FSGS) (Figs. 2, 3) was the most common histopathological finding, accounting for 34.2% of all the NDRD, followed by membranous nephropathy (Figs. 4, 5), IgA nephropathy, glomerulonephritis with crescents, and minimal change glomerulopathy. In renal biopsies belonging to group II the most common pathological

findings superimposed on underlying DG was FSGS (45.5%), followed by membranous nephropathy (36.4%), and interstitial nephritis (18.1%). Among 27 biopsies with evidence of diabetic glomerulosclerosis histological evaluation revealed class III diabetic nephropathy (nodular sclerosis, Kimmelstiel-Wilson

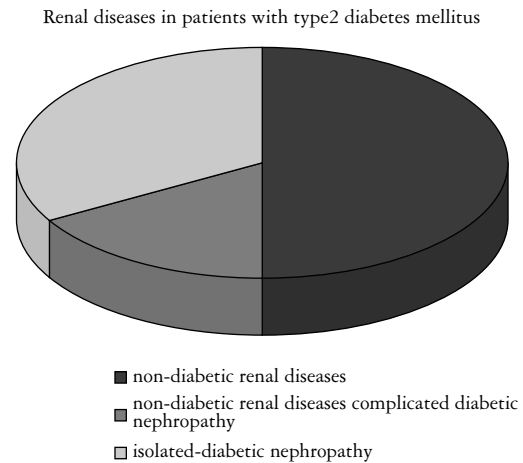


Fig. 1. Biopsy-proven renal diseases in patients with type 2 diabetes mellitus

Table I. Clinical and laboratory data in the three studied groups in diabetic patients

| PARAMETERS | GROUP I (NDRD) (N = 38) | GROUP II (NDRD + DN) (N = 11) | GROUP III (DN) (N = 27) | P-VALUE |
|---------------------------------------|-------------------------------|-------------------------------------|-------------------------------|---|
| Age (years) | 58.2 ± 9.8 | 59.4 ± 10.3 | 60.6 ± 8.1 | NS |
| Gender (M/F) | 26/12 | 8/3 | 16/11 | |
| Duration of diabetes (years) | 5.8 ± 2.3 | 9.2 ± 3.8 | 10.3 ± 4.8 | group I vs. group II < 0.001 group I vs. group III < 0.001 |
| Diabetic retinopathy (%) | 42.1 | 54.5 | 70.4 | group I vs. group II NS group I vs. group III < 0.03 |
| Hypertension (%) | 94.7 | 100 | 100 | NS |
| BMI > 25 (%) | 89.5 | 90.9 | 100 | NS |
| Nephrotic syndrome (%) | 65.8 | 72.7 | 70.4 | NS |
| Mean proteinuria g/24 h | 5.2 ± 2.2 | 7.9 ± 3.7 | 8.7 ± 5.1 | group I vs. group II < 0.04 group I vs. group III < 0.001 |
| Microhematuria (%) | 57.9 | 45.5 | 33.3 | group I vs. group III < 0.04 |
| Mean e-GFR ml/min/1.73 m ² | 44.7 ± 10.3 | 36.2 ± 12.6 | 35.6 ± 15.2 | group I vs. group II < 0.03 group I vs. group III < 0.006 |

NDRD – non-diabetic renal disease; DN – diabetic nephropathy

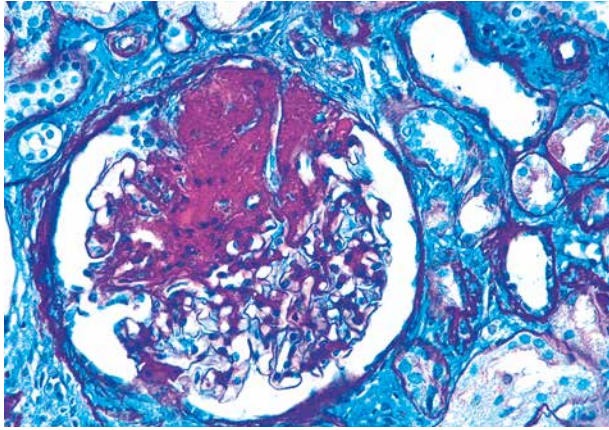


Fig. 2. Focal segmental glomerulosclerosis in patients with type 2 diabetes mellitus. Segmental lesion contains acellular PAS-positive deposit within collapsed glomerular capillaries. PAS staining. Magnification 400×

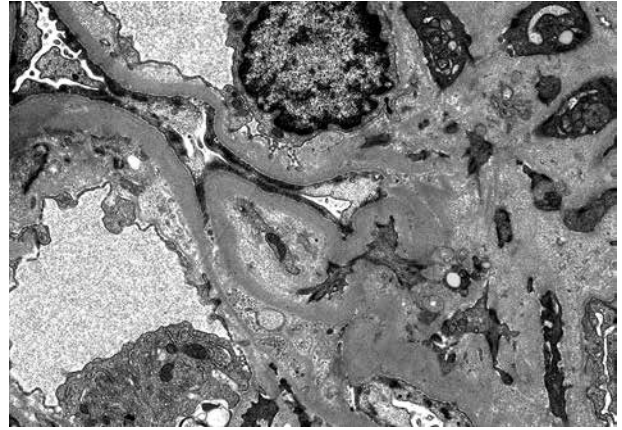


Fig. 3. Focal segmental glomerulosclerosis in patient with type 2 diabetes mellitus. Electron micrograph shows segmental sclerosis and diffuse podocyte foot process effacement. Magnification 10 000×

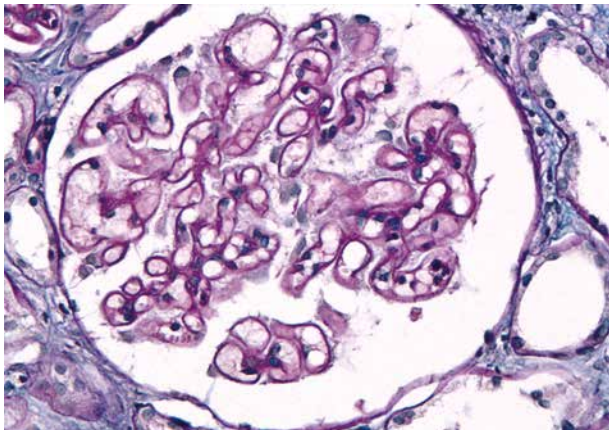


Fig. 4. Membranous nephropathy in patient with type 2 diabetes mellitus. PAS staining shows thickening of the glomerular basement membrane. Magnification 400×

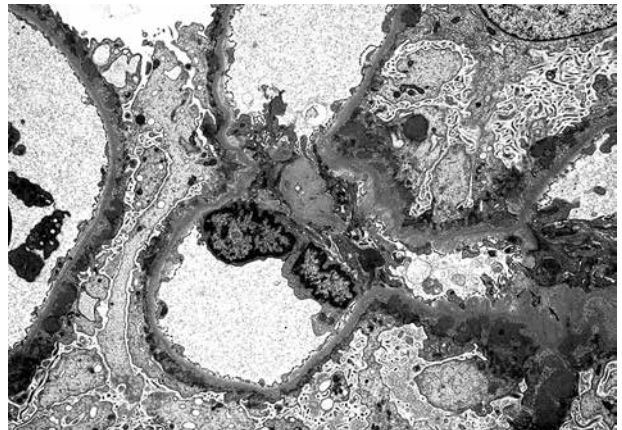


Fig. 5. Membranous nephropathy in patient with type 2 diabetes mellitus. Electron microscopy shows subepithelial deposits consistent with Ehrenreich-Churg stages I and II and podocyte foot process effacement. Magnification 5000×

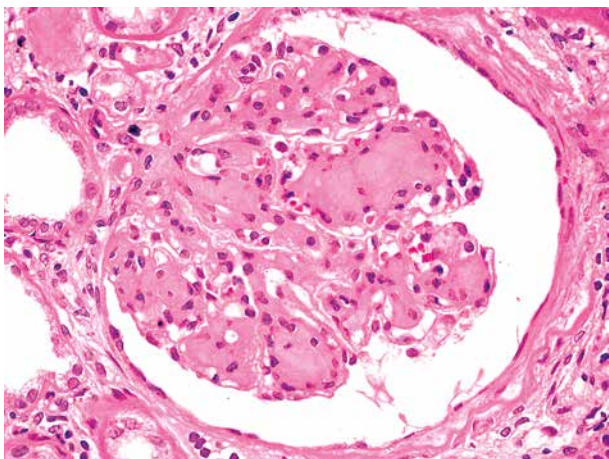


Fig. 6. Classic Kimmelstiel-Wilson nodules in a biopsy from a patient with type 2 diabetes mellitus (class III of pathologic classification of diabetic nephropathy). HE staining. Magnification 400×

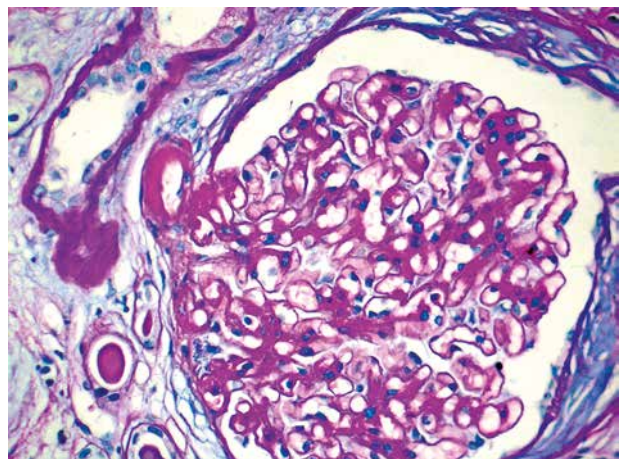


Fig. 7. Renal biopsy in patient with type 2 diabetes mellitus. Enlarged glomerulus with diffuse mesangial sclerosis (class IIb of pathologic classification of diabetic nephropathy). Arteriole hyaline intussusception characteristic for diabetic nephropathy is seen. PAS staining. Magnification 400×

lesions) in 11 cases (40.7%) (Fig. 6), class II b (severe mesangial expansion) in 8 cases (29.6%) (Fig. 7), and class IV (advanced diabetic glomerulosclerosis) in 6 cases (22.2%). Class I and class IIa of diabetic nephropathy were rarely seen in the renal tissue.

Discussion

In this study, renal biopsy findings showed that one-half of patients with type 2 diabetes had non-diabetic renal disease, 14.5% of patients had non-diabetic renal disease superimposed on diabetic nephropathy, whereas 35.5% of patients had isolated diabetic nephropathy. This is in accordance with previous studies of others where the prevalence of NDRD was found to range from 35% to 57% [7, 14, 15]. However, it must be taken into consideration that our results may overestimate the true number of patients with NDRD, because patients were initially selected for renal biopsy owing to a high suspicion of NDRD.

In accordance with other studies, our results showed the preponderance of males in all studied groups [5, 6, 16, 17]. There were no differences in the patient's age at the time of biopsy, the value of BMI, the incidence of hypertension or the incidence of nephrotic syndrome between the three studied groups. In diabetic patients the diagnosis of diabetic nephropathy is almost always based on the presence of diabetic retinopathy, hypertension, progressive decline in renal function and persistent proteinuria without hematuria. It is thought that the validity of this approach is well established in type 1 diabetes mellitus, but not in those with type 2 diabetes [5]. Our study showed that patients with NDRD had shorter duration of diabetes than patients in groups II and III. This is in concordance with Soni *et al.* [5], whereas Bertani *et al.* [18] did not observe a significant difference in the duration of diabetes between NDRD and DN groups. Regarding laboratory parameters in studied groups, our study revealed that in NDRD patients the incidence of microhematuria was higher, whereas protein excretion was lower in comparison with patients with biopsy-proven DN (group III). Mean GFR was significantly lower in patients with evidence of DN than in NDRD and NDRD + DN groups. Nair and Said [19] and Rychlik *et al.* [20] concluded that lower proteinuria was observed to be significant in NDRD, whereas Soni *et al.* [21] revealed that sudden onset of nephrotic proteinuria strongly suggested NDRD.

Our study showed that the incidence of diabetic retinopathy in the NDRD group was lower than in the isolated DN group. However, it must be stressed that about 30% of patients with biopsy-proven diabetic glomerulosclerosis did not have retinopathy. Several studies suggest that the absence of retinopa-

Table II. Histopathological findings in non-diabetic renal disease (NDRD) group

| PATHOLOGIC DIAGNOSIS | NUMBER OF CASES | PERCENTAGE (%) |
|------------------------|-----------------|----------------|
| FSGS | 13 | 34.2 |
| Membranous nephropathy | 8 | 21.1 |
| IgA nephropathy | 6 | 15.8 |
| GN with crescents | 5 | 13.2 |
| MCD | 2 | 5.3 |
| MPGN type I | 1 | 2.6 |
| Fibrillary GN | 1 | 2.6 |
| LCDD | 1 | 2.6 |
| Amyloidosis | 1 | 2.6 |

FSGS – focal segmental glomerulosclerosis; GN – glomerulonephritis; MCD – minimal change disease; MPGN – mesangioproliferative glomerulonephritis; LCDD – light chain deposition disease

thy is a strong predictor of NDRD [7, 22, 23, 24]. In contrast, the study of Prakash *et al.* [8] demonstrated that presence or absence of diabetic retinopathy was a poor predictor of diabetic nephropathy, because DN was noted in 50% of patients without diabetic retinopathy and 40% of patients with diabetic retinopathy had NDRD either alone or in combination with DN. In our study, statistical analysis revealed a significant difference in the incidence of microhematuria between the studied groups, but it must be highlighted that microhematuria was also present in 33% of patients with biopsy-proven DN. Kharrat *et al.* [25] found that the presence of hematuria and the absence of diabetic retinopathy correlate with NDRD in diabetic patients. Wilfred *et al.* [26] found that absence of retinopathy and presence of microscopic hematuria and active urinary sediment had positive predictive value for NDRD in diabetic patients. Mak *et al.* [27] and Matias *et al.* [28] found a strong correlation between NDRD and microscopic hematuria, whereas Serra *et al.* [22] reported that DN was most commonly found in diabetic patients manifesting microscopic hematuria. In the study of Yaqub *et al.* [29] there was no difference in the prevalence of microscopic hematuria among isolated NDRD and NDRD superimposed on underlying DN. A study of Tone *et al.* [7] showed that microscopic hematuria had lower sensitivity and specificity for the prediction of NDRD compared with the other parameters, suggesting that microscopic hematuria is not a good predictor of NDRD. Taken together, these facts may suggest that laboratory and clinical data do not always accurately predict NDRD in diabetes patients; thus performing the renal biopsy in patients with type 2 diabetes mellitus is mandatory. It must be stressed that differentiating non-diabetic glomerular disease from diabetic

renal disease in early stages may be difficult. Olsen [30] stated that in such cases it is hazardous to make the diagnosis of glomerulonephritis based on light microscopy alone; immunofluorescence microscopy should always be added to the investigation, and optimally also electron microscopy. It is obvious that early diagnosis and management of NDRD in diabetics is important because these patients have significantly better outcomes compared to biopsy-proven diabetic glomerulosclerosis.

With regard to renal biopsy findings in our study, FSGS was the most prevalent type of NDRD, followed by membranous nephropathy, IgA nephropathy and crescentic glomerulonephritis. Similarly to our results, the most common lesion in the US was focal and segmental glomerular sclerosis [31]. In other studies IgA nephropathy and minimal change disease were found to be the commonest NDRD [32, 33]. It must be taken into consideration that the incidence and type of renal involvement depend on biopsy criteria and geographical distribution. Studies from Korea and China reported IgA nephropathy as the commonest NDRD, accounting for 59% of patients [33, 34, 35]. Our study showed that FSGS and membranous nephropathy was also the most common pathologic finding superimposed on underlying DN. The diagnosis of nondiabetic renal disease complicated by diabetes is important for the treatment of renal disease. The differences in the prevalence patterns of glomerulopathies in diabetic patients may be related to the racial predispositions for specific glomerulopathies. It is well known that FSGS is the most common primary glomerulopathy in non-diabetic adults in Poland, whereas IgA nephropathy is observed in up to 40% of all biopsies performed for glomerular disease in Asia. The pathogenesis of NDRD in diabetic patients is not clear. Some authors have suggested that the predisposition of DN to glomerulonephritis could be attributed to enhanced exposure of antigenic cellular components, triggering immune responses [36].

Histological evaluation in the DN group revealed that class III was the commonest glomerular lesion of diabetic nephropathy. This observation is in accordance with others [37]. Nodular type of diabetic nephropathy is regarded as further development of the diffuse type. Nodules are formed from mesangial matrix, and they occur later in the disease than the diffuse lesions. It is thought that nodules never occur without associated marked diffuse lesions. Widening of the mesangial matrix and thickening of the peripheral glomerular basement membrane – the first ultrastructural lesion – can be identified 2-3 years after onset of diabetes mellitus [38]. It is well known that the early changes can usually not be seen by light microscopy until several years of diabetes. The differential diagnosis of nodular diabetic glomerulosclerosis is wide and

includes membranoproliferative glomerulonephritis, membranous glomerulonephritis, and other immune complex glomerulopathies, monoclonal immunoglobulin deposition disease, cryoglobulinemic glomerulonephritis, fibronectin glomerulonephritis, hypertensive nephropathy, fibrillary and immunotactoid glomerulopathies, amyloidosis, and idiopathic nodular glomerulosclerosis [39, 40, 41]. The accurate diagnosis of glomerular lesions requires immunofluorescence evaluation and electron microscopy study of renal tissue. Moreover, a close clinicopathological correlation is mandatory to diagnose diabetic nephropathy.

In summary, the present study demonstrated the heterogeneous pattern of injury in renal tissue in patients with type 2 diabetes mellitus and renal involvement. Non-diabetic renal disease is a common feature in diabetics. Differentiating NDRD from DN on the basis of clinical and laboratory parameters is difficult; however, hematuria, short duration of diabetes and absence of diabetic retinopathy in type 2 diabetic patients manifesting renal involvement may indicate NDRD. Our study revealed that renal biopsy should be performed in diabetics for determining the pattern of renal injury. The accurate diagnosis of glomerular injury in patients with diabetes should include the examination of renal tissue by light microscopy, immunofluorescence and electron microscopy.

The authors declare no conflict of interest.

This work was supported by grant 503/6038-01/503-01 of the Medical University of Lodz.

References

1. Ritz E, Zeng XX, Rychlik I, et al. Clinical manifestation and natural history of diabetic nephropathy. *Nontrib Nephrol* 2011; 170: 19-27.
2. Wild S, Roglic G, Green A, et al. Global prevalence of diabetes: estimates for year 2000 and projections for 2030. *Diabetes Care* 2004; 27: 1047-1053.
3. Wiggins RC. The spectrum of podocytopathies: a unifying view of glomerular diseases. *Kidney Int* 2007; 71: 1205-1214.
4. Ruggenenti P, Gambaro V, Perna A, et al. The nephropathy of non-insulin-dependent diabetes: Predictors of outcome relative to diverse pattern of renal injury. *J Am Soc Nephrol* 1998; 9: 2336-2343.
5. Soni SS, Gowrishankar S, Kishan AG, et al. Non-diabetic renal disease in type 2 diabetes mellitus. *Nephrology* 2006; 11: 533-537.
6. Pham TT, Sim JJ, Kujubu DA, et al. Prevalence of nondiabetic renal disease in diabetic patients. *Am J Nephrol* 2007; 27: 322-328.
7. Tone A, Shikata K, Matsuda M, et al. Clinical features of non-diabetic renal diseases in patient with type 2 diabetes. *Diabetes Res Clin Pract* 2005; 69: 237-242.
8. Prakash J, Sen D, Usha, Kumar NS. Non-diabetic renal disease in patients with type 2 diabetes mellitus. *J Assoc Physicians India* 2001; 49: 415-420.
9. Lin YL, Peng SJ, Ferng SH, et al. Clinical indicators with necessitate renal biopsy in type 2 diabetes mellitus patients with renal disease. *Int J Clin Pract* 2009; 63: 1167-1176.

10. Mazzucco G, Bertani T, Fortunato M, et al. Different patterns of renal damage in type 2 diabetes mellitus: A multicentric study on 393 biopsies. *Am J Kidney Dis* 2002; 39: 713-720.
11. Yoshikawa Y, Truong LD, Mattioli CA, et al. Membranous glomerulonephritis in diabetic patients: A study of 15 cases and review of the literature. *Mod Pathol* 1990; 3: 36-42.
12. Tervaert TW, Mooyaart AL, Amann K, et al. Pathologic classification of diabetic nephropathy. *J Am Soc Nephrol* 2010; 21: 556-563.
13. Colvin RB, Chang A, Kambham N, et al. Glomerular Diseases In: Diagnostic Pathology Kidney Diseases. Colvin RB (eds.) 1st ed. Amirsys Publishing, Inc. Canada 2011; 2.2-358.
14. Huang F, Yang Q, Chen L, et al. Renal pathological changes in patients with type 2 diabetes are not always diabetic nephropathy: A report of 52 cases. *Clin Nephrol* 2007; 67: 293-297.
15. Gambará V, Mecca G, Remuzzi G, et al. Heterogenous nature of renal lesions in type II diabetes. *J Am Soc Nephrol* 1993; 3: 1458-1466.
16. Ghani AA, Waheeb SA, Sahow AA, et al. Renal biopsy in patients with type 2 diabetes mellitus: Indications and nature of the lesions. *Ann Saudi Med* 2009; 29: 450-453.
17. Bi H, Chen N, Ling G, et al. Nondiabetic renal disease in type 2 diabetic patients: a review of our experience in 220 cases. *Ren Fail* 2011; 33: 26-30.
18. Bertani T, Mecca G, Sacchi G, et al. Superimposed nephritis: A separate entity among glomerular diseases? *Am J Kidney Dis* 1986; 7: 2015-212.
19. Nair R, Said M. Diabetic woman with massive proteinuria and acute renal failure. *Am J Kidney Dis* 2005; 46: 362-366.
20. Rychlik T, Jancova E, Tesar V. Non-diabetic renal disease among diabetic patients undergoing renal biopsy 5-year results of The Czech Registry (CRRB). 3rd World Congress of Nephrology Brussels. International Society of Nephrology (ISN); 2005.
21. Soni SS, Swanalatha G, Kishen AG, et al. Predictors of non-diabetic renal disease in type 2 diabetes mellitus; South Indian experience. *Nephrology* 2005; 10 (Suppl): A18.
22. Serra A, Romero R, Bayes B, et al. Is there a need for changes in renal biopsy criteria in proteinuria in type 2 diabetes? *Diabetes Res Clin Pract* 2002; 58: 149-153.
23. Christensen PK, Larsen S, Horn T, et al. Causes of albuminuria in patients with type 2 diabetes without diabetic retinopathy. *Kidney Int* 2000; 58: 1719-1731.
24. Haddiya I, Hamzaoui H, Al Hamany Z, et al. Isolated non diabetic renal disease in diabetic patients: a Moroccan report. *Saudi J Kidney Dis Transpl* 2009; 21: 555-558.
25. Kharrat M, Kammoun K, Charfeddine K, et al. Renal biopsy findings in diabetes mellitus. *Tunis Med* 2007; 85: 216-219.
26. Wilfred DC, Mysorekar VV, Venkataramana RS, et al. Nondiabetic renal disease in type 2 diabetes mellitus patients: A clinicopathological study. *J Lab Physicians* 2013; 5: 94-99.
27. Mak SK, Gwi E, Chan KW, et al. Clinical predictors of non-diabetic renal disease in patients with non-insulin dependent diabetes mellitus. *Nephrol Dial Transpl* 1997; 12: 2588-2591.
28. Matias P, Viana H, Carvalho F, et al. Diabetes mellitus and renal disease: when to perform a renal biopsy? *Port Nephrol Hypert* 2009; 23: 167-73.
29. Yaqub S, Kashif W, Hussain SA. Non-diabetic renal disease in patients with type-2 diabetes mellitus. *Saudi J Kidney Dis Transpl* 2012; 23: 1000-1007.
30. Olsen S. Identification of non-diabetic glomerular disease in renal biopsies from diabetics- a dilemma. *Nephrol Dial Transplant* 1999; 14: 1846-1849.
31. Nzerue CM, Hewan-Lowe K, Harvey P, et al. Prevalence of non-diabetic renal disease among African-American patients with type II diabetes mellitus. *Scand J Urol Nephrol* 2000; 34: 331-335.
32. Das U, Dakshinamutry KV, Prayaga A, et al. Nondiabetic kidney disease in type 2 diabetic patients: A single center experience. *Indian J Nephrol* 2012; 22: 358-362.
33. Lee EY, Chung CH, Choi SO. on-diabetic renal disease in patients with non-insulin dependent diabetes mellitus. *Yonsei Med J* 1999; 40: 321-326.
34. Zhuo L, Zou G, Li W, et al. Prevalence of diabetic nephropathy complicating non-diabetic renal disease among Chinese patients with type 2 diabetes mellitus. *Eur J Med Res* 2013; 22: 4.
35. Li H, Li XW, Huang QY, et al. Non-diabetic renal disease in type II diabetes mellitus. *Zhongguo Yi Xue Ke Xue Yuan Xue Bao* 2003; 25: 101-104.
36. Orfila C, Lepert JC, Modesto A, et al. IgA nephropathy complicating diabetic glomerulosclerosis. *Nephron* 1998; 79: 279-287.
37. Zhu X, Liu F, Peng Y, et al. New pathologic classification of diabetic nephropathy (retrospective study of 37 cases). *Zhong-Nan Da Xue Xue Bao Yi Xue Ban* 2012; 37: 185-189.
38. Osterby R. Early phases of in the development of diabetic glomerulopathy. A quantitative electron microscopic study. *Acta Med Scand* 1975; (suppl 574) (thesis).
39. Alsaad KO, Herzenberg AM. Distinguishing diabetic nephropathy from other causes of glomerulosclerosis: an update. *J Clin Pathol* 2006; 60: 18-26.
40. Wróblewski K, Sodolska M, Wągrowaska-Danilewicz M, et al. When "diabetic nephropathy" is not always of diabetic origin: a case report. *Pol J Pathol* 2012; 63: 134-137.
41. Haloń A. Zmiany w nerkach w chorobach metabolicznych. *Pol J Pathol* 2011; 1 (Suppl.1): s72-s81.

Address of correspondence

Małgorzata Wągrowaska-Danilewicz MD, PhD
 Department of Nephropathology, Medical University of Lodz
 Pomorska 251
 92-216 Lodz, Poland
 tel./fax +48 42 675 76 33
 e-mail: malgorzata.wagrowska-danilewicz@umed.lodz.pl