

ORIGINAL PAPER

MAST CELLS IN SYSTEMIC AND CUTANEOUS LUPUS ERYTHEMATOSUS

KAROLINA KACZMARCZYK-SEKUŁA¹, GRZEGORZ DYDUCH¹, MARCIN KOSTAŃSKI¹,
DOROTA WIELOWIEYSKA-SZYBIŃSKA², JOANNA SZPOR¹, MAGDALENA BIAŁAS¹, KRZYSZTOF OKOŃ¹

¹Department of Pathomorphology, Jagiellonian University Collegium Medicum, Krakow, Poland

²Department of Dermatology, Jagiellonian University Collegium Medicum, Krakow, Poland

Mast cells (MCs) are known to be regulators of inflammation and immunity, due to the released mediators and expressed cell surface molecules.

Lupus erythematosus (LE) is a group of diseases which can be systemic or limited to the skin. Due to the fact that cytokines and chemokines produced by inflammatory cells contribute to the pathogenesis of LE, we quantified the number of mast cells present in the skin.

The aim of the study was to compare the chymase-positive and tryptase-positive mast cell counts within skin biopsies from patients with systemic lupus erythematosus (SLE), discoid lupus erythematosus (DLE) and subacute cutaneous lupus erythematosus (SCLE).

The material consisted of 45 skin biopsies: 6 with SLE, 34 with DLE and 5 with SCLE. Chymase- and tryptase-positive cells were stained by immunohistochemistry and counted.

The mean count of chymase-positive mast cells was 85.14 hpf for the whole group, 35.83 for SLE, 88.48 for DLE and 121.6 for SCLE. The mean count of tryptase-positive cells was 120.05 hpf for the entire group, 59.17 for SLE, 126.42 for DLE and 149.8 for SCLE. The differences between groups were significant for chymase- and tryptase-positive cells.

Key words: systemic lupus erythematosus, discoid lupus erythematosus, SLE, DLE, mast cell, chymase, tryptase.

Introduction

Mast cells (MCs) are bone-marrow derived cells well known for their contribution to allergic reactions. They also play an important role in innate and adaptive immune responses [1]. Mast cells reside in vascularized tissues, i.e. in the intestinal mucosa and in the skin. In normal conditions they are found in subcutaneous fat and dermis, near blood vessels, hair follicles and nerves [2, 3]. They contain granules with a vast array of mediators, i.e. histamine, heparin, chymase, tryptase, etc. [1, 3]. In the innate response, they can both detect the pathogens and release prop-

er mediators to promote a pathogen-specific clearance mechanism. They play an important role in the protection against bacteria, viruses and parasites [1, 4]. In adaptive immunity they interact with T helper (Th) and T regulatory (Treg) cells, mainly stimulating T effector cells and suppressing Tregs [1, 5].

Initially, human mast cells were divided into two subtypes: chymase-positive, containing both chymase and tryptase (MC_{TC}), and tryptase-positive (MC_T), containing only tryptase [6, 7]. However, there is a claim that a third subset – only chymase-positive mast cells (MC_C) – exists [8] or even there is a wider spectrum of MCs subgroups, varying in the number and types

of mediators they produce when activated [3]. In the skin, the MC_{TC} population predominates [9].

Chymase and tryptase are multifunctional serine proteases playing a role *inter alia* in wound healing by promoting fibroblast proliferation and metalloproteinase activation. Chymase induces vascular permeability and collagen remodeling. Tryptase, creating a complex with heparin, degrades fibrinogen in the wound healing process to prevent its further accumulation and thrombus formation. It regulates granulocyte and/or macrophage accumulation in tissues [3]. However, these two proteases have the ability to degrade many protein and peptides, which can lead to skin damage [10]. Also, MCs are suspected to participate in skin inflammation in the course of lupus erythematosus (LE), due to the metalloproteinase production and contribution to immune cell migration and tissue damage [11].

Lupus erythematosus can be divided into systemic and cutaneous forms. Systemic lupus erythematosus (SLE) is an autoimmune disorder affecting multiple organs: lungs, brain, heart, kidney and skin. It is characterized by the loss of tolerance for self antigens and production of auto-antibodies. Formed immune complexes trigger the complement cascade, resulting in inflammation and tissue damage [12]. The skin is the second most frequently involved organ in SLE [13].

Discoid lupus erythematosus (DLE) is a cutaneous form of lupus with a wide spectrum of manifestations [14]. Its name can be confusing, due to the fact that it may refer to a particular type of LE or to coin-shaped lesions occurring in the course of LE. Discoid lupus erythematosus is the most common type of LE, limited to the skin. It has a localized form in the head and neck area, or it can be disseminated (head, neck, limb and trunk). The disseminated form can transform into SLE. The other name for DLE, often used in publications, is cutaneous lupus erythematosus (CLE) [15].

Subacute cutaneous lupus erythematosus (SCLE) is a transitional type of LE, between DLE and SLE. It affects only some organs and is associated with UV hypersensitivity.

To distinguish the subtypes of LE there are some diagnostic criteria established: histological changes of skin biopsy and laboratory abnormalities [14, 16].

The aim of the study was to compare the counts of chymase-positive and tryptase-positive mast cells in the skin biopsies from patients with SLE, DLE and SCLE.

Material and methods

The material consisted of 45 skin biopsies: 6 from patients with SLE, 34 from patients with DLE, and 5 from patients with SCLE. The biopsy area was noted – face, hairy head or other (trunk, limb). Material was collected from the archives of the Department of

Pathomorphology (Collegium Medicum, Jagiellonian University, Krakow).

All cases were examined by immunofluorescence for the presence of IgA, IgG, IgM, C3c and fibrinogen (the lupus band test) on frozen sections.

Afterwards, the material was fixed in formalin, processed by a routine method and embedded in paraffin; 4 µm sections were cut from paraffin blocks and stained with standard hematoxylin and eosin, periodic acid–Schiff and Alcian blue methods.

The immunohistochemistry was done by a routine manual method. Primary anti-tryptase antibody (1 : 100; Leica Biosystems GmbH, Wetzlar, Germany) and anti-chymase antibody (1 : 100; Abcam, Cambridge, UK) were used. The Lab Vision detection system (Thermo Fisher Scientific, Waltham, MA, USA) was used with 3-amino-9-ethylcarbazole as the chromogen. The slides were counterstained with Mayer's hematoxylin (Thermo Fisher Scientific) and coverslipped. The immunostained slides were examined on an Olympus CH20 optical microscope equipped with a 40× lens; the number of immunopositive cells and number of fields of view were documented. The results were expressed as a sum of positive cells from 10 high power fields (hpf), while the area of one hpf was 0.159 mm². The person performing the assessment was not aware of the diagnoses.

The statistical analysis was performed with Statistica 10 (StatSoft Inc., Tulsa, OK, USA). Kruskal-Wallis ANOVA was used; correlations were measured by Spearman's correlation. The significance level was set at 0.05.

Results

Mean age of all patients was 44.53 ± 11.5 years (all values expressed as arithmetic mean ± SD), range 22–66 years. For SLE the mean age was 47.5 ± 17.84, for DLE 43.65 ± 10.16 years and for SCLE 47 ± 13.3 years. Mean age for females was 45.59 ± 12.06 years and 42.63 ± 10.5 years for males. The differences between patients' ages in groups were not statistically significant.

The mean count of chymase-positive mast cells (MCs) was 85.14 ± 52.08 per 10 high power fields, while the mean count for tryptase-positive MCs was 120.05 ± 68.05. The average ratio of chymase-positive to tryptase-positive cell count was 0.73 ± 0.29.

In SLE the chymase-positive mast cell count was 35.83 ± 30.17 per 10 high power fields, while the mean count for tryptase-positive MCs was 59.17 ± 40.94. The average ratio of chymase-positive to tryptase-positive cell count was 0.6 ± 0.23. In DLE the chymase-positive mast cell count was 88.48 ± 50.71 per 10 high power fields, while the mean count for tryptase-positive MCs was 126.42 ± 69.01. The average ratio of chymase-positive to trypt-

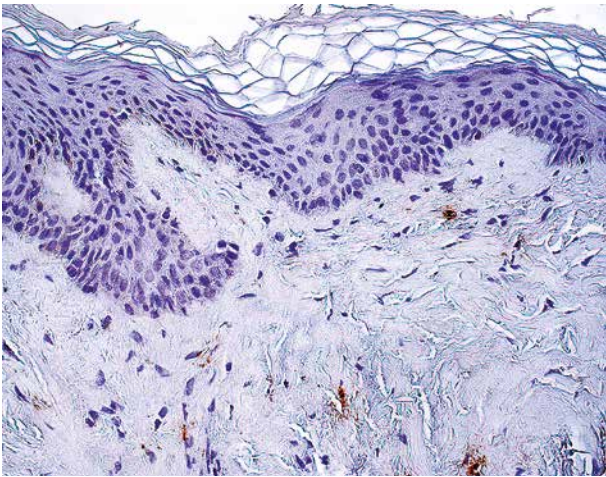


Fig. 1. Tryptase positive cells in skin, systemic lupus erythematosus. Immunohistochemistry, original magnification 400×

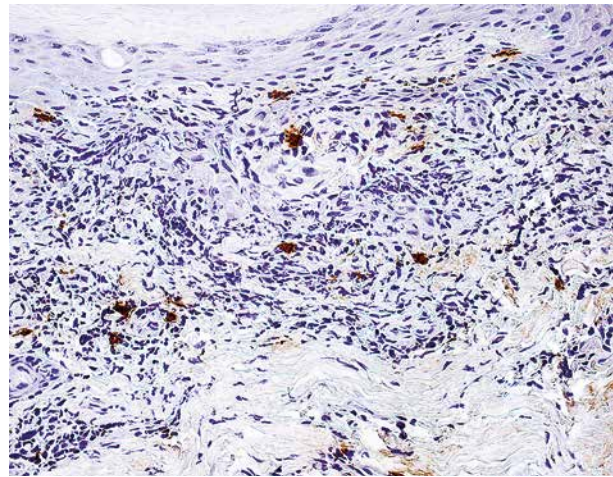


Fig. 2. Tryptase positive cells in skin, discoid lupus erythematosus. Immunohistochemistry, original magnification 400×

ase-positive cell count was 0.75 ± 0.32 . In SCLE the chymase-positive mast cell count was 121.6 ± 45.64 per 10 high power fields, while the mean count for tryptase-positive MCs was 149.8 ± 50.5 . The average ratio of chymase-positive to tryptase-positive cell count was 0.82 ± 0.11 .

The differences between groups in chymase-positive cell counts and tryptase-positive cells were statistically significant ($p = 0.008$ and $p = 0.02$, respectively). On post-hoc analysis differences in chymase-positive MC count were found between all three groups, SLE, DLE and SCLE, whereas in the tryptase-positive MC count a difference was found between SLE and SCLE. The differences in the ratio of chymase-positive to tryptase-positive cells between groups were not significant; however, there was a significant correlation between the ratio of chymase-positive to tryptase-positive cells and chymase-positive cell count ($R = 0.31$). Chymase-positive MC counts and tryptase-positive MC counts were strongly correlated ($R = 0.85$). In SLE and DLE groups there was a strong correlation between chymase-positive MC count and tryptase-positive MC count ($R = 0.89$ and $R = 0.82$, respectively). The highest mean count of chymase-positive and tryptase-positive mast cells was in the biopsies collected from the face (106.56 ± 44.72 , 142.66 ± 67.08 , respectively). It was lower in the biopsies collected from the hairy head (94.13 ± 70.91 , 135.56 ± 83.55 , respectively) and the lowest in the biopsies collected from other places (74.43 ± 44.35 , 90.14 ± 51.60 , respectively). There was no statistically significant difference in the number of mast cells between the biopsy areas.

Discussion

Mast cells are the principal immune cells taking part in allergic reactions and playing an important

role in innate and adaptive immunity [1]. In many organs, e.g. the kidney, they contribute to local inflammation and tissue remodeling [17, 18].

Mast cells are found in the skin in normal conditions, but their number increases in chronic skin inflammation, e.g. psoriasis, and in some tumors such as basal cell carcinoma. They may be involved in the pathogenesis of these diseases due to the wide range of released mediators. Their activity is dual, both proinflammatory and immunosuppressive. Mast cells can recruit other immune cells such as T cells, eosinophils and neutrophils, as well as activate Langerhans and dendritic cells. Two of their serine proteases – chymase and tryptase – contribute to these processes. Tryptase activates endothelial cells, peripheral blood mononuclear cells, T cells and neutrophils, as well as metalloproteinases and pro-urokinase. It also degrades chemokines, neuropeptides and cathelicidin LL-37 acting as an inhibitor. Chymase also recruits immune cells and activates some pro-interleukins. However, it degrades interleukin-6 and -15 and to some extent IL-5 and tumor necrosis factor α (TNF- α) [9].

The pathogenesis of the cutaneous form of LE encompasses immunologic, environmental and genetic factors. Some of the genes encoding cytokines [interleukin (IL)-1, IL-10], their receptors, apoptosis genes and adhesion molecules seem to increase the susceptibility to CLE, as well as inherited deficiencies of complement components. From the environmental factors, the major trigger is UV light, which induces the release of proinflammatory factors such as TNF- α , IL-1, IL-6, etc., and apoptosis. However, other agents eliciting inflammation such as trauma, scratching, coldness or burns may contribute to LE development. In this disease, the tissue damage is caused by overlapping events such as impaired clearance of apoptotic material, the presence of autoanti-

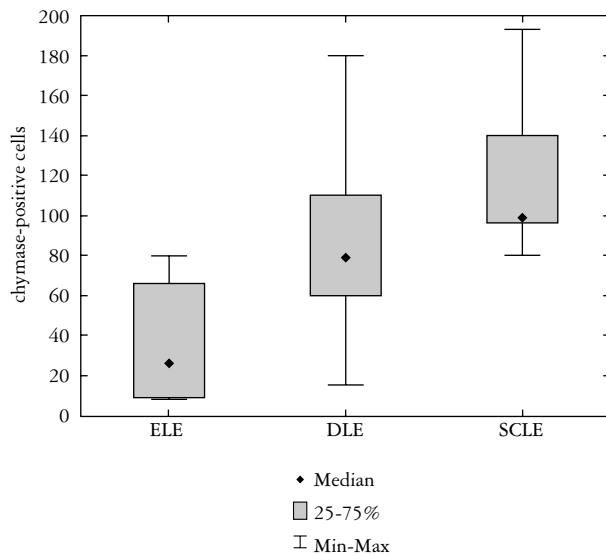


Fig. 3. Number of chymase positive cells in systemic lupus erythematosu (SLE), discoid lupus erythematosus (DLE) and subacute cutaneous lupus erythematosus (SCLE). Central point – Median; Box 25-75%; Whiskers – Min-Max

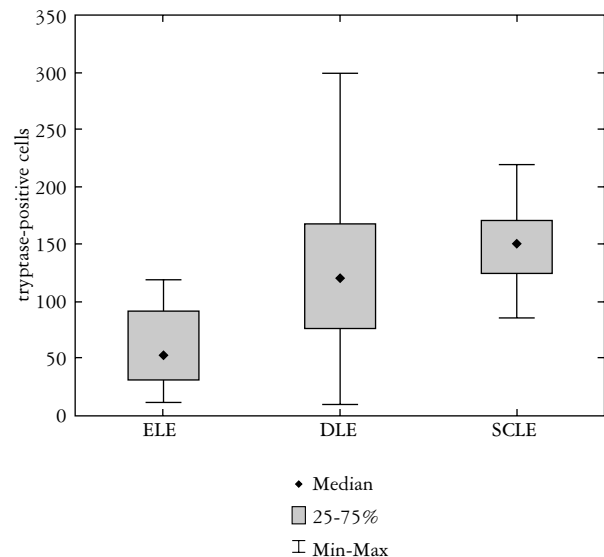


Fig. 4. Number of tryptase positive cells systemic lupus erythematosu (SLE), discoid lupus erythematosus (DLE) and subacute cutaneous lupus erythematosus (SCLE). Central point – Median; Box 25-75%; Whiskers – Min-Max

bodies, activity of TNF- α and interferons (INFs), as well as disturbance of immune regulation due to the lower number of Tregs.

Recent studies have shown that CLE subsets share some similarities in their pathogenesis. However, they differ in particular points of the pathogenic mechanism, e.g. in the type of antinuclear antibodies binding to the antigens on the surface of keratinocytes [19, 20].

The clinical manifestation of the subtypes of cutaneous lupus varies. SCLE is characterized by symmetric distribution of lesions on sun-exposed areas presenting initially as erythematous macules or papules, transforming into scaly, papulosquamous or annular/polycyclic plaques. The lesions can be triggered by UV light or drugs. Discoid lupus erythematosus presents as a localized form with lesions on the face, ears, and scalp or rarely as a disseminated type with lesions above and below the neck. Lesions appear in sun-exposed areas but also in palmoplantar sites. Most commonly it is characterized by scaling erythematous discoid plaques, leading with time to scarring. The inflammation in DLE mostly involves the bulge area of the follicles [16, 21].

To distinguish SLE from other diseases, the American College of Rheumatology (ACR) established criteria including 11 clinical and laboratory features; 4 of the 11 ACR criteria include mucocutaneous lesions (malar rash, discoid lesions, photosensitivity, and oral ulcers). In 2012, the Systemic Lupus International Collaborating Clinics (SLICC) improved the ACR criteria, specifying 17 clinical and immunological features [16, 22].

The diagnosis of LE should be based on patient history, clinical examination, laboratory studies, serology as well as histology. The cutaneous forms of LE can be diagnosed by lesional biopsy and followed by a lupus band test. They also require profound analysis of clinical features [16].

In our previous studies, we found that the mast cell counts in renal interstitium differ in the classes of SLE and despite the similar pattern of pathological changes in the renal glomerulus in lupus nephritis class IV and membranoproliferative glomerulonephritis, the quantity of mast cells in these two diseases is different. Moreover, we confirmed that mast cells contribute to renal tubulointerstitial fibrosis, while the number of mast cells correlates with the renal interstitial volume (RIV) [23, 24].

In this study, we examined the chymase- and tryptase-positive mast cell numbers in skin biopsies from patients with SLE, DLE and SCLE. We found a statistically significant difference in the number of mast cells in these three groups. The highest number of mast cells was in SCLE, lower in DLE and the lowest in SLE. These findings suggest that the higher number of mast cells in the cutaneous types of LE, especially in the subacute type, may be related to the formation of the skin lesions. Despite the fact that more abundant inflammation is seen in DLE rather than in SCLE, the higher number of mast cells in SCLE may be related to the epidermal exocytosis of lymphocytes, which can be recruited by MCs [15]. Moreover, the higher number of tryptase-positive rather than chymase-positive mast cells in all kinds of LE may be associated with the partial inactivation

of chymase in many skin diseases [10]. Our findings show that the number of mast cells varies depending on the biopsy location. The lowest number of MCs was noted in the samples taken from the limb or trunk; it was higher on the scalp and the highest in the biopsies collected from the face. This fact may be related to the higher UV exposure of those areas.

There are only a few studies about mast cell quantification in the skin biopsies from patients with CLE or SLE; none of them include examination of mast cell protease expression. Van Nguyen *et al.* examined the quantification of mast cells in skin of patients with CLE after UV radiation; the number of MCs was significantly higher. These findings suggest that mast cells might play a role in the skin inflammation in CLE due to immune cell recruitment and metalloproteinase production [11]. In our study, the number of mast cells from the biopsies collected from sun-exposed areas was higher too. Martins *et al.* counted the mast cells in skin from patients with cutaneous mucinosis; one of the subgroups was mucinosis associated with LE. They observed an increase in MC number in the skin of patients with cutaneous mucinosis compared with the control group; however, there was no significant difference in the number of mast cells between the subgroups of cutaneous mucinosis [25]. Patel *et al.* in their study quantified the mast cells in five dermatoses: lichen simplex chronicus, psoriasis, lichen planus, lupus, and insect bite/allergic contact dermatitis/nummular dermatitis with two methods of staining: CD117 and toluidine blue. The study showed that the mast cell distribution pattern was different in the two methods of staining [8]. Naik *et al.* studied non-neoplastic skin lesions for mast cells. The MC number in lupus vulgaris was lower than in bullous pemphigoid, viral infections of the skin, leprosy or dermatitis but higher than in congenital diseases [26].

In conclusion, we examined, for the first time, the chymase- and tryptase-positive mast cell counts within skin biopsies from patients with SLE, DLE and SCLE. We found that mast cell numbers differ between these groups. The highest count occurs in SCLE, a lower one in DLE and the lowest in SLE. However, the matter should be investigated further with a larger group of patients.

The authors would like to thank Mr. Krzysztof Skomski for preparing the microphotographs.

The authors declare no conflict of interest.

References

- Rodewald HR, Feyerabend TB. Widespread immunological functions of mast cells: fact or fiction? *Immunity* 2012; 37: 13-24.
- Metz M, Siebenhaar F, Maurer M. Mast cell functions in the innate skin immune system. *Immunobiology* 2008; 213: 251-260.
- Douaiher J, Succar J, Lancerotto L, et al. Development of mast cells and importance of their tryptase and chymase serine proteases in inflammation and wound healing. *Adv Immunol* 2014; 122: 211-252.
- St John AL, Abraham SN. Innate immunity and its regulation by mast cells. *Immunol* 2013; 190: 4458-4463.
- Hershko AY, Rivera J. Mast cell and T cell communication; amplification and control of adaptive immunity. *Immunol Lett* 2010; 128: 98-104.
- Buckley MG, McEuen AR, Walls AF. The detection of mast cell subpopulations in formalin-fixed human tissues using a new monoclonal antibody specific for chymase. *J Pathol* 1999; 189: 138-143.
- Andoh A, Deguchi Y, Inatomi O, et al. Immunohistochemical study of chymase-positive mast cells in inflammatory bowel disease. *Oncol Rep* 2006; 16: 103-107.
- Patel N, Mohammadi A, Rhatigan R. A comparative analysis of mast cell quantification in five common dermatoses: lichen simplex chronicus, psoriasis, lichen planus, lupus, and insect bite/allergic contact dermatitis/nummular dermatitis. *ISRN Dermatol* 2012; 2012: 759630.
- Harvima IT, Nilsson G. Mast cells as regulators of skin inflammation and immunity. *Acta Derm Venereol* 2011; 91: 644-650.
- Diaconu NC, Kaminska R, Naukkarinen A, et al. The increase in tryptase- and chymase-positive mast cells is associated with partial inactivation of chymase and increase in protease inhibitors in basal cell carcinoma. *J Eur Acad Dermatol Venereol* 2007; 21: 908-915.
- Van Nguyen H, Di Girolamo N, Jackson N, et al. Ultraviolet radiation-induced cytokines promote mast cell accumulation and matrix metalloproteinase production: potential role in cutaneous lupus erythematosus. *Scand J Rheumatol* 2011; 40: 197-204.
- Tsokos GC. Systemic lupus erythematosus. *N Engl J Med* 2011; 365: 2110-2121.
- Obermoser G, Sontheimer RD, Zelger B. Overview of common, rare and atypical manifestations of cutaneous lupus erythematosus and histopathological correlates. *Lupus* 2010; 19: 1050-1070.
- Okon LG, Werth VP. Cutaneous lupus erythematosus: diagnosis and treatment. *Best Practice Res Clin Rheumatol* 2013; 27: 391-404.
- Calonje IE, Brenn T, Lazar A, McKee Ph. McKee's pathology of the skin. Elsevier 2012; vol. 1.
- Kuhn A, Landmann A. The classification and diagnosis of cutaneous lupus erythematosus. *J Autoimmun* 2014; 48-49: 14-19.
- Hiromura K, Kurosawa M, Yano S, et al. Tubulointerstitial mast cell infiltration in glomerulonephritis. *Am J Kidney Dis* 1998; 32: 593-599.
- Holdsworth SR, Summers SA. Role of mast cells in progressive renal diseases. *J Am Soc Nephrol* 2008; 19: 2254-2261.
- Wenzel J, Zahn S, Tüting T. Pathogenesis of cutaneous lupus erythematosus: common and different features in distinct subsets. *Lupus* 2010; 19: 1020-1028.
- Privette ED, Werth VP. Update on pathogenesis and treatment of CLE. *Curr Opin Rheumatol* 2013; 25: 584-590.
- Oke V, Wahren-Herlenius M. Cutaneous lupus erythematosus: clinical aspects and molecular pathogenesis. *J Intern Med* 2013; 273: 544-554.
- Petri M, Orbai AM, Alarcón GS, et al. Derivation and validation of the Systemic Lupus International Collaborating Clinics classification criteria for systemic lupus erythematosus. *Arthritis Rheum* 2012; 64: 2677-2686.

23. Kaczmarczyk K, Kosalka J, Soja J, et al. Renal interstitial mast cell counts differ across classes of proliferative lupus nephritis. *Folia Histochem Cytobiol* 2014; 52: 218-224.
24. Kaczmarczyk K, Musiał J, Soja J, et al. Renal interstitial mast cell count is significantly higher in membranoproliferative glomerulonephritis than in class IV lupus nephritis. *Pol J Pathol* 2015; 66: 149-153.
25. Martins C, Nascimento AP, Monte-Alto-Costa A, et al. Quantification of mast cells and blood vessels in the skin of patients with cutaneous mucinosis. *Am J Dermatopathol* 2010; 32: 453-458.
26. Naik R, Pai MR, Bantwal PB, et al. Study of mast cells in non-neoplastic skin lesions. *Indian J Pathol Microbiol* 2003; 46: 173-175.

Address for correspondence

Krzysztof Okoń
Department of Pathomorphology
Jagiellonian University Collegium Medicum
Grzegórzecka 16
31-531 Krakow, Poland
e-mail: mpokon@cyf-kr.edu.pl