

ORIGINAL PAPER

**ANCIENT CARDIAC MYXOMAS – ANOTHER POINT OF VIEW
IN THE LIGHT OF TETRASPANINS**

PIOTR LEWITOWICZ¹, PIOTR BERNACZYK², AGATA HORECKA-LEWITOWICZ³, URSZULA LESZCZYŃSKA²,
JOANNA RESZEC², TOMASZ HIRNLE⁴, ANDRZEJ WINCEWICZ⁵

¹Department of Pathology, Faculty of Medical Sciences, Jan Kochanowski University, Kielce, Poland

²Department of Medical Pathomorphology, Medical University of Białystok, Białystok, Poland

³Department of Public Health, Faculty of Health Sciences, Jan Kochanowski University, Kielce, Poland

⁴Department of Cardiac Surgery, Medical University of Białystok, Białystok, Poland

⁵Department of Anatomy, Faculty of Medical Sciences, Jan Kochanowski University Specialist Medical Practice-Pathologist, Kielce, Poland

Myxomas are the most common non-invasive but life-threatening cardiac neoplasms due to obstruction of heart chambers and risk of embolism in a manner resembling thromboembolism as well. They can occasionally disseminate via their detached fragments into the bloodstream to seed and grow as secondary still benign tumors. In this study we evaluated morphological and clinical aspects of 14 ancient, degenerated left or right-sided cardiac atrial myxomas with expression of CD9 and CD63, which are found to contribute to platelet activation, aggregation and, as a result, intratumoral thrombosis or fragmentation.

The appearance of tumors varied from sessile to polypoid revealing that a higher rate of endocardial thrombosis was associated with sessile compared to polypoid myxomas and left-sided tumors compared to right-sided ones in our study. In the general aspect of ancient calcifications, amorphous calcification with intra-tumor thrombosis was noted more frequently in sessile tumors, while well-formed osseous metaplasia was usually a feature of polypoid tumors. In our material osseous metaplasia did not coexist with massive thrombosis and was found in polypoid, pedunculated myxomas. Most importantly, CD9 overexpression was recorded in every studied myxoma and CD63 gave a weak reaction in myxoma cells.

Key words: cardiac myxoma, endocardial thrombosis, CD9, CD63, degenerative amorphous calcification, osseous metaplasia.

Introduction

Cardiac myxomas occur with a frequency of 0.5 per million population [1]. In general incidence of cardiac tumors remained at quite a low level of 0.02% or up to 0.3% in autopsy material, of which 75% to 84.9% were benign [2, 3]. Myxomas comprised over 93% of all benign tumors of the heart, with the left atrium as the most common site of growth (74.2%) [3].

Thus, they are relatively rare neoplasms, but they are still the most common benign neoplasms of the human heart [1, 4, 5]. As myxoma is the most common primary cardiac tumor and fibroelastoma is the second one, the operated cardiac mass turned out to be a non-neoplastic thrombus in up to 15.5% in a study of Strucker *et al.* [6].

It should be noted that the heart is not the only location for this kind of tumor. There have been de-

scribed very rare cases in other locations, for instance kidney myxoma [7].

Cardiac myxomas are widespread among species, and their occurrence is not limited to humankind, but they can occur also in domestic animals such as cats with intratumoral focal bone and cartilage formation [8]. They grow as single tumors, but they can also be multiple with dramatic worsening of patients' condition, which can develop into ventricular outflow obstruction, dyspnea and palpitations [9]. Cardiac myxomas usually occur as sporadic tumors, but they can be components of composite clinical syndromes [10]. Up to 7% of cardiac myxomas are manifestations of Carney complex (CNC), which is a multiple neoplasia syndrome manifesting with cardiac, endocrine, and neural neoplasms combined with pigmented cutaneous lesions [11]. Carney complex syndrome should be distinguished from the familial form of cardiac myxomas. Angiogenesis develops in myxomas as true neoplasms and mast cells are usually accumulated in the vicinity of vessels to support a process of vascularization [12]. Namely, mast cells were reported to be positive for the well-known angiogenic factor tryptase in cardiac myxomas, with a correlation between number of tryptase-positive mast cells and formation of pseudovascular structures [12]. However, their biology is still not fully understood. Differential diagnosis is between cardiac myxoma and thrombus as they both could result in syncope and have similar clinical symptomatology which depends on the location, size and shape of the mass but is not greatly affected by the fact of its character, namely whether it is a myxoma or a thrombus in spite of the totally different management of the lesions [13]. For example, differential diagnosis employed echocardiography, autopsy and histopathology to finally state that a cardiac tumor of the right atrium and the inferior vena cava in a young woman was a thrombus [13].

Namely, they are life-threatening because their growth can obstruct heart chambers and their ostia, resulting in acute cardiac failure with clinical presentation, e.g. syncope [14]. Furthermore, the coronary arteries may be affected by tumor-derived, myxomatous emboli that rarely cause acute myocardial infarction or evident tumor displacement [15]. Typically, well-formed, pedunculated tumors are detected easily in the left atrium, with a possibility of protrusion into the ventricular chamber [16]. The risk of recurrences increases in the case of familial myxomas in association with the Carney complex and a mutation in the *PRKAR1A* gene [10, 17]. Characteristically, the rate of recurrences of cardiac myxomas was estimated to vary between 3% for sporadic cases and 22% for tumors of the Carney complex [18]. Detachment, and inoculation of myxoma particles is considered as a direct cause of tumor displacement [19]. In the case of mobile myxomas in the right atrium,

acute pulmonary embolism can develop as a result of dissemination of the thrombus and tumor particles in the form of emboli into the pulmonary circulation [20]. To make things worse, left atrial myxoma could be responsible for induction of pulmonary embolism without any leakage through the cardiac septum by hypercoagulability, hemolysis, or heme oxygenase-1 up-regulation [21]. Indeed, the stroke, pulmonary embolism, syncope and multi-organ emboli are frequent clinical manifestations of cardiac myxomas that are true generators cardiogenic emboli [22, 23, 24, 25, 26]. It should be highlighted here that, embolus material can be both composed from both thrombus and tumor fragments and late complications of embolisation could be brain aneurysms and secondary myxomas [23].

Although myxomas are exposed to a relatively large bloodstream, hypoxia-inducible factor-1 (HIF-1) dependent protein glucose transporter-1 (GLUT-1) was detected in cardiac myxoma cells, which may indicate increased uptake of glucose by these tumors, similarly to a variety of other tumors [27]. Myxomas express various other proteins, such as tenascin-c with its involvement in cellular aggregation and hyaluronan receptors CD44s, CD44v5 and CD44v6 with an impact of CD44 receptors on cellular motility [28].

However, in the context of endocardial thrombosis, which could often accompany myxomas, tetraspanins seem to be a group of great significance. They belong to the transmembrane 4 superfamily of transmembrane proteins, and most of them build cholesterol-rich tetraspanin-enriched microdomains (TEMs) [29, 30]. Tetraspanins usually are expressed on platelets and on components of the vascular system, where they have a clear role in endothelial proliferation, neo-vascularization, smooth muscle fiber motility and contraction, cell motility, adhesion and, importantly, maintenance of the extracellular micro-environment. CD9 (p24), as the main protein member of this family, interacts with many integrins, growth factors including heparin-binding epidermal growth factor (HB-EGF), epidermal growth factor receptor (EGFR) with metalloproteinases, and immunoglobulins [29]. CD63 exhibits an entirely different structure. It is mainly an intercellular protein. It is involved in transmembrane transport of various agents, cell motility and interactions with extracellular mediators by the trafficking phenomenon [29].

CD63 is distributed in the membranes of lysosomal membranes and dense granules of non-activated platelets [30, 31]. However, after platelet stimulation and platelet degranulation, thrombin activation causes transportation of CD63 to the surface of the plasma membrane, adheres to the α IIb β 3-CD9 complex and is incorporated into the Triton-insoluble actin cytoskeleton [30, 31]. CD9, CD63 and α IIb β 3 co-operate with each other

to maintain platelets spread on fibrinogen [30, 31]. In addition, numerous processes such as palmitoylation could induce platelet aggregation and fibrin clot via recruitment of CD9 and CD63 [30]. Platelet assembly is also maintained by the The F11 receptor (F11R) (a.k.a. Junctional Adhesion Molecule, JAM) – a platelet-derived cell adhesion molecule that belongs to the immunoglobulin (Ig) superfamily. F11R recruitment is accompanied by an increase in the level of free intracellular calcium and coupling of the F11R with the integrin GPIIIa and also with CD9, too [32].

Therefore, we aimed to evaluate of CD9 and CD63 expression in ancient, degenerated cardiac myxomas.

Material and methods

Material

The study included a series of 14 cases of ancient degenerated cardiac myxomas with serious clinical suspicion for endocardial thrombosis. Using transthoracic echocardiography and magnetic resonance methods as well, 14 patients were detected with an atrial tumor mass with suspicion of endocardial thrombosis.

Most of the patients had thromboembolic complications and coagulopathy that constituted an additional misleading background on the way to correct diagnosis. Surgical removal of tumor masses was performed after failure of conservative treatment with a median period of 6 weeks from the initial diagnosis.

This completely anonymous retrospective study was strictly performed according to the guidelines of the latest revision of the Declaration of Helsinki from 2004 and does not require the consent of the local Ethics Committee.

The patients comprised 4 women and 10 men in the study group. Seven myxomas were located in the right atrium, while the left atrium was the site of origin of 7 tumors too. Neoplasms measured from 1.2 cm to 4.1 cm, with a medium size of 2.82 cm (SD 0.69) in diameter. Age of patients ranged from 23 to 78, with a medium age of 60.4 (SD 13.3) years old.

Methods

Tumors were fixed in 10% buffered formalin and then processed in routine histopathological procedures. Samples embedded in paraffin blocks were cut on 4 μ m slides and stained routinely with hema-

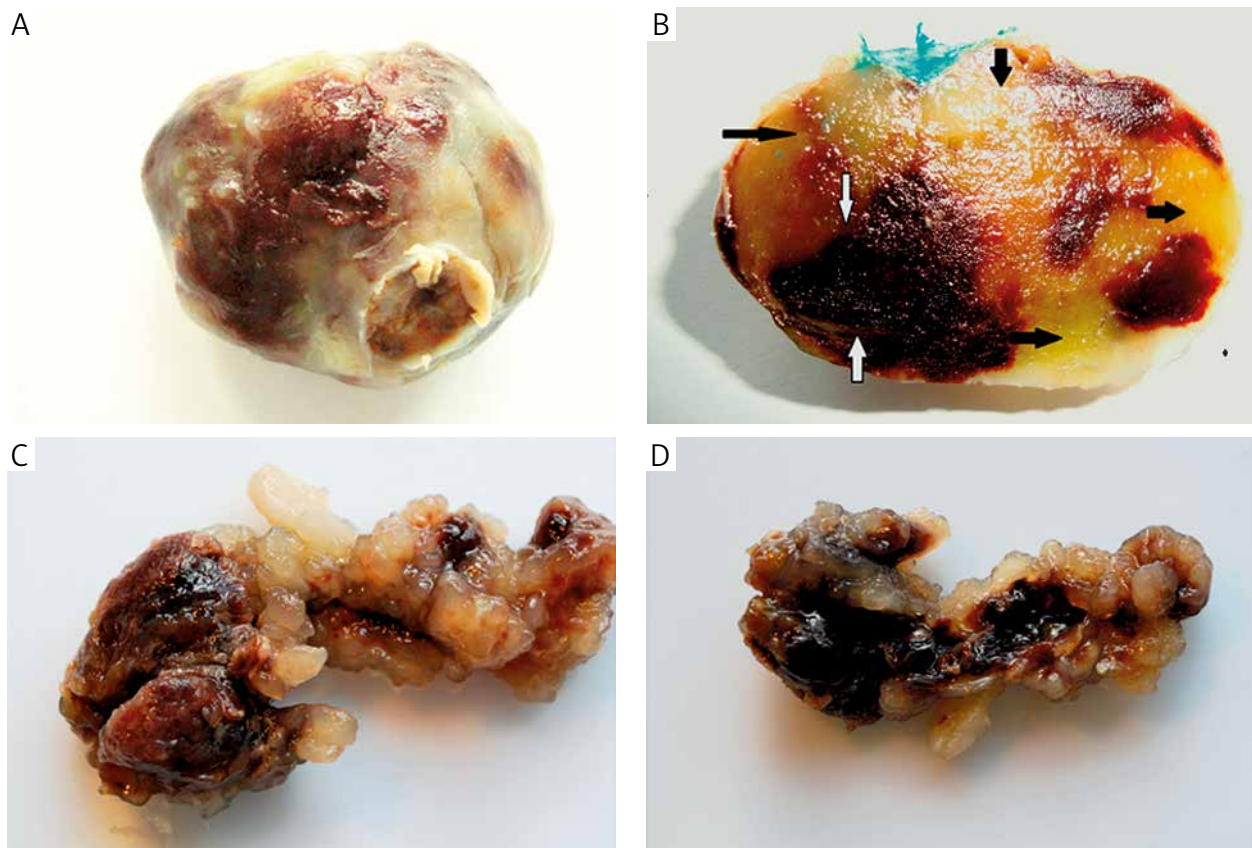


Fig. 1. Macroscopic pictures of typical myxoma. A) Macroscopic view of typical pedunculated cardiac myxoma (original magnification). B) Cut surface of tumour – here, are visible typical regions of myxomatous tumour (black arrows) and haemorrhagic parts with necrosis, fibrin deposits and substantial amount of calcifying deposits (white arrows) (original magnification). C) Typical pattern of sessile cardiac myxoma with prominent villous surface and hemorrhagic foci (original magnification). D) A base of sessile myxoma (original magnification)

toxylin & eosin. CD9 and CD63 were labeled immunohistochemically with appliance of monoclonal antibodies (mouse monoclonal CD9:EPR2949, Biogenex, diluted at 1 : 30; CD63: ready to use solution; NK1/C3, Cell Marque).

After deparaffinization and rehydration of the samples, the unmasking processes, and incubation with primary antibodies the next routine steps were performed using the Ventana ultra View Universal DAB Detection Kit (Ventana Medical Systems; Roche Group, Tucson, USA). As a positive control we used renal cell carcinoma tissue for CD9 and malignant melanoma tissue for CD63 in accordance with the manufacturer's recommendations.

In our point of view, the number of examined cases did not allow us to make any reliable statistically significant evaluation; thus no statistical analysis was performed. That is why – due to the interesting results – we decided to present the results in a table and illustrations with an appropriate description.

Results

Macroscopic and microscopic findings

Macroscopically, two main types of myxomas were present in our material. Namely, there were 5 classic polypoid tumors with a smooth surface (Fig. 1A, B) and 9 neoplasms of sessile type, partially of carpet-like appearance with a broad base and irregular surface (Fig. 1C, D). On the cut surface (Fig. 1B) there were visible hemorrhagic foci partially with hemorrhagic necrosis with intra-tumoral thrombosis besides typical myxomatous parts of the tumor.

Microscopic evaluation of tumors showed typical histopathological patterns of benign cardiac myxoma. Our attention was drawn to usually pathological ancient, degenerative changes. There were various forms of calcification in the tumors. We categorized the foci of compact tissue into classical Gamna-Gandy bodies and well-formed, mature osseous metaplasia (Fig. 2A, B) and amorphous calcifications (Fig. 2A-D). These findings also included areas of extravasated erythrocytes, many hemosiderin-laden macrophages, hemorrhagic foci, fibrin deposits of florid thrombosis, fibrosis and ischemic necrosis. Numerous plasmatic cells were observed perivascularly and in the myxoid stroma. Mast cells and histiocytes were observed to a lesser extent.

CD9 expression was visualized as a diffuse and strong cytoplasmic granular reaction within perivascular tumor cells and inflammatory cells as well. We did not observe differences in expression according to the tumor type. In tumor areas with a considerable intratumoral thrombosis there was observed evident CD9 expression within the extracellular matrix (ECM) components. These features as a background reaction resulted from overexpression in platelets

rather than being a real artifact. Opposite to CD9, CD63 expression in tumor cells was less evident. The pattern of the reaction was cytoplasmic and granular in nature too but was weak in comparison with the strong reaction in inflammatory cells. Interestingly, at the border between intratumoral thrombosis and necrosis and “persistent and alive” tissue of the tumor, CD63 had strong expression. Worth noting is potent expression equally of CD9 and CD63 in inflammatory cells, especially within plasma cells. In addition, CD9 and CD63 expressions were compared to GLUT-1 immunoreactivity of myxomas but these tetraspanins failed to correlate with GLUT-1 in this limited study group.

Clinical symptomatology versus pathologic features of myxomas

Pathological traits coexisted characteristically with certain clinical manifestations. Namely, atrial fibrillation was recorded predominantly in right-sided tumors. Left atrial tumors presented occasionally with arterial hypertension, syncope, cardiac insufficiency and stroke. Polypoid myxomas were characterized by the presence of well-formed osseous metaplasia with or without coexisting diffuse thrombosis. Amorphous calcifications combined with thrombosis constituted the dominant type of tissue degeneration in sessile myxoma. Most of the studied right-sided myxomas were sessile and were frequently surfaces for thrombosis and became sites of amorphous calcifications. The higher incidence of endocardial thrombosis was associated with sessile versus polypoid myxomas. In general, amorphous calcification was combined with endocardial thrombosis in sessile tumors, while well-formed osseous metaplasia was usually a feature of polypoid tumors. In our material osseous metaplasia did not coexist with high-grade thrombosis and was predominantly found in polypoid, pedunculated myxomas. Special surface changes are worth noting in sessile tumors. Here, were observed polypoid, papillary, tumor projections with evident signs of tumor defragmentation and spread into the bloodstream. As a result, superficial erosions with thrombosis occurred (Fig. 2E, F). These findings explain why thrombosis and subsequent embolism could result from persistence of cardiac myxoma. Moreover, the finding of the release into the bloodstream of acid mucopolysaccharides explains the serological marks of hypercoagulability too.

Discussion

In our study left atrial tumors presented with arterial hypertension, syncope, and cardiac insufficiency and these findings were similar to the reported clinical picture for left cardiac myxomas [1, 15, 16, 33]. On the basis of our findings it could be suggested

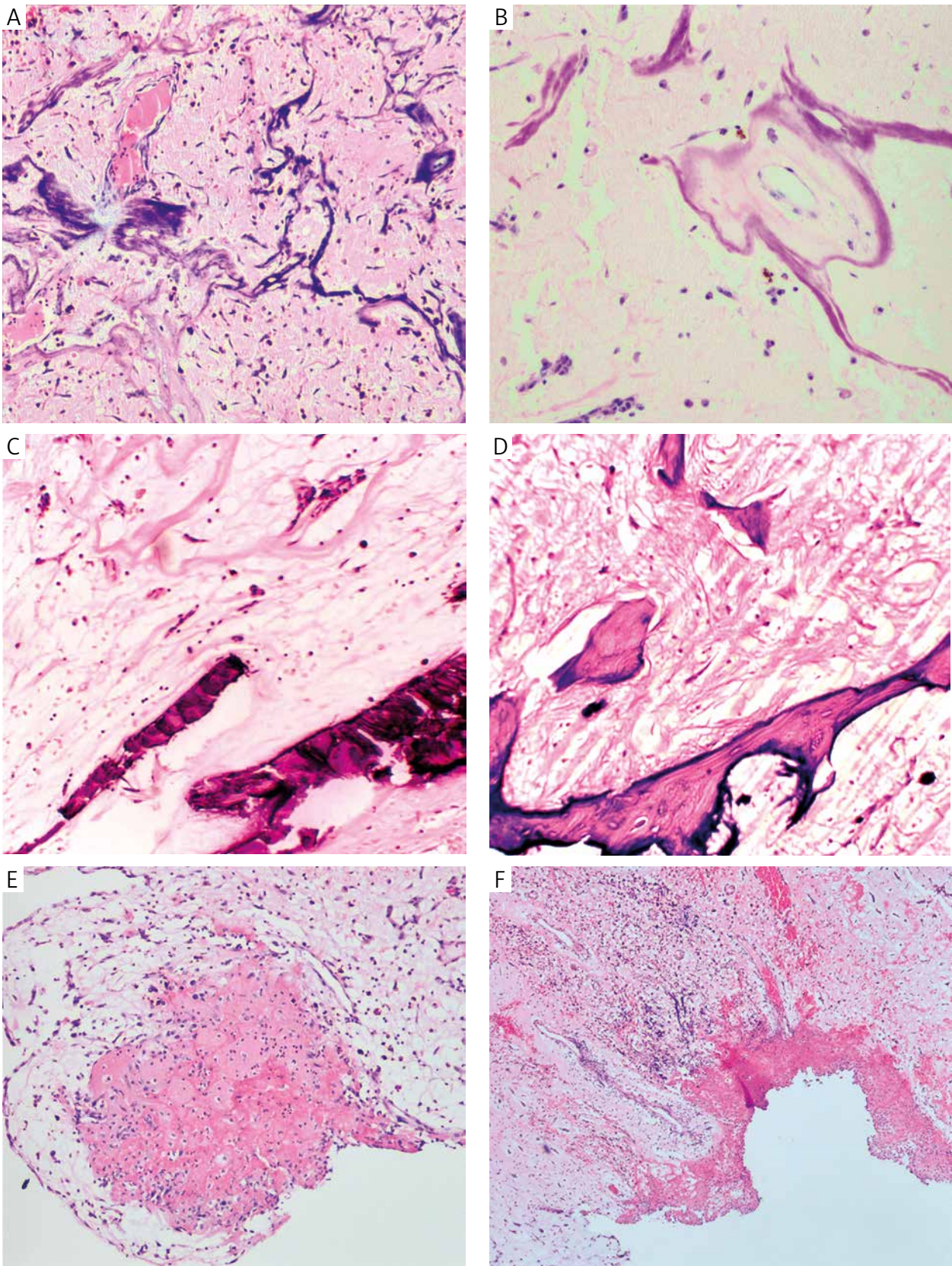


Fig. 2. Calcified changes and thrombotic foci (magnification 100×). A) Florid, shapeless Gamna-Gandy bodies (magnification 100×). B) Perivascular regular calcification as a progenitor of osseous metaplasia with the tails of Gamna-Gandy bodies (magnification 100×). C) Amorphous deposits of calcium in myxoma (magnification 100×). D) Well formed osseous metaplasia (magnification 100×). E) Intra-tumoral thrombosis and necrosis of tumor's part detachment within villous tumor's projection (magnification 100×). F) Erosion and thrombosis at place of detachment tumor's part (magnification 100×)

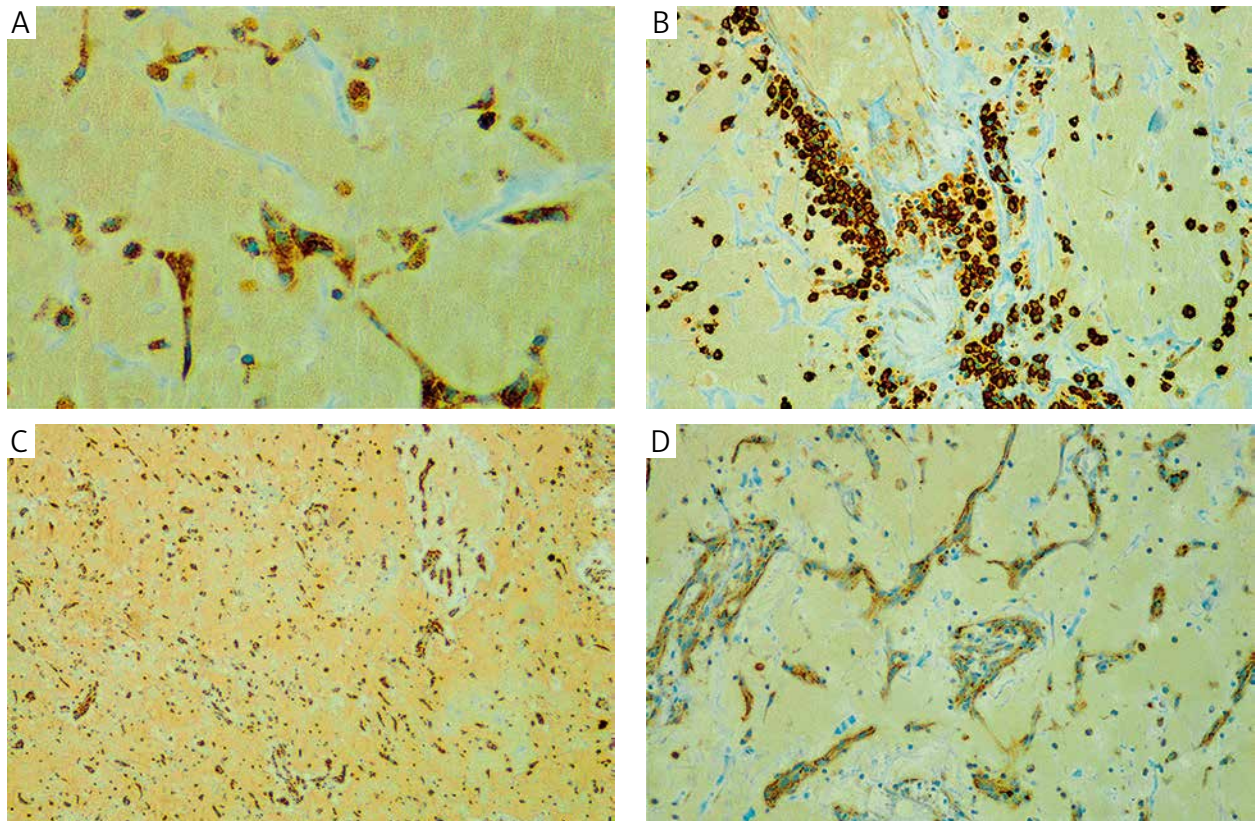


Fig. 3. A) CD9 overexpression in tumor's cells with granular type of staining (magnification 100×). B) CD9 overexpression in perivascular plasmatic cells (magnification 100×). C) CD9 as a background staining (magnification 100×). D) CD63 overexpression at the border with thrombosis and necrosis (magnification 100×)

that right-sided myxomas tend to be mainly sessile, they frequently are surfaces for thrombosis and become sites of amorphous calcifications. From a clinical point of view it is important to note that they are often diagnosed as parietal endocardial thrombus on magnetic resonance (MR) and ultrasonographic imaging. As we take into account that the differential diagnosis is hindered by a variety of calcifications in our relatively limited group, it is not unusual to record that the clinical picture is also overlapped by such degenerative changes in the literature [17, 18, 23, 34]. These additional morphological traits make tumors friable and prone to micro-fragmentation with release of particles of them to the circulation especially in sessile tumors [17, 18, 23, 34]. Although cytologically and histologically benign tumors without invasion, cardiac myxomas can disseminate via blood flow. According to some researchers, they ought not to be categorized as metastatic cardiac myxoma in any way, but others use the term “benign metastasizing tumor” [34]. Nevertheless, there was no dissemination of the myxoma particles in the bloodstream in the patients of our study. One patient in our study, a 23-years-old man with massive stroke and fragmentation of superficial projections of the tumor, could be an indirect proof of the

possibility tumor spread to the bloodstream. Clinically sessile tumors were expected to be endocardial thromboses in our material, until proved otherwise similarly to other reported concerns relating to some mainly sessile intra-cardiac masses [35, 36]. Sometimes the diagnosis is so challenging because myxomas can often imitate endocarditis or endocardial thrombosis regardless of their shape [37, 38]. There are a few other types of benign cardiac tumors, e.g. calcified amorphous tumor of the the heart, papillary fibroelastoma of the heart, or extremely rare entities such as ectopic thyroid tissue. Myxoma is diagnosed conclusively based exclusively on histopathological evaluation no matter how detailed the radiological report may be, bearing in mind that clinical signs, e.g. embolisation-related cerebral infarction and cardiac ischemia are not exclusively specific for each of these neoplasms [39, 40, 41].

We present in Fig. 2 such calcifying changes that might be a developmental continuum of Gamna-Gandy bodies in nature. Namely, slow tumor growth is connected with production of ECM and the changes within its structural protein. Elastic fiber can undergo incrustation with calcium ions and form shapeless Gamna-Gandy bodies. In other parts this phenomenon of modeling ECM makes regular perivascular

Table I. Rate of incidence of clinical and pathological features among studied myxomas

| | THE CALCIFYING CHANGES AND/OR INTRA-TUMORAL THROMBOSIS | | | |
|--|---|------------------------|--------------------------|---|
| | | OSSEOUS METAPLASIA | AMORPHOUS CALCIFICATIONS | INTRA-TUMORAL THROMBOSIS AND GAMNA-GANDY BODIES |
| Age (years) | 60.4 (13.3 SD) | 64.8 | 57.3 | 51.2 |
| Sex | n | | | |
| male | 10 | 40% (n = 4) | 60% (n = 6) | 70% (n = 7) |
| female | 4 | 75% (n = 3) | 25% (n = 1) | 50% (n = 2) |
| Size (cm) | 2.82 (0.69 SD) | 3.38 | 2.50 | 2.10 |
| Tumor location | | | | |
| left atrium | 7 | 43% | 57% | 80% |
| right atrium | 7 | 28% | 72% | 55% |
| Type | | | | |
| polypoid | 5 | 100% (n = 5) | 0% | 20% (n = 1) |
| sessile | 9 | 23% (n = 2) | 77% (n = 7) | 77% (n = 7) |
| CD9 in tumor cells and in stromal inflammatory cells | | diffuse overexpression | diffuse overexpression | diffuse overexpression |
| CD63 in tumor cells | | weak expression | weak expression | weak expression |
| CD63 in stromal inflammatory cells | | diffuse overexpression | diffuse overexpression | diffuse overexpression |
| Clinical signs (No of cases) | | | | |
| arterial hypertension | 3 cases with polypoid shape (2 left sided, 1 right sided) | | | |
| massive brain stroke | 1 case (left sided sessile type) | | | |
| atrial fibrillation | 8 cases; 6 sessile type, right sided, 2 polypoid left sided (6 cases with small sized pulmonary embolism) | | | |
| cardiac insufficiency | 5 cases (left sided – 3 polypoid and 1 sessile; right sided 2 sessile) | | | |
| syncope | 3 cases sessile left sided | | | |
| High/moderate suspicion for atrial thrombosis | | 30% | 70% | 100% |

features which can be a nucleus of osseous metaplasia foci (Fig. 2B). It seems that a central vascular canal coated with tumor cells is crucial for the following mesenchymal metaplasia. Similarly, amorphous calcifications could be a consequence of progression of Gamna-Gandy bodies. At that point one should note differences in age of patients with different types of calcifications. As presented in Table I, Gamna-Gandy bodies were observed in a younger group of patients

in comparison with amorphous calcifications and osseous metaplasia. And last but not at least, the actual role of tetraspanins as thrombotic agents fits well to the biology of myxomas as masses that favor thrombosis at least at the tumor surface. CD9 overexpression and evident expression of CD63 at the border of the thrombosis suggest their evident involvement in thrombosis [30]. The potential role of CD63 in regulation of tumorigenicity is less described than CD9.

Lupia *et al.* reported that CD63-silenced melanoma cells showed enhanced motility and invasiveness with downregulation of E-cadherin and upregulation of N-cadherin and Snail [42]. These findings, even though experimental in nature, highlight a suppressor role of CD63 in oncogenesis. In accordance with other studies about the role of tetraspanins in cancer, where CD9 is regarded as a suppressor too, our cases were characterized by strong CD9 overexpression, which could explain why myxoma tumors grow slow enough to develop osseous metaplasia with time [11, 43]. The study of Blumenthal *et al.* on cultured podocytes with mechanical stress has revealed CD9 overexpression [44]. This finding about the impact of pressure as a physical factor, is interesting enough with a connection with a specific location of cardiac myxoma which favours an atrial rather than a ventricular site for their growth.

Conclusions

The main finding of this paper is that myxomas are thrombogenic because these neoplasms hugely express CD9 – a trigger of platelet activation and aggregation and CD63 – a blood platelet activation marker. Thus, regarding CD9 and CD63 positivity of myxomas, thrombogenicity of myxomas does not derive exclusively from the fact that every intracardiac tumor constitutes a mass that disturbs blood flow through the cardiac chambers, but it can also be a consequence of expression of peculiar thrombosis-favoring proteins in tumor tissues.

The limitations of this study should be noted here. The examined group was too small to perform a reliable statistical evaluation, and it is necessary to undertake a comparative analysis with typical non-degenerated myxomas in the future.

The authors declare no conflict of interest.

The study was based on personal academic funds without any support from external organizations or companies.

References

- Singh SK, Kumar A, Tewarson V, Rani AK et al. Calcified left atrial myxoma with osseous metaplasia. *Indian J Chest Dis Allied Sci* 2012; 54: 201-203.
- Hoffmeier A, Sindermann JR, Scheld HH, et al. Cardiac tumors--diagnosis and surgical treatment. *Dtsch Arztebl Int* 2014; 111: 205-211.
- Barreiro M, Renilla A, Jimenez JM, et al. Primary cardiac tumors: 32 years of experience from a Spanish tertiary surgical center. *Cardiovasc Pathol* 2013; 22: 424-427.
- Gupta P, Kapoor A, Jain M, Kumar S, et al. A butterfly shaped mobile biatrial cardiac mass: Myxoma or something else. *Indian Heart J* 2014; 66: 372-374.
- Kośmider A, Jaszewski R, Marcinkiewicz A, et al. 23-year experience on diagnosis and surgical treatment of benign and malignant cardiac tumors. *Arch Med Sci* 2013; 9: 826-830.
- Strecker T, Rösch J, Weyand M, et al. Primary and metastatic cardiac tumors: imaging characteristics, surgical treatment, and histopathological spectrum: a 10-year-experience at a German heart center. *Cardiovasc Pathol* 2012; 21: 436-443.
- Gómez-González C, Moreno-Nieto V, Vicente-Pablos M, Fernandez-Vega I. Renal myxoma: an unexpected differential diagnosis. *Pol J Pathol* 2014; 65: 157-159.
- Campbell MD, Gelberg HB. Endocardial ossifying myxoma of the right atrium in a cat. *Vet Pathol* 2000; 37: 460-462.
- Ozcan AV, Evrengul H, Bir F, et al. Multiple myxomas originating from anterior and posterior mitral leaflets in the left ventricle leading to LV outflow tract obstruction. *Circ J* 2008; 72: 1709-1711.
- Maleszewski JJ, Larsen BT, Kip NS, et al. PRKAR1A in the development of cardiac myxoma: A study of 110 cases including isolated and syndromic tumors. *Am J Surg Pathol* 2014; 38: 1079-1087.
- Sardar MR, Lahoti A, Khaji A, et al. Recurrent right ventricular cardiac myxoma in a patient with Carney complex: a case report. *J Med Case Rep* 2014; 8: 134.
- Donato G, Conforti F, Camastra C, et al. The role of mast cell tryptases in cardiac myxoma: Histogenesis and development of a challenging tumor. *Oncol Lett* 2014; 8: 379-383.
- Verma R, Duncanson ER2, Bajpai A, et al. Right atrial thrombus arising from the junction of the right atrium and the inferior vena cava. *Cardiovasc Pathol* 2014; 23: 317-318.
- Al Zahrani IM, Alraqtan A, Rezk A, et al. Atrial myxoma related myocardial infarction: Case report and review of the literature. *J Saudi Heart Assoc* 2014; 26: 166-169.
- Seo IS, Warner TF, Colyer RA, et al. Metastasizing atrial myxoma. *Am J Surg Pathol* 1980; 4: 391-399.
- Strecker T, Agaimy A. Giant left atrial myxoma causing drop attacks by prolapsing into the mitral valve. *Int J Clin Exp Pathol* 2012; 5: 996-999.
- Scheffel H, Baumüller S, Stolzmann P, et al. Atrial myxomas and thrombi: comparison of imaging features on CT. *AJR Am J Roentgenol* 2009; 192: 639-645.
- Altundag MB, Ertas G, Ucer AR, et al. Brain metastasis of cardiac myxoma: case report and review of the literature. *J Neurooncol* 2005; 75: 181-184.
- Liesting C, Ramjankhan FZ, van Herwerden LA, et al. Systemic embolisation as presentation and recurrence of cardiac myxoma two years after surgery. *Neth Heart J* 2010; 18: 499-502.
- Puls M, Hünlich M, Schillinger W. Free-floating right heart thrombi in pulmonary embolism: therapeutic options and differential diagnosis. *Dtsch Med Wochenschr* 2014; 139: 887-891.
- Redford DT, Thompson JL, McCulloch JC, et al. Left atrial myxoma presenting as pulmonary embolism: potential role of heme oxygenase-1. *Blood Coagul Fibrinolysis* 2014; 25: 621-624.
- Soleimanpour H, Pashapour A, Mohammadi N, et al. Juvenile ischemic stroke secondary to cardiogenic embolism: a rare case report. *Int J Prev Med* 2014; 5: 117-122.
- Kamiya Y, Ichikawa H, Mizuma K, et al. A case of acute ischemic stroke due to cardiac myxoma treated by intravenous thrombolysis and endovascular therapy. *Rinsho Shinkeigaku* 2014; 54: 502-506.
- Sha D, Fan G, Zhang J. Multiple cerebral infarction as the initial manifestation of left atrial myxoma: a case report and literature review. *Acta Cardiol* 2014; 69: 189-192.
- Long Y, Gao C. Brain embolism secondary to cardiac myxoma in fifteen Chinese patients. *ScientificWorldJournal* 2014; 2014: 718246.
- Fuchs J, Leszczyszyn D, Mathew D. Cardiac myxoma causing acute ischemic stroke in a pediatric patient and a review of literature. *Pediatr Neurol* 2014; 50: 525-529.

27. Okazaki Y, Yamada S, Kitada S, et al. Significance of 18 F-FDG PET and immunohistochemical GLUT-1 expression for cardiac myxoma. *Diagn Pathol* 2014; 9: 117.
28. Donato G, Conforti F, Zuccalà V, et al. Expression of tenascin-c and CD44 receptors in cardiac myxomas. *Cardiovasc Pathol* 2009; 18: 173-177.
29. Zhang F, Kotha J, Jennings LK, et al. Tetraspanins and vascular functions. *Cardiovasc Res* 2009; 83: 7-15.
30. Israels SJ, McMillan-Ward EM. Palmitoylation supports the association of tetraspanin CD63 with CD9 and integrin alphaIIb-beta3 in activated platelets. *Thromb Res* 2010; 125: 152-158.
31. Israels SJ, McMillan-Ward EM. CD63 modulates spreading and tyrosine phosphorylation of platelets on immobilized fibrinogen. *Thromb Haemost* 2005; 93: 311-318.
32. Sobocka MB, Sobocki T, Babinska A, et al. Signaling pathways of the F11 receptor (F11R; a.k.a. JAM-1, JAM-A) in human platelets: F11R dimerization, phosphorylation and complex formation with the integrin GPIIIa. *J Recept Signal Transduct Res* 2004; 24: 85-105.
33. De Viti D, Stragapede A, Riccioni G, et al. Cardiac myxoma originating from areas of ventricular akinesia. *J Biol Regul Homeost Agents* 2014; 28: 349-350.
34. Rupp GM, Heyman RA, Martinez AJ, et al. The pathology of metastatic cardiac myxoma. *Am J Clin Pathol* 1989; 91: 221-227.
35. Laird-Fick H, Tiwari A, Narayanan S, et al. A case of comorbid myxoma and chronic lymphocytic leukemia: not just a coincidence? *Case Rep Oncol Med* 2014; 2014: 142746.
36. Mazzeffi M, Reich DL, Adams DH, et al. A mitral valve mass: tumor, thrombus, or vegetation? *J Cardiothorac Vasc Anesth* 2011; 25: 889-890.
37. Kshatriya S, Villarreal D, Liu K. Angina pectoris in a patient with protein C deficiency and deep vein thrombosis: thrombus versus myxoma? *Catheter Cardiovasc Interv* 2012; 79: 291-293.
38. Fernández-Ruiz M, López-Medrano F, Alonso-Navas F, et al. *Coxiella burnetii* infection of left atrial thrombus mimicking an atrial myxoma. *Int J Infect Dis* 2010; 14: e319-e321.
39. Choi EK, Ro JY, Ayala AG. Calcified amorphous tumor of the heart: case report and review of the literature. *Methodist DeBakey Cardiovasc J* 2014; 10: 38-40.
40. Chosia M, Waligórski S, Listewnik MH, Wiechowski S. Ectopic thyroid tissue as a tumour of the heart – case report and review of the literature. *Pol J Pathol* 2002; 53: 173-175.
41. Seto T, Takano T, Otsu Y, et al. Cardiac papillary fibroelastoma: report of three cases. *Ann Thorac Cardiovasc Surg* 2014; 20 Suppl: 893-896.
42. Lupia A, Peppicelli S, Witort E, et al. CD63 tetraspanin is a negative driver of epithelial-to-mesenchymal transition in human melanoma cells. *J Invest Dermatol* 2014; 134: 2947-2956.
43. Murayama Y, Oritani K, Tsutsui S. Novel CD9-targeted therapies in gastric cancer. *World J Gastroenterol* 2015; 21: 3206-3213.
44. Blumenthal A, Giebel J, Warsaw G, et al. Mechanical stress enhances CD9 expression in cultured podocytes. *Am J Physiol Renal Physiol* 2015; 308: F602-13.

Address for correspondence

Piotr Lewitowicz MD, PhD
Department of Pathology
Faculty of Medical Sciences
Jan Kochanowski University
IX Wieków Kielc 19
25-317 Kielce, Poland
tel. +48 41 349 69 01/09
fax +48 41 349 69 16
e-mail: lewitowicz@gmail.com