

## CASE REPORT

**DYSGERMINOMA AND GONADOBLASTOMA IN THE COURSE OF SWYER SYNDROME**

TOMASZ MILEWICZ<sup>1</sup>, SANDRA MROZIŃSKA<sup>1</sup>, WOJCIECH SZCZEPAŃSKI<sup>2</sup>, MAGDALENA BIALAS<sup>1</sup>, MARTA KIAŁKA<sup>2</sup>, KATARZYNA DOROSZEWSKA<sup>2</sup>, MONIKA KABZIŃSKA-TUREK<sup>3</sup>, ANDRZEJ WOJTYŚ<sup>3</sup>, ARTUR LUDWIN<sup>3</sup>, ŁUKASZ CHMURA<sup>1</sup>

<sup>1</sup>Department of Gynecological Endocrinology, Jagiellonian University Medical College, Krakow, Poland

<sup>2</sup>Department of Pathomorphology, Jagiellonian University Medical College, Krakow, Poland

<sup>3</sup>Department of Gynecological Oncology, Jagiellonian University Medical College, Krakow, Poland

---

We present a case of a woman with primary amenorrhea. Ultrasound imaging showed a uterus of normal size but bands of connective tissues at the site of ovaries. A genetic test was done which revealed the XY karyotype. Swyer syndrome was diagnosed. The patient did not report for the follow-up visits. Three years later, the woman reported back because of increasing abdominal circumference. The patient underwent an operation. Radical hysterectomy was performed. Histopathological examination showed dysgerminoma and gonadoblastoma on the left gonad and dysgerminoma on the right one. This case report presents the natural history of Swyer syndrome.

**Key words:** Swyer syndrome, gonadoblastoma, dysgerminoma.

---

## Introduction

---

Swyer syndrome is a type of gonadal dysgenesis. It is characterized by a male karyotype, female phenotype, normal vagina, hypoplastic uterus and streak gonads instead of ovaries. The affected person has a normal or high growth, does not develop secondary sex characteristics and suffers from primary amenorrhea [1].

Swyer syndrome was described for the first time in 1955 by G. Swyer, who presented two cases of patients with XY karyotype, normal female external genitalia, high growth and primary amenorrhea. He described it as "male pseudohermaphroditism" [2].

The incidence of Swyer syndrome is 1 : 30 000 people. In 10-20% of cases it is caused by loss of function mutations in the *SRY* gene, while in the remaining 80-90% of cases the *SRY* gene is non-mutated [3].

The first symptoms of the disease are usually observed in adolescence. Due to the lack of hormonal

activity of dysgenetic gonads there is no appearance of menstrual periods and breast development [4].

The treatment of Swyer syndrome consists of hormone replacement therapy and the removal of the gonads due to the risk of malignancy. The risk of cancer in dysgenetic gonads in patients with Swyer syndrome is significant and is estimated at 20-30%. The most common neoplasms are gonadoblastoma and dysgerminoma [5].

The likelihood of malignancy increases with age, ranging from 5% at age 15, 27.5% at age 30, up to 50% after 40 years; therefore, rapid diagnosis and removal of gonadal streak is extremely important [6].

## A case report

---

In 2010, an eighteen-year-old woman was referred to the Department of Gynecology and Endocrinology because of primary amenorrhea. Physical examination showed excessive pubic hair and clitoral hypertrophy.

Laboratory tests showed an increased level of follicle stimulating hormone (FSH) 90 mIU/ml (normal range 3.5-12.5 mIU/ml) and an estradiol level below 10 pmol/l (normal range 46-607 pmol/l). Ultrasound imaging and computed tomography (CT) of the abdomen and pelvis were performed. They showed the uterus of a normal size and shape, a normal size of the vagina but lack of ovaries. Streaks of connective tissues were present in the place of gonads. Because of the clinical presentation a genetic test was done and revealed XY karyotype. Based on physical examination and the laboratory, genetic and imaging tests, Swyer syndrome was diagnosed. Hormonal therapy was introduced and surgical removal of streak gonads was planned because of the risk of developing neoplasm. Despite the fact that the patient, her mother and other family members were informed about the health condition of the woman and its consequences, the patient did not start the treatment and did not report for the follow-up visits.

Three years later, the woman reported back to the clinic because of severe pain in the lumbar re-

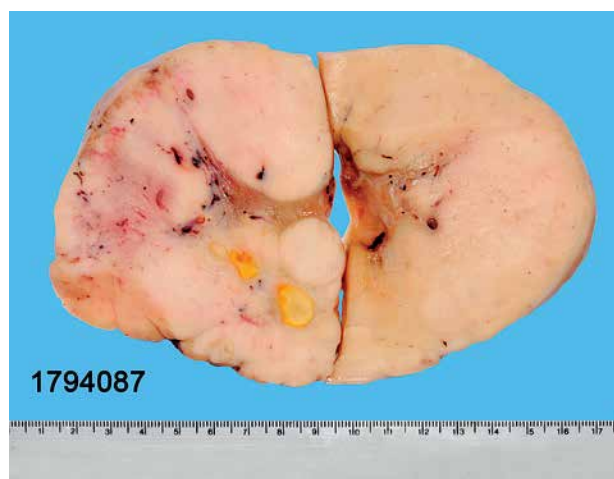

Fig. 1. White-gray, well circumscribed tumor with small foci of necrosis (nr 1794087)

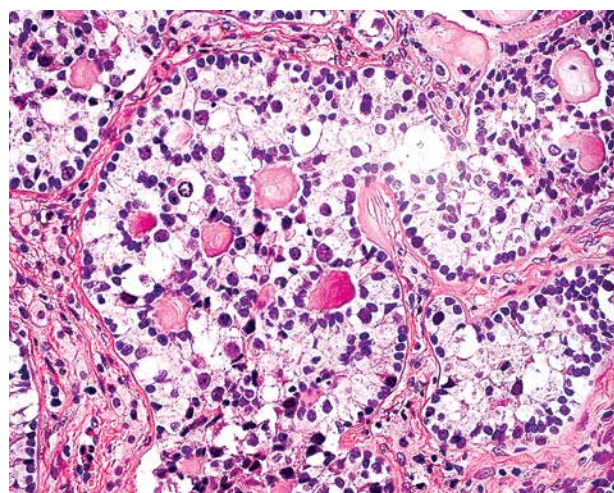


Fig. 2. Histological picture of gonadoblastoma

gion, increasing dyspnea, weakness and abdominal circumference. CT of the abdomen and pelvis was carried out. The examination showed a solid, highly vascularized tumor with a diameter of about 15 cm (14.5 cm × 8.5 cm × 18.5 cm). The tumor filled almost the entire minor pelvis and significantly compressed the urinary bladder. The CT also revealed enlarged, crumbling para-aortic lymph nodes and dilated pyelocalyceal systems. The tumor adhered laterally to the ilio-lumbar muscles and the iliac vessels, anteriorly expanded to the pubic symphysis and posteriorly infiltrated the spine and rectum. Physical examination “per vaginam” revealed that the rear wall of the vagina was lowered because of the tumor. The patient was qualified for urgent surgery.

During laparotomy an enormous, polycystic tumor with an irregular shape was exposed (Fig. 1). It derived from the right ovary.

Numerous metastases were found in the abdominal cavity and pelvis. Para-aortic lymph nodes were enlarged with characteristics of softening. The nodes formed packages about 4-5 cm. The spread was present also in the rectovaginal excavation and around the urinary bladder. Part of the tumor was resected and sent for intra-operative examination (INTRA). A result of INTRA showed a type of malignant tumor – a dysgerminoma. The reproductive organ as well as part of the gastrocolic omentum, the appendix, and the infiltration of the bladder were removed and sent for the histopathological examination. Histopathological examination of the right gonad showed a dysgerminoma and of the left gonad showed two types of malignant neoplasms – gonadoblastoma (Figs. 2 and 3) and dysgerminoma (Fig. 4). Metastases of the dysgerminoma type were present in para-aortic lymph nodes.

The postoperative course was without complications. The patient was discharged home in good condition on the seventh day after surgery. It was recommended to claim their histopathological examination

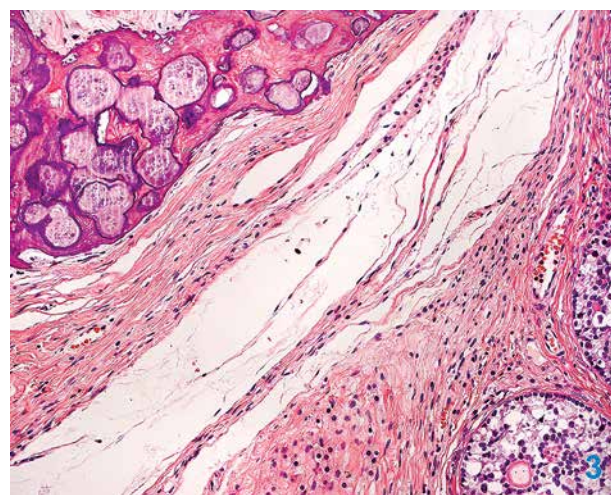


Fig. 3. Gonadoblastoma (the lower right part of the picture) with multiple calcifications (the upper left part of the picture)

after 14 days. Once again the patient was instructed that further specialist treatment was necessary.

The patient reported to the hospital after 3 months and 4 cycles of chemotherapy consisting of bleomycin, etoposide, and cisplatin were introduced.

## Discussion

The described case concerns Swyer syndrome with complications. They may present as gonadoblastoma or, what is less typical, a combination in one gonad of gonadoblastoma and dysgerminoma, giving typically para-aortic node metastases [7, 8]. Gonadoblastoma is a neoplasm frequently encountered in dysgenetic gonads in patients with phenotypic abnormalities such as androgen insensitivity syndrome, Turner's syndrome or syndrome of gonadal dysgenesis [9, 10]. Frequently lesions occur on both sides and may coexist. Surface malignant germ cell tumors can also develop, but dysgerminoma is the most frequent lesion. It is a very malignant tumor that rapidly infiltrates adjacent organs, with distant metastasis and frequent recurrences. That is why bilateral gonadectomy is an essential element in the treatment of Swyer syndrome [11, 12]. A study conducted by Radakovic *et al.* [13] showed that 55% of patients suffering from Swyer syndrome were diagnosed with gonadoblastoma or dysgerminoma. In the literature some cases of co-occurrence of gonadoblastoma with dysgerminoma [14] and gonadoblastoma with choriocarcinoma are also reported. It is assumed that gonadoblastoma is unstable and may result in choriocarcinoma [15].

In patients with primary amenorrhea one should always keep in mind such causes as Swyer syndrome. Only prompt diagnosis may allow early treatment. The risk of malignancy in patients with Swyer syndrome increases with age [16]. It is about 5% at the age of 15 years and increases to 27.5% at the age of 30 years [17]. For this reason prompt bilateral prophylactic surgery of bands of connective tissue resulting in sketch of ovaries (gonadectomy) is recommended. From the clinical stage Ic the treatment of ovarian cancer consists of surgery and chemotherapy [18, 19].

Han *et al.* describe a case of Swyer syndrome in which the patient agreed to the surgery and the bilateral salpingoophorectomy, hysterectomy and lymph node removal was performed. In the cited case dysgerminoma in the right dysgenetic gonad was found. No tumor in the left ovary and no lymph node metastasis were observed [20].

A case of dysgerminoma in a 10-year-old girl with Swyer syndrome has been reported in the literature [21]. Apart from the preventive gonadectomy, treatment of Swyer syndrome includes hormone replacement therapy to induce menstruation, evaluation of secondary sex characteristics and to prevent osteoporosis. Patients with Swyer syndrome can get pregnant

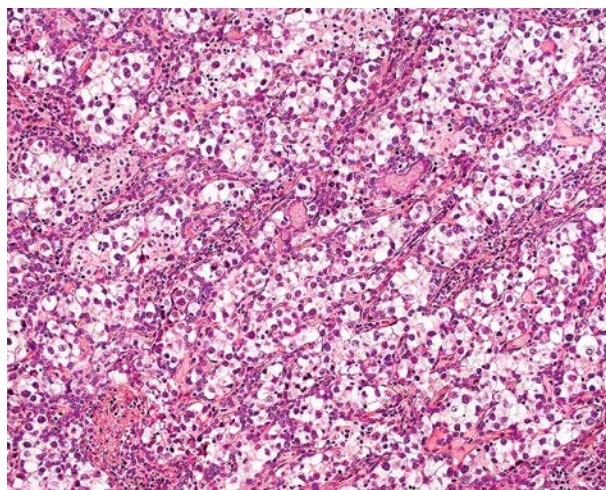


Fig. 4. Typical picture of dysgerminoma that developed on gonadoblastoma

through a combination of egg donation and the in vitro method. Some cases of women with Swyer syndrome who gave birth to a healthy child have been reported [22, 23, 24].

Swyer syndrome is a genetic disorder. 10-20% of cases are caused by a deletion in the *SRY* gene, but cases without *SRY* gene mutations have also been reported [3, 25]. New mutations in the *SRY* gene, which results in the occurrence of this disease are still described, such as a single insertion at position 38 in codon 13 [26], a double insertion in codon 38, resulting in a change in High Mobility Group Box [27] or Q 114X (c.340 C>T), or a nonsense mutation of the *SRY* gene [28].

Because of the genetic origin of Swyer syndrome the possibility of familiar occurrence should be taken into consideration. It may be necessary to test the patient's family to prevent long-term complications associated with Swyer disease [29, 30].

Kulathilake and Tayasundara also described a case of a patient diagnosed with Swyer syndrome who was lost to follow-up and later developed germ cell tumor [31].

*The authors declare no conflict of interest.*

## References

1. Novak E, Jones HW, Jones GS. Novak's textbook of gynecology. 10<sup>th</sup> ed. Williams & Wilkins, Baltimore 1980; 112.
2. Swyer GI. Male pseudohermaphroditism: a hitherto undescribed form. Br Med J 1955; 2: 709-712.
3. Jäger RJ, Anvret M, Hall K, et al. A human XY female with a frame shift mutation in the candidate testis-determining gene *SRY*. Nature 1990; 348: 452-454.
4. Michala L, Goswami D, Creighton SM, et al. Swyer syndrome: presentation and outcomes. BJOG. 2008; 115: 737-741.
5. Speroff L, Fertz MA. Clinical gynecologic endocrinology and infertility. 7th ed. Lippincott Williams & Wilkins, Baltimore 2005; 867.

6. Héту V, Caron E, Francoeur D. Hypoplastic uterus and clitoris enlargement in Swyer syndrome. *J Pediatr Adolesc Gynecol* 2010; 23: 43-45.
7. Takemori M, Ichimura T, Nishimura R, et al. Ovarian dysgerminoma with massive metastases to para-aortic lymph nodes. *Gynecol Obstet Invest* 2000; 49: 211-213.
8. Kasenda B, Harter P, Hirsch T, et al. Para-aortic lymph node metastasis in malignant dysgerminoma of the ovary. *Acta Obstet Gynecol Scand* 2009; 88: 1288-1290.
9. Scully RE. Gonadoblastoma. A review of 74 cases. *Cancer* 1970; 25: 1340-1356.
10. Page DC. Hypothesis: a Y-chromosomal gene causes gonadoblastoma in dysgenetic gonads. *Development* 1987; 101 Suppl: 151-155.
11. Hersmus R, de Leeuw BH, Wolffenbuttel KP, et al. New insights into type II germ cell tumor pathogenesis based on studies of patients with various forms of disorders of sex development (DSD). *Mol Cell Endocrinol* 2008; 291: 1-10.
12. Starzyk J, Górka A, Januś D. Czysta dysgenезja gonad 46, XY u 16 letniej fenotypowej dziewczynki – przedstawienie przypadku. *Endokrynol Diabetol Chor Przemiany Materii Wieku Rozw* 2005; 2: 115-117.
13. Radaković B, Jukić S, Buković D, et al. Morphology of gonads in pure XY gonadal dysgenesis. *Coll Antropol* 1999; 23: 203-211.
14. Zielińska D, Zajęcek S, Rzepka-Górka I. Tumors of dysgenetic gonads in Swyer syndrome. *J Pediatr Surg* 2007; 42: 1721-1724.
15. Beaulieu Bergeron M, Soglio DB, Maietta A, et al. Coexistence of a choriocarcinoma and a gonadoblastoma in the gonad of a 46,XY female: a single nucleotide polymorphism array analysis. *Pediatr Dev Pathol* 2010; 13: 66-71.
16. Manuel M, Katayama PK, Jones HW Jr. The age of occurrence of gonadal tumors in intersex patients with a Y chromosome. *Am J Obstet Gynecol* 1976; 124: 293-300.
17. Hetu V, Caron E, Francoeur D. Hypoplastic uterus and clitoris enlargement in Swyer Syndrome. *J Pediatr Adolesc Gynecol* 2010; 23: e43-e45.
18. Zhu J, Liu X, Jin H, et al. Swyer syndrome, 46,XY gonadal dysgenesis, a sex reversal disorder with dysgerminoma: a case report and literature review. *Clin Exp Obstet Gynecol* 2011; 38: 414-418.
19. Kerimoglu OS, Incesu F, Yilmaz SA, et al. Dysgerminoma complicating Swyer syndrome: A case report. *IJMMS* 2013; 1: 15-16.
20. Yang Han, Yan Wang, Qingchang Li, et al. Dysgerminoma in a case of 46, XY pure gonadal dysgenesis (Swyer syndrome): a case report. *Diagn Pathol* 2011; 6: 84.
21. Michala L, Goswami D, Creighton SM, et al. Swyer syndrome: presentation and outcomes. *BJOG* 2008; 115: 737-741.
22. Creatsas G, Deligeoroglou E, Tsimaris P, et al. Successful pregnancy in a Swyer syndrome patient with preexisting hypertension. *Fertil Steril* 2011; 96: e83-5.
23. Tulic I, Tulic L, Micic J. Pregnancy in patient with Swyer syndrome. *Fertil Steril* 2011; 95: 1789.e1-2.
24. Bianco S, Agrifoglio V, Mannino F, et al. Successful pregnancy in a pure gonadal dysgenesis with karyotype 46,XY patient (Swyer's syndrome) following oocyte donation and hormonal treatment. *Acta Eur Fertil* 1992; 23: 37-38.
25. Midro AT, Panasiuk B, Wolczyński S, et al. Clinical examinations, chromosomal and molecular DNA in patients with Swyer syndrome. *Ginekol Pol* 1993; 64: 257-262.
26. Marchina E, Gambera A, Spinelli E, et al. Identification of a new mutation in the SRY gene in a 46,XY woman with Swyer syndrome. *Fertil Steril* 2009; 91: 932.e7-932.e11.
27. Battiloro E, Angeletti B, Tozzi MC, et al. A novel double nucleotide substitution in the HMG box of the SRY gene associated with Swyer syndrome. *Hum Genet* 1997; 100: 585-587.
28. Machado C, Pereira A, Matos Cruz J, et al. A novel SRY non-sense mutation in a case of Swyer syndrome. *Journal of Pediatric and Neonatal Individualized Medicine* 2014; 3: e030107.
29. Moreira AI, Silva JC, Ferreira MS, et al. Bilateral dysgerminoma in a patient with a previous diagnosis of Swyer syndrome. *J Obstet Gynaecol Res* 2012; 38: 452-454.
30. Ates S, Batmaz G, Sevket O, et al. Familial Swyer syndrome in two sisters with undeveloped uterus. *J Obstet Gynaecol* 2014; 34: 540-541.
31. Kulathilake DT, Jayasundara C. A germ cell tumor in a patient with Swyer syndrome with ambiguous genitalia. *BMC Res Notes* 2015; 8: 747.

### Address for correspondence

**Katarzyna Doroszevska**

Department of Gynecological Endocrinology

Jagiellonian University Medical College

Kopernika 17

Krakow, Poland

e-mail: katarzyna.doroszevska@gmail.com