

REVIEW PAPER

MEMBRANOUS GLOMERULONEPHRITIS – A COMMON, UNSPECIFIC PATTERN OF GLOMERULAR INJURYALEKSANDRA STARZYŃSKA-KUBICKA¹, AGNIESZKA PERKOWSKA-PTASIŃSKA², BARBARA GÓRNICKA¹¹Department of Pathology, Medical University of Warsaw, Poland²Department of Transplantology, Nephrology and Internal Diseases, Medical University of Warsaw, Poland

Membranous nephropathy (MN) is a chronic form of glomerulonephritis, associated with the presence of immune complexes beneath the podocytes on the sub-epithelial region of glomerular capillaries. MN is not a disease entity but one of relatively common patterns of glomerular injury that may be a manifestation of primary renal autoimmunological reaction or may evolve as a phenomenon secondary to wide spectrum of systemic processes.

Key words: membranous glomerulonephritis, membranous nephropathy, PLAR-related MN.

Introduction

Membranous glomerulonephritis (MN) is one of the most common types of chronic glomerulonephritis in the world. Morphologically MN is defined by progressive, diffused thickening of glomerular basement membrane (GBM), which is secondary to the accumulation of immune complexes in a subepithelial region of glomerular capillaries. The main clinical MN manifestation is significant proteinuria [1]. Membranous glomerulonephritis may be a manifestation of primary renal autoimmunological reaction or may evolve as a phenomenon secondary to various systemic processes. This review concentrates on the pathogenesis, morphology, and clinical associations of this relatively common glomerulopathy.

Epidemiology

Membranous glomerulonephritis is one of the most common types of glomerulonephritides (GNs) in adults worldwide: second after IgA nephropathy (IgAN) or third after IgAN and focal segmental glo-

merulosclerosis (FSGS) in Europe and Japan [1, 2, 3, 4, 5], regardless of the ethnicity [6]. In the US MN prevalence follows FSGS but precedes IgAN [6]. Interestingly, studies from different countries consistently show that MN is the most common GN in the elderly [1, 2, 3, 4, 5, 7].

According to several studies the incidence of MN has remained stable for many years [6, 8] ranging from 4.0 p.m.p./year in the Czech Republic [3] to 10.8 p.m.p./year in the UK [2]. Although some studies suggest growth in its incidence [2, 3], it might be related to the general increase in the number of renal biopsies performed each year [2, 3] and changes in biopsy policies, especially regarding elderly patients [3, 8]. Membranous glomerulonephritis incidence increases with age [3]. Peak frequency of MN is at around 60 years of age (55-64 years), and peak relative frequency is at approximately 70 years of age (65-74) [4]. The mean age of patients with histopathological diagnosis of MN is around 50 years [3, 4]. There is a male predominance among MN patients (male-to-female ratio around 1.4 : 1 to 2 : 1) in Europe [1, 3, 4]. In Asia the male-to-female

ratio is varied: from 2 : 1 in Korea [7] to no difference between genders in Japan [5].

Membranous glomerulonephritis is not a disease entity but a common histopathological pattern of glomerular injury. Most commonly (70-80% of cases) it arises as a manifestation of local autoimmunological reaction (idiopathic or primary MN [pMN]), but it may also be a reflection of various infectious, systemic autoimmunological, drug toxicity-related, or neoplastic processes – secondary MN (sMN).

Pathogenesis of membranous glomerulonephritis

Membranous glomerulonephritis was not a separate entity until 1956, when Jones published his new staining method that showed GBM in better contrast and, therefore, detail. Using periodic acid silver methenamine sequence he was able to visualise “silver-positive club-shaped” projections of GBM, later described as “spikes” [9]. The immunological nature of this glomerulopathy was already suspected at that time, which was partially substantiated in 1957 by the recognition of gamma globulins deposited in glomeruli affected by MN [10]. However, the sequence of events leading to glomerular deposits and proteinuria as well as the antigen itself remained unknown.

A lot of light was shed on the pathophysiology of MN in 1959, when Heymann created an animal model of MN utilising homogenates of rat kidney cortex. This model exists in two forms: active and passive Heyman Nephritis (AHN and PHN). In the active model the administration of proximal tubular brush border elicits the production of autologous antibodies to renal antigen by the animal's own immune system. In PHN MN evolves after the administration of anti-brush border antiserum generated in another animal and is composed of two phases: an initial heterologous phase, in which injected antibodies bind to podocytic antigens, and a subsequent autologous phase related to the formation of the animal's own antibodies against the injected ones. In Heymann nephritis the immunologic reaction is targeted against antigenic complex (Heymann nephritis antigenic complex – HNAC). The HNAC main antigen is megalin, a glycoprotein expressed in both the brush border of proximal tubular cells and in pits on the sole of podocyte foot processes [11]. It has been shown that these pits are the initial spot of immune complex (IC) formation in both AHN and PHN models. Once formed, IC are rapidly shed into the subepithelial space, where they accumulate in the lamina rara externa of the glomerular basement membrane (GBM) until they obscure the slit diaphragm [11]. The IC deposition triggers complement activation, which mediates further podocytes damage and proteinuria. Although the Heymann ne-

phritis model has greatly enriched the understanding of MN origin and evolution, the rest of the puzzle, namely the antigen (antigens) involved in pMN evolution in humans, remained unknown for years.

In the 1980s interest in the role of the antigen electrical charge in the GN pathogenesis arose because the glomerular wall is not only a size-selective but also a charge-selective barrier, due to its polyanion composition. Border *et al.* [12] analysed the results of diverse forms of bovine serum albumin (BSA) injections into rabbits and found that the following lesions significantly differed: cationic BSA almost exclusively caused subepithelial deposits accompanied by proteinuria, while anionic and native BSA tended to cause mesangial deposits and hypercellularity [12]. Further experiments showed that IC were formed *in situ* secondary to cationic BSA binding to the podocytic basement membrane [13]. These experimental findings were then confirmed in 2011 in cases of early-childhood MN, associated with *in situ* subepithelial formation of IC containing cationic BSA and anti-BSA IgG antibodies [14].

In 2002 Debiec *et al.* published a case report of an antenatal MN caused by anti-neutral endopeptidase (NEP) antibodies aroused in the NEP-deficient mother [15, 16]. NEP is a zinc-dependent metallopeptidase present on the cell surface of many human and rabbit organs, including podocyte basement membrane [16]. NEP-deficiency was found to be a reflection of the NEP coding gene functional knock-out related to its autosomal recessive, truncating mutation [17]. A mother's NEP deficiency leads to her immunisation against the foetal NEP with subsequent *in situ* IC formation in the subepithelial region of neonatal glomerular capillaries [15, 16]. The severity of the neonatal renal disease was found to be dependent on the anti-NEP antibodies titre as well as their subclass [18].

In 2009 Beck *et al.* published their breakthrough discovery of the 185-kD glycoprotein that was bound by antibodies present in the sera from patients with pMN [19]. Their work was a tremendous step forward in understanding MN pathogenesis because they not only found the target protein but also managed to identify it as an M-type phospholipase A2 receptor (PLA2R) and performed a detailed analysis of the circulating antibodies. The findings of Beck *et al.* opened a new path of research for new diagnostic and prognostic tools in MN. Over the last decade many studies focusing on aPLA2R-ABs and their antigen target were performed across the world [19, 20, 21, 22, 23].

aPLA2R-ABs titres were identified as a prognostic factor and early predictor of remission because changes in aPLA2R-AB levels precede the corresponding changes in MN activity (defined by the level of albuminemia and urine protein loss) [20] regardless of whether they arise spontaneously or in relation to immunosuppressive

treatment [20]. Some patients who produce low quantities of the antibody may be seronegative until the antibody has saturated the PLA2R binding sites on podocytes and only then become seropositive [24]. Since the absence of aPLA2R-ABs in an MN patient's serum does not exclude the diagnosis of PLAR-related MN [22], the additional method allowing for its recognition is the identification of PLA2R antigen in glomerular deposits [22, 23, 25]. PLA2R tissue staining was found to be particularly useful in the case of delayed serum sampling [22]; it also created the possibility of a retrospective diagnosis of PLA2R-related MN [22], especially because tissue preparation (frozen vs. paraffin embedded) did not significantly affect staining results [23]. Serologic and histologic techniques for detecting aPLA2R-ABs and PLA2R antigens are useful prognostic and diagnostic tools, helpful in the differentiation between pMN and sMN. Their correlation with pMN is still disputable, however, with some studies reporting nearly 100% specificity [25, 26] and others documenting aPLA2R-ABs presence in some cases of HBV-, HCV-, sarcoidosis-, and neoplasm-related sMN [19, 22, 27, 28]. The term "PLAR-related MN" seems therefore more suitable.

In 2014 Tomas *et al.* [29] discovered thrombospondin Type-1 Domain-Containing 7A (THSD7A), a transmembrane protein expressed on podocyte foot processes [29]. The prevalence of anti-THSDA7 antibodies' (a-THSD7A-ABs') is about 10% of a-PLA2R-ABs-negative pMN patients [29, 30] and about 2.5-5% of all pMN patients in European and US cohorts [29]. Much higher prevalence (9.1% of pMN patients) was reported in a Japanese study [31]. Although initial studies spoke for the mutual exclusivity [29, 30], in 2016 the first two cases of dual positivity (the concomitant presence of a-THSD7A-ABs and a-PLA2R-ABs) were published [30]. Some similarities regarding antibodies against PLA2R and THSD7A were documented: IgG4 is a dominant/co-dominant subclass [29, 30, 31], and the level of antibodies seems to correlate with disease activity [29]. The fact that (in contrast to PLA2R) THSDA7 is also expressed on murine podocytes has been exploited in a series of experiments, which revealed that murine THSD7As was bound by human antibodies from the sera of patients with THSD7A-related MN and that the injection of these sera into mice is followed by proteinuria development [32]. These observations proved the relationship between podocyte-directed auto-antibodies and the development of MN [32]. Patients with THSD7A-related MN show typical clinical presentation together with ordinary MN histomorphology [29, 30, 32] and do not significantly differ in basic clinical characteristics (age, urinary protein, serum albumin, serum creatinine) from patients with PLA2R-related

MN [29, 31] except for gender: THSD7A-related MN is more prevalent in female patients [29].

Apart from the MN cases being a manifestation of local glomerular autoimmunological reaction, MN may evolve as secondary to the presence of subepithelial IC containing antigens that are not a glomerular component. Secondary MN comprises about 30% of MN cases [33] and is itself a very heterogenous group. Among the major causes are lupus nephritis (WHO class V) [34], various drugs such as NSAIDs [35], penicillamine [36, 37] and gold salts [36], hepatitis B virus [38] and other infections [39, 40], sarcoidosis [27], haematopoietic stem cell transplantation [41], and various malignancies [42, 43]. The association between these agents and conditions and MN evolution is largely based on the observation that their elimination leads to the resolution of proteinuria.

The relation between MN and malignancy seems particularly important. It was first described by Lee *et al.* in 1965 [44] and since then many studies were published confirming this phenomenon [43, 45, 46]. The prevalence of malignancies in MN patients ranges from 5 to 20%, particularly in those aged > 65 years [43, 44, 47, 48]. MN individuals are at 2 to 12 times higher risk of malignancy than other members of the general population after adjustment for age and gender [42]. The mechanism of this intriguing relationship remains unclear. Since the very beginning researchers suspected that renal lesions in malignancy-related MN could be a result of the host's immune response to the neoplasm [44], but finding a direct link proved to be challenging because there are several factors that may be misleading [49]. There might be detection bias connected to the fact that MN patients are more vigorously screened for malignancies [49]. Also, both MN and malignancy tend to occur in elderly patients [49], and older age is the only significant risk factor of neoplasia-related MN [42, 43, 45, 46, 47]. Lastly, the use of alkylating agents, such as cyclophosphamide, in the treatment of MN can also increase the risk of subsequent malignancy [47]. The most common carcinoma related to MN is lung cancer [42, 47, 49], but numerous other locations (e.g. prostate, breast, gastrointestinal tract) were also reported [42, 43, 44, 49]. Although MN is actually the most frequent GN associated with solid tumours [44, 49], its relationship with haematological malignancies was also reported [43, 49].

One of the rare, peculiar types of MN is membranous-like glomerulopathy with masked IgG- κ . It is a type MN with a typical morphology in light microscopy and EM, which is negative for Ig and light chains in standard immunofluorescence on frozen tissue. Only the usage of formalin-fixed pronase-digested, paraffin-embedded tissue allows for the detection of IgG deposits with light κ chain restriction. The aetiology

of this condition is unknown, but the majority of cases reported so far were young individuals, mostly women with autoimmune disorders [50].

Genetic factors

In search of causative factors for pMN, genetic studies were also involved that focused on genes related to inflammatory process [51, 52], autoimmunity [43, 54, 55], and PLA2R [53, 54, 55]. It was shown that the TNF- α (a pro-inflammatory cytokine) gene is associated with an increased susceptibility to MN [51]; a correlation between high-risk STAT4 (transcription factor involved in inflammation) allele and higher frequency of kidney failure in MN patients was also established [52]. These findings support the role of inflammatory response and cellular injury in the pathogenesis of MN. Genome-wide association studies (GWAS) of single-nucleotide polymorphisms (SNPs) performed in large European [53] as well as Chinese [54] and Indian [55] cohorts of patients with pMN identified two genomic *loci*, HLA-DQA1 and PLA2R1, to be associated with higher risk of MN.

Membranous glomerulonephritis morphological picture

Membranous glomerulonephritis is a chronic glomerulonephritis related to the presence of immune complexes (IC) in the subepithelial region of glomerular basement membrane (GBM), causing diffuse GBM thickening accompanied by the effacement

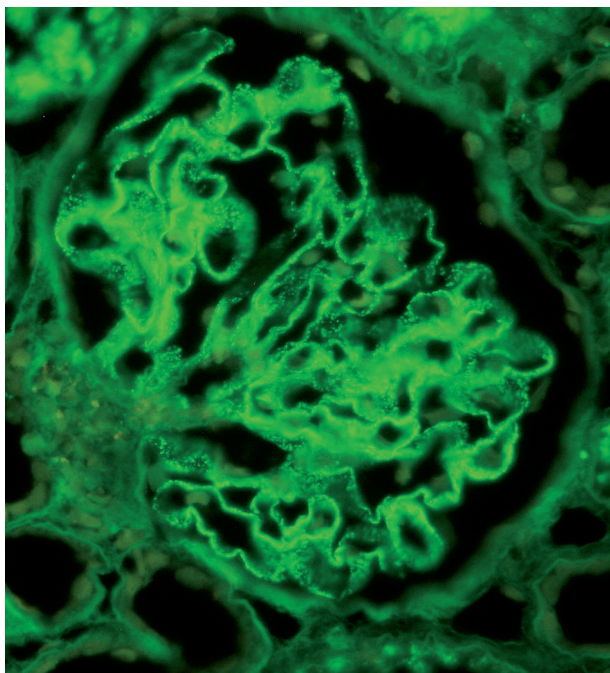


Fig. 1. Finely granular IgG deposits along GBM. Immunofluorescence

of the foot processes of the overlying podocytes. Morphological changes in glomeruli reflect structural responses of GBM to IC deposits and were ascribed by Ehrenreich and Churg to four stages [56] based on electron microscopy findings. The description of these stages was later extended to include lesion characteristics visualised through light microscopy and immunomorphological analysis. The initial phase of MN evolution is limited to IgG-containing IC accumulation on the outer aspect of GBM, which may be detected by immunofluorescence and electron microscopy (Figs. 1, 2). These deposits are finely granular, dispersed, and do not seem to evoke any changes in the neighbouring GBM except perhaps for small, focal depressions, which are inconsistently present. These early (stage I) lesions are not recognisable in light microscopy [57]. In the second stage the deposits become larger and separated by GBM projections (Fig. 3), which may be demonstrated in light microscopy by Jones methenamine silver (JMS) stain in the form of silver-stained “spikes” on the outer GBM aspect (Fig. 4). In further MN stages deposits become entirely incorporated in thickened GBM (Fig. 5). With time the deposits undergo resorption, which results in their electron density variability reflected by the vacuolar appearance acquired by GBM in JMS staining (Figs. 6, 7).

Along the MN evolution there is a change in the appearance of deposits in immunomorphological visualisation: initially finely granular and uniform, later becoming more massive (Fig. 8). Deposits consist mostly of IgGs and C3; they stain most vividly in the initial stage, then gradually decrease in intensity. In the case of remissions (spontaneous or treatment-related) there is a decrease in the number of subepithelial deposits, and the persisting ones become more lucent, which is a hallmark of their resolution. Repeated kidney biopsies in patients with at least partial resolution of proteinuria

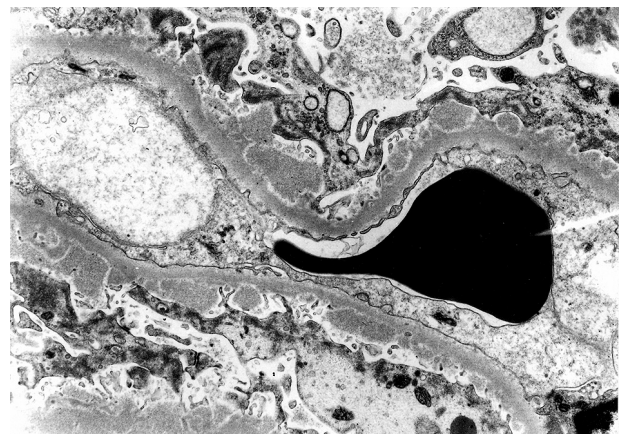


Fig. 2. Membranous glomerulonephritis stage 1, with fine subepithelial electron dense deposits. Electron microscopy

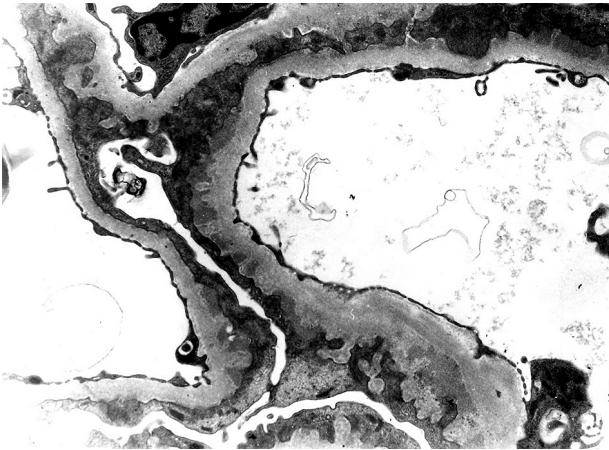


Fig. 3. Membranous glomerulonephritis stage 2, hallmarked by the presence of subepithelial electron dense deposits separated by GBM projections. Electron microscopy

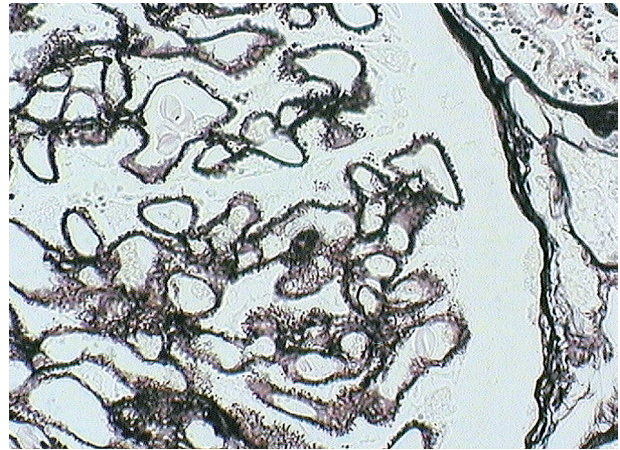


Fig. 4. Silver-stained spikes on the outer aspect of GBM. JMS stain

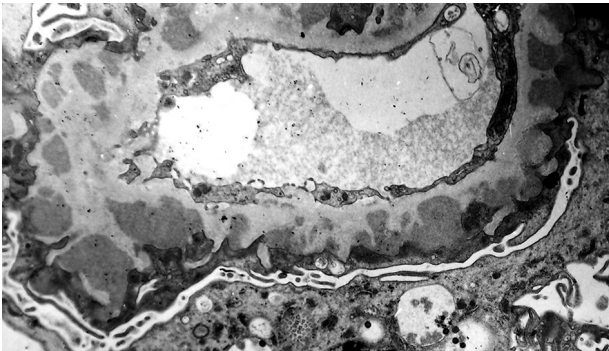


Fig. 5. Membranous glomerulonephritis stage 3, with subepithelial and intramembranous deposits. Electron microscopy

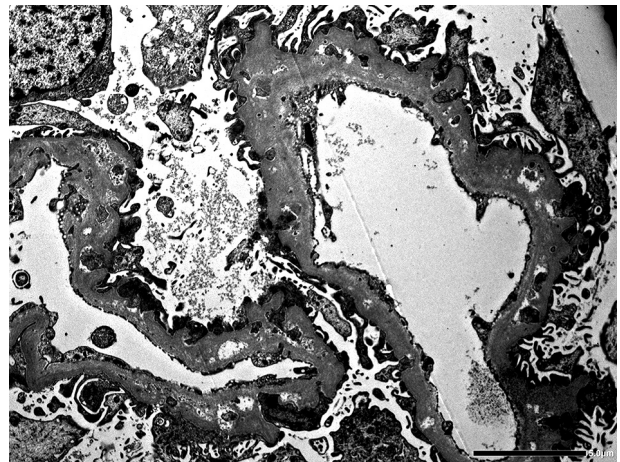


Fig. 6. Membranous glomerulonephritis stage 4. Electro-lucent areas represent intramembranous deposits in the resolution phase. Electron microscopy

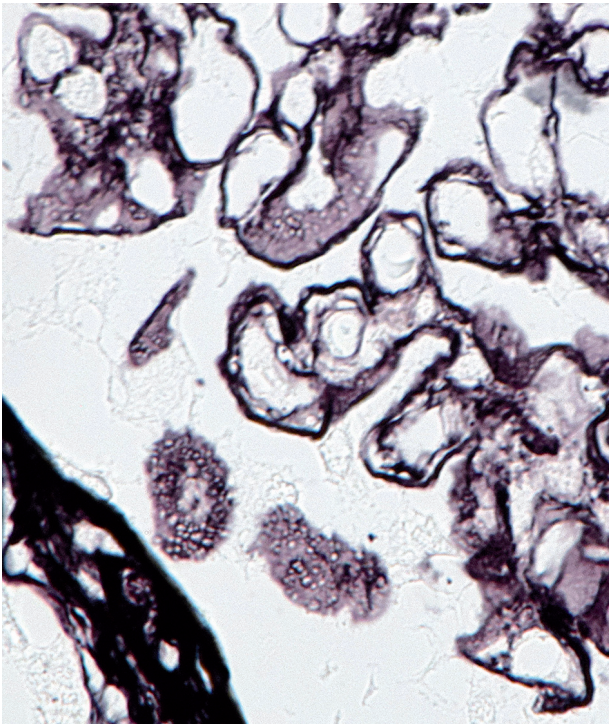


Fig. 7. Double contouring of some of glomerular capillaries, vacuolar appearance of the obliquely sectioned GBM. JMS stain

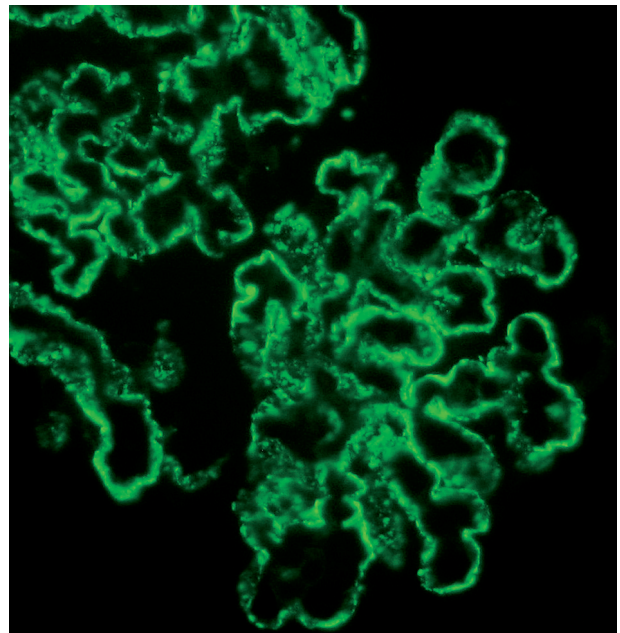


Fig. 8. Coarse granular IgG deposits along GBM. Immunofluorescence

additionally show the regression of abnormalities seen in the structure of podocytes [58].

In some cases (10.4 to 51.9% [59] with a mean value of 23.7%) MN is complicated by the superimposition of secondary focal segmental glomerulosclerosis (FSGS). Focal segmental glomerulosclerosis is typically seen in more advanced stages (III and IV) [60] and correlates in more advanced stages with tubular atrophy and interstitial fibrosis [60]. The overlap of secondary FSGS upon MN is considered a scarring response to the immune complex-induced injury [59, 60].

The presence of tubulointerstitial lesions in the form of inflammatory infiltration, interstitial fibrosis (IF), and tubular atrophy (TA) is considered a negative prognostic factor, which correlates with worse patient outcome, greater decline in estimated glomerular filtration rate (eGFR), and quicker progression to end-stage renal disease (ESRD) [61]. Glomerular density (GD) defined as the relation between the number of non-sclerotic glomeruli and renal cortical area of the biopsy could be an earlier predictor of renal outcome in MN, since low GD was associated with a greater risk of eGFR decline or progression to ESRD [62]. However, it is a non-specific marker because nephron loss and the subsequent hyperfiltration are associated with a worse prognosis in many other glomerular diseases [62].

Other patterns such as “full house” staining for immunoglobulins, the presence of mesangial or sub-endothelial immune deposits, glomerular inflammatory infiltrates, fibrinoid necrosis, and crescent formation are not typical for MN.

Membranous glomerulonephritis clinical presentation, natural history, and prognosis

The main clinical presentation of MN in all age groups is nephrotic range proteinuria (NRP) [1] making MN the second cause of nephrotic syndrome (NS) in the whole adult population [3, 5] and the first in patients aged ≥ 65 years [1, 4, 7]. Approximately 73% of adult MN patients have nephrotic syndrome [1]. The mean level of proteinuria at the time of presentation in MN patients ranges from 3.9 to 9.1 g/day [63, 64]. About 25-30% of MN patients present with sub-nephrotic proteinuria. Microscopic haematuria can be present, but macroscopic haematuria almost never occurs. Other clinical presentations of MN, such as asymptomatic urinary abnormalities, are also possible but much less frequent [1].

At the time of MN presentation renal function is mostly preserved with a mean eGFR around 75 ml/min/1.73 m² [63] and approximately 30% of patients present with some degree of renal insufficiency.

Membranous glomerulonephritis is generally considered to be a nephropathy with a relatively good prognosis, with about 30% of patients experiencing

spontaneous remission. In untreated patients the risk of end-stage renal failure is approximately 14% at 5 years, 35% at 10 years, and 41% at 15 years [65]. The tool most commonly used in individuals with MN for the prognosis prediction is the Toronto Risk Score. This risk calculation is based on time-average proteinuria (highest sustained six-month period of proteinuria), creatinine clearance at diagnosis, and the slope of creatinine concentration over six months [66]. Additionally, several factors not included in the Toronto Risk Score formula have been used in the MN prognosis prediction, such as urinary excretion of β_2 - and α_1 -microglobulins, as well as the titre of a-PLA2R-AB in the serum [67].

IgG classes in membranous glomerulonephritis

In pMN the dominating IgG subclass in the sub-epithelial IC is IgG4 [23]. Studies addressing the IgG subclass distribution across different stages of pMN show that in the early stage there is a domination of IgG1, whereas IgG4 is the most prevalent one in the later phase of this glomerulopathy evolution. It has also been documented that among rare pMN cases with segmental deposit distribution there was a dominance of IgG1 and IgG3, whereas in the global form of this glomerulopathy IgG4 was the main subclass present [46, 68, 69, 70, 71]. Notably IgG4 has been also recognised as a negative prognostic factor; it has been shown that it correlates with higher levels of plasminogen activator inhibitor type I (PAI1), and higher PAI1 levels lead to more severe fibrosis [72].

The origin of proteinuria and complement system activation in membranous glomerulonephritis

The principal cause of proteinuria in MN is podocyte injury [73]. Podocytes have several functions, including slit diaphragm formation and assembling of GBM, in which dozens of different proteins take part. One of the mechanisms responsible for proteinuria is a disturbance in the functional link between podocyte cytoskeleton and a slit diaphragm construction [74]. Such a disturbance may be triggered by IC-induced complement activation, in which sublytic quantities of C5-9 membrane attack complex (MAC) cause the dissociation of nephrin from podocyte cytoskeleton, loss of slit diaphragm integrity, and early protein loss [75, 76, 77]. The subsequent increase in actin and decrease in alpha-integrin expressions within podocytes lead to effacement of foot processes, with further proteinuria enhancement [78]. Apart from direct podocyte injury, C5b-9 complex may also exert an injurious effect through the induction of reactive

oxygen species (ROS) production with subsequent damage of podocyte lipids, membrane proteins, and GBM components, thus altering the cell membrane structure of podocytes essential for glomerular permeability maintenance.

The data collected so far on the complement system involvement in MN evolution is still not coherent. C3 and C5b-9 are universally present in subepithelial deposits, and, as was already mentioned, IgG4 seems to be the dominant/codominant subclass in PLA2R-associated MN [23, 79]. In contrast to other IgG subclasses, IgG4 does not activate the classical complement system, which points to the alternative or lectin pathways as the major operators of C5-9 complex formation in pMN. This phenomenon is reflected by a negative correlation between IgG4 and C1q staining in glomeruli of MN patients, although small admixtures of other IgG subclasses (particularly IgG1) may cause some C1q deposition [80]. The deposition of C3c (a short-lived breakdown product of C3), a constituent of lectin and alternative pathways, was shown in almost all cases of MN [68]. On the other hand, there are reports documenting the deposition of C4d, elaborated via classical or lectin pathways in 100% of MN cases. The above findings point to the lectin pathway as an operator of MN evolution, possibly with the cooperation of another two pathways [81]. It has been proposed that IgG1 may dominate in the early phase of MN development, causing an initial activation of the classic pathway, which subsequently could be replaced by IgG4 domination with the enhancement of alternative or lectin pathways [68]. It has also been shown that in pMN patients with a genetic and functional deficiency in lectin pathway the alternate pathway is probably the functional one that is activated [82]. In turn, the activation of classic pathway, marked by C1q deposition, is more closely related to sMN than pMN [80].

It is worth mentioning that complement activation stimulates the enforcement of protective mechanisms targeted against complement-dependent cytotoxicity, such as membrane attack complex (MAC) transportation (via endo- and subsequent exocytosis) through podocytes into the urinary space [83, 84]. Interestingly, proteinuria in MN may also occur via direct modification of podocyte biology by the antibodies themselves, without C5b-9 assembly [85, 86].

An additional mechanism proposed as an operator in proteinuria occurrence is podocyte injury-induced expression of matrix metalloproteinase-9 (MMP-9), which is thought to trigger collagen IV degradation and to alter GBM composition. B7-1 (CD80), a molecule that is normally expressed on B-cells and other antigen-presenting cells, seems to play a role in glomerular danger signalling [87]; it is expressed by podocytes under a variety of stress conditions. It was also shown to contribute to the pathogenesis of pro-

teinuria by altering the podocyte cytoskeleton, which in turn leads to slit diaphragm disruption [87]. Another GBM constituent, suppression of which may play a role in the proteinuria development, is nephronectin [74].

Treatment

The treatment of pMN has always been challenging, mostly due to the variable clinical course of pMN, which is difficult to predict because one third of MN patients attain spontaneous remission [88], while approximately 15% of them reach end-stage kidney disease after 10 years [89]. The overall kidney survival is quite high, reaching 86% after 10 years [89], but nephrotic syndrome (NS), which is the main clinical feature of MN, is associated with significant morbidity (malnutrition, increase in infection susceptibility, cardiovascular disorders, hypercoagulability etc.) [90, 91, 92]. There are no reliable indicators of spontaneous remission [92].

In 2012 Kidney Disease: Improving Global Outcomes (KDIGO) released pMN management guidelines, in which a restrictive treatment strategy was proposed: immunosuppression is reserved for patients with NS, who either show no improvement after six months of supportive therapy (diet modifications, reduction of protein loss via a decrease in glomerular filtration pressure), present severe, disabling NS symptoms, or their renal function is declining [90, 93, 94, 95]. Obviously, patients with remission of proteinuria are less likely to progress to ESRD [88, 90], but even partial remission (PR) improves the prognosis [88]. Although relapse is more frequent after a PR [96], immunosuppression is still worth trying because even after a relapse a second proteinuria remission remains a good prognostic factor [96].

The gold standard for pMN immunosuppressive treatment is the modified Ponticelli regimen: administration of glucocorticoids (GC) and alkylating agents (AA) alternating monthly for six months [91]. Alternative treatment options include calcineurin inhibitors (CNI), mycophenolic acid (MMF), rituximab, ACTH, and plasmapheresis [91].

Membranous glomerulonephritis and kidney transplantation

Membranous glomerulonephritis appears several times in the context of kidney transplantation because it can be the cause of ESRD, leading to the need of renal transplant, but it can also occur in the graft as recurrent disease (primary or secondary), de novo disease [97], or, extremely rarely, be of donor origin [98].

About 3% of all patients who undergo kidney transplantation reach ESRD due to MN [99]. The overall

MN prevalence in kidney grafts ranges from 1 to 5% [99, 100] in different studies and seems to be rising [100]. Clear distinction between recurrent MN (rMN) and de novo MN (dnMN) may be impossible because it requires pre-transplant diagnosis of the cause of ESRD in the native kidney, which is not always available [97]. Different approaches towards pre- and post-transplantation biopsy (e.g. protocol vs. clinically guided biopsy) lead to various data regarding rMN and dnMN prevalence described by different authors [97, 101].

De novo MN is often accompanied by morphologic signs of rejection [102, 103]. This leads to an interesting concept, first presented by Ponticelli and Glassock [102], that due to alloimmune podocyte injury there is exposure of cryptic podocyte antigens, which become the trigger for dnMN [103].

Summary and conclusions

Membranous glomerulonephritis is one of the most common types of glomerulopathy diagnosed on the basis of kidney biopsy examination. It reflects a certain pathomechanism of glomerular injury and should not be considered a disease entity. Membranous glomerulonephritis recognition imposes the implementation of a wide diagnostic repertoire, both clinical and morphological, aiming at the determination of the MN nature. Treatment decisions are individually tailored depending on the MN origin and its clinical associations.

The authors declare no conflict of interest.

References

- Perkowska-Ptasinska A, Bartczak A, Wagrowska-Danilewicz M, et al. Clinicopathologic correlations of renal pathology in the adult population of Poland. *Nephrol Dial Transplant* 2017; 32 (suppl 2): ii209-ii218.
- Hanko JB, Mullan RN, O'Rourke DM, et al. The changing pattern of adult primary glomerular disease. *Nephrol Dial Transplant* 2009; 24: 3050-3054.
- Maixnerova D, Jancova E, Skibova J, et al. Nationwide biopsy survey of renal diseases in the Czech Republic during the years 1994-2011. *J Nephrol* 2015; 28: 39-49.
- Perkowska-Ptasinska A, Deborska-Materkowska D, Bartczak A, et al. Kidney disease in the elderly: biopsy based data from 14 renal centers in Poland. *BMC Nephrol* 2016; 17: 194.
- Nationwide and Long-Term Survey of Primary Glomerulonephritis in Japan as Observed in 1,850 Biopsied Cases. *Nephron* 1999; 82: 205-213.
- Sim JJ, Batech M, Hever A, et al. Distribution of Biopsy-Proven Presumed Primary Glomerulonephropathies in 2000-2011 Among a Racially and Ethnically Diverse US Population. *Am J Kidney Dis* 2016; 68: 533-544.
- Choi IJ, Jeong HJ, Han DS, et al. An analysis of 4,514 cases of renal biopsy in Korea. *Yonsei Med J* 2001; 42: 247-254.
- McGrogan A, Franssen CF, de Vries CS. The incidence of primary glomerulonephritis worldwide: a systematic review of the literature. *Nephrol Dial Transplant* 2011; 26: 414-430.
- Jones DB. Nephrotic glomerulonephritis. *Am J Pathol* 1957; 33: 313-329.
- Mellors RC, Ortega LG, Holman HR. Role of gamma globulins in pathogenesis of renal lesions in systemic lupus erythematosus and chronic membranous glomerulonephritis, with an observation on the lupus erythematosus cell reaction. *J Exp Med* 1957; 106: 191-202.
- Farquhar MG, Saito A, Kerjaschki D, et al. The Heymann nephritis antigenic complex: megalin (gp330) and RAP. *J Am Soc Nephrol* 1995; 6: 35-47.
- Border WA, Ward HJ, Kamil ES, et al. Induction of membranous nephropathy in rabbits by administration of an exogenous cationic antigen. *J Clin Invest* 1982; 69: 451-461.
- Koyama A, Inage H, Kobayashi M, et al. Effect of chemical cationization of antigen on glomerular localization of immune complexes in active models of serum sickness nephritis in rabbits. *Immunology* 1986; 58: 529-534.
- Debiec H, Lefeu F, Kemper MJ, et al. Early-childhood membranous nephropathy due to cationic bovine serum albumin. *N Engl J Med* 2011; 364: 2101-2110.
- Debiec H, Guignon V, Mougenot B, et al. Antenatal membranous glomerulonephritis due to anti-neutral endopeptidase antibodies. *N Engl J Med* 2002; 346: 2053-2060.
- Debiec H, Guignon V, Mougenot B, et al. Antenatal membranous glomerulonephritis with vascular injury induced by anti-neutral endopeptidase antibodies: toward new concepts in the pathogenesis of glomerular diseases. *J Am Soc Nephrol* 2003; 14 Suppl 1: S27-S32.
- Debiec H, Nauta J, Coulet F, et al. Role of truncating mutations in MME gene in fetomaternal alloimmunisation and antenatal glomerulopathies. *Lancet* 2004; 364: 1252-1259.
- Vivarelli M, Emma F, Pellé T, et al. Genetic homogeneity but IgG subclass-dependent clinical variability of alloimmune membranous nephropathy with anti-neutral endopeptidase antibodies. *Kidney Int* 2015; 87: 602-609.
- Beck LH Jr, Bonegio RG, Lambeau G, et al. M-type phospholipase A2 receptor as target antigen in idiopathic membranous nephropathy. *N Engl J Med* 2009; 361: 11-21.
- Beck LH Jr, Fervenza FC, Beck DM, et al. Rituximab-induced depletion of anti-PLA2R autoantibodies predicts response in membranous nephropathy. *J Am Soc Nephrol* 2011; 22: 1543-1550.
- Timmermans SA, Abdul Hamid MA, Cohen Tervaert JW, et al. Anti-PLA2R Antibodies as a Prognostic Factor in PLA2R-Related Membranous Nephropathy. *Am J Nephrol* 2015; 42: 70-77.
- Svobodova B, Honsova E, Ronco P, et al. Kidney biopsy is a sensitive tool for retrospective diagnosis of PLA2R-related membranous nephropathy. *Nephrol Dial Transplant* 2013; 28: 1839-1844.
- Hara S, Goto S, Kamiura N, et al. Reappraisal of PLA2R1 in membranous nephropathy: immunostaining method influence and association with IgG4-dominant phenotype. *Virchows Arch* 2015; 467: 87-94.
- Cattran DC, Brenchley PE. Membranous nephropathy: integrating basic science into improved clinical management. *Kidney Int* 2017; 91: 566-574.
- Dai H, Zhang H, He Y. Diagnostic accuracy of PLA2R autoantibodies and glomerular staining for the differentiation of idiopathic and secondary membranous nephropathy: an updated meta-analysis. *Sci Rep* 2015; 5: 8803.
- Du Y, Li J, He F, et al. The diagnosis accuracy of PLA2R-AB in the diagnosis of idiopathic membranous nephropathy: a meta-analysis. *PLoS One* 2014; 9: e104936.
- Stehlé T, Audard V, Ronco P, et al. Phospholipase A2 receptor and sarcoidosis-associated membranous nephropathy. *Nephrol Dial Transplant* 2015; 30: 1047-1050.

28. Xie Q, Li Y, Xue J, et al. Renal phospholipase A2 receptor in hepatitis B virus-associated membranous nephropathy. *Am J Nephrol* 2015; 41: 345-353.
29. Tomas NM, Beck LH Jr, Meyer-Schwesinger C, et al. Thrombospondin type-1 domain-containing 7A in idiopathic membranous nephropathy. *N Engl J Med* 2014; 371: 2277-2287.
30. Larsen CP, Cossey LN, Beck LH. THSD7A staining of membranous glomerulopathy in clinical practice reveals cases with dual autoantibody positivity. *Mod Pathol* 2016; 29: 421-426.
31. Iwakura T, Ohashi N, Kato A, et al. Prevalence of Enhanced Granular Expression of Thrombospondin Type-1 Domain-Containing 7A in the Glomeruli of Japanese Patients with Idiopathic Membranous Nephropathy. *PLoS One* 2015; 10: e0138841.
32. Tomas NM, Hoxha E, Reinicke AT, et al. Autoantibodies against thrombospondin type 1 domain-containing 7A induce membranous nephropathy. *J Clin Invest* 2016; 126: 2519-2532.
33. Abe S, Amagasaki Y, Konishi K, et al. Idiopathic membranous glomerulonephritis: aspects of geographical differences. *J Clin Pathol* 1986; 39: 1193-1198.
34. Donadio JV Jr, Burgess JH, Holley KE. Membranous lupus nephropathy: a clinicopathologic study. *Medicine (Baltimore)* 1977; 56: 527-536.
35. Nawaz FA, Larsen CP, Troxell ML. Membranous nephropathy and nonsteroidal anti-inflammatory agents. *Am J Kidney Dis* 2013; 62: 1012-1017.
36. Makino H, Yoshinaga Y, Yamasaki Y, et al. Renal involvement in rheumatoid arthritis: analysis of renal biopsy specimens from 100 patients. *Mod Rheumatol* 2002; 12: 148-154.
37. Hall CL, Jawad S, Harrison PR, et al. Natural course of penicillamine nephropathy: a long term study of 33 patients. *Br Med J (Clin Res Ed)* 1988; 296: 1083-1086.
38. Lai KN, Li PK, Lui SF et al. Membranous nephropathy related to hepatitis B virus in adults. *N Engl J Med* 1991; 324: 1457-1463.
39. Ozkok A, Yildiz A. Hepatitis C virus associated glomerulopathies. *World J Gastroenterol* 2014; 20: 7544-7554.
40. Araújo Sde A, Giordano LF, Rosa AA, et al. Membranous glomerulonephritis secondary to syphilis. *Braz J Infect Dis* 2015; 19: 442-443.
41. Hiramatsu R, Ubara Y, Sawa N, et al. Clinicopathological analysis of allogeneic hematopoietic stem cell transplantation-related membranous glomerulonephritis. *Hum Pathol* 2016; 50: 187-194.
42. Lefaucheur C, Stengel B, Nochy D, et al. Membranous nephropathy and cancer: Epidemiologic evidence and determinants of high-risk cancer association. *Kidney Int* 2006; 70: 1510-1517.
43. Leeaphorn N, Kue-A-Pai P, Thamcharoen N, et al. Prevalence of cancer in membranous nephropathy: a systematic review and meta-analysis of observational studies. *Am J Nephrol* 2014; 40: 29-35.
44. Lee JC, Yamauchi H, Hopper J Jr. The association of cancer and the nephrotic syndrome. *Ann Intern Med* 1966; 64: 41-51.
45. Qu Z, Liu G, Li J, et al. Absence of glomerular IgG4 deposition in patients with membranous nephropathy may indicate malignancy. *Nephrol Dial Transplant* 2012; 27: 1931-1937.
46. Lönnbro-Widgren J, Ebefors K, Mölne J, et al. Glomerular IgG subclasses in idiopathic and malignancy-associated membranous nephropathy. *Clin Kidney J* 2015; 8: 433-439.
47. Alnasrallah B, Collins JF, Zwi LJ. Malignancy in membranous nephropathy: evaluation of incidence. *Int J Nephrol* 2017; 2017: 8409829.
48. Murtas C, Ghiggeri GM. Membranous glomerulonephritis: histological and serological features to differentiate cancer-related and non-related forms. *J Nephrol* 2016; 29: 469-478.
49. Pani A, Porta C, Cosmai L, et al. Glomerular diseases and cancer: evaluation of underlying malignancy. *J Nephrol* 2016; 29: 143-152.
50. Larsen CP, Ambuzs JM, Bonsib SM, et al. Membranous-like glomerulopathy with masked IgG kappa deposits. *Kidney Int* 2014; 86: 154-161.
51. Bantis C, Heering PJ, Aker S, et al. Tumor necrosis factor-alpha gene G-308A polymorphism is a risk factor for the development of membranous glomerulonephritis. *Am J Nephrol* 2006; 26: 12-15.
52. Chen SY, Chen CH, Huang YC, et al. Association of STAT4 polymorphisms with susceptibility to primary membranous glomerulonephritis and renal failure. *Clin Chim Acta* 2011; 412: 1899-904.
53. Stanescu HC, Arcos-Burgos M, Medlar A, et al. Risk HLA-DQA1 and PLA(2)R1 alleles in idiopathic membranous nephropathy. *N Engl J Med* 2011; 364: 616-626.
54. Lv J, Hou W, Zhou X, et al. Interaction between PLA2R1 and HLA-DQA1 variants associates with anti-PLA2R antibodies and membranous nephropathy. *J Am Soc Nephrol* 2013; 24: 1323-1329.
55. Ramachandran R, Kumar V, Kumar A, et al. PLA2R antibodies, glomerular PLA2R deposits and variations in PLA2R1 and HLA-DQA1 genes in primary membranous nephropathy in South Asians. *Nephrol Dial Transplant* 2016; 31: 1486-1493.
56. Churg J, Ehrenreich T. Membranous nephropathy. *Perspect Nephrol Hypertens* 1973; 1 Pt 1: 443-448.
57. Paraskevakou H, Kavantzias N, Pavlopoulos PM, et al. Membranous glomerulonephritis: a morphometric study. *Pathol Res Pract* 2000; 196: 141-144.
58. Ruggenenti P, Cravedi P, Sghirlanzoni MC, et al. Effects of rituximab on morphofunctional abnormalities of membranous glomerulopathy. *Clin J Am Soc Nephrol* 2008; 3: 1652-1659.
59. Morita M, Mii A, Shimizu A, et al. Glomerular endothelial cell injury and focal segmental glomerulosclerosis lesion in idiopathic membranous nephropathy. *PLoS One* 2015; 10: e0116700.
60. Gu QH, Cui Z, Huang J, et al. Patients With Combined Membranous Nephropathy and Focal Segmental Glomerulosclerosis Have Comparable Clinical and Autoantibody Profiles With Primary Membranous Nephropathy: A Retrospective Observational Study. *Medicine (Baltimore)* 2016; 95: e3786.
61. Mariani LH, Martini S, Barisoni L, et al. Interstitial fibrosis scored on whole-slide digital imaging of kidney biopsies is a predictor of outcome in proteinuric glomerulopathies. *Nephrol Dial Transplant* 2018; 33: 310-318.
62. Tsuboi N, Kawamura T, Miyazaki Y, et al. Low glomerular density is a risk factor for progression in idiopathic membranous nephropathy. *Nephrol Dial Transplant* 2011; 26: 3555-3560.
63. Sprangers B, Bomback AS, Cohen SD, et al. Idiopathic membranous nephropathy: clinical and histologic prognostic features and treatment patterns over time at a tertiary referral center. *Am J Nephrol* 2012; 36: 78-89.
64. Yokoyama H, Taguchi T, Sugiyama H, et al. Membranous nephropathy in Japan: analysis of the Japan Renal Biopsy Registry (J-RBR). *Clin Exp Nephrol* 2012; 16: 557-63.
65. Hogan SL, Muller KE, Jennette JC, et al. A review of therapeutic studies of idiopathic membranous glomerulopathy. *Am J Kidney Dis* 1995; 25: 862-875.
66. Cattran DC, Pei Y, Greenwood CM, et al. Validation of a predictive model of idiopathic membranous nephropathy: its clinical and research implications. *Kidney Int* 1997; 51: 901-907.
67. Hoxha E, Thiele I, Zahner G, et al. Phospholipase A2 receptor autoantibodies and clinical outcome in patients with primary membranous nephropathy. *J Am Soc Nephrol* 2014; 25: 1357-1366.
68. Segawa Y, Hisano S, Matsushita M, et al. IgG subclasses and complement pathway in segmental and global membranous nephropathy. *Pediatr Nephrol* 2010; 25: 1091-1099.

69. Kuroki A, Shibata T, Honda H, et al. Glomerular and serum IgG subclasses in diffuse proliferative lupus nephritis, membranous lupus nephritis, and idiopathic membranous nephropathy. *Intern Med* 2002; 41: 936-942.
70. Kearney N, Podolak J, Matsumura L, et al. Patterns of IgG subclass deposits in membranous glomerulonephritis in renal allografts. *Transplant Proc* 2011; 43: 3743-3746.
71. Ohtani H, Wakui H, Komatsuda A, et al. Distribution of glomerular IgG subclass deposits in malignancy-associated membranous nephropathy. *Nephrol Dial Transplant* 2004; 19: 574-579.
72. Ma LJ, Fogio AB. PAI-1 and kidney fibrosis. *Front Biosci (Landmark Ed)* 2009; 14: 2028-2041.
73. Scharpé J, Maes B, Van Damme B. The podocyte: from bench to bedside. *Acta Clin Belg* 2005; 60: 86-93.
74. Müller-Deile J, Dannenberg J, Schroder P, et al. Podocytes regulate the glomerular basement membrane protein nephronec tin by means of miR-378a-3p in glomerular diseases. *Kidney Int* 2017; 92: 836-849.
75. Saran AM, Yuan H, Takeuchi E, et al. Complement mediates nephrin redistribution and actin dissociation in experimental membranous nephropathy. *Kidney Int* 2003; 64: 2072-2078.
76. Cunningham PN, Quigg RJ. Contrasting roles of complement activation and its regulation in membranous nephropathy. *J Am Soc Nephrol* 2005; 16: 1214-1222.
77. Nangaku M, Shankland SJ, Couser WG. Cellular response to injury in membranous nephropathy. *J Am Soc Nephrol* 2005; 16: 1195-1204.
78. Nosaka H, Tamura Y, Kojima K, et al. Podocyte foot process effacement in very early phase of passive Heymann nephritis is not a prerequisite for proteinuria. *J Nephrol* 2009; 22: 484-490.
79. Yang Y, Wang C, Jin L, et al. IgG4 anti-phospholipase A2 receptor might activate lectin and alternative complement pathway meanwhile in idiopathic membranous nephropathy: an inspiration from a cross-sectional study. *Immunol Res* 2016; 64: 919-930.
80. Vidarsson G, Dekkers G, Rispens T. IgG subclasses and allotypes: from structure to effector functions. *Front Immunol* 2014; 5: 520.
81. Lhotta K, Würzner R, König P. Glomerular deposition of man nose-binding lectin in human glomerulonephritis. *Nephrol Dial Transplant* 1999; 14: 881-886.
82. Bally S, Debiec H, Ponard D, et al. Phospholipase A2 Receptor-Related Membranous Nephropathy and Mannan-Binding Lectin Deficiency. *J Am Soc Nephrol* 2016; 27: 3539-3544.
83. Tegla CA, Cudrici C, Patel S, et al. Membrane attack by complement: the assembly and biology of terminal complement complexes. *Immunol Res* 2011; 51: 45-60.
83. Bohana-Kashtan O, Ziporen L, Donin N, et al. Cell signals transduced by complement. *Mol Immunol* 2004; 41: 583-597.
84. Spicer ST, Tran GT, Killingsworth MC, et al. Induction of passive Heymann nephritis in complement component 6-deficient PVG rats. *J Immunol* 2007; 179: 172-178.
85. Leenaerts PL, Hall BM, Van Damme BJ, et al. Active Heymann nephritis in complement component C6 deficient rats. *Kidney Int* 1995; 47: 1604-1614.
86. Reiser J, von Gersdorff G, Loos M, et al. Induction of B7-1 in podocytes is associated with nephrotic syndrome. *J Clin Invest* 2004; 113: 1390-1397.
87. Polanco N, Gutiérrez E, Covarsí A, et al. Spontaneous remission of nephrotic syndrome in idiopathic membranous nephropathy. *J Am Soc Nephrol* 2010; 21: 697-704.
88. van den Brand JA, van Dijk PR, Hofstra JM, et al. Long-term outcomes in idiopathic membranous nephropathy using a restrictive treatment strategy. *J Am Soc Nephrol* 2014; 25: 150-158.
89. Ponticelli C. Prognosis and treatment of membranous nephropathy. *Kidney Int* 1986; 29: 927-940.
90. van de Logt AE, Hofstra JM, Wetzels JF. Pharmacological treatment of primary membranous nephropathy in 2016. *Expert Rev Clin Pharmacol* 2016; 9: 1463-1478.
91. Cattran D, Brenchley P. Membranous nephropathy: thinking through the therapeutic options. *Nephrol Dial Transplant* 2017; 32 (suppl. 1): i22-i29.
92. Kidney Disease: Improving Global Outcomes (KDIGO) Glomerulonephritis Work Group. KDIGO Clinical Practice Guideline for Glomerulonephritis 2012.
93. Alfaadhel T, Cattran D. Management of Membranous Nephropathy in Western Countries. *Kidney Dis (Basel)* 2015; 1: 126-137.
94. Barbour SJ, Greenwald A, Djurdjev O, et al. Disease-specific risk of venous thromboembolic events is increased in idiopathic glomerulonephritis. *Kidney Int* 2012; 81: 190-195.
95. du Buf-Vereijken PW, Wetzels JF. Efficacy of a second course of immunosuppressive therapy in patients with membranous nephropathy and persistent or relapsing disease activity. *Nephrol Dial Transplant* 2004; 19: 2036-2043.
96. Golgert WA, Appel GB, Hariharan S. Recurrent glomerulonephritis after renal transplantation: an unsolved problem. *Clin J Am Soc Nephrol* 2008; 3: 800-807.
97. Mirza MK, Kim L, Kadambi PV, et al. Membranous nephropathy transplanted in the donor kidney: observations of resolving glomerulopathy in serial allograft biopsies. *Nephrol Dial Transplant* 2014; 29: 2343-2347.
98. Aline-Fardin A, Rifle G, Martin L, et al. Recurrent and de novo membranous glomerulopathy after kidney transplantation. *Transplant Proc* 2009; 41: 669-671.
99. Pippias M, Stel VS, Aresté-Fosalba N, et al. Long-term Kidney Transplant Outcomes in Primary Glomerulonephritis: Analysis From the ERA-EDTA Registry. *Transplantation* 2016; 100: 1955-1962.
100. Cosio FG, Cattran DC. Recent advances in our understanding of recurrent primary glomerulonephritis after kidney transplantation. *Kidney Int* 2017; 91: 304-314.
101. Ponticelli C, Glasscock RJ. De novo membranous nephropathy (MN) in kidney allografts. A peculiar form of alloimmune disease? *Transpl Int* 2012; 25: 1205-10.
102. Wen J, Xie K, Zhang M et al. HLA-DR, and not PLA2R, is expressed on the podocytes in kidney allografts in de novo membranous nephropathy. *Medicine (Baltimore)* 2016; 95: e4809.

Address for correspondence

Agnieszka Perkowska-Ptasińska
 Department of Transplantology,
 Nephrology, and Internal Diseases
 Warsaw Medical University
 Nowogrodzka 59
 02-006 Warsaw, Poland
 e-mail: aggape@poczta.onet.pl