

CASE REPORT

FATAL SYSTEMIC ANGIOMATOSIS WITH WIDESPREAD SCLEROTIC SKELETAL CHANGES, DIAGNOSED WITH THE AID OF A BONE MARROW BIOPSY: THE LYMPHATICS ENTER THE BONE MARROW

ZBIGNIEW RUDZKI¹, RICHARD LOVELL², BEN MILLER³, VIDHYA MURTHY², SHANKARA PANEESHA², GUY PRATT⁴, NEIL SMITH²

¹Department of Histopathology, University Hospitals Birmingham NHS Foundation Trust, Birmingham, UK

²Department of Haematology, University Hospitals Birmingham NHS Foundation Trust, Birmingham, UK

³Department of Radiology, University Hospitals Birmingham NHS Foundation Trust, Birmingham, UK

⁴Department of Haematology, University Hospitals Birmingham NHS Foundation Trust, Birmingham, UK

A 56-year-old female presented with popliteal venous thrombosis, splenomegaly, and sclerotic bone lesions. Bone marrow biopsy showed fibrosis, proliferation of abnormal blood vessels and lymphatics, bone remodelling, and no significant changes in haematopoietic elements. Following a relatively indolent initial clinical course, one year later she rapidly deteriorated and died of respiratory failure associated with widespread disease. Ingrowth of podoplanin+ lymphatics mixed with CD34+/podoplanin– blood vessels into the bone marrow is a new finding and may be a unique feature of this disease.

Key words: angiomatosis, angiogenesis, bone marrow, trephine bone marrow biopsy.

Introduction

We present a unique case of systemic angiomatosis diagnosed on a correlation of bone marrow histology, radiological imaging, and clinical picture, providing a detailed description of histological changes in bone marrow and demonstrating unusual proliferation of vessels with at least partial lymphatic differentiation into the environment usually lacking this type of vasculature. Our case illustrates a protean, rapidly accelerated clinical course of this rare and enigmatic disease.

Clinical history

A 56-year-old female of white European origin presented in February 2014 with unprovoked left popliteal vein thrombosis, confirmed on Doppler ultrasound. Her past medical history included over two

decades of arterial hypertension, diabetes mellitus, and recent bilateral cataracts successfully resolved by surgery. Magnetic resonance imaging performed for episodic back pain in 2012 showed herniations of two cervical discs but failed to reveal any other skeletal abnormalities. Abdominal ultrasound done for transient abdominal pain in June 2013 did not reveal any notable changes and, in particular, showed a spleen of normal size and texture. However, abdominal ultrasound performed following the 2014 thrombotic episode demonstrated an 18-cm spleen with diffusely irregular heterogeneous appearance, suggestive of a metastatic process, not associated with changes in other abdominal organs (Fig. 1A). Subsequent computerised tomography showed widespread sclerotic skeletal changes raising further concern for a disseminated malignancy (Fig. 1B). This sinister radiological picture sharply contrasted with the clinical presentation because, at that time, the patient was

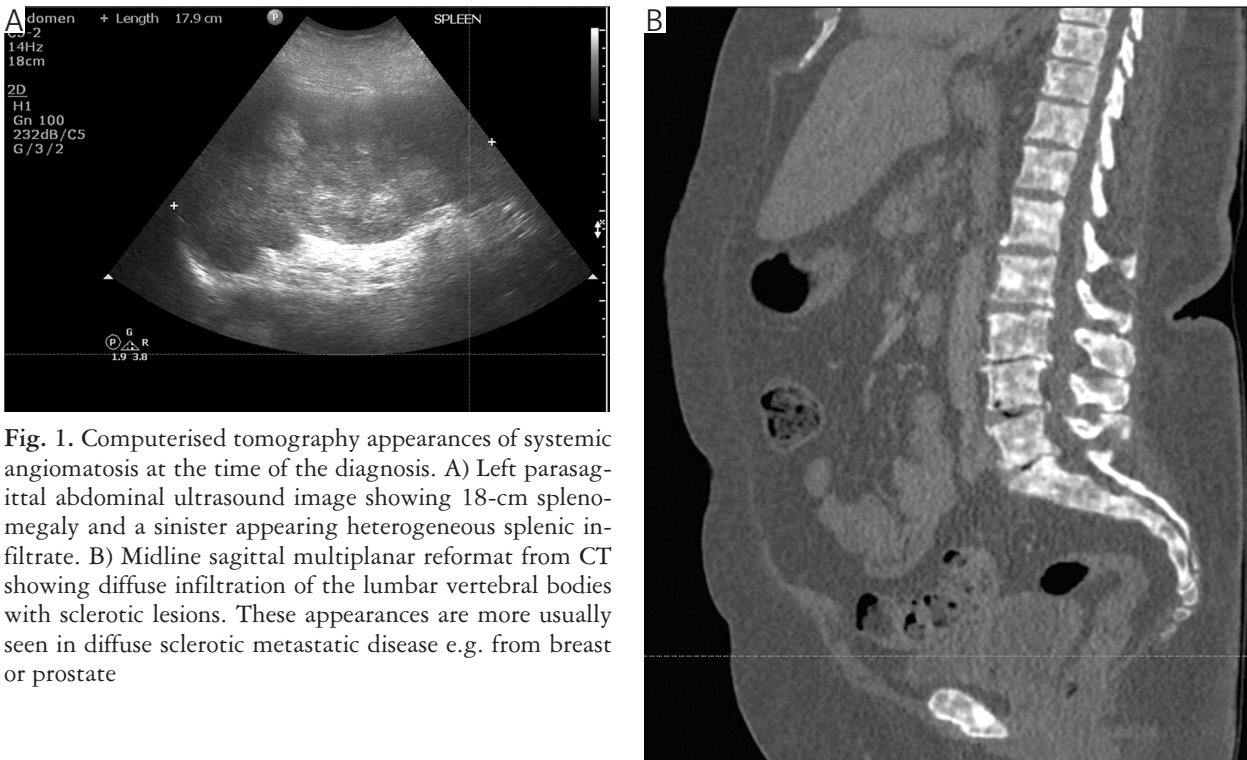


Fig. 1. Computerised tomography appearances of systemic angiomatosis at the time of the diagnosis. A) Left parasagittal abdominal ultrasound image showing 18-cm splenomegaly and a sinister appearing heterogeneous splenic infiltrate. B) Midline sagittal multiplanar reformat from CT showing diffuse infiltration of the lumbar vertebral bodies with sclerotic lesions. These appearances are more usually seen in diffuse sclerotic metastatic disease e.g. from breast or prostate

generally well, with no systemic symptoms. Her peripheral blood counts were normal. Although LDH was elevated at 416 U/l (norm: 125-220 U/l), other biochemical tests did not show any abnormalities beyond what was expected for her comorbidities.

Following the diagnosis of angiomatosis obtained at the correlation of the trephine bone marrow biopsy with radiology (see below), the patient was initially observed, but over the next few months she developed skeletal pains involving shoulders, neck, back, knees, and ankles, even though the skeletal abnormalities remained stable on repeated imaging. Pains were unresponsive to zoledronic acid. Numerous hypodense 'metastatic' lesions appeared in the liver, and previously normal lungs developed extensive nodular and interstitial changes, accompanied by pleural effusions. She developed thrombocytopenia ($83 \times 10^9/l$) and anaemia (Hb 77g/l) with microangiopathic changes on peripheral blood film. Progressive splenomegaly prompted consideration of splenectomy, and further planned therapy included thalidomide and pegylated interferon; however, before these measures were implemented, the patient developed rapidly progressive respiratory failure and died in January 2015. No autopsy was performed.

Material, methods, and results

Bone marrow aspirate was haemodilute and rather non-contributory, save for showing some osteoblasts in addition to scant unremarkable haematopoietic elements. The trephine bone marrow biopsy has been

processed according to the Hammersmith protocol [1], cut at $2 \mu\text{m}$ at three levels, and initially stained with haematoxylin/eosin, Giemsa, and Gordon-Sweet reticulin methods. Immunostains included CD34, CD31, FVIIIIR, D2-40/ Podoplanin, Ki67, CD20, PAX5, CD3, CD117, CD68PGM1, CD30, CD15, Fascin, MUM1, and cytokeratins (AE1/AE3, CK7, CK20), all performed on an automated Ventana stainer. No evidence of micro-organisms was found on EBV EBER *in situ* hybridisation, HHV8 LANA immunohistochemistry, and standard tinctorial stains, including Ziehl-Neelsen, Brown-Brenn Gram, PAS, Warthin-Starry, and Grocott methods.

Changes seen on the trephine bone marrow biopsy were striking (Fig. 2) and included extensive areas of paucicellular fibrosis mixed with chaotic proliferation of abnormal, gaping, thin-walled vessels, which were lined by thin endothelial cells completely lacking any atypia, with negligible Ki67 proliferative activity. Hardly any fat tissue was left. These fibrovascular proliferations replaced most of the sampled marrow, and the scant haematopoietic tissue seen only focally did not demonstrate any obvious dysplastic changes or striking topographic abnormalities suggestive of myeloid neoplasia. CD31 immunostaining of the pathological vascular structures was widespread. Although most vessels also stained with CD34, many – but not all – co-expressed podoplanin (Fig. 2E F). There were areas of active bone remodelling, with formation of immature trabeculae lined

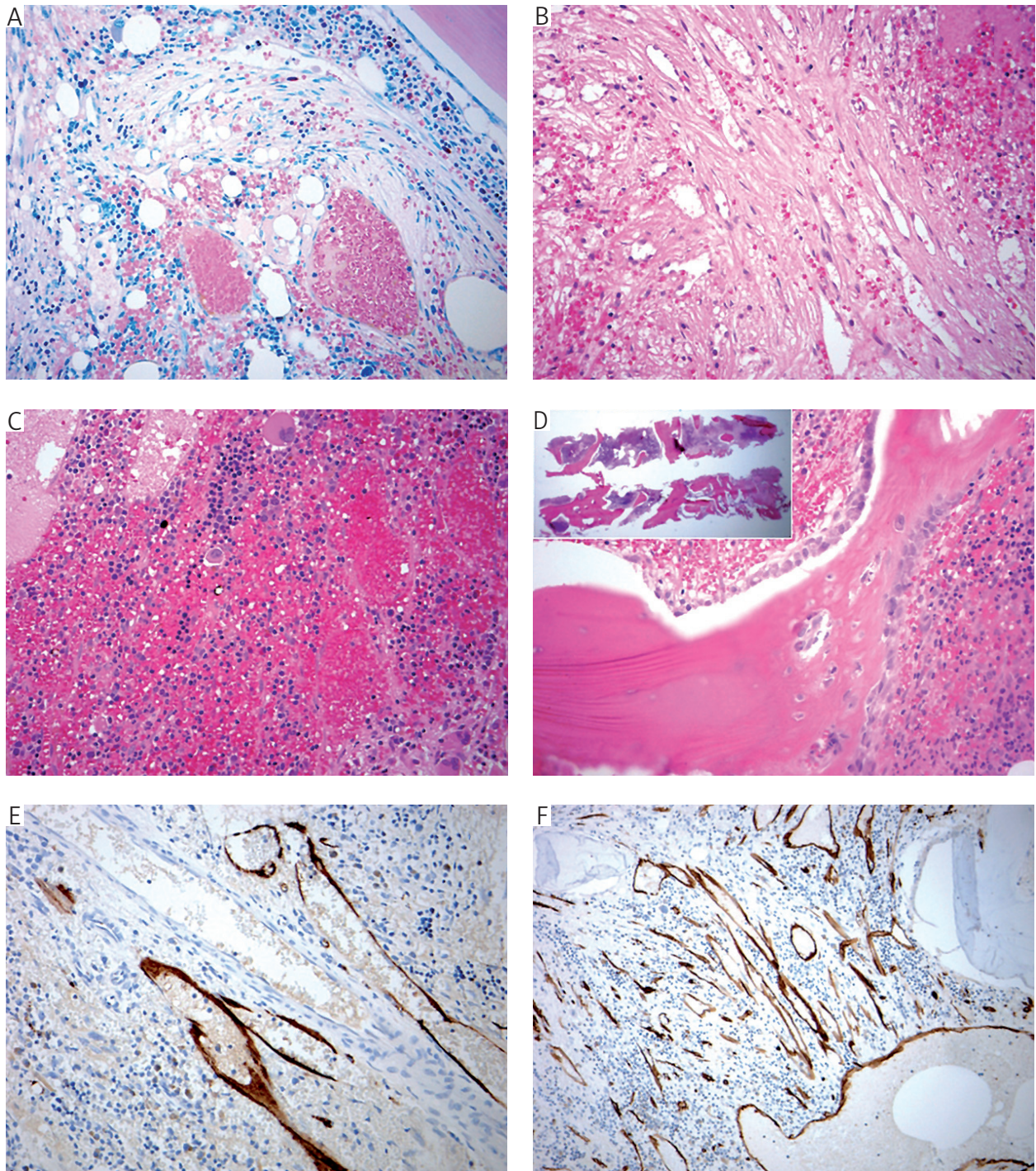


Fig. 2. Histology of systemic angiomatosis in a trephine bone marrow biopsy. A) Abnormal vascular structures and fibrosis displacing haematopoietic elements (Giemsa, objective 20 ×). B) A more fibrotic area with entrapped thin-walled vessels (HE, objective 20 ×). C) Numerous thin-walled sinusoids resulting in a picture of blood lakes (HE, objective 20 ×). D) Florid bone remodelling with osteoblastic activity (HE, objective 20 ×) (inset – the overall low-power picture of the massive sclerotic bone). E) CD34 immunoreactivity of nearly all vessels (objective 20 ×). F) Some but not all vascular structures show expression of podoplanin/D2-40 in keeping with their lymphatic differentiation, possibly unique to this disease (objective 20 ×)

by plump osteoblasts, but most trabeculae appeared quiescent, although massive and irregular with a picture that did not resemble osteomyelosclerosis of advanced fibrotic myeloproliferative neoplasms.

No atypical cells raising concern for any metastatic process were found in this technically good biopsy in which the interpretable bone marrow area measured 17 × 1.5 mm.

Discussion

Systemic angiomasia is a paradoxical disease, combining a seemingly benign histology with a potentially rapid and fatal outcome, not dissimilar to aggressive disseminated malignancies [2, 3, 4]. Its aetiology and pathogenesis are still purely speculative, its real incidence is unknown, the treatment standards are non-existent, and even its name is not well established – the literature is littered with all imaginable combinations of *angiomasia* / *lymphangiomasia* / *haemolymphangiomasia* / with *cystic* / *hamartous* / *generalised* / *systemic* / *multi-system* / *skeletal* / *extraskkeletal* / *disseminated* / *multiple* / *multifocal* / or *diffuse*. To a certain extent it overlaps with the Gorham-Stout disease/syndrome (vanishing/phantom bone disease) [5], but the latter term is more often used to denote a purely skeletal condition affecting mostly the younger patients, resulting in obvious progressive osteolysis.

Systemic angiomasia may involve the skeleton and parenchymatous organs, including the lungs and the spleen [2, 6]. Although most cases are reported in young patients, there seems to be a second peak of incidence well into adulthood [7]. Its course is unpredictable, and the prognosis remains uncertain – some cases, particularly those presenting or complicating with chylothorax, are fatal, but sometimes the disease is indolent and/or self-limiting, and spontaneous resolution has been described even following a multi-systemic presentation [2, 7, 8, 9]. No laboratory tests can positively aid the diagnosis and the routine biochemistry, and peripheral blood counts are often initially normal or nearly-normal, in a striking contrast to the sinister appearances of an apparently “*disseminated (?haematopoietic) malignancy*” seen on the imaging.

Radiolucent lesions, consistent with osteolysis, are the most frequently reported skeletal radiological manifestation of angiomasia [3]; however, rare cases present with sclerotic changes akin to those seen in our case and posing an even greater diagnostic challenge [10, 11]. Thus, although the radiological picture may be suggestive (or, to the contrary, misleading, implying a disseminated malignancy), the final diagnosis requires histological confirmation. Despite this, a truly comprehensive outline of the histological picture is lacking because the overwhelming majority of reports are focused on radiological imaging. Our case provides probably the most detailed description of changes found on a trephine bone marrow biopsy, even though the picture of the bone marrow in this entity has been briefly reported already [4]. Taking advantage of the relatively recently available marker of lymphatic vessels: podoplanin/ D2-40, we have for the first time demonstrated that the abnormally shaped lesional vessels of systemic angiomasia found in the bone marrow represent an unusual mix-

ture of blood vessels (Podoplanin –), lymphatic-like vessels (Podoplanin +), and perhaps hybrid structures (Podoplanin +/-). Interestingly, the data on lymphatics in the bone marrow are close to non-existent. Most standard textbook and papers cite one not easily obtainable reference [12], stating that normal bone marrow does not contain lymphatic vessels. Recent experimental studies demonstrated that lymphatic vessel progenitors are present in the haematopoietic tissue [13, 14], even though the ingrowth of lymphatics is not encountered in an everyday pathology diagnostic practice in the bone marrow in a vast spectrum of pathologies – such as myeloid neoplasms, lymphomas, non-haematopoietic metastases, hereditary haemorrhagic telangiectasia, and richly vascularised fibrosis due to healing trauma (our own unpublished diagnostic data). Thus, systemic angiomasia seems to be an absolutely unique condition of improper ‘invasion’ of lymphatics into this primarily lymphatic-free environment or – more probably – of pathological activation and successful maturation of the normally quiescent lymphatic progenitors. This finding may be of significant diagnostic help because, at first glance, the picture of angiomasia on a trephine bone marrow biopsy is perplexing, prompting the frantic and futile search for signs of a myeloproliferative neoplasm hidden non-haematopoietic cancer or even consideration of a previous biopsy site/traumatic lesion. The bony lesions, although far less specific, are also characteristic, showing superficial similarities to Paget’s disease. Although the mineralisation line of massive angiomasia-related trabeculae are not so irregular, osteolytic lacunae are less impressive, and the osteoclasts do not have so many nuclei, as in Paget’s disease.

Thus, with the aid of little immunohistochemistry, the diagnosis of systemic angiomasia is achievable on trephine bone marrow biopsy once the clinical and radiological presentations are concordant. Sadly, the therapy lags behind, and this fascinating and unpredictable disease is still potentially life-threatening, even in cases with an early diagnosis.

In addition to new histological data, our case also provides a unique insight into the dynamics of the disease. Radiological studies performed for unrelated complaints two years before the presentation showed absolutely no changes indicative of systemic angiomasia, so the disease had to develop from its pre-clinical stage to symptomatic state relatively quickly. Also, the initial, deceptively indolent clinical course, prompting the watch-and-wait approach, in a span of a few months gave rise to sudden deterioration caused by progressive involvement of skeleton, liver, and the respiratory tract.

This is an epitomic orphan disease and there is little chance of obtaining funds and tissue material for its comprehensive studying; however, one cannot

resist speculations how much we could learn about human angiogenesis from elucidating its vagarious mechanisms.

Compliance with ethical standards

Following the diagnosis, the patient gave informed consent for the publication; the study was performed according to the Declaration of Helsinki. Ethics Committee approval was not necessary because this was a single case report.

Acknowledgments

Dr Petra Kasparova, Fingerland's Department of Pathology, Faculty Hospital Hradec Kralove, Czech Republic, is thanked for providing the difficult to obtain reverence [12].

Mr Gavin Rock is credited for standardising and performing the immunohistochemical stains.

The authors declare no conflict of interest.

References

1. Naresh KN, Lampert I, Hasserjian R, et al. Optimal processing of bone marrow trephine biopsy: the Hammersmith Protocol. *J Clin Pathol* 2006; 59: 903-911.
2. Aviv RI, McHugh K, Hunt J. Angiomas of bone and soft tissue: a spectrum of disease from diffuse lymphangiomas to vanishing bone disease in young patients. *Clin Radiol* 2001; 56: 184-190.
3. Kwag E, Shim SS, Kim Y, et al. CT features of generalized lymphangiomas in adult patients. *Clin Imaging* 2013; 37: 723-727.
4. Marcucci G, Masi L, Carossino AM, et al. Cystic bone angiomas: a case report treated with aminobisphosphonates and review of the literature. *Calcif Tissue Int* 2013; 93: 462-471.
5. Nikolaou VS, Chytas D, Korres D, et al. Vanishing bone disease (Gorham-Stout syndrome): A review of a rare entity. *World J Orthop* 2014; 18: 694-698.
6. Vanhoenacker FM, Schepper AM, Raeve H, et al. Cystic angiomas with splenic involvement: unusual MRI findings. *Eur Radiol* 2003; 13 Suppl 6: L35-39.
7. Devaney K, Vinh TN, Sweet DE. Skeletal-extraskeletal angiomas. A clinicopathological study of fourteen patients and nosologic considerations. *J Bone Joint Surg Am* 1994; 76: 878-891.
8. Soler R, Pombo F, Bargiela A, et al. Diffuse skeletal cystic angiomas: MR and CT findings. *Eur J Radiol* 1996; 22: 149-151.
9. Faber DL, Galili R, Nitzan O, et al. Systemic Generalized Lymphangiomas: A Diagnostic Challenge. *Isr Med Assoc J* 2015; 17: 785-786.
10. Forstner R, Datz C, Dietze O, et al. Sclerotic variant of lymphangiomas of bone: imaging findings at diagnosis and long-term follow-up. *Skeletal Radiol* 1998; 27: 445-448.
11. Renjen P, Kovanlikaya A, Narula N, et al. Importance of MRI in the diagnosis of vertebral involvement in generalized cystic lymphangiomas. *Skeletal Radiol* 2014; 43: 1633-1638.
12. Munka V, Gregor A. Lymphatics and bone marrow. *Folia Morphol (Praha)* 1965; 13: 404-412.
13. Religa P, Cao R, Bjorndahl M, et al. Presence of bone marrow-derived circulating progenitor endothelial cells in the newly formed lymphatic vessels. *Blood* 2005; 106: 4184-4190.

14. Tawada M, Hayashi S, Ikegame Y, et al. Possible involvement of tumor-producing VEGF-A in the recruitment of lymphatic endothelial progenitor cells from bone marrow. *Oncol Rep* 2014; 32: 2359-2364.

Address for correspondence

Dr Zbigniew Rudzki, Consultant Histopathologists
Department of Histopathology
Birmingham Heartlands Hospital
B9 5SS, Birmingham
United Kingdom
tel. 0044 121 424 0703
fax 0044 121 424 0196
e-mail: zbigniew.rudzki@heartofengland.nhs.uk