

ORIGINAL PAPER

HYPOXIA-INDUCIBLE FACTOR 1 α IN COMBINATION WITH VASCULAR ENDOTHELIAL GROWTH FACTOR COULD PREDICT THE PROGNOSIS OF POSTOPERATIVE PATIENTS WITH OESOPHAGEAL SQUAMOUS CELL CANCER

JING-BO SHAO^{1,2}, ZHE LI³, NAN ZHANG⁴, FEI YANG⁵, WEI GAO⁵, ZHI-GANG SUN⁶

¹Weifang Medical University, Weifang, People's Republic of China

²Department of Thoracic Surgery, Jinan Central Hospital Affiliated to Shandong University, Jinan, People's Republic of China

³Department of Medical Examination, Jinan Central Hospital Affiliated to Shandong University, Shandong University, Jinan, Shandong Province, People's Republic of China

⁴Department of Oncology, Jinan Central Hospital Affiliated to Shandong University, Jinan, People's Republic of China

⁵Department of Pathology, Jinan Central Hospital Affiliated to Shandong University, Shandong University, Jinan, Shandong Province, People's Republic of China

⁶Department of Thoracic Surgery, Jinan Central Hospital Affiliated to Shandong University, Shandong University, Jinan, Shandong Province, People's Republic of China

The purpose of the study is to investigate the clinicopathological and prognostic features of dual hypoxia-inducible factor 1 α (HIF-1 α) and vascular endothelial growth factor (VEGF) expression in oesophageal squamous cell carcinoma (OSCC) patients. A total of 73 patients were enrolled in this study. The positive expression of HIF-1 α was identified in 69.9% of the cases. Hypoxia-inducible factor 1 α expression was correlative with pT ($p = 0.008$) and pTNM stage ($p = 0.002$). The positive expression of VEGF was identified in 63.0% of the cases. Vascular endothelial growth factor expression was correlative with pT ($p = 0.005$), pN ($p = 0.045$), and pTNM stage ($p < 0.05$). HIF-1 α and VEGF expressions had a significantly positive correlation ($p = 0.010$). Dual positive expression of HIF-1 α and VEGF was identified in 50.7% (37/73) of the cases, and it was significantly correlative with pT ($p = 0.025$), pN ($p = 0.008$), and pTNM stage ($p = 0.014$). The OSCC patients' 5-year survival rate was correlative with pT ($p < 0.05$), pN ($p < 0.01$), pTNM stage ($p < 0.01$), VEGF expression ($p < 0.01$), and dual expressions of HIF-1 α and VEGF ($p < 0.01$). Cox regression analysis showed that pN and dual HIF-1 α and VEGF expression were independent prognostic factors for the 5-year survival rate of the patients. In conclusion, HIF-1 α combined with VEGF could enable us to more accurately predict the prognosis of OSCC patients.

Key words: oesophageal squamous cell cancer, HIF-1 α , VEGF, immunohistochemistry.

Introduction

Oesophageal cancer (OC) is one of the most common malignant neoplasms. Oesophageal squamous cell carcinoma (OSCC) remains the major histological type of OC worldwide, although the morbidity of oesophageal adenocarcinoma is rising in North America and Europe [1]. Oesophagostomy alone or combined with adjuvant chemotherapy and/or radiotherapy remains the main therapeutic regimen for OSCC patients. However, their long-term effect is unsatisfactory, and the 5-year survival rate is only 20-30% [2]. Molecular markers are urgently needed to improve the prognosis of OSCC patients [3].

Hypoxia-inducible factor 1 α (HIF-1 α) is a key transcription factor induced by hypoxia; HIF-1 α is conducive to the regulation of multiple adaptive responses involved in crucial aspects of cancer biology, including cell proliferation, glucose metabolism, and angiogenesis [4]. Hypoxia-inducible factor 1 α plays an important role in tumour phenotype, angiogenesis, invasion, and metastasis in some malignant neoplasms [5]. It is a complicated, multistep, and temporally ordered procedure involved in a lot of genes and pathways regulated by HIF-1 α . Hypoxia-inducible factor 1 α can regulate vascular endothelial growth factor (VEGF) directly [6]. Vascular endothelial growth factor is regarded as one of the most potent sources of angiogenesis and has been shown to be responsible for the development and maintenance of vascular networks that promote tumour growth and metastasis in many malignant neoplasms, including OSCC [7].

Many previous studies focused on HIF-1 α expression or VEGF expression in OC separately, with little research to combine them. The purpose of our study is to investigate the clinicopathological and prognostic features of dual HIF-1 α and VEGF expression in OSCC patients who underwent surgery. Because no immunohistochemistry (IHC) biomarker has been accepted into clinical prognostic models in practice, we use IHC to detect HIF-1 α and VEGF expression at the protein level.

Material and methods

Patients

A total of 73 patients were enrolled in this study at the Department of Thoracic Surgery Jinan Central Hospital Affiliated to Shandong University, from January 2010 to January 2013. The inclusion criteria were as follows: 1) patients with OSCC diagnosed after undergoing complete resection and postsurgical pathology; 2) patients diagnosed as postoperative pathologic stage I-III – the TNM staging was determined by the criteria established by the International

Union Against Cancer (UICC) in 2009; 3) patients with no preoperative radiotherapy or chemotherapy; and 4) patients with no serious surgical contraindications. The clinicopathological characteristics of the patients are listed in Table I. This study was approved by the Ethics Committee of Jinan Central Hospital Affiliated to Shandong University.

Immunohistochemistry

All the OSCC specimens were obtained from the 73 patients. Ten corresponding normal tissue samples, which came from the 73 patients' normal oesophagus (5 cm away from ESCC) randomly, were used as controls. The tissue specimens were fixed in 10% neutral buffered formalin and processed routinely. Hypoxia-inducible factor 1 α and VEGF were detected by the streptavidin-peroxidase (SP) method using the same paraffin-embedded tissue samples, which were cut into 4-mm-thick slices. The primary antibody was applied using rabbit anti-human monoclonal HIF-1 α antibodies (1:100, Catalogue #PB0245, Boster Biological Technology, Wuhan, P.R. China) or rabbit anti-human monoclonal VEGF antibodies (1:100, Catalogue #BA0407, Boster Biological Technology, Wuhan, P.R. China). A secondary antibody was applied using Goat Anti-Rabbit IgG Antibody (1:100, Catalogue #BA1003, Boster Biological Technology, Wuhan, P.R. China). When intensive positive staining of HIF-1 α or VEGF was observed in more than 10% of the tumour cells, the case was considered HIF-1 α -positive or VEGF-positive. These evaluation criteria have been described in previous reports [8, 9, 10, 11].

Statistical analysis

The enumeration data was analysed using χ^2 test or Fisher's exact probability test. The correlation between HIF-1 α and VEGF expression was analysed using Spearman's rank correlation coefficient. Univariate analysis was performed with Kaplan-Meier survival curves. The Cox proportional hazard model was used for multivariate analysis. Differences were considered significant when the P value was less than 0.05. The statistical data were obtained using the SPSS 13.0 software package (SPSS Inc., Chicago, IL, USA).

Results

Positive HIF-1 α expression was primarily shown on cytoplasm and nuclei (Fig. 1). The positive expression of HIF-1 α was identified in 69.9% (51/73) of all cases. Table I showed that HIF-1 α expression correlated significantly with pT (pT1 0.0%, pT2 67.3%, pT3 85.7%; $p = 0.008$) and pTNM stage (pI 0.0%, pII 67.2%, pIII 100.0%; $p = 0.002$).

The positive VEGF expression was shown primarily on cytoplasm (Fig. 2). The positive expression of

Table I. Correlation between HIF-1 α and VEGF expression and clinicopathological features of the patients with oesophageal squamous cell carcinoma

CLINICAL FEATURES	PATIENTS (N = 73)	HIF-1 α			VEGF			DUAL HIF-1 α AND VEGF		
		NEGATIVE (N = 22)	POSITIVE (N = 51)	P	NEGATIVE (N = 27)	POSITIVE (N = 46)	P	NEGATIVE (N = 36)	POSITIVE (N = 37)	P
Gender				0.289*			0.522*			0.754*
Male	62	17	45		22	40		30	32	
Female	11	5	6		5	6		6	5	
Age, years				0.613*			0.234			0.102
< 60	34	9	25		10	24		13	21	
\geq 60	39	13	26		17	22		23	16	
Differen- tiation				0.074*			0.989*			0.591*
Good	13	7	6		5	8		8	5	
Moderate	46	13	33		17	29		22	24	
Poor	14	2	12		5	9		6	8	
pT				0.008*			0.005*			0.025*
pT1	3	3	0		3	0		3	0	
pT2	49	16	33		21	28		27	22	
pT3	21	3	18		3	18		6	15	
pN				0.295*			0.045*			0.008*
-	45	16	29		21	24		28	17	
+	28	6	22		6	22		8	20	
pTNM				0.002*			0.027*			0.014*
pI	3	3	0		3	0		3	0	
pII	58	19	39		22	36		31	27	
pIII	12	0	12		2	10		2	10	

P - χ^2 test, * - Fisher's exact probability test; pT - tumour invasion; pN - lymph node metastasis; pTNM - tumour stage; HIF-1 α - hypoxia-inducible factor 1 α ; VEGF - vascular endothelial growth factor

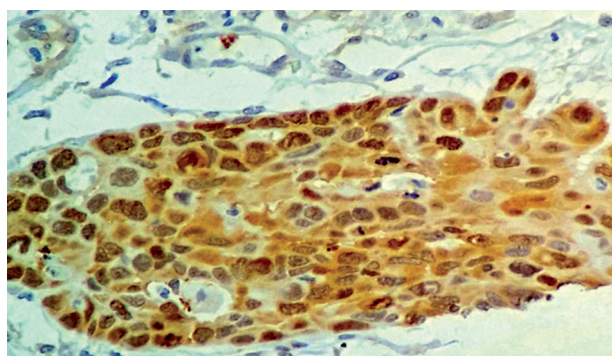


Fig. 1. Immunohistochemical staining of OSCC tissue sections demonstrating positive expression of HIF-1 α (original magnification 400 \times)

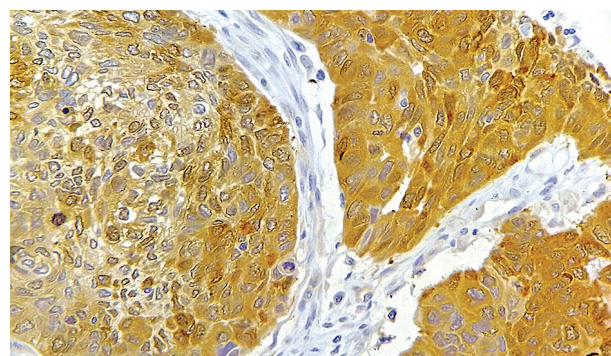


Fig. 2. Immunohistochemical staining of OSCC tissue sections demonstrating positive expression of VEGF (original magnification 400 \times)

VEGF was identified in 63.0% (46/73) of all cases. Table I shows that VEGF expression was significantly correlative with pT (pT1 0.0%, pT2 57.1%, pT3 85.7%; $p = 0.005$), pN (negative 53.3%, positive

78.6%; $p = 0.045$), and pTNM stage (pI 36.8%, pII 65.1%, pIII 88.2%; $p < 0.05$).

Table II shows that HIF-1 α and VEGF expression had a significantly positive correlation ($p = 0.010$).

Dual positive expression of HIF-1 α and VEGF was identified in 50.7% (37/73) of cases. Moreover, it was significantly correlative with pT (pT1 0.0%, pT2 46.6%, pT3 71.4%; $p = 0.025$), pN (negative 37.8%, positive 71.4%; $p = 0.008$), and pTNM stage (pI 0.0%, pII 46.6%, pIII 83.3%; $p = 0.014$), as shown in Table I.

After undergoing operations, 48 patients had chemotherapy and 27 had radiotherapy. The 5-year survival rate for the 73 OSCC patients was 39.7%. In the log-rank test with univariate analysis, the OSCC patients' 5-year survival rate was significantly correlative with pT ($p < 0.05$), pN ($p < 0.01$), pTNM stage ($p < 0.01$), VEGF expression ($p < 0.01$), and dual expression of HIF-1 α and VEGF ($p < 0.01$; Fig. 3, Table III). In the Cox regression with multi-

variate analysis, pN and dual expression of HIF-1 α and VEGF were the independent prognostic factors on the 5-year survival rate of the OSCC patients (Table IV).

Table II. Correlation between HIF-1 α and VEGF expression in the patients with oesophageal squamous cell carcinoma

VARIABLE	Rs	P
HIF-1 α	0.301	0.010
VEGF		

P – Spearman's rank correlation; *Rs* – rank correlation coefficient; HIF-1 α – hypoxia-inducible factor 1 α ; VEGF – vascular endothelial growth factor

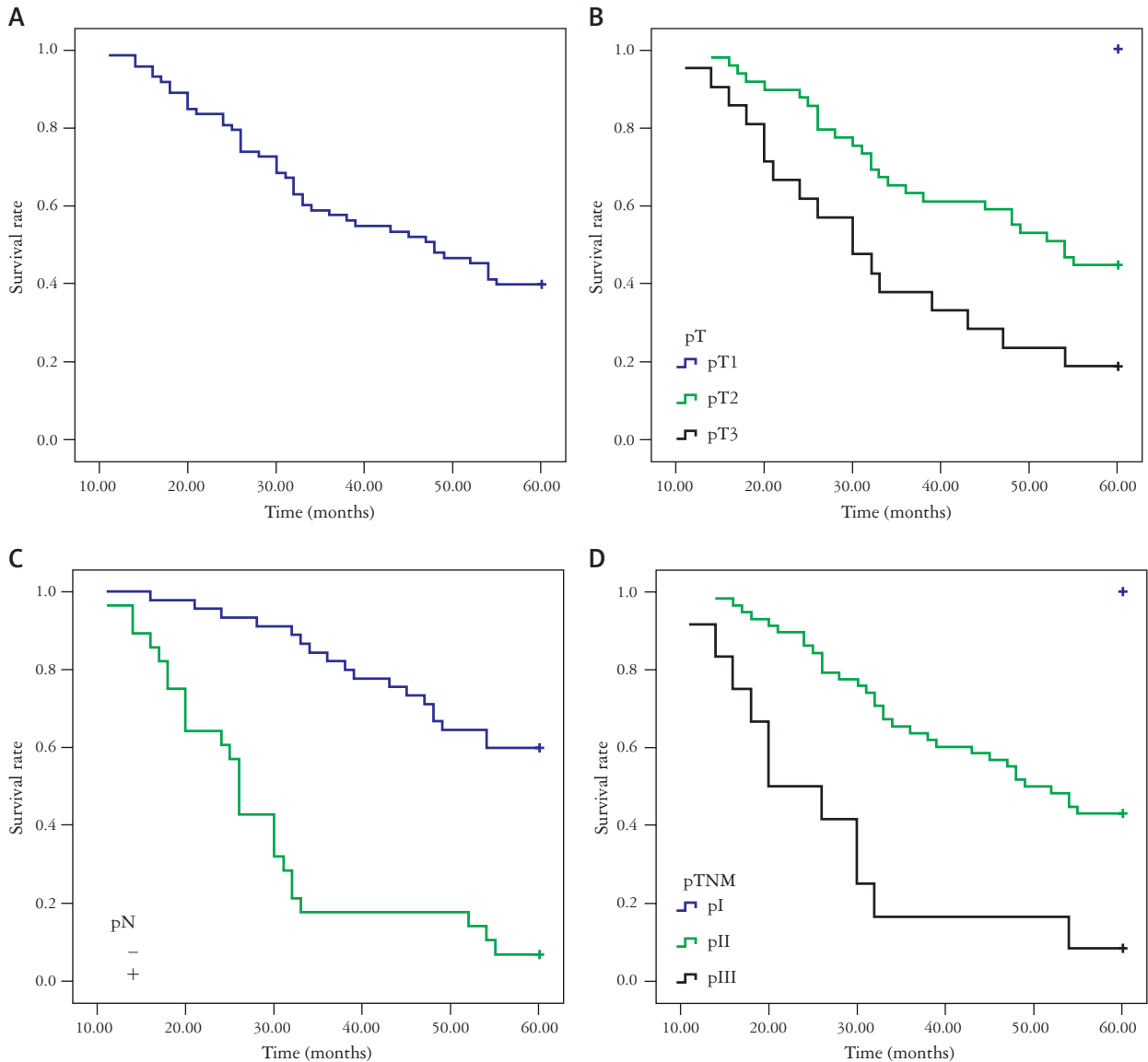


Fig. 3. Kaplan-Meier analysis of the overall survival rate after operation (A), in patients with pT (B), and in patients with pTNM stage (C)

Table III. Univariate analysis with respect to 5-year survival of the patients with oesophageal squamous cell carcinoma

CLINICAL FEATURES	PATIENTS (N = 73)	5-YEAR SURVIVAL (%) PATIENTS 29	RATE (%) 39.7	P
Gender				0.120
Male	62	22	35.5	
Female	11	7	63.6	
Age, year				0.422
< 60	34	12	35.3	
≥ 60	39	17	43.6	
Differentiation				0.535
Good	13	6	46.2	
Moderate	46	18	39.1	
Poor	14	5	35.7	
pT				0.006
pT1	3	3	100	
pT2	49	22	44.9	
pT3	21	4	19.0	
pN				0.001
-	45	27	60.0	
+	28	2	7.1	
pTNM				0.001
pI	3	3	100	
pII	58	25	43.1	
pIII	12	1	8.3	
Chemotherapy				0.481
No	25	12	48.0	
Yes	48	17	35.4	
Radiotherapy				0.457
No	46	20	43.5	
Yes	27	9	33.3	
HIF-1α				0.099
Negative	22	11	50.0	
Positive	51	18	35.3	
VEGF				0.001
Negative	27	21	77.8	
Positive	46	8	17.4	
Dual HIF-1α and VEGF				0.001
Negative	36	24	66.7	
Positive	37	5	13.5	

P – Log-rank test; SCC – squamous cell carcinoma; ADC – adenocarcinoma; pT – tumour invasion; pN – lymph node metastasis; pTNM – tumour stage; HIF-1α – hypoxia-inducible factor 1α; VEGF – vascular endothelial growth factor

Discussion

In 1999, Zhong *et al.* provided the first clinical data showing that HIF-1α might play an important role in human cancer progression [12]. Since then, more and more literature has reported the relationship between HIF-1α expression and clinical characteristics of tumourous cancers. Sun *et al.* [13] used meta-analysis to sum up 16 studies and HIF-1α expression was detected by IHC. They concluded that HIF-1α expression was associated with tumour invasion, lymph node metastasis, and advanced pathological stage for OSCC. In their meta-analysis, the prognostic value of HIF-1α for survival in OSCC patients was evaluated only in a few studies, and the results were conflicting. In our study, 69.9% of OSCC patients had HIF-1α expression, and it correlated significantly with pT and pTNM stage. Our results support previous studies and suggest that HIF-1α plays an important clinicopathological role in OSCC. The 5-year survival rate of OSCC patients was 39.7%, and we did not find HIF-1α to be correlative with the 5-year survival rate. Because many downstream genes involving crucial aspects of cancer biology are regulated by HIF-1α, it is reasonable to expect that HIF-1α is the leading biomarker, but it is not the only proposed prognosis marker for OSCC.

Vascular endothelial growth factor is a transcriptional target for HIF-1α. It is regarded as one of the most potent antigenic factors, which can promote vascular permeability [14]. Vascular endothelial growth factor stimulates angiogenesis and is associated with invasion and metastasis in many tumours, including OC. Xu *et al.* [15] used meta-analysis to sum up 17 studies to investigate the associations between VEGF expression and clinicopathological features. They concluded that there was a significantly increased risk for patients with VEGF overexpression to have advanced stage disease. Vascular endothelial growth factor overexpression was moderately associated with a lower grade of differentiation, depth of invasion, and lymph node metastasis. They also showed that VEGF expression had an impact on the survival of OC patients from Asia and patients with OSCC. In our study, 63.0% of OSCC patients had VEGF expression. Vascular endothelial growth factor expression was significantly correlative with pT, pathological lymph node, and pTNM stage. The 5-year survival rate in the negative VEGF expression group was significantly higher than that in the positive VEGF expression group. However, VEGF was not a relevant independent factor for the 5-year survival rate. Our result demonstrated that VEGF expression was associated with invasion and metastasis in OSCC patients.

Most of the previous reports are mainly on HIF-1α expression or VEGF expression alone, and few studies combine them. In Terashima's report, VEGF expres-

Table IV. Results of cox regression multivariate 5-year survival analysis of the patients with oesophageal squamous cell carcinoma

	B	SE	WALD	P	HR	95% CI FOR HR
Gender	0.288	0.601	0.229	0.632	1.333	0.410~4.333
Age	0.105	0.341	0.096	0.757	1.111	0.570~2.166
Differentiation	0.354	0.306	1.336	0.248	1.425	0.782~2.597
pT	0.909	0.593	2.351	0.125	2.481	0.777~7.927
pN	1.662	0.484	11.778	0.001	5.269	2.040~13.613
pTNM	0.604	0.732	0.680	0.409	0.547	0.130~2.296
Chemotherapy	0.249	0.393	0.402	0.526	0.780	0.361~1.683
Radiotherapy	0.017	0.384	0.002	0.965	0.983	0.463~2.087
HIF-1 α	1.926	1.148	2.816	0.093	0.146	0.015~1.382
VEGF	0.595	0.671	0.787	0.375	1.813	0.487~6.746
Dual HIF-1 α and VEGF	2.703	1.253	4.653	0.031	14.928	1.280~174.070

B – regression coefficient; *SE* – standard error; *Wald* – Wald value; *HR* – hazard ratio; *CI* – confidence interval; *pT* – tumour invasion; *pN* – lymph node metastasis; *pTNM* – tumour stage; *HIF-1 α* – hypoxia-inducible factor 1 α ; *VEGF* – vascular endothelial growth factor

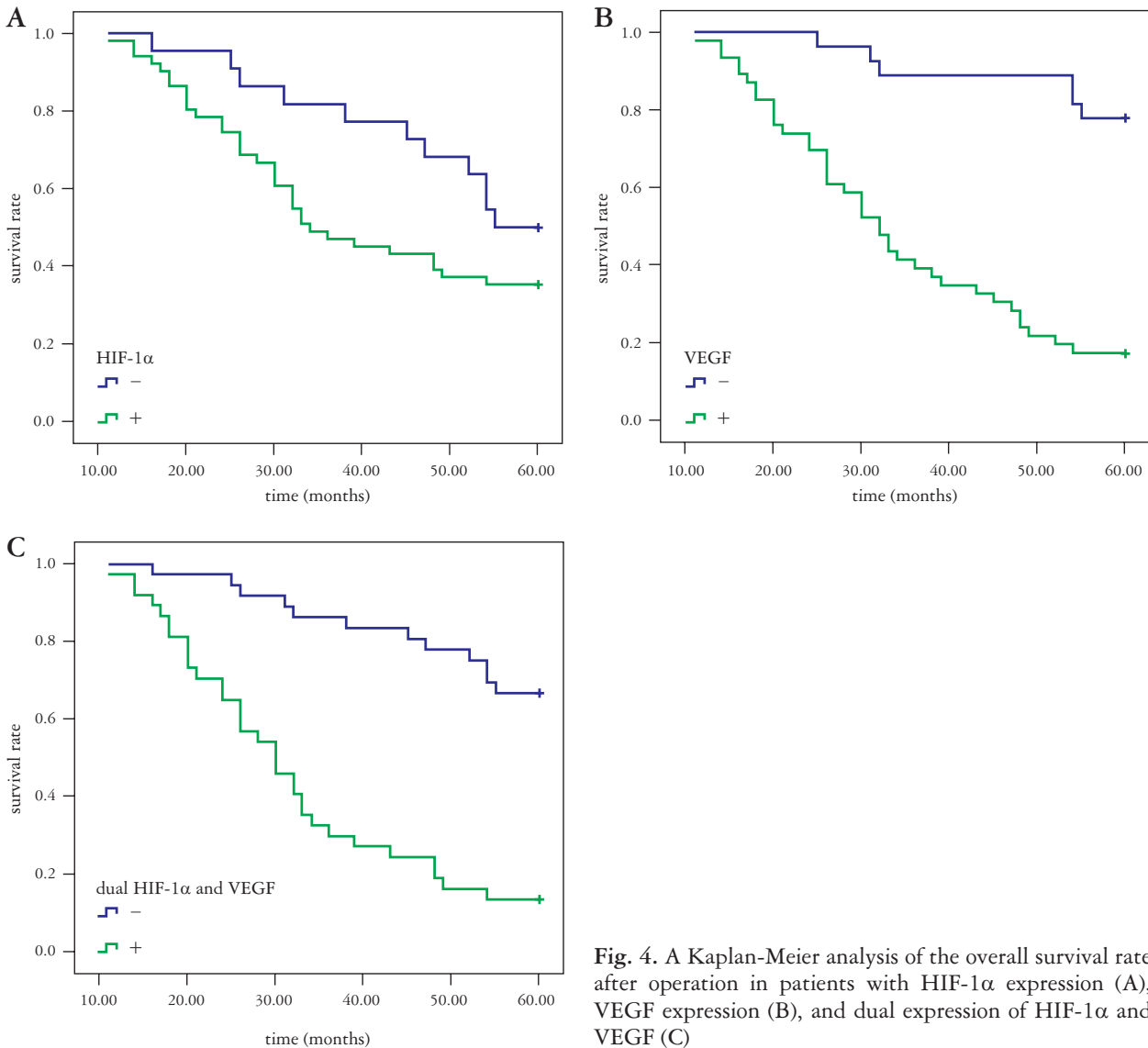


Fig. 4. A Kaplan-Meier analysis of the overall survival rate after operation in patients with HIF-1 α expression (A), VEGF expression (B), and dual expression of HIF-1 α and VEGF (C)

sion could be regulated by HIF-1 α in OC spheroids *in vivo* [16]. Takala *et al.* detected HIF-1 α and VEGF expression using immunohistochemistry from 88 OC patients, and they identified that there was also a tendency for association between HIF-1 α and VEGF immunoreactivity ($p = 0.073$) [17]. Kimura detected HIF-1 α expression and VEGF expression both in OSCC cell lines and human OSCC tissue, and concluded that HIF-1 α expression correlated significantly with VEGF expression both at mRNA and protein levels. Moreover, they found that both HIF-1 α and VEGF immunohistochemical expression correlated with microvessel density (MVD) by light microscopy. The survival rate of OSCC patients with both high expression HIF-1 α and positive VEGF expression was significantly lower than that of the negative group in univariate analysis. [18]. Our study showed that HIF-1 α expression was positively related to VEGF expression in cancer tissues. Dual positive HIF-1 α and VEGF expression was identified in 50.7% of cases. It was significantly correlative with pT, pN, and pTNM stage. The 5-year survival rate for the dual positive expression of HIF-1 α and VEGF group was significantly lower than that of the negative group. The results of multivariate analysis showed that pN and dual HIF-1 α and VEGF expression were relevant independent factors for the 5-year survival rate. Our data demonstrated that HIF-1 α and VEGF worked synergistically in invasion, metastasis, and poor survival in the OSCC patients.

In China, therapeutic regimens not only rely on doctors' advice, but also on patients' desirability and economic condition. In our study, 48 patients had postoperative chemotherapy, and 27 had postoperative radiotherapy. However, no statistically significant correlations with postoperative radiotherapy and chemotherapy were demonstrated for the 5-year survival rate with either univariate or multivariate analysis.

In conclusion, HIF-1 α and VEGF work synergistically in invasion and metastasis of OSCC. Hypoxia inducible factor 1 α combined with VEGF enables more accurate prediction in the prognosis of OSCC patients.

Our study was funded by the Second Group of Jinan Science and Technology Development Program (No. 201602204) and the National Natural Science Foundation of China (No.81502525).

The authors declare no conflict of interest.

References

1. Ping W, Sun W, Zu Y, et al. Clinicopathological and prognostic significance of hypoxia-inducible factor-1 α in esophageal squamous cell carcinoma: a meta-analysis. *Tumour Biol* 2014; 35: 4401-4409.
2. Sun ZG, Yu L, Yang F, et al. Mucin 1 expression correlates with metastatic recurrence in postoperative patients with esophageal squamous cell cancer. *Pol J Pathol* 2016; 67: 384-391.

3. Kleespies A, Bruns CJ, Jauch KW. Clinical significance of VEGF-A, -C and -D expression in esophageal malignancies. *Onkologie* 2005; 28: 281-288.
4. Swartz JE, Pothan AJ, Stegeman I, et al. Clinical implications of hypoxia biomarker expression in head and neck squamous cell carcinoma: a systematic review. *Cancer Med* 2015; 4: 1101-1116.
5. Giatromanolaki A, Harris AL. Tumour hypoxia, hypoxia signalling pathways and hypoxia inducible factor expression in human cancer. *Anticancer Res* 2001; 21: 4317-4324.
6. Fu Z, Chen D, Cheng H, et al. Hypoxia-inducible factor-1 α protects cervical carcinoma cells from apoptosis induced by radiation via modulation of vascular endothelial growth factor and p53 under hypoxia. *Med Sci Monit* 2015; 21: 318-325.
7. Peng J, Shao N, Peng H, et al. Prognostic significance of vascular endothelial growth factor expression in esophageal carcinoma: a meta-analysis. *J BUON* 2013; 18: 398-406.
8. Katsuta M, Miyashita M, Makino H, et al. Correlation of hypoxia inducible factor-1 α with lymphatic metastasis via vascular endothelial growth factor-C in human esophageal cancer. *Exp Mol Pathol* 2005; 78: 123-130.
9. Ogawa K, Chiba I, Morioka T, et al. Clinical significance of HIF-1 α expression in patients with esophageal cancer treated with concurrent chemoradiotherapy. *Anticancer Res* 2011; 31: 2351-2359.
10. Ogata Y, Fujita H, Yamana H, et al. Expression of vascular endothelial growth factor as a prognostic factor in node-positive squamous cell carcinoma in the thoracic esophagus: long-term follow-up study. *World J Surg* 2003; 27: 584-589.
11. Choi JY, Jang KT, Shim YM, et al. Prognostic significance of vascular endothelial growth factor expression and microvessel density in esophageal squamous cell carcinoma: comparison with positron emission tomography. *Ann Surg Oncol* 2006; 13: 1054-1062.
12. Zhong H, De Marzo AM, Laughner E, et al. Overexpression of hypoxia-inducible factor 1 α in common human cancers and their metastases. *Cancer Res* 1999; 59: 5830-5835.
13. Sun G, Hu W, Lu Y, et al. A meta-analysis of HIF-1 α and esophageal squamous cell carcinoma (ESCC) risk. *Pathol Oncol Res* 2013; 19: 685-693.
14. Peng J, Shao N, Peng H, et al. Prognostic significance of vascular endothelial growth factor expression in esophageal carcinoma: a meta-analysis. *J BUON* 2013; 18: 398-406.
15. Xu XL, Ling ZQ, Chen W, et al. The overexpression of VEGF in esophageal cancer is associated with a more advanced TMN stage: a meta-analysis. *Cancer Biomark* 2013; 13: 105-113.
16. Terashima J, Sampei S, Iidzuka M, et al. VEGF expression is regulated by HIF-1 α and ARNT in 3D KYSE-70, esophageal cancer cell spheroids. *Cell Biol Int* 2016; 40: 1187-1194.
17. Takala H, Saarnio J, Wiik H, et al. HIF-1 α and VEGF are associated with disease progression in esophageal carcinoma. *J Surg Res* 2011; 167: 41-48.
18. Kimura S, Kitadai Y, Tanaka S, et al. Expression of hypoxia-inducible factor (HIF)-1 α is associated with vascular endothelial growth factor expression and tumour angiogenesis in human oesophageal squamous cell carcinoma. *Eur J Cancer* 2004; 40: 1904-1912.

Address for correspondence

Zhi-Gang Sun

Department of Thoracic Surgery
Jinan Central Hospital Affiliated to Shandong University
Shandong University
250013 Jinan, Shandong Province
People's Republic of China
e-mail: sunszg@126.com