

## CASE REPORT

**COMPLEX GRADE III ASTROCYTOMA WITH GRANULAR CELLS AND PXA FEATURES IN A PATIENT WITH TUBEROUS SCLEROSIS COMPLEX (BOURNEVILLE-PRINGLE SYNDROME) – CASE REPORT AND REVIEW OF LITERATURE**

ANNA MUCHA-MAŁECKA<sup>1</sup>, KRZYSZTOF MAŁECKI<sup>2,3</sup>, MICHAŁ KURZYŃSKI<sup>4</sup>, DARIUSZ ADAMEK<sup>5</sup>,  
BEATA BIESAGA<sup>6,7</sup>, KONRAD URBANEK<sup>1</sup>, ALEKSANDRA GRELA-WOJEWODA<sup>8</sup>, ELŻBIETA PLUTA<sup>1</sup>,  
ANNA PATLA<sup>1</sup>, MACIEJ MODRZEJEWSKI<sup>1</sup>, PAWEŁ BLECHARZ<sup>9</sup>, NATALIA AMROGOWICZ<sup>10</sup>

<sup>1</sup>Department of Radiotherapy, Maria Skłodowska-Curie National Research Institute of Oncology, Krakow Branch, Poland

<sup>2</sup>Department of Radiotherapy for Children and Adults, University Children's Hospital of Krakow, Poland

<sup>3</sup>Jagiellonian University in Cracow, Faculty of Health Sciences, Krakow, Poland

<sup>4</sup>Amethyst Radiotherapy Poland, Krakow, Poland

<sup>5</sup>Department of Pathology, Jagiellonian University Medical College, Krakow, Poland

<sup>6</sup>Center for Translational Research and Molecular Biology of Cancer, Maria Skłodowska-Curie National Research Institute of Oncology, Gliwice Branch, Poland

<sup>7</sup>Department of Tumour Pathology, Maria Skłodowska-Curie National Research Institute of Oncology, Krakow Branch, Poland

<sup>8</sup>Department of Clinical Oncology, Maria Skłodowska-Curie National Research Institute of Oncology, Krakow Branch, Poland

<sup>9</sup>Gynecologic Oncology Department, Maria Skłodowska-Curie National Research Institute of Oncology, Krakow Branch, Poland

<sup>10</sup>I Radiation and Clinical Oncology Department, Maria Skłodowska-Curie National Research Institute of Oncology, Gliwice Branch, Poland

---

Tuberous sclerosis complex (Bourneville-Pringle syndrome) is a rare genetic condition included in the group of diseases called phakomatoses. Most of the patients are diagnosed with abnormalities within the central nervous system and tend to develop tumors more frequently, especially gliomas. We present a case of 50-year-old patient suffering from tuberous sclerosis complex, who had been diagnosed with pleomorphic xanthoastrocytoma (PXA). The patient underwent surgery and adjuvant radiotherapy and has remained free from local recurrence for 5 years.

**Key words:** pleomorphic xanthoastrocytoma, tuberous sclerosis complex, Bourneville-Pringle syndrome, surgery, radiotherapy.

---

## Introduction

Tuberous sclerosis complex (Bourneville-Pringle syndrome) is a rare genetic condition included in the group of diseases called phakomatoses. It is a multi-

organ syndrome with a wide clinical spectrum. Lesions in kidneys, lungs, heart, musculoskeletal system, skin and eyes can be observed. Most of the patients are diagnosed with abnormalities within the central nervous system (CNS) [1]. The presence of

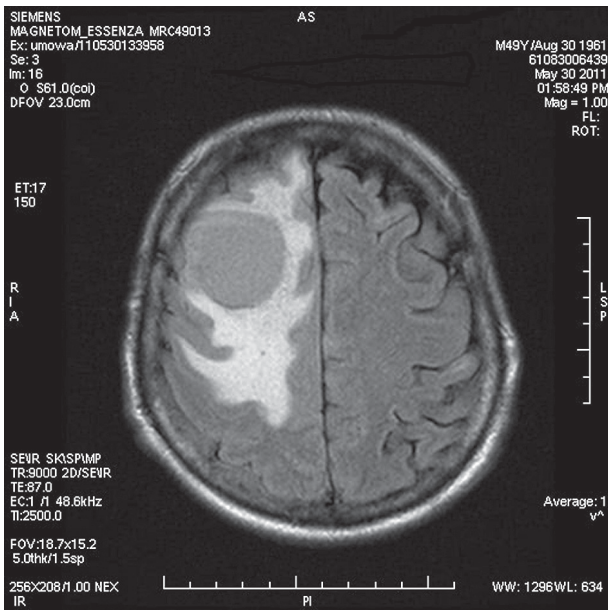


Fig. 1. MRI scan – right frontal lobe tumor surrounded by edema

subependymal paraventricular nodes is a frequently observed phenomenon. Patients with tuberous sclerosis complex (TSC) tend to develop CNS tumors more frequently, especially gliomas. We present a case of a patient suffering from TSC, who had been diagnosed with complex grade III astrocytoma with granular cells and PXA features.

To the best of our knowledge, there is no report of PXA associated with tuberous sclerosis as well as no report of granular cell astrocytoma published so far.

### Case report

A 50-year-old patient was admitted to a neurology department because of left-side muscle weakness. Other symptoms were abnormal speech, disorientation and slight central facial palsy. In past the patient was diagnosed due to TSC, based on the presence of numerous angiofibromas (Pringle tumors) covering face, subependymal nodules and molecular testing (TSC1 mutation present). Magnetic resonance imaging (MRI) scan revealed the presence of a tumor measuring  $44 \times 43 \times 39$  mm, located in right frontal lobe. The lesion was solid, contained a liquid compartment, and was surrounded by edema (Fig. 1). The patient had to be referred to a neurosurgery clinic, where he underwent tumor resection. Histopathology report was unclear – possible diagnoses were: low grade astrocytoma or vascular lesion with secondary gliosis. No further treatment was applied and after six months of observation local recurrence was revealed in control MRI scan. The patient underwent re-surgery.

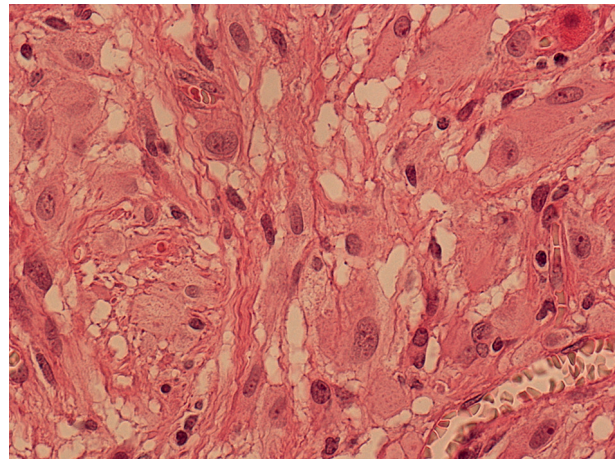


Fig. 2. Typical prominent cellular and nuclear polymorphism of PXA can be seen; some large cells with conspicuous (and characteristic) microvacuolation of cytoplasm. HE

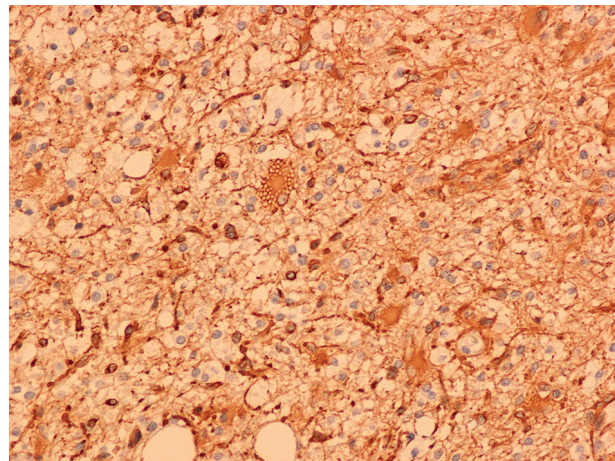


Fig. 3. Strong GFAP immunopositivity. GFAP

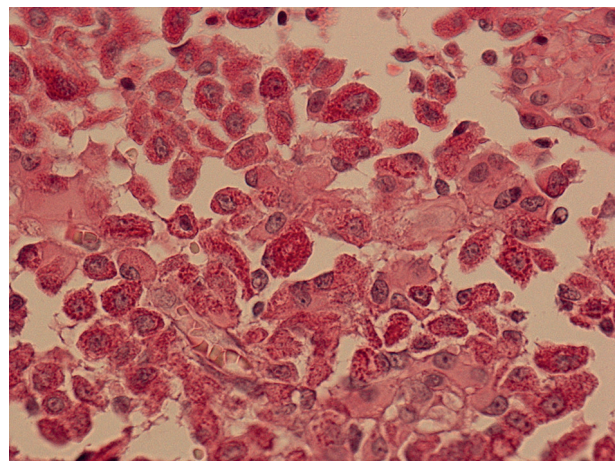


Fig. 4. Relatively monomorphic cells with abundant gently or coarsely granular cytoplasm corresponding to rare but aggressive form of astrocytoma known as granular cell astrocytoma. HE



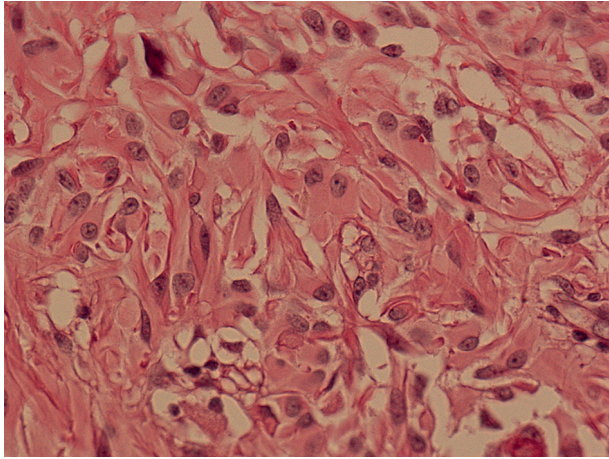


Fig. 5. Large and somewhat elongated astrocytes with glassy cytoplasm, typical for subependymal giant cell astrocytomas (SEGAs). HE

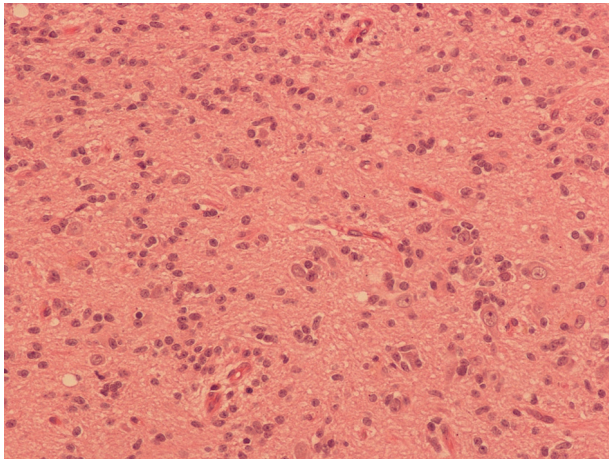


Fig. 6. Brain cortex invaded by tumor cells resembling oligodendroglioma. HE

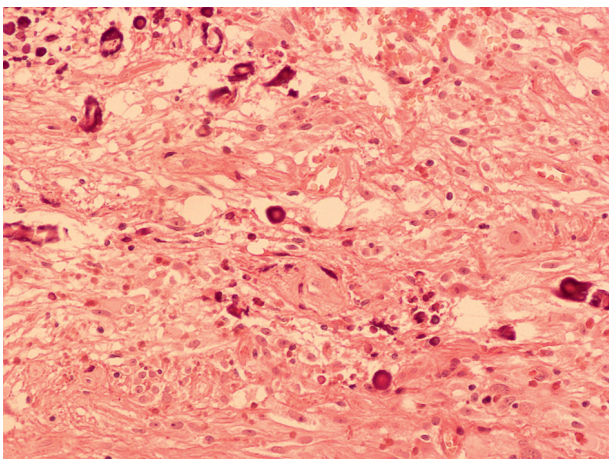


Fig. 7. Some dispersed calcifications within the tumor. HE

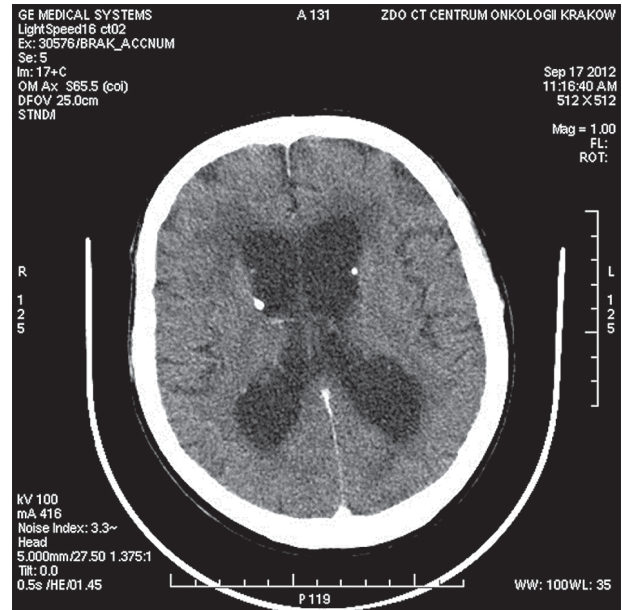


Fig. 8. CT scan – subependymal calcifications in lateral ventricles

The histopathological examination of the resected material showed glial neoplasm of a very complex morphology. It was a glioma formed by large pleomorphic neoplastic cells, including giant cells with bizarre nuclei and abundant vacuolated cytoplasm (Fig. 2) and showing glial fibrillary acidic protein (GFAP) immunopositivity (Fig. 3). Some aggregates of lymphocytes within the tumor were also seen. This picture justified the diagnosis of PXA. However, a considerable portion of the tumor showed relatively monomorphic medium-sized cells with eccentric nuclei with prominent nucleoli and cytoplasm heavy loaded with eosinophilic granules (Fig. 4). This histology is typical for a rare variant of astrocytoma – so called “granular cell astrocytoma”. Finally, a part of the tumor was composed of large astrocytes with glassy cytoplasm (Fig. 5) that resembled morphologically the cells typically occurring in subependymal giant cell astrocytomas (SEGAs) – very well known as being associated with tuberous sclerosis. Though PXA is a grade II glioma, granular cell astrocytoma is regarded as biologically more aggressive and corresponding to grade III. Moreover, there were also regions of brain cortex invaded by tumor cells in a form of ‘satellitosis’ and, hence, resembling oligodendroglioma (Fig. 6). Some calcifications were scattered among tumor cells (Fig. 7). Mitotic activity was not conspicuous, but there were features of extensive necrosis, which, together with “granular cell astrocytoma” pattern led to the diagnosis of grade III glioma and the PXA-type pattern was regarded as most characteristic for this peculiar neoplasm; however, the tumor in fact had a quite unique cellular

composition. No BRAF mutation was found in the material tested with real time – PCR test (RT-PCR).

Following surgery, due to WHO grade and recurrence of the disease, the patient was referred to radiation therapy. He received 60 Gy in 30 fractions to the tumor bed. Conformal radiotherapy was used. No significant early toxicity occurred during irradiation. After completion of treatment the patient was followed up. CT scans were performed and revealed subependymal calcifications in lateral ventricles. This symptom is a typical phenomenon in TSC (Fig. 8).

The patient has remained free from local recurrence for 5 years.

## Discussion

TSC is a rare genetic disease described for the first time as a new medical condition by Desire-Magloire Bourneville in 1880 [2]. The prevalence of this disease is estimated to be 1 in 6,000 to 10,000 [3]. It is caused by loss-of-function mutations in *TSC1* or *TSC2* genes [4]. Clinical manifestation is very variable and symptoms may occur in each stage of patient's life. Of all phakomatoses, tuberous sclerosis is characterized by probably the most diverse range of tumours that can develop in different organs and sites. The most common are skin lesions, hamartomas as well as malignant tumors that occur more frequently than in healthy individuals. Characteristic skin lesions are: numerous angiofibromas (Pringle tumors) covering face, café au lait spots, and hypomelanotic 'ash leaf' macules [5]. 75 to 85% of patients with TSC develop benign, hamartomatous kidney tumors (angiomyolipomas) [6], which may cause disturbances in organ functioning and increase the risk of malignancy [7]. Children with TSC are diagnosed with heart rhabdomyomas often leading to arrhythmias [8]. Hamartomatous tumors are also observed in other organs, including retina (retinal astrocytic hamartoma) and lungs (lymphangioliomyomatosis) [9]. Typical lesions occurring in central nervous system are cortical tubers, from which the disease is named, and subependymal nodules, which are usually located in the walls of lateral ventricles and tend to calcify, therefore, they can be detected in CT scan. These lesions, though benign, may become the basis for the development of malignant gliomas, mostly subependymal giant-cell astrocytomas (SEGA) [10, 11]. Diagnosis of TSC in our patient was made since typical skin lesions (angiofibromas) and subependymal nodules are two major diagnostic features of the disease [12]. Additionally, the patient underwent molecular tests that confirmed the presence of a mutation in the *TSC1* gene [4].

Pleomorphic xanthoastrocytoma is a very rare type of astroglial malignancy, constituting about 1% of all glial tumours. Differential diagnosis includes

glioblastoma, giant-cell astrocytoma, fibrillary astrocytoma, anaplastic astrocytoma, malignant fibrous histiocytoma, vascular angioma, ganglioglioma or meningioma. Histopathological hallmarks of PXA are: nuclear and cytoplasmic pleomorphism with spindle cells and mononucleated or multinucleated giant stocytes, as well as xanthomatous cells. Various numbers of lymphocytes and plasma cells are also present [13, 14]. This picture could be seen in our patient's microscopic specimens.

According to our knowledge, there is no report of PXA associated with tuberous sclerosis as well as no report of granular cell astrocytoma published so far. Our case represents even more complex neoplastic peculiarity combining PXA and granular cell astrocytoma with SEGA-like (as it was not in periventricular location) and oligodendroglioma-like patterns. Although grade III glioma was diagnosed, the follow-up results do not necessarily confirm the expected malignant behavior. From the practical and diagnostic point of view, this report emphasizes even stronger potential of development of extremely diverse morphological patterns of brain tumors in the course of tuberous sclerosis than was known so far; this has to be taken into account in histopathological diagnosis.

Neurosurgery is the first-line treatment in PXA and granular cell astrocytoma. The role of radiotherapy and systemic treatment is still unclear, due to the fact that available literature is based on small studies. Irradiation to dose of 30-60 Gy should be considered in patients after non-radical surgery [15] or in malignant, anaplastic cases of PXA [16]. In our case, the patient was referred to postoperative radiotherapy because of WHO grade III, and received 60 Gy in 30 fractions. Application of chemotherapy in this tumor type is casuistic, since studies on larger group of patients were not performed. Prognosis in PXA is relatively favorable, 10-year overall- and relapse-free survival range from 60 to 70% [17, 18].

## Conclusions

The case described above shows how variable the clinical course of TSC can be and why it is so important to take under consideration the possibility of development of CNS tumors in patients suffering from this syndrome. PXA itself requires further studies of its genetics, histopathology and clinical course that could lead to better assessment of treatment modalities.

*The authors declare no conflict of interest.*

## References

1. Peron A, Northrup H. Tuberous sclerosis complex. *Am J Med Genet Part C* 2018; 178C: 274-277.



2. Brigo F, Lattanzi S, Trinka E, et al. First descriptions of tuberous sclerosis by Désiré-Magloire Bourneville (1840-1909). *Neuropathology* 2018; 38: 577-582.
3. O'Callaghan FJ, Shiell AW, Osborne JP, Martyn CN. Prevalence of tuberous sclerosis estimated by capture – recapture analysis. *Lancet* 1998; 351: 1490.
4. Caban C, Khan N, Hasbani DM, Crino PB. Genetics of tuberous sclerosis complex: implications for clinical practice. *Appl Clin Genet* 2016; 10: 1-8.
5. Strowd RE, Strowd LC, Blakeley JO. Cutaneous manifestations in neuro-oncology: clinically relevant tumor and treatment associated dermatologic findings. *Semin Oncol* 2016; 43: 401-407.
6. Dallos G, Chmel R, Alföldy F, et al. Bourneville-Pringle disease for kidney transplantation: a single-center experience. *Transplant Proc* 2006; 38: 2823-2824.
7. Crino PB, Nathanson KL, Henske EP. Medical Progress: The Tuberous Sclerosis Complex. *N Eng J Med* 2006; 355: 1345-1356.
8. Martinez-Garcia A, Michel-Macias C, Cordero-Gonzalez G, et al. Giant left ventricular rhabdomyoma treated successfully with everolimus: case report and review of literature. *Cardiol Young* 2018; 15: 1-7.
9. Gupta N, Henske EP. Pulmonary manifestations in tuberous sclerosis complex. *Am J Med Genet Part C* 2018; 178C: 326-337.
10. Curatolo P, Moavero R, de Vries PJ. Neurological and neuropsychiatric aspects of tuberous sclerosis complex. *Lancet Neurol* 2015; 14: 733-745.
11. Lu DS, Karas PJ, Krueger DA, Weiner HL. Central nervous system manifestations of tuberous sclerosis complex. *Am J Med Genet Part C* 2018; 178C: 291-298.
12. Northrup H, Krueger DA; International Tuberous Sclerosis Complex Consensus Group. Tuberous sclerosis complex diagnostic criteria update: Recommendations of the 2012 International Tuberous Sclerosis Complex Consensus Conference. *Pediatr Neurol* 2013; 49: 243-254.
13. Zorzi F, Facchetti F, Baronchelli C, Cani E. Pleomorphic xanthoastrocytoma: an immunohistochemical study of three cases. *Histopathology* 1992; 20: 267-269.
14. Loiseau H, Rivel J, Vital C, et al. Pleomorphic xanthoastrocytoma: Apropos of 3 new cases. Review of the literature. *Neurochir* 1991; 37: 338-347.
15. Naidich MJ, Walker MT, Gottardi-Littell NR, et al. Cerebellum pleomorphic xanthoastrocytoma in a patient with neurofibromatosis type 1. *Neuroradiology* 2004; 46: 825-829.
16. Gil-Gouveia R, Cristino N, Farias JP, et al. Pleomorphic xanthoastrocytoma of the cerebellum: illustrated review. *Acta Neurochir* 2004; 146: 1241-1244.
17. Kepes JJ, Rubinstein LJ, Eng LF. Pleomorphic xanthoastrocytoma: a distinctive meningocerebral glioma of young subjects with relatively favorable prognosis. A study of 12 cases. *Cancer* 1979; 44: 1839-1852.
18. Giannini C, Scheithauer BW, Burger PC, et al. Pleomorphic xanthoastrocytoma. What Do We Really Know about It? *Cancer* 1999; 85: 2033-45.

### Address for correspondence

**Anna Mucha-Malecka**  
Department of Radiotherapy  
Maria Skłodowska-Curie National Research Institute of Oncology  
Krakow Branch  
Garncarska 11  
31-115 Krakow, Poland  
e-mail: annamucham@o2.pl