

SHORT COMMUNICATION

AN UNUSUAL SHAPED MASS FILLING THE RIGHT CARDIAC CHAMBERS IN A WOMAN WITH A VASCULAR MALFORMATIONCRISTIAN PODOLEANU¹, SORIN BALOS², SIMONA STOLNICU³¹Cardiology Department, George Emil Palade University of Medicine, Pharmacy, Science, and Technology of Targu Mures, Romania²Cardiovascular Surgery Department, Sf. Constantin Hospital, Brasov, Romania³Pathology Department, George Emil Palade University of Medicine, Pharmacy, Science, and Technology of Targu Mures, Romania

We present an interesting case of a patient with uterine leiomyoma and a vascular abnormality of the internal iliac artery and peri-uterine veins presenting a right intracardiac mass with an extremely unusual and misleading shape, requiring surgical removal and pathological examination to confirm the diagnosis.

Key words: vascular abnormality, right intracardiac mass, ring-shaped thrombus.

Dear Editor,

A-52-year-old female patient was admitted for uncontrolled arterial hypertension and non-sustained palpitations.

The echocardiography revealed an elongated, ring-shaped, highly mobile intracardiac mass apparently extending from the inferior vena cava into the right atrium and penetrating the tricuspid valve into the right ventricle, impairing closure of the tricuspid valve and causing mild tricuspid regurgitation (Fig. 1A). No other abnormalities were found by transthoracic and transoesophageal echocardiography while cardiac magnetic resonance imaging was inconclusive due to the high mobility of the intracardiac mass. Abdominal contrast – computed tomography showed filling defects in the distal segment of the inferior vena cava, arteriovenous fistula involving the left internal iliac artery and peri-uterine veins as well as presence of a 7 cm diameter uterine fibroid associated with multiple subserosal smaller uterine nodules. Biopsy of the largest uterine fibroid revealed proliferation of smooth muscle cells, suggestive for a leiomyoma.

The patient was referred to cardiac surgery for removal of the cardiac mass. Surgically, the intracardiac mass was confirmed to extend from the inferior vena

cava and had to be resected at this level. Macroscopic examination revealed a ring-shaped mass of 4 cm diameter, of grey colour and elastic consistency with a central pinhole, while microscopic examination showed the right intracardiac mass to be an old ring-shaped thrombus, composed of fibrin, red blood cells, platelets, leukocytes, with central neovascularization vessels (Fig. 1B,C).

The differential diagnosis of the highly mobile ring-shaped intracardiac mass included intravenous leiomyomatosis originating from previously documented uterine fibroid [1] as well as an intracardiac thrombus associated with vascular malformation of the peri-uterine veins [2]. The macroscopic aspect and consistency were suggestive for cardiac leiomyomatosis rather than a thrombus, but microscopic examination confirmed the diagnosis [3]. Also, differential diagnosis included right atrial myxoma, a rare and benign tumour, presenting as a sessile, pedunculated cardiac mass, isoechoic with definite margins and with smooth, sometimes friable and gelatinous-like macroscopic appearance and a particular microscopic appearance [4]. A giant Eustachian valve may also mimic a thrombus but appear as a rigid, elongated structure or as a membranous, undulating, echogenic mass [5].

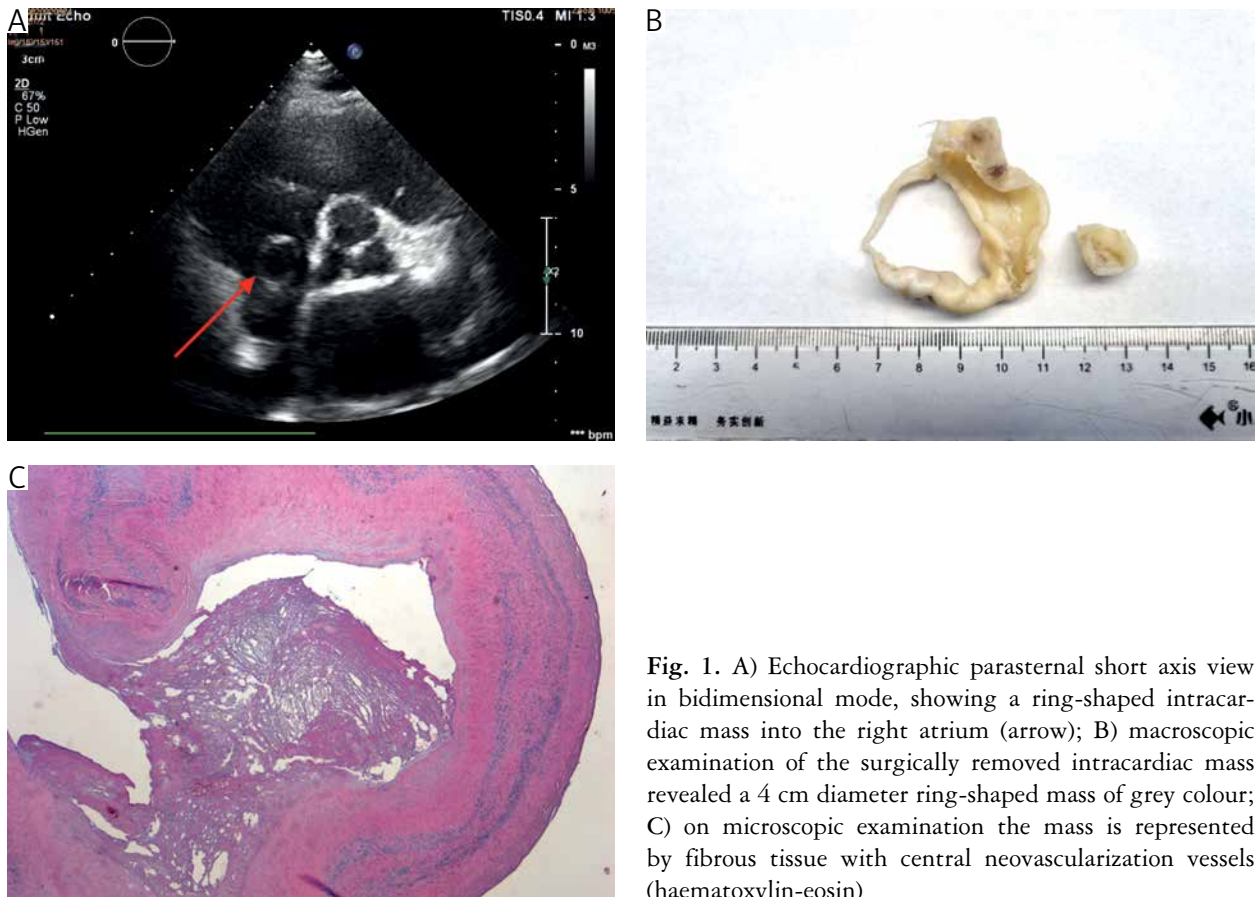


Fig. 1. A) Echocardiographic parasternal short axis view in bidimensional mode, showing a ring-shaped intracardiac mass into the right atrium (arrow); B) macroscopic examination of the surgically removed intracardiac mass revealed a 4 cm diameter ring-shaped mass of grey colour; C) on microscopic examination the mass is represented by fibrous tissue with central neovascularization vessels (haematoxylin-eosin)

The patient was discharged in good condition, was medically treated to prevent pulmonary embolism and to control her blood pressure and was scheduled for hysterectomy.

This case is suggestive for the very rare and unusual presentation of a life-threatening, ring-shaped intracardiac thrombus and emphasizes the limitations of the non-invasive diagnostic techniques used to differentiate the aetiology of intracardiac masses with unusual shape and associated with particular clinical situations, requiring surgical removal and pathological examination to confirm the diagnosis.

The author declares no conflict of interest.

References

1. Kullo IJ, Oh JK, Keeney GL, et al. Intracardiac leiomyomatosis: echocardiographic features. *Chest* 1999; 115: 587-591.
2. Peters PJ, Reinhardt S. The echocardiographic evaluation of intracardiac masses: a review. *J Am Soc Echocardiog* 2006; 19: 230-240.
3. Price JD, Anagnostopoulos C, Benvenisty A, et al. Intracardiac extension of intravenous leiomyomatosis. *Ann Thorac Surg* 2017; 103: e145-e147.
4. Griborio-Guzman AG, Aseyev OI, Shah H, et al. Cardiac myxomas: clinical presentation, diagnosis and management. *Heart* 2022; 108: 827-833.
5. Yavuz T, Nazli C, Kinay O, et al. Giant eustachian valve with echocardiographic appearance of divided right atrium. *Tex Heart Inst J* 2002; 29: 336-338.

Address for correspondence

Simona Stolnicu
 Pathology Department
 George Emil Palade University of Medicine, Pharmacy,
 Science, and Technology of Targu Mures
 Romania
 Phone: +40265215551
 Fax: +40744765716
 e-mail: stolnicu@gmx.net